

Review

Corresponding author*A. Chiappa, MD, FACS**

Professor

Department of Surgery

European Institute of Oncology

via Ripamonti 435 20141

Milan, Italy

Tel. +39 0257489307

E-mail: antonio.chiappa@ieo.it

Volume 1 : Issue 2

Article Ref. #: 1000EMOJ1110

Article HistoryReceived: April 29th, 2015Accepted: June 12th, 2015Published: June 15th, 2015**Citation**

Zbar AP, Wun L, Chiappa A, et al. Primary intra-abdominal hypertension and abdominal compartment syndrome: pathophysiology and treatment. *Emerg Med Open J*. 2015; 1(2): 46-63. doi: [10.17140/EMOJ-1-110](https://doi.org/10.17140/EMOJ-1-110)

Copyright

©2015 Chiappa A. This is an open access article distributed under the Creative Commons Attribution 4.0 International License (CC BY 4.0), which permits unrestricted use, distribution, and reproduction in any medium, provided the original work is properly cited.

Primary Intra-Abdominal Hypertension and Abdominal Compartment Syndrome: Pathophysiology and Treatment

AP Zbar¹, L. Wun², A. Chiappa^{3*}, M. Al-Hashemy⁵, M. Monteleone⁴, C. Ferrari⁴ and S. Parkes⁵¹*School of Human Life Sciences, University of Tasmania, Tasmania, Australia*²*Department of Surgery, Launceston General Hospital Launceston, Tasmania, Australia*³*University Department of Surgery, European Institute of Oncology, Milan, Italy*⁴*Department of Surgery, European Institute of Oncology, Milan, Italy*⁵*Launceston General Hospital, Intensive Care Unit Launceston, Tasmania, Australia***ABSTRACT**

Abdominal Compartment Syndrome (ACS) is a potentially lethal condition caused by various events that produce intra-abdominal hypertension. The most common cause is blunt abdominal trauma. Increasing intra-abdominal pressure causes progressive hypoperfusion and ischemia of the intestines and other peritoneal and retroperitoneal structures. Pathophysiological effects include release of cytokines, production of oxygen free radicals, and decreased cellular formation of adenosine triphosphate. These processes may lead to translocation of bacteria from the gut and intestinal edema, predisposing patients to multiorgan dysfunction syndrome. The consequences of abdominal compartment syndrome are profound and affect many vital body systems. Respiratory, hemodynamic, cardiovascular, renal, and neurological abnormalities are signs of abdominal compartment syndrome. Medical management of critically ill patients with raised intra-abdominal pressure should be instigated early to prevent further organ dysfunction and to avoid progression to ACS. Many treatment options are available and are often part of routine daily management in the ICU (nasogastric, rectal tube, prokinetics, enema, sedation, body position). Some of the newer treatments are very promising options in specific patient populations with raised IAP. Nursing care involves vigilant monitoring for early detection, including serial measurements of intra-abdominal pressure.

KEYWORDS: Intra-abdominal hypertension; Abdominal compartment syndrome; Damage control laparotomy; Laparostomy; Open abdomen.

ABBREVIATIONS: IAH: Intra-Abdominal Hypertension; IAP: Intra-Abdominal Pressure; APP: Abdominal Perfusion Pressure; WSACS: World Society of the Abdominal Compartment Syndrome; HOB: Head of Bed; ICU: Intensive Care Unit; CO: Cardiac Output; ICP: Intra-Cranial Pressure; CPP: Cerebral Perfusion Pressure; CVP: Central Venous Pressure; IVP: Intra-Vesical Pressure; PAOP: Pulmonary Arterial Occlusion Pressure; PCWP: Pulmonary Capillary Wedge Pressure; MABP: Mean Arterial Blood Pressure; GFR: Glomerular Filtration Rate; RBF: Renal Blood Flow; RPP: Renal Perfusion Pressure; PEEP: Positive End-Expiratory Pressure; RVEDV(I): Right Ventricular End-Diastolic Volume (index); MOFS: Multi-Organ Failure Syndrome; SOFA: Sepsis-Related Organ Failure Assessment; V/Q: Ventilation/Perfusion Ratio; SVR: Systemic Vascular Resistance; FRC: Functional Residual Capacity; TAC: Temporary Abdominal Closure; IBP: Intra-Bladder Pressure; IGP: Intra-Gastric Pressure; GRV: Gastric Residual Volume; VAP: Ventilator-Associated Pneumonia.

DEFINITIONS, INCIDENCE AND MEASUREMENT STRATEGIES IN INTRA-ABDOMINAL HYPERTENSION (IAH) AND ABDOMINAL COMPARTMENT SYNDROME (ACS)

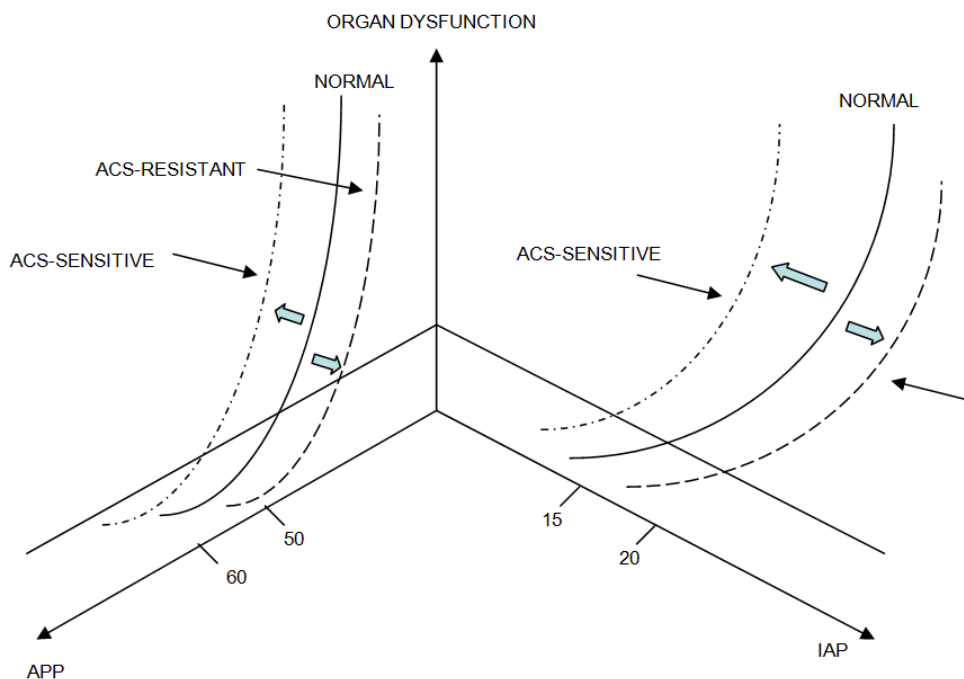
The concept of the Abdominal Compartment Syndrome (ACS) has been rediscovered as a final common pathway of the physiologic sequelae of increased Intra-Abdominal Pressure

(IAP) and Intra-Abdominal Hypertension (IAH). The recent establishment of the World Society of the Abdominal Compartment Syndrome (WSACS: www.wsacs.org) in 2004 and its endorsement by the European Society of Intensive Care Medicine and the Society of Critical Care Medicine has provided the imprimatur of international for a through the three World Congresses on ACS to emphasize the importance of this syndrome and its prodrome as distinct clinical entities in surgical and intensive care practice.¹ Part of this acceptance has been a rediscovery of these entities and of their complex pathophysiology and that of surgical decompression since they were originally highlighted in limb compartments by Richard von Volkmann² and since Abdominal Compartment Hypertension was suggested by Etienne-Jules Marey who was the first to measure intrathoracic pressures in 1863.³ These original descriptions of the syndrome were supplemented by direct abdominal pressure measurements in dogs and the effects of IAP on major venous return and cardiac output by Haven Emerson in 1911,⁴ and establishment of some of the factors which controlled IAP by Helen Coombs.⁵ The coining of the term Abdominal Compartment Syndrome was probably used first by Robert Fietsam of Michigan in 1989 following abdominal aortic aneurysm repair.⁶⁻⁸

There is no strict definition of what represents abnormal IAP, but there is a general acceptance that measured pressures >12 mmHg when recorded 1-6 hours apart are considered to represent IAH, where Sugrue, et al. have shown that this rep-

resents up to 40% of cases admitted to a surgical Intensive Care Unit (ICU).⁹ Although there are biases in the prospective assessment of a selective population admitted to an ICU who actually undergo IAP measurement, there is an inverse correlation between those patients deemed to have IAH who do not have surgical decompression and overall survival.¹⁰ IAP behavior is similar to intra-cranial pressure (ICP) and there is an exponential correlation between organ dysfunction and IAP. The Monroe-Kellie doctrine would dictate an hyperbolic association between ICP and intracranial volume. This is illustrated in Figure 1 which shows that a distinction can be made between IAH, (a recording without organ dysfunction) and a state when the curve shifts to the left where with organ dysfunction the IAH value becomes clinically more critical. The further assumption that the abdomen behaves somewhat similarly to the cranium as a closed box is clearly not accurate. There are anisotropic variable compliances between the abdominal components, some rigidity in the relatively unyielding nature of the thoracic cage, costal margin, spine and pelvis, variability in the amount and type of soft-tissue intestinal and peritoneal distension and *in vivo* differences between the hydrostatic effects on abdominal contents and those dictated by Pascal's Law for *in vitro* systems.¹¹ The latter stating that there is equivalency of transmitted pressure of an incompressible fluid at all points within a connected system is largely true in the absence of significant intra-abdominal adhesions.

The effective definition of ACS would then represent



In each case if the graph shifts to the right, higher IAP and lower APP values may not be associated with significant end-organ dysfunction creating a degree of "ACS-resistance." Shifts to the left would create "ACS-sensitivity" where lower values of IAP (higher APP values) may still be associated with organ dysfunction which might not occur normally. This results in difficulty for broader acceptance of critical IAP and APP levels for individual cases. ACS-sensitivity may potentially occur in patients where there is pre-existing partial end-organ failure, morbid obesity or following fluid hyper-resuscitation in patients with severe burns, haemorrhagic pancreatitis, massive blood loss, widespread intra-peritoneal sepsis and high-output intestinal fistulae.

IAP= Intra-abdominal pressure
APP= Abdominal perfusion pressure¹²
where APP = Mean arterial BP- IAP

Figure 1: Relationship between organ dysfunction, IAP and APP.

a pathophysiological effect as a consequence of raised IAP characterized by a tense abdomen with elevation in peak airway pressures, inadequate spontaneous ventilation and reduced urine output in combination with a documented improvement in these parameters following abdominal decompression.¹³ This stated, that represents pathological IAH in some patients won't have deleterious effects, in others minor variations in IAP will have significant morbidity and mortality. Definitions will then be consequent upon associated organ failure in individual cases,¹⁴ where other parameters such as falling arterial pH, decreased Cardiac Output (CO), rising serum lactate levels, rising peak airway pressures and falling oxygen delivery indices are secondary to the principal definition but not essential for its diagnosis.¹⁵ The same process will be evident after surgery or secondary event rather than in the context of gradual increases in IAP as may occur in ascites or in morbid obesity.^{16,17} This latter definition describes the syndrome secondary ACS which has been reported in patients without abdominal injury but who develop ACS after aggressive fluid resuscitation.¹⁸⁻²¹ The concept of tertiary ACS is ACS redevelops after prophylactic or therapeutic management of primary or secondary ACS cases.²² Such a situation may occur following the definitive closure of the abdominal wall after primary ACS or in the utilization of temporary abdominal closure as part of a damage-control laparotomy.²³

IAH is only a prodrome to a potentially fatal syndrome.²⁴⁻³¹ Interest in direct IAP measurement has been refreshed during the rise of interventional laparoscopy³² as well as part of the management of patients undergoing continuous ambulatory peritoneal dialysis³³ and in patients with intraperitoneal drains which may be readily connected to pressure transducers.³⁴ Most IAP measurements are made *via* a urinary catheter as transmitted IAP; a technique originally described by Kron and colleagues³⁵ showing validation with direct pressure measurements.³⁶ The original technique has the disadvantages of repeated needling and disconnection of the urinary flow tract with the risk of urosepsis, its intermittent measurement nature and debate concerning the optimal volume of bladder instillation for consistent Intra-Vesical Pressure (IVP) measurement without falsely high values being recorded due to detrusor contraction.^{37,38} Modification of this system (where a multi-stopcock attachment is part of a closed system avoiding the use of repeated needling and urinary disconnection) has been made independently by Cheatham³⁹ and Sugrue, et al.⁹ who used a T-piece to obviate violation of the catheter and commercially available devices such as the AbViser two-way valve mechanism for anuric patients⁴⁰ and the Holtech manometric meniscus biofilter system (Holtech Medical, Copenhagen DK) have recently provided an opportunity to use the urine as a pressure transmitting medium as first described for clinical use by Harrahill.⁴¹ This latter system has recently been validated.^{42,43} The recent introduction by Balogh, et al. of continuous IAP measurement *via* a 3-way Foley catheter shows wide agreement with intermittent methodology over a wide range of pressures in general surgical and trauma patients⁴⁴ where these authors recommend its routine use after major abdominal sur-

gery, in severe pancreatitis, major burns and following damage control laparotomy.

Other validated methods of IAP measurement include the nasogastric route as originally suggested by Collee,⁴⁵ misurations can be made *via* a gastrostomy tube or gastric tonometry catheter,⁴⁶ through an oesophageal balloon catheter⁴⁷⁻⁵¹ or from a perfused rectal or trans-uterine catheter similar to that used for anorectal manometry.^{52,53} These trans-intestinal methods are subject to all the disadvantages encountered in any form of gastrointestinal manometry where there may be extraneous migrating motor complexes and where extra-intestinal compliances and viscoelastic properties of the gut during perfusion and release will create alterations in recorded pressure that may not reflect intraperitoneal values.¹¹

Other techniques have estimated IAP from caval catheters (both superior and inferior) which provides a continuous monitoring like a Central Venous Pressure (CVP) line with all its inherent problems, where there is a correlation with Intra-Vesical Pressures but not with gastric or rectal pressures in animal studies⁵⁴ and where superior vena cava pressures poorly correlate with IAP in a ventilated canine model using PEEP variations.⁵⁵ Most recently, a range of catheters for placement *via* the rectal, uterine, vesical or gastric routes have been fitted with microchip transducers for rapid calibration showing a high correlation with other methodologies although there are large variations with this new technique.⁵⁶ Another new technique is the Intra-Gastric Pressure (IGP) monitoring through a Gastro PV (Holtech Medical, Charlottenlund, Denmark). Advantages are potentially large: we can compare Intra-Abdominal Pressure (IAP) values from IGP and Intra-Bladder Pressure (IBP) to study the upper abdominal compartment in particular and to compare with the lower abdominal compartment. The Gastro PV technique reduces the nursing manipulations to measure the Gastric Residual Volume (GRV) and allows more frequent GRV measurements to anticipate possible GRV increases, with a potential to prevent Ventilator-Associated Pneumonia (VAP). An easier method to measure GRV reduces the nursing workload and allows more time to be spent on other activities. Measurement of IGP does not carry a potential risk for urinary tract infections. The cost analysis shows the Gastro PV to be cost-effective, in particular for those cases with large amounts of GRV.¹²

Somewhat akin to the parameter Cerebral Perfusion Pressure (CPP), Cheatham and colleagues have suggested utilization of the parameter Abdominal Perfusion Pressure (APP) where [APP=Mean arterial BP-IAP] as a more reliable guide for the diagnosis of ACS and as part of its management algorithm.⁵⁷ In utilization of the APP, Cheatham, et al. performed a retrospective analysis of patients admitted to a surgical ICU with IAH who underwent IAP monitoring using an intra-vesical method where there was a liberal unit policy towards abdominal decompression.⁵⁸ In this study, logistic regression analysis for a patient group with 53% overall mortality showed IAP, MABP,

APP, arterial lactate, arterial pH, base deficit and urine output to all correlate with patient survival when IAH was present, with APP and arterial lactate being the most significant survival-related variables. Receiver-operating characteristic (ROC) curves generated for both IAP and APP show great similarity although the best APP threshold has proven to be about 50 mm Hg with moderate sensitivity (76%) and a lower specificity (57%) for APP as a predictor for patient survival under these conditions. These results have better ROC features for survival than the use of MABP alone and these findings have been confirmed initially in a small prospective analysis of 8 patients by Malbrain, et al.⁵⁹ designed to evaluate the clinical validity of APP as an end-point and then subsequently in a large mixed ICU cohort.²⁴ In this latter study²⁴ APP was significantly lower in non-survivors where an APP of 60 mmHg had a sensitivity of 55% and a specificity of 76% for predicting survival performing better than IAP in more commonly encountered pressure ranges. It is currently unknown whether APP may have some general value as a critical end-point as the total numbers of IAH patients in this large study were only 18% and ACS was defined in only 2% of cases. These findings have also been confirmed by both the Critically Ill and Abdominal Hypertension (CIAH) and the Critically Ill Renal Failure and Abdominal Hypertension (CIRFAH) multicentre study groups.⁶⁰ In the latter study, outcome did not vary in those patients with designated IAH although non-survivors had a higher overall IAP and a lower APP after day 3, suggesting that sustained increases in IAP of continuously monitored patients, where the overall period of time spent above a critical IAP threshold may be more important to outcome than individual IAP measurements. Clearly, both clinical standardization and validation of IAP measurement methodology (and parameter decision, namely IAP vs. APP) are essential in an effort to define the incidence and severity of IAH for use as a management-decision parameter.

PATHOPHYSIOLOGIC EFFECTS OF INTRA-ABDOMINAL HYPERTENSION

Raised IAP has a deleterious effect on respiratory mechanics, the cardiovascular system, liver and renal function and has an interrelationship with intracranial pressure and the splanchnic circulation.

RESPIRATORY SYSTEM DYNAMICS

Much of the understanding on pulmonary derangements during IAH have been studied in the pneumoperitoneum induced by laparoscopy where there is a diminution of functional residual capacity and pulmonary compliance and an increase in lung and chest wall impedance that mirrors the extent of the IAP rise.^{61,62} Although most of these changes are eminently reversible,⁶³ diaphragmatic function can remain significantly impaired for some time after relief of the pneumoperitoneum.⁶⁴ In ICU patients, the pulmonary effects of IAH will be complicated by ventilation (and its mode), patient position, sedation or the

use of neuromuscular blocking agents, atelectasis, ARDS, infection, massive volume infusion, traumatic lung injury and PEEP; some of which will contribute to a diminution in lung compliance, alveolar de-recruitment and poor gas exchange.⁶⁵

These effects are all exaggerated in ACS, with diaphragmatic elevation compressing basal lung segments, reduction in alveolar dead space and Ventilation/Perfusion (V/Q) mismatch.⁶⁶ Pressures transmitted to the thoracic cage reduce total lung capacity with the principal reduction in compliance resulting from altered chest wall compliance without a definitive effect on the lungs.⁶⁷ Exact interpretations of these changes in compliance are dependent upon the techniques used to measure intra-thoracic pressure and the methodology of lung volume estimates.⁶⁸ The changes occurring in elevated IAP are exaggerations of those induced by general anaesthesia, where atelectasis is promoted but where there are no specific elastic or resistive changes in chest wall properties.⁶⁹ In ACS, there is actually an increase in chest wall elastance which for a given applied airway pressure results in a lower distending force of the lung, the transpulmonary pressure (i.e. $P_{\text{Alveolar}} - P_{\text{Pleural}}$). This is accompanied by a higher pleural pressure with less lung distension,^{70,71} a decreased respiratory system compliance and a rightward shift of the compliance (Pressure/Volume) curve.⁷² In ventilated patients with IAH, the diaphragm moves upwards statically causing lower lobe compression; an effect which is exaggerated if the patient is obese.^{73,74} This effect on Functional residual capacity of the lung (FRC) is offset by abdominal decompression and PEEP which both recruit lung volume and increase the $\text{PaO}_2/\text{FiO}_2$ ratio thereby reducing the alveolar/arterial O_2 pressure differential.^{75,76}

This condition is associated, in animal models, with pulmonary oedema, depressed trans-thoracic lymphatic drainage, high-grade atelectasis and increases in both pulmonary neutrophil infiltrates and extra-vascular lung water content, correlating directly with the level of IAH.⁷⁷ These specific effects of IAH are all reversible with abdominal decompression. The clinical implications of these changes suggest that patients with IAH may develop a secondary ARDS pattern with a cytokine profile and bacterial translocation propensity which creates a ventilator-induced lung change resembling primary ARDS.^{78,79} The ventilator strategy in these patients is specific and distinct from that of an ARDS case where the reduction in FRC and the trend towards pulmonary oedema suggests a role for a greater utilization of muscle relaxation and higher PEEP values despite its risk for barotrauma,⁸⁰ keeping alveoli recruited and open with permissive hypercapnia, a restricted tidal volume and peak inspiratory pressure that more readily permits weaning.^{81,82} In summary the pulmonary effects of IAH are complex with diaphragmatic elevation increasing intra-thoracic and pleural pressure causing a reduction in FRC and all lung volumes commensurate with a restrictive lung deficit combined with basal compression atelectasis, with increases in mean, plateau and peak airway pressures and pulmonary vascular resistance. Static and dynamic chest wall (but not lung) compliance is reduced with hypoxia and hy-

percapnia, reduced oxygen transport, increased dead space ventilation and shunting, alveolar oedema and V/Q mismatch.

CARDIOVASCULAR SYSTEM EFFECTS

In patients with the IAH/ACS complex the causes of cardiac depression are multi-factorial where there is commonly an overlay of haemorrhagic shock, systemic inflammatory response syndrome and the cardiac effects of mechanical ventilation. The principal effect of IAH on the heart is a reduction of pre-load through venous compression and reduced venous return which acts in a pressure-dependent manner.⁸³ This effect is noted in humans during higher pressure laparoscopy where MABP reductions are fluid responsive.⁸⁴ This is exaggerated in hypovolaemic patients and those with limited myocardial reserve where further evidence of reduced pre-load is shown by an increase in femoral vein pressures through peripheral venous pooling with reduced femoral blood flow and pulsatility,⁸⁵ increasing the risk in these patients for deep venous thrombosis. This is reinforced in studies which have shown that a fluid challenge before the induction of pneumoperitoneum causes an increase intra-thoracic blood volume as part of an auto-transfusion so that unchanged values actually reflect relative hypovolaemia during IAH.⁸⁶

Cardiac contractility is directly affected by increases of intra-thoracic pressure creating a combination of reduced right ventricular pre-load with increased pulmonary vascular resistance and after-load. These effects may be worsened by excessive fluid resuscitation increasing right ventricular myocardial work and leading to right ventricular infarction. The septal deviation and altered ventricular geometry induced by right ventricular overload will also impair left ventricular end-diastolic volume.⁸⁷⁻⁸⁹ Systemic Vascular Resistance (SVR) generally rises in IAH consequent upon an increase in intra-thoracic pressure and through direct compressive effects on the aorta, the systemic vasculature and pulmonary radicals.⁹⁰ The initial reductions in stroke volume during the early phases of IAH are compensated by a concomitant rise in SVR which leaves the CO normalized, however, this state may be disabled by the utilization in the ventilated patient of high PEEP levels and consequent right heart failure.⁹¹

In this setting, the concerns about the complications of invasive monitoring methods have resurfaced particularly since in IAH the utilization of pressure monitoring to define volumetric analyses is suspect; an effect exaggerated by PEEP where the CVP and PAOP values are both falsely elevated.⁹²⁻⁹⁴ This has the potential (along with catheter malplacement in a squeezed lung zone) to lead to under-resuscitation if these invasive values are relied upon in IAH cases. These difficulties in IAH and a lack of availability of RVEDVI catheters⁹⁵ has placed a greater reliance on semi-quantitative bedside echocardiographic estimations of left ventricular filling in these patients as well as a direct assessment of parameters predictive of fluid challenge responsiveness such as caval diameter,^{96,97} peak aortic flow velocity⁹⁸ or the

broad demonstration of right ventricular dilatation and dyskinesia⁹⁹ and increased left ventricular wall stress.^{100,101}

RENAL FUNCTION IN INTRA-ABDOMINAL HYPERTENSION

Renal dysfunction is one of the definitional features of the IAH/ACS complex with an independently specific association between renal failure (and mortality with renal failure) and hypotension, age > 60 years, sepsis and IAH when patients are admitted to ICU following abdominal surgery.^{9,102} The aetiology of renal failure in IAH is unknown but probably multi-factorial including an overall decreased CO, reduced renal perfusion pressure and arterial flow, increased renal venous pressure and vascular resistance, enhanced cortico-medullary shunting (with consequent reduced GFR) and renal parenchymal and ureteric compression.¹⁰³⁻¹⁰⁵ This is associated with an increase in ADH production^{106,107} and stimulation of the renin-angiotensin-aldosterone mechanism¹⁰⁸ which is not ameliorated by fluid resuscitation except in the rat.^{109,110} The concept of impaired Renal Perfusion Pressure (RPP) is akin to that of APP and CPP previously mentioned although there is no evidence that restoration of MABP (where RPP=MABP-IAP) prevents the development of renal failure in these patients.¹¹¹ Ulyatt has suggested that the more important parameter is the glomerular filtration gradient (i.e. $P_{\text{GLOMERULAR FILTRATION}} - P_{\text{PROXIMAL TUBULE}}$) which reflects the force across the glomerulus, where in ACS proximal tubular pressure approaches the IAP value and where effectively the glomerular filtration pressure=MABP-IAP.¹¹² This would suggest that changes in IAP create a unique renal sensitivity over and above changes in the MABP. The renal structure implies a specific vulnerability to the effects of IAH where RPP also is significantly reduced when renal venous pressure is elevated in animal banding studies even in the face of a normal MABP and CO level.¹¹³ There are no consistent studies which show that abdominal decompression will reverse these renal effects of IAH.^{114,115} although there is a trend for post-decompressive diuresis in most studies.¹¹⁶ The natural history of renal failure in this setting is ameliorated by the early institution of continuous veno-venous haemo-filtration with IAH¹¹⁷ and with some evidence suggesting an advantage of continuous rather than intermittent renal replacement therapy.¹¹⁸ This may on occasion not be an option in patients with hypotensive unstable ACS and associated Multi-organ failure syndrome (MOFS) plus coagulopathy.

SPLANCHNIC PERFUSION AND INTRA-ABDOMINAL HYPERTENSION

Intra-abdominal hypertension results in a steady reduction in mesenteric and mucosal blood flow with consequent metabolic acidosis that is disproportionate to the associated CO reduction.^{119,120} These effects are combined with a commensurate reduction in hepatic arterial and microvascular blood flow;¹²¹ an effect which is reversible after normalization of IAP.¹²² These changes in mesenteric vascular resistance are in some studies

reversible by low-dose Dobutamine¹²³ and are synergistically aggravated by concomitant hypovolaemia/resuscitation cycling in animal models of IAH.^{124,125} These effects are followed by bacterial translocation^{126,127} although this is not in animal studies exacerbated by concomitant IAH.¹²⁸ The importance of mucosal splanchnic ischaemia is in its integral role in the genesis of MOFS partly through enhanced bacterial translocation where the effect of IAH/ACS is a 'second-hit' after initial hypovolaemic shock in these patients.^{129,130} This has been shown in animal models submitted to haemorrhagic shock with and without sustained increases in IAP where the combination resulted in greater acute phase pro-inflammatory cytokinaemic responses and lung neutrophil activation, provided that they were timed to stimulate neutrophil priming.¹³¹ These changes are not, however, ameliorated by abdominal decompression.¹³²

The effect of IAH on the liver is well documented but poorly understood. It is likely that part of the liver damage is the result of the impairment in mucosal barrier function^{133,134} but there is also an alteration in hepatic arterial and venous blood flow which is locally pressure-dependent¹³⁵ as well as the global reduction of cardiac output. This has been supplemented by an observed alteration in hepatic mitochondrial function, unexplained unexplained liver enzyme changes and a pressure-related Budd-Chiari-like effect in IAH,¹³⁶⁻¹³⁹ although others have been unable to demonstrate a clear association between hepatic function and IAP in mixed ICU populations.¹⁴⁰ Some of this data has been extrapolated from those patients experience liver trauma, intra-abdominal packing and sepsis¹⁴¹ as well as some of the changes observed in IAP following liver transplantation; both of which are not strictly comparable to the changes observed as part of IAH/ACS syndromes alone.¹⁴² What is evident, however, is that conventional pressure-related parameters for intravascular volume resuscitation assessment (such as CVP, PCWP, RVEDV) are inaccurate as estimates for management with the need for more sophisticated volumetric methodology not generally available at the bedside using modified pulmonary artery catheters equipped with fast-response thermistors or intra-thoracic blood volume indices designed to calculate stroke volume variation as more dynamic markers of pre-load assessment in these complicated cases.^{85,143-146}

MISCELLANEOUS PATHOPHYSIOLOGY AND INTRA-ABDOMINAL HYPERTENSION

There is considerable evidence showing in both animal¹⁴⁷⁻¹⁵¹ and human¹⁵² studies that there is a direct relationship between steadily increasing IAP and rising Intra-cranial pressure (ICP) as well as a coincident fall in Cerebral Perfusion Pressure (CPP); effects which are mechanical in nature in accordance with the Monroe-Kellie Doctrine through increases in jugular venous and sagittal sinus pressure. This is potentially relieved by abdominal decompression as well as by central volume expansion and PEEP ventilation.¹⁵³ The dynamics of the effect of IAP on ICP are different if there is a concomitant traumatic or non-traumatic brain injury,¹⁵⁴ although in patients with brain trauma

and IAH, a more liberal approach towards decompressive laparotomy and a more judicious delay in closure of the open abdomen when it is employed is indicated.^{155,156}

MANAGING IAH AND ACS

Part of the management of this syndrome is its early recognition and prevention. Those at risk include situations of shock with massive or supranormal volumes of fluid resuscitation on a background of abdominopelvic injury, widespread peritonitis and excessive abdominal wall tension occasioned by a tight abdominal closure. This may be exacerbated by difficulty in ventilation, coagulopathy and pre-existing disease such as hepatic cirrhosis. In multivariate analysis of ICU patients with ACS although there is a clustering of higher acute physiological scoring and MOFS, the 24-hour fluid balance and the peak airway pressures are most predictive of full-blown ACS.¹⁵⁷ Regular IAP assessment will alert the clinician to impending IAH, combined with a policy preventing overaggressive fluid resuscitation,^{158,159} particularly in those with a prior cardiac or pulmonary history and in marked obesity.¹⁶⁰

MEDICAL MANAGEMENT

The medical approach to assist with limiting IAP includes neuromuscular blockade, often used in combination with abdominal decompression.^{161,162} The IAP may in some patients be diminished by abdominal paracentesis particularly in IAH associated with severe burns,¹⁶³ although in chronic ascites this can lead to a well recognized circulatory collapse.¹⁶⁴⁻¹⁶⁶ This approach has been supported in one human study of the continuous negative extra-abdominal pressure (NEXAP) device¹⁶⁷ where previous animal studies have shown no reduction in IAP for IAH cases but where there has been an IAP reduction when its commencement value was normal.¹⁶⁸ The effects on respiratory dynamics of the NEXAP device are complicated and partially counterproductive. In their human study, Valenza and Gattinoni showed a slight NEXAP-induced reduction of CVP, shifting blood from the intra-thoracic compartment¹⁶⁹ similar to devices which have been used extra-thoracically. This has been coupled with an insignificant increase in functional lung volume in animal studies although this effect is counterbalanced by a slight reduction in chest wall compliance and a commensurate increase in pleural pressure imposed by the device. Octreotide,^{170,171} melatonin¹⁷² and high-dose diuretics in haemodynamically stable patients can reduce IAP with an unproven value of early dialysis and ultra-filtration, each of which is administered often with relatively high-dose inotropic support.¹⁷³ These approaches may be supplemented in the absence of prospective randomized data with gastric suctioning,¹⁷⁴ enemata, concentrated albumin,¹⁷⁵ gastric pro-kinetic therapy and colo-pro-kinetic administration but there are no proven advantages of these medical therapies.

Besides studies have shown that IAP in the semi-recumbent position increases in relation to Head of bed elevation (HOB).¹⁷⁶ Cheatham, et al.¹⁷⁷ demonstrated in a multicentre trial

of 132 ventilated patients that IAP increased by 1.5 and 3.6 mm Hg when patients were placed in the semi-recumbent position at 15° and 30° HOB respectively. However, these differences were less obvious in patients with IAP > 20 mm Hg. A more recent study by Yi, et al.¹⁷⁸ showed an increase in IAP by 4.1 mm Hg among 88 patients in the semi-recumbent position at 30° HOB. Pressure differences between the supine and HOB at 30° in other trials ranged between 0.41 and 5 mm Hg, with a higher range at HOB 45° (2.7-14.9 mm Hg). Clinicians should be aware of this pressure increase when changing body position, especially in patients with impending ACS, although other factors like body anthropomorphy may also play a role.¹⁷⁸

SURGICAL DECOMPRESSION

The increasing use of 'damage-control' laparotomy provides some experience of the open abdomen as well as Temporary Abdominal Closure, (TAC) providing easier access for monitoring bowel viability, the possibility of repeat pancreatic necrosectomy and the ready potential for debridement in cases of necrotizing fasciitis.¹⁷⁹ This approach, however, provides a considerable risk for fistula formation and intra-abdominal sepsis as well as creating difficulties in fluid management and nursing. Generous midline releases are favoured as they do not result in denervation or devascularization permitting later local flap mobilizations if needed. The presence of the open abdomen does not, however, preclude the monitoring of IAP since a secondary ACS may still occur.¹⁸⁰ The physiological consequences of decompression have been little studied since there is less of a tendency to follow IAP after this surgery.¹⁸¹ Many of the aberrant parameters return towards normal but do not normalize, such as the mean PaO₂/FiO₂ ratio,¹¹⁴ however, there are no prospective studies assessing objective serial scoring of organ dysfunction through decompressive laparotomy despite reported improvements in peak inspiratory pressures, MABP and urine output which themselves may not be the best markers for individual organ function.¹⁸²

Variations in the technique for TAC management are evolving and depend upon available materials and experience as well as an operative decision concerning the likelihood of early closure or re-exploration. The techniques of towel-clip closure¹⁸³ and the Bogota bag^{184,185} are now fairly obsolete. Currently, a passive 'sandwich' pack dressing is more commonly recommended¹⁸⁶ or where available, a Wittman Dynamic Patch TM (Star Surgical Inc, Wisconsin USA) or Abra[®] dynamic closure system (Canica design, Ontario CA) may be used permitting patch advancement at the bedside.¹⁸⁷ The negative pressure vacuum-VAC closure device (KCI International, San Antonio TX) has had considerable recent success as a first-up method of open wound management¹⁸⁸ with selected alternatives including temporary absorbable and non-absorbable forms of mesh,^{189,190} silos¹⁹¹ and 'zipper-style' techniques.¹⁹²⁻¹⁹⁴

The sandwich suction dressing is the easiest and cheapest method to employ being a forerunner of the VAC technique

with placement of large adhesive drapes into the paracolic gutter under suction drains.¹⁹⁵ This simple dressing is effective, containing the abdominal contents with minimal fluid leakage and is non-contributory either to worsening IAP or the early development of adhesions. It prevents skin maceration or blistering allowing some give with underlying peristalsis (as opposed to fascially fixed techniques) and permitting rapid access for repeat laparotomy. Moreover, if IAH is developing in its presence, the outer adhesive can be split and then reapplied without disturbing the internal arrangement. A range of meshes have been advocated for this circumstance although these have numerous disadvantages principally with sepsis, a lack of water-tightness and some degree of incorporation into the wound over time. Goretex (Polytetrafluoroethylene, Gore & Assoc, Flagstaff, AZ), Vicryl (Polyglactin, Ethicon), Dexon (Polyglycolic acid, Davis & Geck) and Polypropylene (Marlex, Bard, Prolene, Ethicon or Surgipro US Surgical, Norwalk, CT) are all alternatives which have been used. These may still be associated with ACS after placement and some cases may need mesh replacement or further decompression after deployment. The absorbable meshes have little tensile strength and can result in evisceration during patient turning with the non-absorbables being associated with a moderate rate of intestinal fistula.^{196,197}

The further advantages of the VAC proprietary devices over temporary mesh usage include their versatility to the contour of large defects permitting the utilization of a laterally placed stoma in conjunction¹⁹⁸ and potential use even in the presence of a pre-existing intestinal fistula.¹⁹⁹ Where possible, stomas should be avoided as the geography of the abdominal wall may change in such a way that they retract significantly or where in a delayed setting they can compromise abdominal wall reconstruction and rectus advancements.²⁰⁰ Where possible, enteral nutrition in patients with an open abdomen should be utilized and may be continued in the majority after abdominal wall closure.²⁰¹ A protocolized approach to the use of the VAC device in such patients has provided a high early secondary closure rate, with some 88% of patients being able to be closed between 9-21 days after initial decompression.²⁰² This compares with earlier reports with standard techniques of less than 50% secondary closure rates where open wounds were eventually skin grafted²⁰³ and where there was a moderate incidence of delayed difficult hernia repair.^{204,205} These modalities can be combined when there is excessive bowel wall oedema precluding early fascial closure so that decisions regarding either primary VAC closure (for example in the absence of a nearby intestinal anastomosis) or absorbable mesh can be selectively made.²⁰⁶ The likelihood of early closure using this protocol is, however, affected by the presence of extra-abdominal sepsis, in particular ventilator-related pneumonia, blood stream infection and other surgical site sepsis in these patients.²⁰⁷

DELAYED ABDOMINAL WALL RECONSTRUCTION

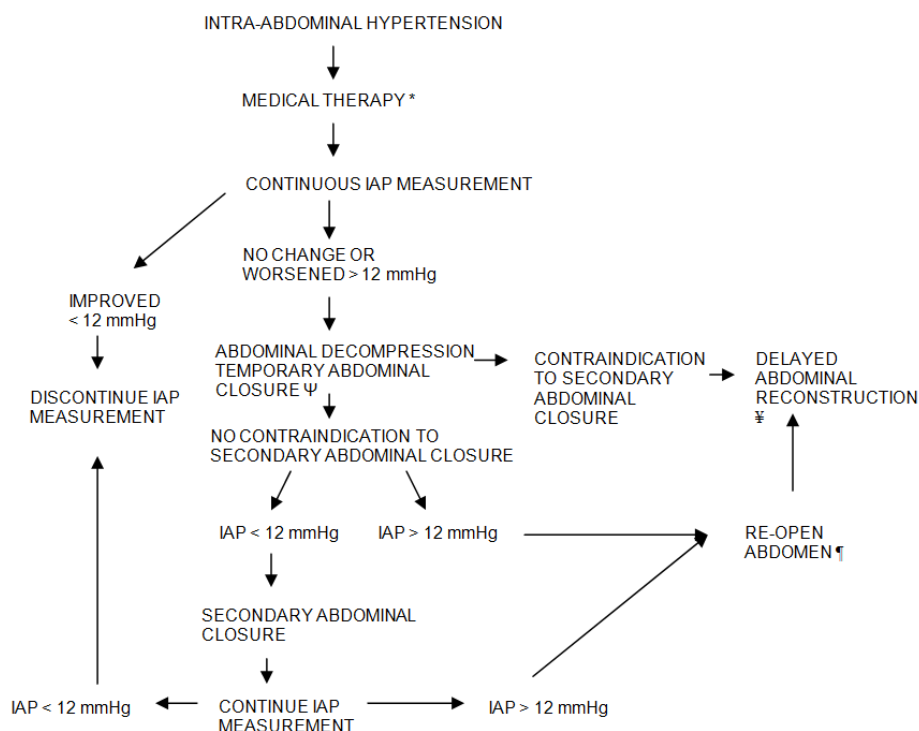
There is no optimal management of the open abdomen which is capable of providing total protection of the abdomi-

nal viscera from desiccation and adhesions and which supports easy delayed fascial closure.²⁰⁸ Significant delays in secondary closure which may occur for a range of complex extra-abdominal reasons may result in loss of abdominal domain for gut repositioning and have resulted in a variety of approaches including prosthetic mesh insertion, tissue expansion, local abdominal wall and free flap techniques and component separation methods.²⁰⁹⁻²¹³ Equally, local effects may preclude early direct approximation including ongoing haemorrhage, coagulopathy, intraperitoneal and retroperitoneal sepsis or bowel wall oedema. The simplest approach is delayed primary wound approximation although this is dependent upon feasibility issues to provide the best muscle function capable of supporting movement, coughing, defaecation and micturition as well as providing an acceptable cosmetic result and psychological outcome.^{214,215}

This approach can be partial and equally assisted by mesh split skin grafting or with VAC assistance as part of a combination therapy^{216,217} where further reconstructive surgery may leave the skin in place following initial de-Epithelialization. The insertion of mesh, acellular human dermis substitutes or composites can be supported by inter-muscular insertion of a temporary tissue expander although this usually requires repeated revision.²¹⁸⁻²²⁰ Advancement of the rectus muscles for approximation may be facilitated by components separation where the external oblique aponeurosis and the internal rectus fascia are in-

cised and separated so that large defects above the umbilicus (up to 10 cm), at the umbilicus (up to 20 cm) and below the umbilicus (up to 6 cm) can effectively be closed.²²¹ This technique has been reported to suffer from considerable wound-related complications²²² which have been reduced by endoscopic-assisted²²³ and periumbilical perforating vessel-preserving techniques.^{224,225} Decisions regarding these techniques can be informed by intra-operative monitoring including intra-vesical pressure measurement.²²⁶ The abdominal wall lends itself to random pattern flaps such as those used normally in abdominoplasty when the defect is infra-umbilical or axial pattern flaps including groin, rectus abdominis, tensor fasciae latae, external oblique fascio- and myocutaneous flaps as well as free tissue transfers.^{213,227,228} A suggested algorithm for the management of IAH/ACS and its aftermath are shown in Figure 2.

Medical management of critically ill patients with raised IAP should be instigated early to prevent further organ dysfunction and to avoid progression to ACS. Many treatment options are available and are often part of routine daily management in the ICU (nasogastric, rectal tube, prokinetics, enema, sedation, body position).^{229,230} Some of the newer treatments such as tPA-assisted decompression of a haematoma, theophylline infusions to reduce circulating adenosine concentrations, octreotide as a reperfusion injury-limiting agent, and CNAP to reduce IAP, are all very promising treatment options in specific



*Medical therapy consists of selective use of sedation, neuromuscular blockade, nasogastric suction, gastro (colo) pro-kinetic therapy, enteral feeding, abdominal paracentesis and haemodialysis/ultrafiltration
 ΨTemporary abdominal closure may consist of Bogota bag, sandwich-packing, VAC-assisted devices or dynamic commercial closure systems (see text)
 ‡Delayed definitive abdominal closure includes mesh utilization, abdominal components separation, tissue expansion, local axial pattern myo(fascio)cutaneous flaps or free flaps (see text)

Figure 2: A suggested algorithm for the management of IAH/ACS and its aftermath.

patient populations (ruptured triple A, pancreatitis) with raised IAP. Future studies are warranted to confirm some of these findings.¹⁷⁶

CONCLUSIONS

The relatively recent recognition of the IAS/ACS complex has resulted in a profusion of animal and human work on its pathophysiology. Many of the features of the syndrome are still unknown and require a connection with the possibility of the diagnosis, with a routine IAP measurement, (most likely in high-risk cases by continuous technology) and a more liberal policy towards surgical decompression. This view would allow a less prolonged ventilatory, cardiac and renal support and is based on an improved management of the open abdomen and its consequences. Measurement techniques of the IAP and consensus concerning what levels are abnormal are needed, as well as prospective ICU-framed studies, to better assess circulatory filling status utilizing volumetric-modified pulmonary artery catheters and which more accurately define end-organ perfusion and dysfunction. This will be supported by better 'pathological' animal models which more directly address the capillary leakage syndrome as part of ACS, which separate the effects of decompression and volume restoration and which distinguish organ from global resuscitation.

CONFLICTS OF INTEREST

We declare that I have no conflict of interest in connection with this paper.

ACKNOWLEDGEMENT

All the authors have no potential or actual personal, political or financial interest in the material, information or techniques described in the paper.

REFERENCES

1. Malbrain MLNG. Abdominal compartment syndrome: it is time. *Acta Clin Belg.* 2007; 62: 1-5.
2. von Volkmann R. The ischemic muscle paralysis and contractions. *Zbl. Chir.* 1881; 8: 801-803.
3. Marey EJ. Medical physiology of blood circulation, based on the graphic study of the movements of the heart and arterial pulse with application to diseases of the circulatory apparatus. Paris: A Delahaye. 1863.
4. Emerson H. Intra-abdominal pressures. *Arch Intern Med.* 1911; 7: 754-784.
5. Coombs HC. The mechanisms of the regulation of intra-abdominal pressure. *Am J Physiol.* 1920; 61: 159-163.
6. Fietsam R Jr, Villaba M, Glover JL, et al. Intra-abdominal compartment syndrome as a complication of ruptured abdominal aortic aneurysm repair. *Am Surg.* 1989; 55: 396-402.
7. Schein M. Abdominal compartment syndrome. Historical background. Abdominal compartment syndrome. In: Ivatury RR, Cheatham ML, Malbrain MLNG, Sugrue M, eds. Landes Bioscience, Georgetown TX. 2006; 1-7.
8. van Hee R. Historical highlights in concept and treatment of abdominal compartment syndrome. *Acta Clin Belg.* 2007; 62: 9-15.
9. Sugrue M, Buist MD, Hourihan F, et al. Prospective study of intra-abdominal hypertension and renal function after laparotomy. *Br J Surg.* 1995; 82: 235-238.
10. Saggi BH, Sugerman HJ, Ivatury RR, et al. Abdominal compartment syndrome. *J Trauma.* 1998; 45: 597-609.
11. Zbar AP. Compliance and capacity of the normal human rectum-physical considerations and measurement pitfalls. *Acta Chir Jugosl.* 2007; 54: 49-57.
12. Van Stappen J, Pigozzi C, Tepaske R, et al. Validation of a novel method for measuring intra-abdominal pressure and gastric residual volume in critically ill patients. *Anaesthesiology Intensive Therapy.* 2014; 46(4): 245-254.
13. Ivatury RR, Diebel L, Porter JM, et al. Intra-abdominal hypertension and the abdominal compartment syndrome. *Surg Clin N Am.* 1997; 77: 783-800.
14. Vincent JL, McKinley BA, Cocanour CS, et al. The SOFA (Sepsis-related Organ Failure Assessment) score to describe organ dysfunction/failure. *Intensive Care Med.* 1996; 22: 707-710. doi: [10.1007/BF01709751](https://doi.org/10.1007/BF01709751)
15. Meldrum DR, Moore FA, Moore EE, et al. prospective characterization and selective management of the abdominal compartment syndrome. *Am J Surg.* 1997; 174: 667-672. doi: [10.1016/S0002-9610\(97\)00201-8](https://doi.org/10.1016/S0002-9610(97)00201-8)
16. Lambert DM, Marceau S, Forse RA. Intra-abdominal pressure in the morbidly obese. *Obes Surg.* 2005; 15: 1225-1232. doi: [10.1381/096089205774512546](https://doi.org/10.1381/096089205774512546)
17. Hamad GG, Peitzman AB. Morbid obesity and chronic intra-abdominal hypertension. Abdominal compartment syndrome. In: Ivatury RR, Cheatham ML, Malbrain MLNG, Sugrue M, eds. Landes Bioscience, Georgetown TX. 2006; 189-196.
18. Balogh Z, McKinley BA, Cocanour CS, et al. Secondary abdominal compartment syndrome is an elusive early complication of traumatic shock resuscitation. *Am J Surg.* 2002; 184: 538-543.

doi: [10.1016/S0002-9610\(02\)01050-4](https://doi.org/10.1016/S0002-9610(02)01050-4)

19. Britt RC, Gannon T, Collins JN, Cole FJ, Weireter LJ, Britt LD. Secondary abdominal compartment syndrome: risk factors and outcomes. *Am Surg.* 2005; 71: 982-985.
20. Cotton BA, Guy JS, Morris JA Jr, Abumrad NN. The cellular, metabolic and systemic consequences of aggressive fluid resuscitation strategies. *Shock.* 2006; 26: 115-121.
21. Balogh Z, Moore FA, Moore EE, Biffl WL. Secondary abdominal compartment syndrome: a potential threat for all trauma clinicians. *Injury.* 2007; 38: 272-279. doi: [10.1016/j.injury.2006.02.026](https://doi.org/10.1016/j.injury.2006.02.026)
22. Gracias VH, Braslow B, Johnson J, et al. Abdominal compartment syndrome in the open abdomen. *Arch Surg.* 2002; 137: 1298-1300.
23. Raeburn CD, Moore EE, Biffl WL, et al. The abdominal compartment syndrome is a morbid complication of postinjury damage control surgery. *Am J Surg.* 2001; 182: 542-546. doi: [10.1016/S0002-9610\(01\)00821-2](https://doi.org/10.1016/S0002-9610(01)00821-2)
24. Malbrain ML, Chiumello D, Pelosi P, et al. Incidence and prognosis of intraabdominal hypertension in a mixed population of critically ill patients: a multiple-center epidemiological study. *Crit Care Med.* 2005; 33: 315-322.
25. Ivy ME, Atweh NA, Palmer J, et al. Intra-abdominal hypertension and abdominal compartment syndrome in burns patients. *J Trauma.* 2000; 49: 387-391.
26. Loftus IM, Thompson MM. The abdominal compartment syndrome following aortic surgery. *Eur J Vasc Endovasc Surg.* 2003; 25: 97-109. doi: [10.1053/ejvs.2002.1828](https://doi.org/10.1053/ejvs.2002.1828)
27. Ivatury RR, Porter JM, Simon RJ, et al. Intra-abdominal hypertension after life-threatening penetrating abdominal trauma. Prophylaxis, incidence and clinical relevance to gastric mucosal pH and abdominal compartment syndrome. *J Trauma.* 1998; 44: 1016-1023.
28. Plantefève G, Hellmann R, Pajot O, Thirion M, Bleichner G, Mentec H. Abdominal compartment syndrome and intra-abdominal sepsis: two of the same kind? *Acta Clin Belg.* 2007; 62: 162-167.
29. Kirkpatrick AW, Brenneman FD, McLean RF, et al. Is clinical examination an accurate indicator of raised intra-abdominal pressure in critically injured patients? *Can J Surg.* 2000; 43: 207-211.
30. Sugrue M, Bauman A, Jones F, et al. Clinical examination is an inaccurate predictor of intraabdominal pressure. *World J Surg.* 2002; 26: 1428-1431. doi: [10.1007/s00268-002-6411-8](https://doi.org/10.1007/s00268-002-6411-8)
31. Van Mieghem N, Vebrugghe W, Daelemans R, et al. Can abdominal perimeter be used as an accurate estimation of intra-abdominal pressure? *Crit Care.* 2003; 7(Suppl 2): 183. doi: [10.1186/cc2072](https://doi.org/10.1186/cc2072)
32. Ho HS, Saunders CJ, Gunther RA, Wolfe BM. Effector of hemodynamics during laparoscopy: CO2 absorption or intra-abdominal pressure? *J Surg Res.* 1995; 59: 497-503.
33. Enoch C, Aslam N, Piraino B. Intra-abdominal pressure, peritoneal dialysis exchange volume, and tolerance in APD. *Semin Dial.* 2002; 15: 403-406. doi: [10.1046/j.1525-139-X.2002.00100.x](https://doi.org/10.1046/j.1525-139-X.2002.00100.x)
34. Risin E, Kessel B, Ashkenazi I, Lieberman N, Alfici R. A new technique of direct intra-abdominal pressure measurement: a preliminary study. *Am J Surg.* 2006; 191: 235-237. doi: [10.1016/j.amjsurg.2005.07.038](https://doi.org/10.1016/j.amjsurg.2005.07.038)
35. Kron IL, Harman PK, Nolan SP. The measurement of intra-abdominal pressure as a criterion for abdominal re-exploration. *Ann Surg.* 1984; 199: 28-30.
36. de Laet IE, Malbrain MMLG. Intra-abdominal hypertension and abdominal compartment syndrome: what do we know today? *Care Crit.* 2007; 3(23): 4-14.
37. Sgraves SG, Cheatham ML, Johnson JL, et al. Intravesicular pressure monitoring does not increase the risk of urinary tract or systemic infection. *Crit Care Med.* 2007; 27: A48.
38. Johna S, Taylor E, Brown C, Zimmerman G. Abdominal compartment syndrome: does intra-cystic pressure reflect actual intra-abdominal pressure? A prospective study in surgical patients. *Journal.* 1999; 3: 135-138. doi: [10.1186/cc366](https://doi.org/10.1186/cc366)
39. Cheatham ML, Safcsak K. Intraabdominal pressure. A revised method for measurement. *J Am Coll Surg.* 1998; 186: 594-595. doi: [10.1016/S1072-7515\(98\)00122-7](https://doi.org/10.1016/S1072-7515(98)00122-7)
40. Wolfe Tory Medical, Inc. Available at: www.wolfetory.com, 1994; Accessed 2015.
41. Harrahill M. Intra-abdominal pressure monitoring. *J Emerg Nurs.* 1998; 24: 465-466.
42. Malbrain MLNG, Leonard M, Delmarcelle D. A novel technique of intra-abdominal pressure measurement: validation of two prototypes. *Crit Care.* 2002; 6: S2-S3.
43. De Potter TJ, Dits H, Malbrain ML. Intra- and interobserver variability during in vitro validation of two novel methods for

- intra-abdominal pressure monitoring. *Intensive Care Med.* 2005; 31: 747-751. doi: [10.1007/s00134-005-2597-1](https://doi.org/10.1007/s00134-005-2597-1)
44. Balogh Z, Jones F, D'Amours S, Parr M, Sugrue M. Continuous intra-abdominal pressure measurement technique. *Am J Surg.* 2004; 188: 679-684. doi: [10.1016/j.amjsurg.2004.08.052](https://doi.org/10.1016/j.amjsurg.2004.08.052)
45. Colle GG, Lomax DM, Ferguson C, et al. Bedside measurement of intra-abdominal pressure (IAP) via an indwelling nasogastric tube: clinical validation of the technique. *Intensive Care Med.* 1993; 19: 478-480.
46. Debaveye Y, Bertiaux S, Malbrain MLNG. Simultaneous measurement of intra-abdominal pressure and regional CO₂ via a gastric tonometer. *Intensive Care Med.* 2000; 26(Suppl 3): S324.
47. Ravishankar N, Hunter J. Measurement of intra-abdominal pressure in intensive care units in the United Kingdom: a national postal questionnaire study. *Br J Anaesth.* 2005; 94: 763-766.
48. Kirkpatrick AW, Laupland KB, Karmali S, et al. Spill your guts! Perceptions of Trauma Association of Canada member surgeons regarding the open abdomen and the abdominal compartment syndrome. *J Trauma.* 2006; 60: 279-286.
49. Kimball EJ, Rollins MD, Mone MC, et al. Survey of intensive care physicians on the recognition and management of intra-abdominal hypertension and abdominal compartment syndrome. *Crit Care Med.* 2006; 34: 2340-2348.
50. Malbrain ML. Different techniques to measure intra-abdominal pressure (IAP): time for a critical re-appraisal. *Intensive Care Med.* 2004; 30: 357-371. doi: [10.1007/s00134-003-2107-2](https://doi.org/10.1007/s00134-003-2107-2)
51. Diaz FJ, Fernandez Sein A, Gotay F. Identification and management of abdominal compartment syndrome in the pediatric intensive care unit. *P R Health Sci J.* 2006; 25: 17-22.
52. Shafik A, El Sharkawy A, Sharaf WM. Direct measurement of intra-abdominal pressure in various conditions. *Eur J Surg.* 1997; 163: 883-837.
53. Dowdle M. Evaluating a new intrauterine pressure catheter. *J Reproduct Med.* 1997; 42: 506-513.
54. Lacey SR, Bruce J, Brooks SP, et al. The relative merits of various methods of indirect measurement of intraabdominal pressure as a guide to closure of abdominal wall defects. *J Pediatr Surg.* 1987; 22: 1207-1211.
55. Joynt GM, Gomersall CD, Buckley TA, et al. Comparison of intrathoracic and intra-abdominal measurements of central venous pressure. *Lancet.* 1996; 347(9009): 1155-1157.
56. Schachtrupp A, Henzler D, Orfao S, et al. Evaluation of a modified piezoelectric technique and a water-capsule technique and continuous measurement of intra-abdominal pressure in a porcine model. *Crit Care Med.* 2006; 34: 745-750.
57. Cheatham ML, White MW, Sagraves SG, et al. Abdominal perfusion pressure a superior parameter in the assessment of intra-abdominal hypertension. *J Trauma.* 2000; 49: 621-627.
58. Cheatham ML, Malbrain MLNG. Abdominal perfusion pressure. Abdominal Compartment Syndrome. In: Ivatury RR, Cheatham ML, Malbrain MLNG, Sugrue M, eds. Landes Bioscience Georgetown TX. 2006; 69-81.
59. Malbrain MLNG. Abdominal perfusion pressure as a prognostic marker in intra-abdominal hypertension. Yearbook of Intensive Care and Emergency Medicine. In: Vincent JL, eds. Springer, NY, 2002; 792-814.
60. Sugrue M. Intra-abdominal pressure: time for clinical practice guidelines? *Intensive Care Med.* 2002; 28: 389-391. doi: [10.1007/s00134-002-1253-2](https://doi.org/10.1007/s00134-002-1253-2)
61. Bardoczky GI, Engelman E, Levarlet M, et al. Ventilatory effects of pneumoperitoneum monitored with continuous spirometry. *Anesthesia.* 1993; 48: 309-311. doi: [10.1111/j.1365-2044.1993.tb06949.x](https://doi.org/10.1111/j.1365-2044.1993.tb06949.x)
62. Fahy BG, Barnas GM, Flowers JL, et al. The effects of increased abdominal pressure on lung and chest wall mechanics during laparoscopic surgery. *Anesth Analg.* 1995; 81: 744-750.
63. Fahy BG, Barnas GM, Nagle SE, et al. Changes in lung and chest wall properties with abdominal insufflation of carbon dioxide are immediately reversible. *Anesth Analg.* 1996; 82: 501-505.
64. Erice F, Fox GS, Salib YM, et al. Diaphragmatic function before and after laparoscopic cholecystectomy. *Anesthesiology.* 1993; 79: 966-975.
65. Pelosi P, Goldner M, McKibben A, et al. Recruitment and derecruitment during acute respiratory failure: an experimental study. *Am J Respir Crit Care Med.* 2001; 164: 122-130. doi: [10.1164/ajrcm.164.1.2007010](https://doi.org/10.1164/ajrcm.164.1.2007010)
66. Puri GD, Singh H. Ventilatory effects of laparoscopy under general anaesthesia. *Br J Anaesth.* 1992; 68: 211-213. doi: [10.1093/bja/68.2.211](https://doi.org/10.1093/bja/68.2.211)
67. Pelosi P, Aliverti A, Dellaca A. Chest wall mechanics in normal subjects and in critically ill patients. 2000.
68. Gauthier AP, Verbanck S, Estenne M, Segebarth C, Macklem PT, Paiva M. Three-dimensional reconstruction of the in

- vivo human diaphragm shape at different lung volumes. *J Appl Physiol*. 1994; 76: 496-506.
69. Aliverti A, Carlesso E, Dellaca R, et al. Chest wall mechanics during pressure support ventilation. *Crit Care*. 2006; 10: R54-R61.
70. Mutoh T, Lamm WJ, Embree LJ, et al. Volume infusion produces abdominal distension, lung compression and chest wall stiffness in pigs. *J Appl Physiol*. 1992; 72: 575-582.
71. Pelosi P, Cereda M, Foti G et al. Alterations of lung and chest wall mechanics in patients with acute lung injury: effects of positive end-expiratory pressure. *Am J Respir Crit Care Med*. 1995; 152: 531-537. doi: [10.1164/ajrcm.152.2.7633703](https://doi.org/10.1164/ajrcm.152.2.7633703)
72. Pelosi P, Qunitel M, Malbrain MLNG. Effect of intra-abdominal pressure on respiratory mechanics. *Acta Clin Belg*. 2007; 62: 78-88.
73. Rouby JJ, Puybasset L, Nieszkowska A, et al. Acute respiratory distress syndrome: lessons from computed tomography of the whole lung. *Crit Care Med*. 2003; 31: S285-S295.
74. Pelosi P, Luecke T, Caironi P, Chiumello D. A physiologically based approach to peri-operative management of obese patients. In: Albert RK, Slutsky A, Ranieri M, Takala J, Torres A, eds. *Clinical Critical Care Medicine*. Mosby Inc. 2006; 263-273.
75. Loeckinger A, Kleinsasser A, Hoermann C, et al. Inert gas exchange during pneumo-peritoneum at incremental values of positive end-expiratory pressure. *Anesth Analg*. 2002; 90: 466-471.
76. Hazebroek EJ, Haitsma JJ, Lachmann B, et al. Mechanical ventilation with positive end-expiratory pressure preserves arterial oxygenation during prolonged pneumo-peritoneum. *Surg Endosc*. 2002; 16: 685-689. doi: [10.1007/s00464-001-8174-y](https://doi.org/10.1007/s00464-001-8174-y)
77. Toens Ch, Schachtrupp A, Hoer J, Schumpelick VR. Porcine model of abdominal compartment syndrome. *Shock*. 2002; 18: 316-321.
78. Verbrugge S, Lachman B. Mechanisms of ventilation-induced lung injury: physiological rationale to prevent it. *Monaldi Arch Chest Dis*. 1999; 54: 22-37.
79. Ranieri VM, Suter PM, Tortorella C, et al. Effect of mechanical ventilation on inflammatory mediators in patients with acute respiratory distress syndrome: a randomized controlled trial. *JAMA*. 1999; 282: 54-61. doi: [10.1001/jama.282.1.54](https://doi.org/10.1001/jama.282.1.54)
80. Santos CL, Moraes L, Santos RS et al. The biological effects of higher and lower positive end-expiratory pressure in pulmonary and extrapulmonary acute lung injury with intra-abdominal hypertension. *Critical Care*. 2014; 18: R121. doi: [10.1186/cc13920](https://doi.org/10.1186/cc13920)
81. Wrigge H, Zinserling J, Stuber F, et al. Effects of mechanical ventilation on release of cytokines into systemic circulation in patients with normal pulmonary function. *Anesthesiology*. 2000; 93: 1413-1437.
82. De Waele JJ, Benoit D, Hoste E, Colardyn F. A role for muscle relaxation in patients with abdominal compartment syndrome? *Intensive Care Med*. 2003; 29: 332.
83. Esteban A, Frutos F, Tobin MJ, et al. A comparison of four methods of weaning patients from mechanical ventilation. Spanish Lung Failure Collaborative Group. *N Engl J Med*. 1995; 332: 345-350. doi: [10.1056/NEJM199502093320601](https://doi.org/10.1056/NEJM199502093320601)
84. Amato MB, Barbas CS, Medeiros DM, et al. Effect of a protective ventilation strategy on mortality in the acute respiratory distress syndrome. *N Engl J Med*. 1998; 338: 347-354.
85. Grasso S, Mascia L, Del Turco M, et al. Effects of recruiting maneuvers in patients with acute respiratory distress syndrome ventilated with protective ventilatory strategy. *Anesthesiology*. 2002; 96: 795-802.
86. Kashtan J, Green JF, Parsons EQ, Holcroft JW. Hemodynamic effects of increased abdominal pressure. *J Surg Res*. 1981; 30: 249-255.
87. Cheatham ML, Nelson LD, Chang MC, et al. Right ventricular end-diastolic volume index as a predictor of preload status in patients on positive end-expiratory pressure. *Crit Care Med*. 1998; 28: 1801-1806.
88. Cheatham ML, Malbrain MLNG. Cardiovascular implications of abdominal compartment syndrome. *Acta Clin Belg*. 2007; 62(Suppl 1): 98-112.
89. Andersson L, Wallin CJ, Sollevi A, Odeberg-Wernerman S. Pneumoperitoneum in healthy humans does not affect central blood volume or cardiac output. *Acta Anaesthesiol Scand*. 1999; 43: 809-814. doi: [10.1034/j.1399-6576.1999.430805.x](https://doi.org/10.1034/j.1399-6576.1999.430805.x)
90. Brooks H, Kirk ES, Vokonas PS, et al. Performance of the right ventricle under stress: relation to right coronary flow. *J Clin Invest*. 1971; 50: 2176-2183.
91. Calvin JE, Driedger AA, Sibbald WJ. Does the pulmonary capillary wedge pressure predict left ventricular preload in critically ill patients? *Crit Care Med*. 1981; 9: 437-443.
92. Eddy AC, Rice CL, Anardi DM. Right ventricular dysfunction in multiple trauma victims. *Am J Surg*. 1998; 155: 712-715.

93. Ridings PC, Bloomfield GL, Blocher CR, et al. Cardiopulmonary effects of raised intra-abdominal pressure before and after intravascular volume expansion. *J Trauma*. 1995; 39: 1071-1075.
94. Safcsak K, Fusco MA, Miles WS, et al. Does transmural pulmonary artery occlusion pressure (PAOP) via oesophageal balloon improve prediction of ventricular preload in patients receiving positive end-expiratory pressure (PEEP)? *Crit Care Med*. 1995; 23: A244.
95. Diebel LN, Wilson RF, Tagett MG, et al. End-diastolic volume: a better indicator of preload in the critically ill. *Arch Surg*. 1992; 127: 817-822.
96. Osman D, Ridel C, Ray P, et al. Cardiac filling pressures are not appropriate to predict hemodynamic response to volume challenge. *Crit Care Med*. 2007; 35: 64-68.
97. Chaney JC, Derdak S. Minimally invasive hemodynamic monitoring for the intensivist: current and emerging technology. *Crit Care Med*. 2002; 30: 2338-2345.
98. Vieillard-Baron A, Chergui K, Rabiller A, et al. Superior vena caval collapsibility as a gauge of volume status in ventilated septic patients. *Intensive Care Med*. 2004; 30: 1734-1739. doi: [10.1007/s00134-004-2361-y](https://doi.org/10.1007/s00134-004-2361-y)
99. Feissel M, Michard F, Faler JP, Terboul JL. The respiratory variation in inferior vena cava diameter as a guide to fluid therapy. *Intensive Care Med*. 2004; 30: 1834-1837. doi: [10.1007/s00134-004-2233-5](https://doi.org/10.1007/s00134-004-2233-5)
100. Feissel M, Mkichard F, Mangin I, Ruyer O, Faller JP, Terboul JL. Respiratory changes in aortic blood velocity as an indicator of fluid responsiveness in ventilated patients with septic shock. *Chest*. 2001; 119: 867-873. doi: [10.1378/chest.119.3.867](https://doi.org/10.1378/chest.119.3.867)
101. Jardin F, Dubourg O, Bourdarias JP. Echocardiographic pattern of acute cor pulmonale. *Chest*. 1997; 111: 209-217. doi: [10.1378/chest.111.1.209](https://doi.org/10.1378/chest.111.1.209)
102. Reichek N, Wilson J, St John Sutton M, Plappert TA, Goldberg S, Hirschfeld JW. Noninvasive determination of left ventricular end-systolic stress: validation of the method and initial application. *Circulation*. 1982; 65: 99-108. doi: [10.1161/01.CIR.65.1.99](https://doi.org/10.1161/01.CIR.65.1.99)
103. Vieillard-Baron A, Augarde R, Prin S, Page B, Beauchet A, Jardin F. Hemodynamic instability in sepsis: bedside assessment by Doppler echocardiography. *Am J Resp Crit Care Med*. 2003; 168: 1270-1276. doi: [10.1164/rccm.200306-816CC](https://doi.org/10.1164/rccm.200306-816CC)
104. Sugrue M, Jones F, Deane SA, Bishop G, Bauman A, Hillman K. Intra-abdominal hypertension is an independent cause of postoperative renal impairment. *Arch Surg*. 1999; 134: 1082-1085. doi: [10.1001/archsurg.134.10.1082](https://doi.org/10.1001/archsurg.134.10.1082)
105. Stone HH, Fulenwider JT. Renal decapsulation in the prevention of post ischaemic oliguria. *Ann Surg*. 1977; 186: 343-355.
106. Vargas JC, Fields D, Razvi I. Direct parenchymal compression to 15 mmHg produces oliguria. *J Urol*. 1995; 153: 514.
107. Doty JM, Saggi BH, Blocher CR, et al. Effects of increased renal parenchymal pressure on renal function. *J Trauma*. 2000; 48: 874-878.
108. Le Roith D, Bark H, Nyska M, Glick SM. The effect of abdominal pressure on plasma antidiuretic hormone levels in the dog. *J Surg Res*. 1982; 32: 65-69. doi: [10.1016/0022-4804\(82\)90186-X](https://doi.org/10.1016/0022-4804(82)90186-X)
109. Vinamki O, Punnonen R. Vasopressin release during laparoscopy: role of increased intra-abdominal pressure. *Lancet*. 1982; 175-176.
110. Bloomfield GL, Blocher CR, Fakhry IF, Sica DA, Sugerman HJ. Elevated intra-abdominal pressure increases plasma rennin activity and aldosterone levels. *J Trauma*. 1997; 42: 997-1004.
111. Balogh Z, McKinley BA, Cocanour CS, Kozar RA, Cox CS, Moore FA. Patients with impending abdominal compartment syndrome do not respond to early volume loading. *Am J Surg*. 2003; 186: 602-608. doi: [10.1016/j.amjsurg.2003.09.002](https://doi.org/10.1016/j.amjsurg.2003.09.002)
112. Lindstrom P, Wadstrom J, Ollerstam A, Johnsson C, Persson AE. Effects of increased intra-abdominal pressure and volume expansion on renal function in the rat. *Nephrol Dial Transplant*. 2003; 18: 2269-2277.
113. Schachtrupp A, Lawong C, Afify M, Graf J, Toens S, Schumpelick V. Fluid resuscitation preserves cardiac output but cannot prevent organ damage in a porcine model during 24 h of intraabdominal hypertension. *Shock*. 2005; 24: 153-158.
114. Ulyatt DB. Elevated intra-abdominal pressure. *Australian Anaes*. 1992; 108-114.
115. Doty JM, Saggi BH, Sugerman HJ, et al. Effect of increased renal venous pressure on renal function. *J Trauma*. 1999; 47: 1000-1003.
116. Sugrue M, Jones F, Janjua KJ, Deane SA, Bristow P, Hillman K. Temporary abdominal closure: a prospective evaluation of its effects on renal and respiratory physiology. *J Trauma*. 1998; 45: 914-921.
117. Sugrue M, Balogh Z, Malbrain M. Intra-abdominal hyper-

- tension and renal failure. *Aust N Z J Surg.* 2004; 74: 78.
118. Balogh Z, McKinley BA, Holcomb JB, et al. Both primary and secondary abdominal compartment syndrome can be predicted early and are harbingers of multiple organ failure. *J Trauma.* 2003; 54: 848-861.
119. Vachharajani V, Scott LK, Grier L, Conrad S. Medical management of severe intra-abdominal hypertension with aggressive diuresis and continuous ultra-filtration. *Internet J Emerg Intensive Care Med.* 2003; 6.
120. Vinsonneau C, Camus C, Combes A, et al. Continuous venovenous haemodia filtration versus intermittent haemodialysis for acute renal failure in patients with multiple-organ dysfunction syndrome: a multicentre randomized trial. *Lancet.* 2006; 368: 379-385. doi: [10.1016/S0140-6736\(06\)69111-3](https://doi.org/10.1016/S0140-6736(06)69111-3)
121. Diebel LN, Dulchavsky SA, Wilson RF. Effect of increased intra-abdominal pressure on mesenteric arterial and intestinal mucosal flow. *J Trauma.* 1992; 33: 45-49.
122. Bongard FB, Ryan M, Dubecz. Adverse consequences of increased intraabdominal pressure on bowel tissue oxygen. *J Trauma.* 1995; 39: 519-525.
123. Diebel LN, Wilson RF, Dulchavsky SA. Effect of increased intra-abdominal pressure on hepatic arterial, portal venous and hepatic microcirculatory blood flow. *J Trauma.* 1992; 33: 279-283.
124. Eleftheriadis S, Kotzampassi K, Botsios D, et al. Splanchnic ischemia during laparoscopic cholecystectomy. *Surg Endosc.* 1996; 10: 324-326.
125. Agusti M, Elizalde JI, Adalia R, et al. Dobutamine restores intestinal mucosal blood flow in a porcine model of intra-abdominal hypertension. *Crit Care Med.* 2000; 28: 467-472
126. Simon RJ, Friedlander MH, Ivatury RR, et al. Hemorrhage lowers the threshold for intra-abdominal hypertension (IAH) induced pulmonary dysfunction. *J Trauma.* 1997; 42: 398-405.
127. Friedlander M, Simon RJ, Ivatury RR, et al. The effect of hemorrhage on SMA flow during increased intraabdominal pressure. *J Trauma.* 1998; 45: 433-439.
128. Eleftheriadis E, Kotzampassi K, Papanatos K, et al. Gut ischemia, oxidative stress and bacterial translocation in elevated abdominal pressure in rats. *World J Surg.* 1996; 20: 11-16. doi: [10.1007/s002689900002](https://doi.org/10.1007/s002689900002)
129. Diebel LN, Dulchavsky SA, Brown HJ. Splanchnic ischemia and bacterial translocation in abdominal compartment syndrome. *J Trauma.* 1997; 43: 852-855.
130. Doty J, Oda J, Ivatury RR, et al. The effect of haemorrhage followed by intraabdominal hypertensions on bacterial translocation. *J Trauma.* 2002; 52: 13-17.
131. Balogh Z, McKinley BA, Cox CS Jr, et al. Abdominal compartment syndrome: the cause or effect of post injury multiple organ failure. *Shock.* 2003; 20: 483-492.
132. Rezende-Neto JB, Moore EE, Masuno T, et al. The abdominal compartment syndrome as a second insult during systemic neutrophil priming provokes multiple organ injury. *Shock.* 2003; 20: 303-308.
133. Oda J, Ivatury RR, Blocher CL, et al. Amplified cytokine response and lung injury by sequential haemorrhagic shock and abdominal compartment syndrome in a laboratory model of ischemia-reperfusion. *J Trauma.* 2002; 52: 625-631.
134. Rezende-Neto JB, Moore EE, Melo de Andrade MV, et al. Systemic inflammatory response secondary to abdominal compartment syndrome. Stage for multiple organ failure. *J Trauma.* 2002; 53: 1121-1128.
135. Düzgün AP, Gülgez B, Özmutlu A, et al. The relationship between intestinal hypoperfusion and serum D-lactate levels during experimental intra-abdominal hypertension. *Dig Dis Sci.* 2006.
136. Sukhotnik I, Bejar J, Srugo I, et al. Adverse effects of increased intra-abdominal pressure on small bowel structure and bacterial translocation in the rat. *J Laparoendosc Adv Surg Tech A.* 2006; 16: 404-410. doi: [10.1089/lap.2006.16.404](https://doi.org/10.1089/lap.2006.16.404)
137. Meierhenrich R, Gauss A, Vandenesch PP, Georgieff M, Poch B, Schutz W. The effects of intra-abdominally insufflated carbon dioxide on hepatic blood flow during laparoscopic surgery assessed by transesophageal echocardiography. *Anesth Analg.* 2005; 100: 340-347.
138. Nakatani T, Sakamoto Y, Kaneko Y, et al. Effects of intra-abdominal hypertension on hepatic energy metabolism in a rabbit model. *J Trauma.* 1998; 44: 446-453.
139. Ye A, Schein M, Margolis M, et al. Liver enzymes are commonly elevated following laparoscopic cholecystectomy. Is elevated intra-abdominal pressure the cause? *Dig Surg.* 1998; 15: 256-259.
140. Saber AA, Laraja RD, Nalbandian HI, Pablos-Mendez A, Hanna K. Changes in liver function tests after laparoscopic cholecystectomy. *Am Surg.* 2000; 66: 699-702.
141. Wachsberg RH. Narrowing of the upper abdominal inferior vena cava in patients with elevated intra-abdominal pressure: sonographic observations. *J Ultrasound Med.* 2000; 19: 217-222.

142. Dalfino L, Malcangi V, Cinnella G, Brienza N. Abdominal hypertension and liver dysfunction in Intensive Care Unit patients: an “on-off” phenomenon? *Transpl Proc.* 2006; 38: 838-840. doi: [10.1016/j.transproceed.2006.03.002](https://doi.org/10.1016/j.transproceed.2006.03.002)
143. Muftuoglu MA, Aktekin A, Ozdemir NC, Saglam A. Liver injury and abdominal compartment syndrome in rats. *Surg Today.* 2006; 36: 519-524.
144. Biancofiore G, Bindi ML, Romanelli AM, et al. Intra-abdominal pressure monitoring in liver transplant recipients: a prospective study. *Intensive Care Med.* 2003; 1: 30-36. doi: [10.1007/s00134-002-1552-7](https://doi.org/10.1007/s00134-002-1552-7)
145. Coriat P, Vrillon M, Perel A, et al. A comparison of systolic blood pressure variations and echocardiographic estimates of end-diastolic left ventricular size in patients after aortic surgery. *Anesth Analg.* 1994; 78: 46-53.
146. Cheatham ML, Safcsak K, Block EF, et al. Preload assessment in patients with an open abdomen. *J Trauma.* 1999; 46: 16-22.
147. Sutcliffe R, Meares H, Auzinger G, et al. Preload assessment in severe liver disease associated with intraabdominal hypertension. *Intensive Care Med.* 2002; 28(Suppl 1): S177 A 688.
148. Auzinger GM, Tilley R, Sizer L, et al. Markers of preload in patients with severe liver disease and intra-abdominal hypertension. *Intensive Care Med.* 2002; 28(Suppl 1): S7 A12.
149. Huseby JS, Luce JM, Cary JM, et al. Effects of positive end-expiratory pressure on intracranial pressure in dogs with intracranial hypertension. *J Neurosurg.* 1981; 55: 704-705.
150. Ratjen F, Trost A, Welker J, Spangenberg P, Weisemann HG. The effect of rapid thoracoabdominal compressions on intracranial pressure in newborn lambs. *Pediatr Res.* 1995; 38: 664-667. doi: [10.1203/00006450-199511000-00006](https://doi.org/10.1203/00006450-199511000-00006)
151. Rosenthal RJ, Friedman RL, Kahn AM, et al. Reasons for intracranial hypertension and hemodynamic instability during acute elevations of intra-abdominal pressure: observations in a large animal model. *J Gastrointest Surg.* 1998; 2: 415-425.
152. Josephs LG, Este-McDonald JR, Birkett DH, et al. Diagnostic laparoscopy increases intracranial pressure. *J Trauma.* 1994; 36: 815-818.
153. Bloomfield GL, Ridings PC, Blocher CR, et al. A proposed relationship between increased intra-abdominal, intrathoracic and intracranial pressure. *Crit Care Med.* 1997; 25: 496-503.
154. Citerio G, Vascotto E, Villa F, Celotti S, Presenti A. Induced abdominal compartment syndrome increases intracranial pressure in neurotrauma patients: a prospective study. *Crit Care Med.* 2001; 29: 1466-1471.
155. Bloomfield GL, Ridings PR, Blocher CR, et al. Effects of increased intra-abdominal pressure upon intracranial and cerebral perfusion pressure before and after volume expansion. *J Trauma.* 1996; 40: 936-943.
156. Dereen DH, Dits H, Malbrain ML. Correlation between intraabdominal and intracranial pressure in nontraumatic brain injury. *Intensive Care Med.* 2005; 31: 1577-1581. doi: [10.1007/s00134-005-2802-2](https://doi.org/10.1007/s00134-005-2802-2)
157. Joseph DK, Dutton RP, Aarabi B, et al. Decompressive laparotomy to treat intractable intracranial hypertension after traumatic brain injury. *J Trauma.* 2004; 57: 687-695.
158. Lyons WS. Surgical abdominal decompression on relieving intractable ICH is of considerable general interest. *J Trauma.* 2004; 56: 723-724.
159. McNelis J, Marini CP, Jurkiewicz A, et al. Predictive factors associated with the development of abdominal compartment syndrome in the surgical intensive care unit. *Arch Surg.* 2002; 137: 133-136. doi: [10.1001/archsurg.137.2.133](https://doi.org/10.1001/archsurg.137.2.133)
160. Balogh Z, McKinley BA, Cocanour CS, et al. Supranormal trauma resuscitation causes more cases of abdominal compartment syndrome. *Arch Surg.* 2003; 138: 637-643. doi: [10.1001/archsurg.138.6.637](https://doi.org/10.1001/archsurg.138.6.637)
161. Ivatury RR. Supranormal trauma resuscitation and abdominal compartment syndrome. *Arch Surg.* 2004; 139: 225-227.
162. Sugeran H, Windsor A, Bessos M, et al. Intra-abdominal pressure, sagittal abdominal diameter and obesity comorbidity. *J Intern Med.* 1997; 241: 71-79.
163. Macalino JU, Goldman RK, Mayberry JC. Medical management of abdominal compartment syndrome: case report and a caution. *Asian J Surg.* 2002; 5: 244-246. doi: [10.1016/S1015-9584\(09\)60184-6](https://doi.org/10.1016/S1015-9584(09)60184-6)
164. De Waele JJ, Benoit D, Hoste E, et al. A role for muscle relaxation in patients with abdominal compartment syndrome? *Intensive Care Med.* 2003; 29: 332.
165. Latenser BA, Kowal-Vern A, Kimball D, et al. A pilot study comparing percutaneous decompression with decompressive laparotomy for acute abdominal compartment syndrome in thermal injury. *J Burn Care Rehabil.* 2002; 23: 190-195.
166. Cabrera J, Falcon L, Gorriz E, et al. Abdominal decompression plays a major role in early postparacentesis haemodynamic changes in cirrhotic patients with tense ascites. *Gut.* 2001; 48:

384-389. doi: [10.1136/gut.48.3.384](https://doi.org/10.1136/gut.48.3.384)

167. Corcos AC, Sherman HF. Percutaneous treatment of secondary abdominal compartment syndrome. *J Trauma*. 2001; 51: 1062-1064.

168. Reckard JM, Chung MH, Varma MK, Zagorski SM. Management of intraabdominal hypertension by percutaneous catheter drainage. *J Vasc Interv Radiol*. 2005; 16: 1019-1021. doi: [10.1097/01.RVI.0000157781.67279.72](https://doi.org/10.1097/01.RVI.0000157781.67279.72)

169. Valenza F, Gartinoni L. Continuous Negative Abdominal Pressure. Abdominal Compartment Syndrome. In: Ivatury RR, Cheatham ML, Malbrain MLNG, Sugrue M, eds. Landes Bioscience Georgetown TX. 2006; 240-253.

170. Bloomfield GL, Saggi BH, Blocher C, et al. Physiologic effects of externally applied continuous negative abdominal pressure for intra-abdominal hypertension. *J Trauma*. 1999; 46: 1009-1014.

171. Adams J, Osiovich H, Goldberg R, et al. Hemodynamic effects of continuous negative extrathoracic pressure and continuous positive airway pressure in piglets with normal lungs. *Biol Neonate*. 1992; 62: 69-75.

172. Kaçmaz A, Polat A, User Y, et al. Octreotide: a new approach to the management of acute abdominal hypertension. *Peptides*. 2003; 24: 1381-1386. doi: [10.1016/j.peptides.2003.09.004](https://doi.org/10.1016/j.peptides.2003.09.004)

173. Kaçmaz A, Polat A, User Y, et al. Octreotide improves reperfusion-induced oxidative injury in acute abdominal hypertension in rats. *J Gastrointest Surg*. 2004; 8: 113-119.

174. Sener G, Kaçmaz A, User Y, et al. Melatonin ameliorates oxidative organ damage induced by acute intra-abdominal compartment syndrome in rats. *J Pineal Res*. 2003; 35: 163-168. doi: [10.1034/j.1600-079X.2003.00070.x](https://doi.org/10.1034/j.1600-079X.2003.00070.x)

175. Vachharajani V, Scott LK, Grier L, Conrad S. Ultra medical management of severe intra-abdominal hypertension with aggressive diuresis and continuous-filtration. *The Internet J Emerg and Intensive Care Med*. 2003; 6. doi: [10.4103/2349-0977.131859](https://doi.org/10.4103/2349-0977.131859)

176. Keulenaer B, Regli R, De laet I, et al. What's new in medical management strategies for raised intra-abdominal pressure: evacuating intra-abdominal contents, improving abdominal wall compliance, pharmacotherapy, and continuous negative extra-abdominal pressure. *Anaesthesiology Intensive Therapy*. 2014; 47(1): 54-62 doi: [10.5603/AIT.a2014.0065](https://doi.org/10.5603/AIT.a2014.0065)

177. Cheatham ML, De Waele JJ, De Laet I, et al. The impact of body position on intra-abdominal pressure measurement: a multicenter analysis. *Crit Care Med*. 2009; 37: 2187-2190. doi:

[10.1097/CCM.0b013e3181a021fa](https://doi.org/10.1097/CCM.0b013e3181a021fa)

178. Yi M, Leng Y, Bai Y, et al. The evaluation of the effect of body positioning on intra-abdominal pressure measurement and the effect of intra-abdominal pressure at different body positioning on organ function and prognosis in critically ill patients. *J Crit Care*. 2012; 27: 222.e221-226. doi: [10.1016/j.jcrc.2011.08.010](https://doi.org/10.1016/j.jcrc.2011.08.010)

179. Wilmer A, Dits H, Malbrain ML, Frans E, Tack J. Gastric emptying in the critically ill – the way forward? *Intensive Care Med*. 1997; 23: 928-929.

180. The SAFE Study Investigators. A comparison of albumin and saline for fluid resuscitation in the intensive care unit. *N Engl J Med*. 2004; 350: 2247-2256. doi: [10.1056/NEJMoa040232](https://doi.org/10.1056/NEJMoa040232)

181. Schechter WP, Ivatury RR, Rotondo MF, Hirschberg A. Open abdomen after trauma and abdominal sepsis: a strategy for management. *J Am Coll Surg*. 2006; 32: 1912-1914. doi: [10.1016/j.jamcollsurg.2006.06.001](https://doi.org/10.1016/j.jamcollsurg.2006.06.001)

182. Gracias VH, Braslow B, Johnson J, et al. Abdominal compartment syndrome in the open abdomen. *Arch Surg*. 2002; 137: 1198-1200. doi: [10.1001/archsurg.137.11.1298](https://doi.org/10.1001/archsurg.137.11.1298)

183. De Waele JJ, Hoste EAJ, Malbrain MLNG. Decompressive laparotomy for abdominal compartment syndrome—a critical analysis. *Crit Care*. 2006; 10. doi: [10.1186/cc4870](https://doi.org/10.1186/cc4870)

184. Chang MC, Miller PR, D'Agostino R Jr, Meredith JW. Effects of abdominal decompression on cardiopulmonary function and visceral perfusion in patients with intra-abdominal hypertension. *J Trauma*. 1998; 44: 440-445.

185. Kaplan M. Surgical approaches to the open abdomen. Abdominal Compartment Syndrome. In: Ivatury RR, Cheatham ML, Malbrain MLNG, Sugrue M, eds. Landes Bioscience, Georgetown TX, 2006; 282-296.

186. Myers JA, Latensier BA. Nonoperative progressive Bogota Bag closure after abdominal decompression. *Am Surg*. 2002; 68: 1029-1030.

187. Brox-Jiménez A, Ruiz-Luque V, Torres-Arcos C, et al. Experience with the Bogota bag technique for temporary abdominal closure. *Cir Esp*. 2007; 82: 150-154.

188. Schein M, Saadia R, Jamieson JR, Decker GAG. The 'sandwich technique' in the management of the open abdomen. *Br J Surg*. 1986; 73: 369-370. doi: [10.1002/bjs.1800730514](https://doi.org/10.1002/bjs.1800730514)

189. Hadeed JG, Staman GW, Sariol HS, Kumar S, Ross SE. Delayed primary closure in damage control laparotomy: the value of the Wittmann patch. *Am Surg*. 2007; 73: 10-12.

190. Perez D, Wildi S, Demartines N, Bramkamp M, Koehler C, Clavien PA. Prospective evaluation of vacuum-assisted closure in abdominal compartment syndrome and severe abdominal sepsis. *J Am Coll Surg*. 2007; 205: 586-592. doi: [10.1016/j.jamcollsurg.2007.05.015](https://doi.org/10.1016/j.jamcollsurg.2007.05.015)
191. Nagy KK, Fildes JJ, Mahr C, et al. Experience with three prosthetic materials in temporary abdominal wall closure. *Am Surg*. 1996; 62: 331-335.
192. Mayberry JC, Mullins RJ, Crass RA, et al. Prevention of abdominal compartment syndrome by absorbable mesh prosthesis closure. *Arch Surg*. 1997; 132: 957-961. doi: [10.1001/archsurg.1997.01430330023003](https://doi.org/10.1001/archsurg.1997.01430330023003)
193. Tremblay LN, Feliciano DV, Schmidt J, et al. Skin only or silo closure in the critically ill patient with the open abdomen. *Am J Surg*. 2002; 182: 670-675. doi: [10.1016/S0002-9610\(01\)00805-4](https://doi.org/10.1016/S0002-9610(01)00805-4)
194. Garcia-Sabrido JL, Tallado JM, Christou NV, et al. Treatment of severe intra-abdominal sepsis and/or necrotic foci by an "open abdomen" approach. Zipper and zipper-mesh techniques. *Arch Surg*. 1988; 123: 152-156. doi: [10.1001/archsurg.1988.01400260032002](https://doi.org/10.1001/archsurg.1988.01400260032002)
195. Wittmann DH, Aprahamian C, Bergstein JM. Etappenlavage. Advanced diffuse peritonitis managed by planned multiple laparotomies utilizing zippers, slide fastener and Velcro analogue for temporary abdominal closure. *World J Surg*. 1990; 14: 218-226.
196. Cuesta MA, Doblaz M, Castaneda L, et al. Sequential abdominal re-exploration with the zipper technique. *World J Surg*. 1991; 15: 74-80.
197. Navsaria PH, Bunting M, Omshoro-Jones J, Nicol AJ, Kahn D. Temporary closure of open abdominal wounds by the modified sandwich-vacuum pack technique. *Br J Surg*. 2003; 90: 718-722. doi: [10.1002/bjs.4101](https://doi.org/10.1002/bjs.4101)
198. Fansler RF, Taheri P, Cullinane C, et al. Polypropylene mesh closure of the complicated abdominal wound. *Am J Surg*. 1995; 170: 15-18. doi: [10.1016/S0002-9610\(99\)80244-X](https://doi.org/10.1016/S0002-9610(99)80244-X)
199. Jernigan TW, Fabian TC, Croce MA, et al. Staged management of giant abdominal wall defects. acute and long-term results. *Ann Surg*. 2003; 238: 349-357. doi: [10.1097/01.sla.0000086544.42647.84](https://doi.org/10.1097/01.sla.0000086544.42647.84)
200. Garner GB, Ware DN, Cocanour CS, et al. Vacuum assisted wound provides early fascial reapproximation in trauma patients with open abdomens. *Am J Surg*. 2001; 182: 630-638. doi: [10.1016/S0002-9610\(01\)00786-3](https://doi.org/10.1016/S0002-9610(01)00786-3)
201. Goverman J, Yelon JA, Platz JJ, Singson RC, Turcinovic M. The fistula VAC, a technique for management of enterocutaneous fistulae arising within the open abdomen: report of 5 cases. *J Trauma*. 2006; 60: 428-431.
202. Goettler CE, Rotondo MF, Schwab CW. Surgical management of the open abdomen after damage control or abdominal compartment syndrome. *Abdominal Compartment Syndrome*. In: Ivatury RR, Cheatham ML, Malbrain MLNG, Sugure M, eds. Landes Bioscience Georgetown TX. 2006; 271-282.
203. Cothren CC, Moore EE, Ciesla DJ, et al. Postinjury abdominal compartment syndrome does not preclude early enteral feeding after definitive closure. *Am J Surg*. 2004; 188: 653-658. doi: [10.1016/j.amjsurg.2004.08.036](https://doi.org/10.1016/j.amjsurg.2004.08.036)
204. Miller PR, Meredith JW, Johnson JC, Chang MC. Prospective evaluation of vacuum-assisted fascial closure after open abdomen: planned ventral hernia rate is substantially reduced. *Ann Surg*. 2004; 239: 608-616. doi: [10.1097/01.sla.0000124291.09032.bf](https://doi.org/10.1097/01.sla.0000124291.09032.bf)
205. Wechselberger G, Schoeller T, Rainer C, et al. Temporary closure of full-thickness abdominal wall defects with mesh grafts. *Langenbecks Arch Surg*. 1999; 384: 88-89.
206. Fabian TC, Croce MA, Pritchard FE, et al. Planned ventral hernia: staged management for acute abdominal wall defects. *Ann Surg*. 1994; 219: 643-653.
207. Miller PR, Thompson JT, Faler BJ, et al. Late fascial closure in lieu of ventral hernia: the next step in open abdomen management. *J Trauma*. 2002; 53: 843-849.
208. Petersson U, Acosta S, Bjorck M. Vacuum-assisted wound closure and mesh-mediated fascial traction: a novel technique for late closure of the open abdomen. *World J Surg*. 2007. doi: [10.1007/s00268-007-9222-0](https://doi.org/10.1007/s00268-007-9222-0)
209. Vogel TR, Diaz JJ, Miller RS, et al. The open abdomen in trauma: do infectious complications affect primary abdominal closure? *Surg Infect (Larchmt)*. 2006; 7: 433-441. doi: [10.1089/sur.2006.7.433](https://doi.org/10.1089/sur.2006.7.433)
210. Howdieshell TR, Proctor CD, Sternberg E, Cué JI, Mondy S, Hawkins ML. Temporary abdominal closure followed by definitive abdominal wall reconstruction of the open abdomen. *Am J Surg*. 2004; 188: 301-306. doi: [10.1016/j.amjsurg.2004.03.007](https://doi.org/10.1016/j.amjsurg.2004.03.007)
211. Ramirez OM, Ruas E, Dellon AL. Components separation method for closure of abdominal-wall defects: an anatomic and clinical study. *Plast Reconstr Surg*. 1990; 86: 519-526.
212. Carlson GW, Elwood E, Losken A, et al. The role of tis-

- sue expansion in abdominal wall reconstruction. *Ann Plast Surg.* 2000; 44: 147-153.
213. Mathes SJ, Steinwald PM, Foster RD, Hoffman WY, Anthony JP. Complex abdominal wall reconstruction: a comparison of flap and mesh closure. *Ann Surg.* 2000; 232: 586-596.
214. Cohen M. Management of abdominal wall defects resulting from complications of surgical procedures. *Clin Plast Surg.* 2006; 33: 281-294. doi: [10.1016/j.cps.2005.12.003](https://doi.org/10.1016/j.cps.2005.12.003)
215. Porshinsky B, Ramasastry S. Abdominal wall reconstruction with free flaps. *Clin Plast Surg.* 2006; 33: 269-280.
216. Cheatham ML, Safcsak K, Llerena LE, et al. Long-term physical, mental and functional consequences of abdominal decompression. *J Trauma.* 2004; 56: 237-242.
217. Cothren CC, Moore EE, Johnson ML, Moore JB, Burch JM. One hundred percent fascial approximation with sequential abdominal closure of the open abdomen. *Am J Surg.* 2006; 192: 238-242. doi: [10.1097/TA.0b013e318236b319](https://doi.org/10.1097/TA.0b013e318236b319)
218. Rohrich RJ, Lowe JB, Hackney FL, Bowman JL, Hobar PC. An algorithm for abdominal wall reconstruction. *Plast Reconstr Surg.* 2000; 105: 202-216.
219. Libberecht K, Colpaert SDM, Van Hee R, Jadoul J-L, De Clercq S, Sonnevile T. New developments in abdominal wall reconstruction after abdominal compartment syndrome decompression. *Acat Clin Belg.* 2007; 62: 220-4 OA 29.
220. Paletta CF, Huang DB, Dehgan K, et al. The use of tissue expanders in staged abdominal wall reconstruction. *Ann Plast Surg.* 1999; 42: 259-265.
221. Butler CE, Langstein HN, Kronowitz SJ. Pelvic, abdominal and chest wall reconstruction with AlloDerm in patients at increased risk for mesh-related complications. *Plast Reconstr Surg.* 2005; 116: 1263-1277.
222. Butler CE. The role of bioprosthesis in abdominal wall reconstruction. *Clin Plast Surg.* 2006; 33: 199-211. doi: [10.1016/j.cps.2005.12.009](https://doi.org/10.1016/j.cps.2005.12.009)
223. Giroto JA, Ko MJ, Redett R, Muehlenberger T, Talamani M, Chang B. Closure of chronic abdominal wall defects: a long-term evaluation of the components separation method. *Ann Plast Surg.* 1999; 42: 385-395.
224. Lowe JB 3rd, Lowe JB, Baty JD, Garza JR. Risks associated with components separation for closure of complex abdominal wall defects. *Plast Reconstr Surg.* 2003; 111: 1276-1288.
225. Lowe JB, Garza JR, Bowman JL, Rohrich RJ, Strodel WE. Endoscopically assisted components separation for closure of abdominal wall defects. *Plast Reconstr Surg.* 2000; 105: 720-730.
226. Saulis AS, Dumanian GA. Periumbilical rectus abdominis perforator preservation significantly reduces superficial wound complications in separation of parts hernia repairs. *Plast Reconstr Surg.* 2002; 109: 2275-2280.
227. Nguyen V, Shestak KC. Separation of anatomic components method of abdominal wall reconstruction-clinical outcome analysis and an update of surgical modifications using the technique. *Clin Plast Reconstr Surg.* 2006; 33: 247-257. doi: [10.1016/j.cps.2005.12.010](https://doi.org/10.1016/j.cps.2005.12.010)
228. Shestak KC, Edington HJ, Johnson RR. The separation of anatomic components technique for the reconstruction of massive midline abdominal wall defects: anatomy, surgical technique, applications and limitations revisited. *Plast Reconstr Surg.* 2000; 105: 731-739.
229. Disa JJ, Goldberg NH, Carlton JM, et al. Restoring abdominal wall integrity in contaminated tissue-deficient wounds using autologous fascia grafts. *Plast Reconstr Surg.* 1998; 101: 979-986.
230. Hultman CS, Pratt B, Cairns BA, et al. Multidisciplinary approach to abdominal wall reconstruction after decompressive laparotomy for abdominal compartment syndrome. *Ann Plast Surg.* 2005; 54: 269-275.