

## Case Report

### \*Corresponding author

**CPT. Katherine D. Percy, DO**  
Department of Emergency Medicine  
Carl R. Darnall Army Medical Center  
36000 Darnall Loop, Fort Hood  
TX 76544, USA  
E-mail: [katepercydo@gmail.com](mailto:katepercydo@gmail.com)

Volume 3 : Issue 1

Article Ref. #: 1000EMOJ3133

### Article History

Received: December 9<sup>th</sup>, 2016

Accepted: February 16<sup>th</sup>, 2017

Published: February 17<sup>th</sup>, 2017

### Citation

Percy KD, Federico MD, Mellick LB. Unusual rash development in a 7-year-old male. *Emerg Med Open J.* 2017; 3(1): 14-15. doi: [10.17140/EMOJ-3-133](https://doi.org/10.17140/EMOJ-3-133)

### Copyright

©2017 Percy KD. This is an open access article distributed under the Creative Commons Attribution 4.0 International License (CC BY 4.0), which permits unrestricted use, distribution, and reproduction in any medium, provided the original work is properly cited.

# Unusual Rash Development in a 7-Year-Old Male

**CPT. Katherine D. Percy, DO<sup>1\*</sup>; Lt. Col. Massimo D. Federico, MD<sup>1</sup>; Larry B. Mellick, MD<sup>2</sup>**

<sup>1</sup>Department of Emergency Medicine, Carl R. Darnall Army Medical Center, 36000 Darnall Loop, Fort Hood, TX 76544, USA

<sup>2</sup>Department of Emergency Medicine, Augusta University, Health Sciences Campus, AF-1020, 1120 15<sup>th</sup> Street, Augusta, Georgia 30912, USA

## CHIEF COMPLAINT

Redness and swelling to left leg.

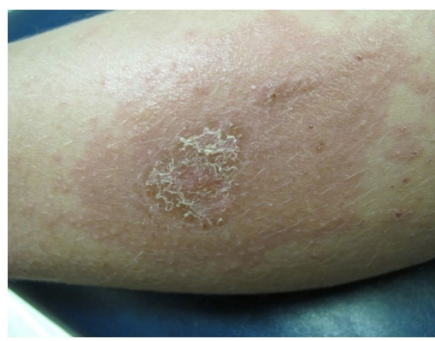## HISTORY OF PRESENT ILLNESS

An otherwise healthy 7-year-old male presented to the emergency department complaining of a pruritic, red rash with that had increased in area over 7 days. The rash reportedly began as a localized lesion on his left lower extremity and developed a secondary diffuse rash over the trunk and upper extremities after the initial ED encounter. During the initial emergency department visit he was prescribed diphenhydramine and topical hydrocortisone with minimal relief. He denied any known environmental or allergen exposures or asthma history suggesting atopic dermatitis, or new exposures to medications. The patient and his parent also denied fever, lymphadenopathy, or any respiratory signs and symptoms. The leg lesion was not indurated or fluctuant to suggest underlying abscess. There were no other ill contacts or family history of similar rashes.

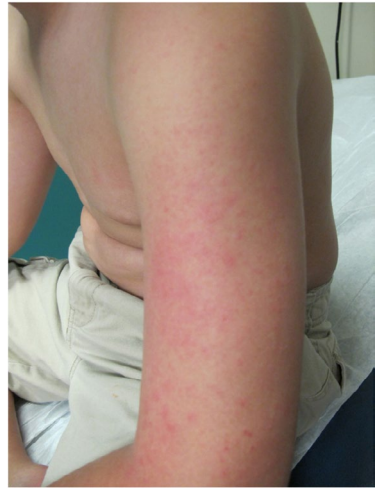## PERTINENT PHYSICAL EXAMINATION

The patient was well appearing, well developed and well nourished with no acute distress. He had no signs of anaphylaxis with normal cardiac, lung, and abdominal exams. An eczematous erythematous fine maculopapular rash was limited to torso and extremities excluding mucous membranes, hands, feet, and groin as seen in the following images. The left lower extremity had a notable round 1 cm crusted plaque with excoriation on an erythematous base. Head, eyes, ears, neck, and throat (HEENT) exam was unremarkable without conjunctivitis, oral lesions, facial swelling, lymphadenopathy or erythema.

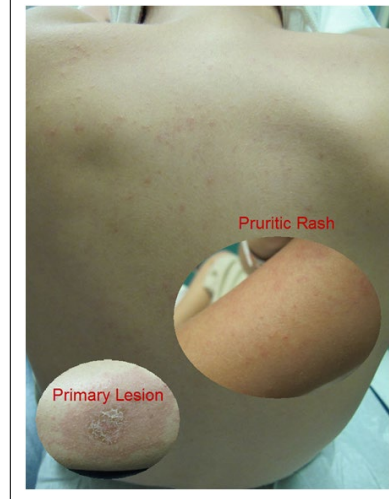
**Figure 1:** Primary Impetigo Lesion Partially Altered in Appearance due to the Recent Application of Topical Corticosteroids.



**Figure 2:** Diffuse Maculopapular Pruritic Rash, a Dermatological ID Reaction Manifestation.



**Figure 3:** Composite Image of the ID Reaction on the Extremity and Back as well as the Primary Lesion.



1. What is the condition?
2. What is the treatment of this condition?

#### ANSWERS

1. The rash on patient in this photograph represents a case of id Reaction. This is a type IV hypersensitivity reaction that results in a generalized, acute skin rash developing as a response to an underlying infectious agent or inflammatory skin condition.<sup>1-3</sup> In this case, the underlying cause is the impetigo found on the left lower extremity noted prior to the onset of the more generalized rash of the id reaction. Note the well-circumscribed erythematous border with central crusting on the image of the primary lesion. The appearance varies depending on the inciting source, but typically involves a symmetrical, maculopapular, pruritic rash distant from the inciting event site. No fungal or bacterial organisms are present outside of the primary rash site. The id reaction occurs 1-2 weeks after the initiating event, and severity increases with excoriation or inappropriate therapy.
2. The antihistamine and topical corticosteroid treatment previously prescribed to the patient are both indicated for symptomatic relief; however, eradicating the inciting source is the only way to rid the body of an id reaction. The time to resolution varies, depending on the underlying etiology. For this patient, mupirocin cream and oral cephalexin were necessary to clear the impetigo, allowing the id reaction to resolve subsequently. One should consider systemic corticosteroids for extensive, severe, or refractory cases. A dermatology consultation for follow-up is also warranted.

#### CONFLICTS OF INTEREST

The authors declare that they have no conflicts of interest.

#### CONSENT

Written informed consent was obtained from the patient who participated in this case.

#### REFERENCES

1. Chirac A, Brzezinski P, Chiriac AE, Foia L, Pinteala T. Auto-sensitisation (Autoeczematisation) reactions in a case of diaper dermatitis candidiasis. *Nigerian Medical Journal*. 2014; 55(3): 274-275. doi: [10.4103/0300-1652.132070](https://doi.org/10.4103/0300-1652.132070)
2. Ilkit M, Durdu M, Karakaş M. Cutaneous id reactions: A comprehensive review of clinical manifestations, epidemiology, etiology, and management. *Crit Rev Microbiol*. 2012; 38(3): 191-202. doi: [10.3109/1040841X.2011.645520](https://doi.org/10.3109/1040841X.2011.645520)
3. Tintinalli JE, Stapczynski JS. Skin disorders. In: *Tintinalli's Emergency Medicine: A Comprehensive Study Guide*. New York, NY, USA: McGraw-Hill; 2011.