

Case Report

Transcatheter Arterial Embolization in Postpartum Hemorrhage: A Case Report

Alka Chhabra, MBBS, MD, DNB, MNAMS^{1*}; Anil Bhiwal, MBBS, DA, DNB, MNAMS, FIPM¹; Neha Pandey, MD¹; Sitaram Barath, MBBS, MD, FNVIR²; Sunanda Gupta, MBBS, MD, PhD, FAMS, FICA¹

¹Department of Anaesthesiology and Critical Care Geetanjali Medical College and Hospital, Udaipur 313001, Rajasthan, India

²Department of Neuro & Vascular Interventional Radiology, Geetanjali Medical College and Hospital, Udaipur 313001, Rajasthan, India

*Corresponding author

Alka Chhabra, MBBS, MD, DNB, MNAMS

Professor, Department of Anaesthesiology and Critical care Geetanjali Medical College and Hospital, 35, Krishna Vihar, New Vidhya Nagar, Hiran Magri Sec-4, Udaipur 313001, Rajasthan, India; Tel. 08890911487; E-mail: alkakk_26@yahoo.co.in

Article information

Received: July 2nd, 2019; **Revised:** July 12th, 2019; **Accepted:** July 22nd, 2019; **Published:** July 25th, 2019

Cite this article

Chhabra A, Bhiwal A, Pandey N, Barath S, Gupta S. Transcatheter arterial embolization in postpartum hemorrhage: A case report. *Res Pract Anesthesiol Open J.* 2019; 4(1): 14-17. doi: [10.17140/RPAOJ-4-125](https://doi.org/10.17140/RPAOJ-4-125)

ABSTRACT

Background

Postpartum haemorrhage is the leading cause of maternal mortality and morbidity. The significant impact of postpartum haemorrhage (PPH) on maternal mortality can be reduced if timely measures are implemented. Transcatheter arterial embolisation (TAE) is an alternative therapeutic strategy for PPH.

Case report

We report a case of postpartum haemorrhage which was managed by transcatheter arterial embolization in lieu of hysterectomy to preserve fertility and menstruation in a 27-year-old patient.

Conclusion

The critical role of obstetrician, anaesthesiologist and interventional radiologist as a team, improve the quality of care and patient safety.

Keywords

Postpartum hemorrhage (PPH); Peripartum hysterectomy; Transarterial embolisation.

INTRODUCTION

Postpartum haemorrhage (PPH) is often unpredictable, catastrophic and remains a challenge for anaesthesiologist and obstetricians. Peripartum hysterectomy is usually reserved for refractory cases of PPH, when all other methods to arrest bleeding fails which results in inability to preserve fertility, a psychological impact in young females and risk of intraoperative surgical morbidities. Advances in interventional radiology and surgical techniques are being utilized as alternatives to hysterectomy in many cases.¹ TAE should be widely available and in patients who are at risk of developing PPH and in actively bleeding parturients, indeed in some cases it should be considered as a primary treatment. At hospital level, the multi-professional, interdisciplinary approach have shown to improve quality of care and patient safety.² This case report highlights PPH secondary to perineal trauma during vaginal

delivery which was successfully managed by transcatheter arterial embolization in interventional radiology suite.

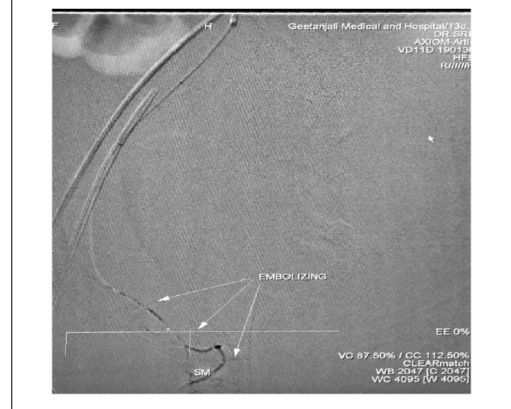
CASE REPORT

A 27-years-old, second gravida (G2A1) was admitted in our hospital in labor at 37-weeks gestation. Her past medical and obstetric history was remarkable for hypothyroidism and spontaneous abortion 2-years back. Syntocinon infusion was commenced to augment labor along with rupture of membranes prematurely. Six hours later, after right mediolateral episiotomy, a live 2.9 kg male baby was delivered vaginally. The placenta and its membrane were delivered intact without any difficulty. Episiotomy was sutured, haemostasis was achieved and she was transferred to maternity ward. Patient had initially stable haemodynamics while in ward, but two hours later she had an acute episode of giddiness,

became tachypnoic, pale and drowsy. Her blood pressure dropped to 90/50 mm Hg, heart rate increased to 120 bpm, respiratory rate 26 per mins and observed oxygen saturation was 93% on room air. Initial resuscitation with one litre of crystalloid and oxygen by face mask at 5 L/min was done. Vaginal examination by the obstetric team revealed a large lateral wall haematoma while, per abdomen examination revealed a palpable, relaxed uterus above the umbilicus. Immediately, IV ergometrine 0.2 mg, IM carboprost 250 mcg, rectal misoprost 500 mg and IV tranexamic acid 1 gm was supplemented. Based on her clinical symptoms and consideration of haemorrhagic shock, she was shifted to the operating room (OR) for further monitoring, resuscitation and possible surgical intervention. In the OR, general anesthesia was induced, trachea intubated and maintained on intermittent fentanyl, atracurium, oxygen and Sevoflurane. Two units of blood was transfused as 100 ml of clot was evacuated and haemostasis was achieved. She was kept on conservative treatment and transferred to the surgical intensive care unit (SICU) on mechanical ventilation. On reexamination by the obstetric team after an hour, multiple clots in the cervix and vagina with active trickle of blood was observed. She was hemodynamically unstable and her systemic vascular resistance was supported by IV Norepinephrine infusion. Bed side ultrasonography revealed mild free fluid in the peritoneal cavity and bulky contracted uterus. Haematologic investigation showed haemogram of 7 gm/dL, platelet count 68×10^9 litre⁻¹, aPTT 40.5, PT 14.5, INR 1.15. Arterial blood gas analysis was within normal range. On bed side 2D echocardiogram, ejection fraction was 45-50%. A femoral venous access under ultrasonographic guidance was placed and massive transfusion protocol was activated with 4U packed red cells and 4 FFP's. The interventional radiology team was contacted and decision for transcatheter arterial embolisation was taken in an attempt to stop bleeding while preparing for further laparotomy and hysterectomy.

further bleeding. No immediate complications occurred and she was transferred back to SICU. She remained haemodynamically stable there after, maintaining blood pressure without vasopressors. She was extubated on 2nd day and discharged on day 3 after an uneventful recovery.

Figure 2. Showing Transarterial Embolisation



DISCUSSION

Postpartum haemorrhage is a life threatening complication and still remains a major cause of maternal death in developed and developing countries. According to statistics of World Health Organization (WHO), 25% of maternal death are due to PPH. Incidence of PPH reported after vaginal delivery is 2% - 4% while it is 6% after caesarean section; with uterine atony has been found as the cause in about 50% cases.³

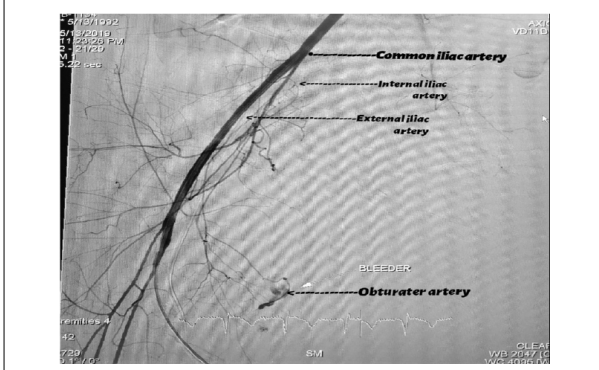
Obstetric intervention for uterine atony, examination of retained or adherent placenta, trauma to genital urinary tract, restoration of haemodynamics, correction of coagulopathy and timely management by surgical or radiological intervention are included in Standard of care of PPH.⁴

PPH secondary to trauma may follow after vaginal delivery, mediolateral episiotomy, more than 4 kgs neonate delivered vaginally.⁵ Lacerations and haematomas of perineum, vagina and cervix during vaginal delivery accounts for 8-20% of PPH alone or in association with uterine atony and are sometimes associated with significant haemorrhage, subsequently leading to hypovolemia.^{6,7} Management includes surgical exploration, evacuation, and ligation of vessels to avoid severe complications like pelvic infection, septicemia, pressure necrosis, profuse bleeding and death.^{8,9}

Regardless of the cause of PPH, when medical and surgical options such as curettage, B-Lynch, uterine or internal iliac artery ligation fails, timely decision for hysterectomy is often the definitive treatment to control bleeding. Technical difficulties during anaesthetic management of PPH, massive blood transfusion, coagulopathy and injury of the urinary tract are some of the known complications of peripartum emergency hysterectomy.¹⁰

The anaesthesiologist play an important role in

Figure 1. Showing Bleeding from Obturator Artery



Subsequently the patient was transferred to interventional radiology suite under continuous midazolam sedation and mechanical ventilation. Following right femoral artery approach, internal iliac artery was catheterized using 5F, 0.17 microcatheter. Digital subtraction angiography (Artis zee - Siemens) showed active extravasation from right obturator artery and site of bleeding was identified (Figure 1), embolization of obturator artery using super selective gel foam was performed successfully (Figure 2). Post embolization angiogram was satisfactory and showed no

management of PPH and should confirm anaesthetic plan with team until resolution of PPH. Although anaesthetic management includes neuraxial block in haemodynamic stable patients, initial plan for general anaesthesia is usually planned for severe cases of PPH.

Interventional radiology and surgical techniques have proved secured and potent alternatives to hysterectomy in many cases and an interventional radiologist should be involved at the time when abnormal bleeding is observed or expected, regardless of severity of PPH and haemodynamic status of the patients,¹¹ transcatheter arterial embolization (TAE) is widely accepted as an productive therapeutic procedure for PPH of various causes with several advantages such as being a fast and a repeatable procedure that can be performed under local anaesthesia and or monitored anaesthesia care. In our case the patient was already on mechanical ventilation support and haemodynamically unstable so it was carried under continuous sedation. It also preserves the uterus and makes future menstruation and fertility possible. The most frequently bleeding source in PPH is collaterals to uterus, uterine, vaginal and internal pudental arteries which manifest as a pseudoaneurysm or contrast extravasation in angiography of the pelvic floor vasculature. The advantages of TAE are pointing out bleeding site easily, reduced re-bleeding from collaterals as more distal occlusion of bleeding vessels are carried out. Therefore, knowledge regarding normal and deviated anatomy of the female genital tract is essential for accurate interpretation of angiographic images and safe performance of PPH embolisation to minimize complication rate during the procedure, TAE obviates the need for laparotomy and should be considered as first line hemostatic measure for patients. However, if ligation would be carried out first, embolisation after ligation is almost difficult and sometimes impossible and in such cases, the only remaining option is hysterectomy.¹² Some studies have reported a role of intraoperative uterine artery embolization in prevention of massive PPH in cases of caesarean hysterectomy.^{13,14}

TAE for control of obstetric hemorrhage was first carried out successfully by Brown in 1979.¹⁵ A high success rate of 94.9% with low complication rate was found by Badaway et al who reviewed 138 cases of PPH and need for hysterectomy due to failure of embolization was only in 5% of cases,¹⁶ while Pelage et al, used gelatin sponge in all fourteen continuous cases of uncontrolled hemorrhage, and in two cases of false aneurysm they used N-butyl-acrylate.¹⁷

Although there is high success rate and low complication rate of arterial embolization making it a beneficial alternative in managing PPH, there are potential complications angiography comprise low grade fever, hematoma at the site of catheter placement, infection like pelvic abscess; contrast related side effects, ischemic phenomena, and rarely iliac artery perforation.^{16,18}

The potential limitations include the management of performing the procedure during labour and delivery when equipment and interventional radiologists may not be available at

all centers.

CONCLUSION

A multidisciplinary collaboration between anaesthesiologist-obstetrician and interventional radiologist can avert maternal morbidity and mortality secondary to PPH, through early diagnosis and rapid intervention. TAE should be implemented without any delay as effective and safe therapeutic modality for PPH to preserve fertility by avoiding hysterectomy.

CONSENT

The patient has provided written permission for publication of the case details.

CONFLICTS OF INTEREST

The authors declare that they have no conflicts of interest.

REFERENCES

1. Abouzahr C. Global burden of maternal death and disability. *Br Med Bull.* 2003; 67(1): 1-11. doi: [10.1093/bmb/ldg015](https://doi.org/10.1093/bmb/ldg015)
2. Cooper JB. Critical role of surgeon–anesthesiologist relationship for patient safety. *Anesthesiology.* 2018; 129(3): 402-405. doi: [10.1097/ALN.0000000000002324](https://doi.org/10.1097/ALN.0000000000002324)
3. Amy JJ. Severe postpartum hemorrhage: A rational approach. *Natl Med J India.* 2008; 11(2): 86-88.
4. Phillips LE, McLintock C, Pollock W, et al. Recombinant activated factor VII in obstetric hemorrhage: Experiences from the Australian and New Zealand Haemostasis Registry. *Anesth Analg.* 2009; 109(6): 1908-1915. doi: [10.1213/ANE.0b013e3181c039e6](https://doi.org/10.1213/ANE.0b013e3181c039e6)
5. Royal College of Obstetricians and Gynaecologists Green Top 52. Postpartum haemorrhage, prevention and management. *Int J Obstet Anesth.* 2001; 20: S22.
6. Sentilhes L, Vayssière C, Deneux-Tharoux C, et al. Postpartum hemorrhage: Guidelines for clinical practice from the French College of Gynaecologists and Obstetricians (CNGOF): In collaboration with the French Society of Anesthesiology and Intensive Care (SFAR). *Eur J Obstet Gynecol Reprod Biol.* 2016; 198: 12-21. doi: [10.1016/j.ejogrb.2015.12.012](https://doi.org/10.1016/j.ejogrb.2015.12.012)
7. Lee HY, Shin JH, Kim J, et al. Primary postpartum hemorrhage: Outcome of pelvic arterial embolization in 251 patients at a single institution. *Radiology.* 2012; 264: 903-909. doi: [10.1148/radiol.12111383](https://doi.org/10.1148/radiol.12111383)
8. Chestnut DH, Polley LS, Wong CA, Tsen LC. *Chestnut's Obstetric Anaesthesia Principles and Practice.* 4th ed. Maryland Heights, Missouri,

USA: Mosby publisher; 2009: 825-830.

9. You WB, Zahn CM. Postpartum hemorrhage: Abnormally adherent placenta, uterine inversion, and puerperal hematomas. *Clin Obstet Gynecol.* 2006; 49(1): 184-197. doi: [10.1097/01.grf.0000197544.87808.9c](https://doi.org/10.1097/01.grf.0000197544.87808.9c)
10. Anast N, Kwok J, Carvalho B, Lipman S, Flood P. Intact survival after obstetric hemorrhage and 55 Minutes of cardiopulmonary resuscitation. *A A Case Rep.* 2015; 5: 9-12. doi: [10.1213/XAA.0000000000000163](https://doi.org/10.1213/XAA.0000000000000163)
11. Cali G, Forlani F, Giambanco L, et al. Prophylactic use of intra-vascular balloon catheters in women with placenta accreta, increta and percreta. *Eur J Obstet Gynecol Reprod Biol.* 2014; 179: 36-41. doi: [10.1016/j.ejogrb.2014.05.007](https://doi.org/10.1016/j.ejogrb.2014.05.007)
12. Hong TM., Tseng HS, Lee RC, Wang JH, Chang CY. Uterine artery embolization: An effective treatment for intractable obstetric haemorrhage. *Clin Radiol.* 2004; 59: 96-101. doi: [10.1016/j.crad.2003.08.007](https://doi.org/10.1016/j.crad.2003.08.007)
13. Li Q, Yang ZQ, Mohammed W, Feng YL, Shi HB, Zhou X. Prophylactic uterine artery embolization assisted cesarean section for the prevention of intrapartum hemorrhage in high risk patients. *Cardiovas Intervent Radiol.* 2014; 37: 1458-1463. doi: [10.1007/s00270-014-0855-8](https://doi.org/10.1007/s00270-014-0855-8)
14. Lee JW, Song IA, Ryu J, Park HP, Jeon YT, Hwang JW. Anesthetic management of a parturient with placenta previa totalis undergoing preventive uterine artery embolization before placental expulsion during cesarean delivery: A case report. *Korean J Anesthesiol.* 2014; 67: 279-282. doi: [10.4097/kjae.2014.67.4.279](https://doi.org/10.4097/kjae.2014.67.4.279)
15. Heaston DK, Mineau DE, Brown BJ, Miller FJ. Transcatheter arterial embolization for control of persistent massive puerperal hemorrhage after bilateral surgical hypogastric artery ligation. *Am J Roentgenol.* 1979; 133: 152-154. doi: [10.2214/ajr.133.1.152](https://doi.org/10.2214/ajr.133.1.152)
16. Badaway SZA, Etman A, Singh M, Murphy K, Mayelli T, Philadelphia M. Uterine artery embolization: The role in obstetrics and gynecology. *Clin Imaging.* 2001; 25: 288-295. doi: [10.1016/S0899-7071\(01\)00307-2](https://doi.org/10.1016/S0899-7071(01)00307-2)
17. Pelage JP, Soyer P, Repiquet D, et al. Secondary postpartum hemorrhage: Treatment with selective arterial embolization. *Radiology.* 1999; 212: 385-389. doi: [10.1148/radiology.212.2.r99jl05385](https://doi.org/10.1148/radiology.212.2.r99jl05385)
18. Vedantham S, Goddwin SC, McLucas B, Mohr G. Uterine artery embolization: An underused method of controlling pelvic hemorrhage. *Am J Obstet Gynecol.* 1997; 176: 938-948. doi: [10.1016/s0002-9378\(97\)70624-0](https://doi.org/10.1016/s0002-9378(97)70624-0)