

## Systematic Review

# The Prevalence of Pathologic Q Waves on Electrocardiograms of Pediatric Patients with Confirmed Hypertrophic Cardiomyopathy: A Systematic Review of the Literature

Larry B. Mellick, MD, MS, FAAP, FACEP<sup>1\*</sup>; Kanya Singhapakdi, DO<sup>2</sup>; Clista Clanton, MSLS<sup>3</sup>; Ronnie Waldrop, MD<sup>1</sup>

<sup>1</sup>Division of Pediatric Emergency Medicine, Department of Emergency Medicine, University of South Alabama, Mobile, AL, USA

<sup>2</sup>Department of Pediatrics, University of South Alabama, Mobile, AL, USA

<sup>3</sup>Baugh Biomedical Library, University of South Alabama, Mobile, AL, USA

\*Corresponding author

Larry B. Mellick, MD, MS, FAAP, FACEP

Professor, Division of Pediatric Emergency Medicine, Department of Emergency Medicine, University of South Alabama, Mobile, AL, USA;

E-mail: [lmellick@health.southalabama.edu](mailto:lmellick@health.southalabama.edu)

### Article information

Received: August 25<sup>th</sup>, 2021; Accepted: October 18<sup>th</sup>, 2021; Published: January 2<sup>nd</sup>, 2022

### Cite this article

Mellick LB, Singhapakdi K, Clanton C, Waldrop R. The prevalence of pathologic Q waves on electrocardiograms of pediatric patients with confirmed hypertrophic cardiomyopathy: A systematic review of the literature. *Emerg Med Open J.* 2022; 8(1): 1-6. doi: [10.17140/EMOJ-8-163](https://doi.org/10.17140/EMOJ-8-163)

## ABSTRACT

### Objectives

The electrocardiogram (ECG) of patients with hypertrophic cardiomyopathy (HCM) ranges from normal to exhibiting evidence of ventricular hypertrophy, including pathologic Q waves and ST-T wave changes. Deep Q waves in the inferior and lateral leads are one of the classic ECG findings associated with HCM. The prevalence or frequency of this finding in pediatric HCM patients, however, is not well-established. Furthermore, other pediatric health conditions have also been associated with pathologic and non-pathologic Q waves and an awareness of those conditions is important to consider when Q waves are observed. The primary goal of this systematic review of the literature is to describe the prevalence of pathologic Q waves in the ECGs of pediatric patients with echocardiogram proven HCM. A secondary goal is to review other pediatric conditions that can present with pathologic and non-pathologic Q waves.

### Methods

The databases PubMed, Web of Science, Scopus and cumulative index to nursing and allied health literature (CINAHL) were searched utilizing the preferred reporting items for systematic reviews and meta-analyses (PRISMA) format. The Rayyan systemic review software was used to screen articles for final review. The initial search (Search 1) consisted of the following terms: “dagger Q wave”, “dagger-like Q waves”, “dagger shape Q waves”. Subsequently, a broader search (Search 2) was conducted to determine if viable articles were omitted in the first search. This broader search strategy eliminated the term “HCM”. The authors then performed detailed review of the articles these two searches yielded, as well as a review of the references of these articles to find other relevant articles as well as produce a list of other pediatric conditions that may be associated with pathologic or non-pathologic Q waves.

### Results

Of the articles found *via* the three searches, a total of nine English language articles that specifically addressed the prevalence of pathological Q waves in pediatric HCM patients were ultimately included in our systematic review. These nine articles described a total of 845 pediatric patients with HCM. Of these, 258 (30.5%) demonstrated pathological Q waves on their electrocardiograms. The range of percentages reported for pathological Q waves was 12.5 to 66.7%. Additionally, our review found fifteen different pediatric conditions reported to be associated with pathologic or non-pathologic Q waves.

### Conclusion

Our systematic review confirmed that pathologic Q waves are a common and early electrocardiographic finding in children with HCM and may, in fact, be the only ECG finding. In addition, our review provided an extensive list of other pediatric diseases and conditions associated with pathologic or non-pathologic Q waves on the electrocardiogram.

### Keywords

Hypertrophic cardiomyopathy; Q wave; Pathologic Q wave; Sudden cardiac death; Pediatric.

**INTRODUCTION**

Q waves indicate the depolarization of the interventricular septum<sup>1</sup> and in neonates may be a normal finding in the inferior and left lateral leads. They should not, however, be wide or deep. The normal Q wave duration is 0.02 seconds and does not exceed 0.03 seconds<sup>2-5</sup> and voltages vary based on age but should never exceed 0.15 mV in an infant or 0.1 mV in a teenager.<sup>5</sup> Although prominent Q waves are a characteristic finding in myocardial infarction, they can be seen in other disease states and serve as a screening tool for a spectrum of pathology.

There are several possible explanations for the Q waves found in the setting of hypertrophic cardiomyopathy (HCM), but most agree that the Q waves are generated by the increased electrical forces of disproportionate hypertrophy of the basal septum as well as the ventricular free wall found in HCM.<sup>5-7</sup>

Currently, the Seattle criteria<sup>8</sup> are most frequently used to delineate abnormal Q waves (Q waves >3 mm deep and/or >40 ms duration in ≥2 leads except III and a VR), as originally proposed by Charron et al<sup>9</sup> and found to be the most sensitive criteria for abnormal Q waves in pediatric patients.<sup>10</sup>

In this systematic review, we had two research goals. The first was to describe the reported prevalence of pathologic Q waves in the electrocardiograms (ECGs) of pediatric patients with echocardiogram proven HCM. The second goal was to perform an extensive review and report other pediatric conditions that can present with pathologic and non-pathologic Q waves.

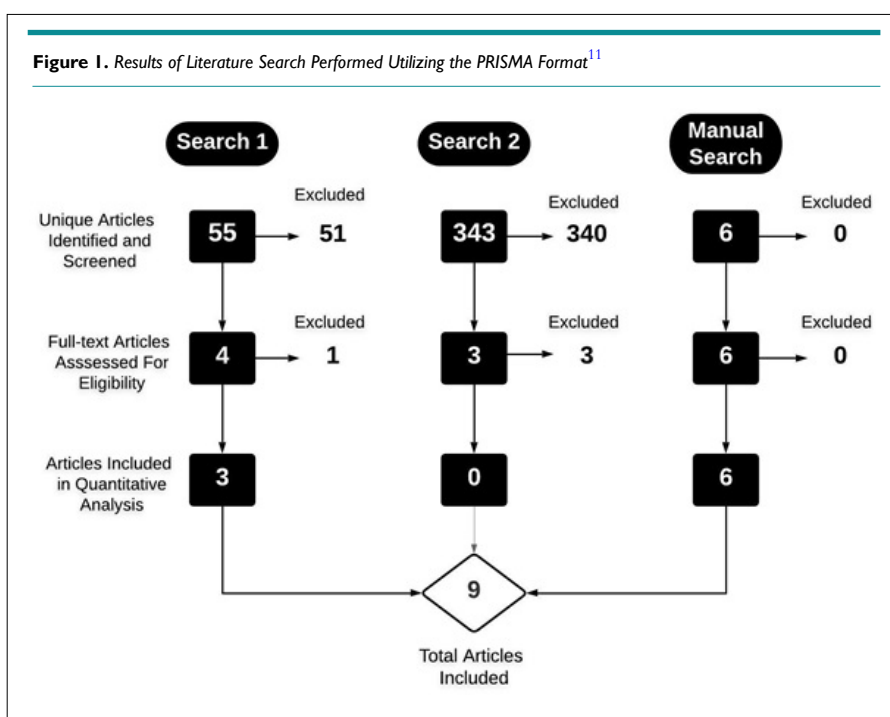
Our paper is unique in that it is the first systematic review of the prevalence of pathologic Q waves in the ECGs of pediatric patients with echocardiogram proven HCM.

**METHODS**

The databases PubMed, Web of Science, Scopus and cumulative index to nursing and allied health literature (CINAHL) were searched utilizing the preferred reporting items for systematic reviews and meta-analyses (PRISMA) format.<sup>11</sup> The publication dates ranged from inception to October 2019. We included retrospective and prospective studies, chart reviews, systemic reviews, and case series. Non-english or opinion articles were excluded. The Rayyan Systemic Review Software was used to screen articles for final inclusion in the review. Two search strategies were employed. The initial search (Search 1) consisted of the following terms: “dagger Q wave”, “dagger-like Q waves”, “dagger shape Q waves”, “deep Q wave”, “narrow Q wave” or “Q wave elevation” and “hypertrophic cardiomyopathy”. After reviewing those articles, a broader search (Search 2) was conducted to determine if viable articles were omitted in the first search. This broader search strategy included the same terms as Search 1 but eliminated the term “HCM” (Figure 1). The authors then performed an exhaustive manual review of the articles gleaned from these two searches to find other references that met the two research goals.

**RESULTS**

Search one yielded 55 articles, all of which were screened by the authors. Of these, only 4 were found eligible for full-text assessment by both reviewers.<sup>10,12-14</sup> Search Two yielded 343 articles, all of which were screened by the authors. Of these, only 3 were found eligible for full-text assessment by both reviewers.<sup>15-17</sup> A manual search of the literature was also performed by two of the authors. This yielded six additional articles that discussed pathologic Q wave abnormalities. Of all the articles found in the three searches, a total of nine articles ultimately specifically addressed the prevalence of pathological Q waves in pediatric



Reference	Pathological Q Waves	Criteria
Charron et al <sup>9</sup>	2/16 (12.5%)	Q waves >3 mm or duration > 0.04 second, and present in > 2 leads. Q waves present only in VI and V2 or only in lead III were not considered as abnormal.
Konno et al <sup>10</sup>	7/15 (46.6%) Visual estimate from chart	Q wave >3 mm in depth and/or >0.04 s in duration in at least two leads except aVR
Balaji et al <sup>12</sup>	107/446 (23.99%)	Q waves either >25% of the size of the R wave or >3 mm in any of the inferior leads (II, III, and aVF)
Guerrier et al <sup>13</sup>	9/40 (22.5%) Phenotype positive voltage and non-voltage Q wave abnormalities	Q waves >3 mm in depth or >40 ms in two or more leads
Shimizu et al <sup>18</sup>	4/6 (66.7%)	Q wave >0.04 second in duration or >25% of the ensuing R wave in depth in at least 2 leads except aVR.
Thompson et al <sup>19</sup>	31/148 (21%)	Q waves >3 mm deep or 40 ms in duration in ≥2 leads excluding III and aVR
Dipchand et al <sup>20</sup>	16/37 (43%)	The Q wave in lead III was > 95 <sup>th</sup> percentile.
Morimoto et al <sup>21</sup>	18/44 (40.9%) school screening 23/44 (52.3%) last eval	Q waves >3 mm deep and/or >40 ms duration in ≥2 leads except III and aVR
Yetman et al <sup>22</sup>	59/93 (63.4%)	Prominent inferolateral Q-wave
Total	258/845 (30.5%)	

HCM patients (Table 1).<sup>9,10,12,13,18-22</sup> These nine articles described a total of 845 pediatric patients with hypertrophic cardiomyopathy. Of these, 258 (30.5%) demonstrated pathological Q waves on their electrocardiograms. The range of percentages reported for pathological Q waves was 12.5 to 66.7%. The Seattle criteria<sup>8,23</sup> was used to delineate pathological Q waves in seven of 9 articles.

The second aim of our review is to list all pediatric conditions that may be associated with Q waves, both non-pathological and pathological by the Seattle criteria. Q waves can be normal in some age groups. Neonates normally have small Q waves in the inferior (II, III, aVF), and lateral (V5 and V6) leads. Deep Q waves in V5 and V6 can be seen with improperly (too high) placed leads.<sup>24</sup> However, Q waves in other leads can signify disease. Deep Q waves can be found in patients with disorders such as infiltrative myocardial diseases, accessory pathways, arrhythmogenic right ventricular cardiomyopathy, and transmural myocardial infarction.<sup>25</sup> Although the ECGs of athletes frequently meet the criteria for left ventricular hypertrophy, Q waves are relatively uncommon.<sup>26,27</sup> However, Pelliccia et al<sup>28</sup> found that a deep Q wave can be found in about 10% of trained athletes in the

absence of any changes on two-dimensional echocardiogram, suggesting that Q waves can be a non-pathologic consequence of athletic training. Table 2 lists in addition to HCM other pediatric conditions that can present with Q waves on ECG.

## DISCUSSION

The evidence suggests that Q waves >3 mm in depth or 0.40 ms in duration in at least two leads may be the most accurate diagnostic definition for HCM.<sup>10,13</sup> Guerrier et al<sup>13</sup> found that voltage-based ECG criteria were associated with a low sensitivity but a high specificity for HCM; specifically, Q waves >3 mm in depth in two or more leads had a sensitivity of 13% and a specificity of 100%, whereas Q waves >40 ms had a sensitivity of 10% but a specificity of 100%.

The recognition of HCM is critical as it is the single most common cardiac cause of sudden death, especially in young patients. The diagnosis of HCM is often based on the presence of unexplained left ventricular hypertrophy which usually does not develop until late adolescence or adulthood.<sup>29</sup> An abnormal electrocardiogram is often the first evidence of this disease and abnormal Q waves may be one of the earliest ECG findings to suggest HCM.<sup>18,29,30</sup> Therefore, abnormal Q waves can be helpful in finding preclinical carriers of HCM.<sup>10</sup>

Konno et al<sup>10</sup> reported that in the young population, abnormal Q waves, compared to other ECG abnormalities, showed the highest sensitivity (50%) and specificity (90%) for HCM, in contrast to the adult population where abnormal Q waves showed the lowest sensitivity (29%), a high specificity (97%) and the lowest accuracy (52%). Shimizu et al<sup>18</sup> reported in a smaller study that the sensitivity, specificity, positive predictive value, and negative predictive value of abnormal Q waves in teens were 67%, 100%, 100% and 78%, respectively. Abnormal Q waves were frequently observed in leads II, III, aVF, V5, and V6 in teenage patients, whereas they were observed in many leads in patients >20-years

Pediatric Conditions Associated with Q Waves on Electrocardiogram	
Core pulmonale <sup>2</sup>	Athletic heart <sup>8,17,23,28</sup>
Duchene muscular dystrophy <sup>15</sup>	Incorrect lead placement <sup>24</sup>
Myocardial infarction <sup>31</sup>	Anomalous origin left coronary artery (ALCAPA) <sup>32,33</sup>
Hypertrophic cardiomyopathy <sup>34</sup>	Idiopathic dilated cardiomyopathy <sup>34</sup>
Tricuspid atresia <sup>35</sup>	Normal variant <sup>36,37</sup>
Kawasaki disease <sup>37</sup>	Dextrocardia <sup>38</sup>
Myocarditis <sup>39</sup>	Left ventricular aneuysm <sup>40</sup>
Spinal muscular atrophy <sup>41</sup>	

old.<sup>18</sup> Lakdawala et al<sup>29</sup> reported that in overt HCM, 75% had Q waves and/or repolarization changes, but <25% demonstrated common isolated voltage criteria for LVH. In conclusion, Q waves and repolarization abnormalities are the most discriminating ECG features of sarcomere mutation carriers with and without LVH.

## LIMITATIONS

Despite two slightly different systematic reviews of the literature, it is still possible that other relevant articles may have been missed as evidenced by the fact that the majority of the relevant articles were discovered by a careful and detailed manual search.

The papers available, reviewed and selected for the systematic review were overall low to moderate quality.

Minimal heterogeneity of the definition of abnormal Q wave definitions existed, but most articles reported in our review used the Seattle criteria (Q waves >3 mm deep and/or >40 ms duration in ≥2 leads except III and aVR). Five of the articles included in Table 1 were published prior to 2013 when the Seattle criteria were first formalized.<sup>9,10,18,20,22</sup> However, three of the earlier studies did apply the Seattle criteria<sup>9,10,18</sup> The remaining two studies either used Q waves at the 95<sup>th</sup> percentile as their criteria<sup>20</sup> or reported prominent Q waves.<sup>22</sup>

## CONCLUSION

The diagnosis of Hypertrophic Cardiomyopathy requires a high index of suspicion by the emergency physician as it is a potentially fatal condition. However, there are relatively few articles that specifically address the diagnostic importance of Q waves in the pediatric population with hypertrophic cardiomyopathy. Our systematic review confirms that pathologic Q waves are a common and early electrocardiographic finding in children with HCM. In fact, pathologic Q waves may initially be the only ECG findings. Consequently, the importance of this ECG finding cannot be over emphasized in the early diagnosis of this condition.

Finally, while it is essential to be familiar with the ECG criteria for HCM, it is also important to note that Q waves in pediatric electrocardiograms have other potential etiologies as evidenced by our secondary search. Many of these etiologies are pathologic and require a detailed history, complete physical examination, and additional diagnostic testing.

## FUNDING

The authors have no financial interest concerning the material in this work.

## CONFLICT OF INTEREST

The authors declare that they have no conflicts of interest.

## REFERENCES

1. Goldberger AL. *Goldberger's Clinical Electrocardiography: A Simplified Approach*. 9<sup>th</sup> ed. Philadelphia, PA, USA: Elsevier Health Sciences; 2017.

2. Andrag L, Decker R. Pattern recognition in paediatric ECGs: The hidden secrets to clinical diagnosis. Web site. <http://www.cmej.org.za/index.php/cmej/article/view/2283/2048>. Accessed June 3, 2021.

3. Bruen C. Ahead of Print: Demystifying the Pediatric ECG: Emergency Medicine News. Web site. <https://journals.lww.com/em-news/blog/spontaneouscirculation/pages/post.aspx?PostID=24>. Accessed June 3, 2021.

4. Gros G, Gordon A, Miller R. Electrocardiographic Patterns of normal children from birth to five years of age. *Pediatrics*. 1951; 8(3): 349-361.

5. Park MK. *Park's Pediatric Cardiology for Practitioners*. 6<sup>th</sup> ed. Philadelphia, PA, USA: Elsevier Saunders; 2014.

6. Koga Y, Yamaga A, Hiyamuta K, Ikeda H, Toshima H. Mechanisms of abnormal Q waves in hypertrophic cardiomyopathy assessed by intracoronary electrocardiography. *J Cardiovasc Electrophysiol*. 2004; 15(12): 1402-1408. doi: 10.1046/j.1540-8167.2004.04314.x

7. Fronza M, Raineri C, Valentini A, et al. Relationship between electrocardiographic findings and cardiac magnetic resonance phenotypes in patients with hypertrophic Ccardiomyopathy. *Int J Cardiol Heart Vasc*. 2016; 11: 7-11. doi: 10.1016/j.ijcha.2016.02.001

8. Drezner JA, Ackerman MJ, Anderson J, et al. Electrocardiographic interpretation in athletes: The 'Seattle Criteria'. *Br J Sports Med*. 2013; 47: 122-124. doi: 10.1136/bjsports-2012-092067

9. Charron P, Dubourg O, Desnos M, et al. Diagnostic value of electrocardiography and echocardiography for familial hypertrophic cardiomyopathy in genotyped children. *Eur Heart J*. 1998; 19(9): 1377-1382. doi: 10.1053/ehj.1998.1049

10. Konno T, Shimizu M, Ino H, et al. Diagnostic value of abnormal Q waves for identification of preclinical carriers of hypertrophic cardiomyopathy based on a molecular genetic diagnosis. *Eur Heart J*. 2004; 25(3): 246-251. doi: 10.1016/j.ehj.2003.10.031

11. Liberati A, Altman DG, Tetzlaff, J, et al. The PRISMA statement for reporting systematic reviews and meta-analyses of studies that evaluate healthcare interventions: Explanation and elaboration. *BMJ*. 2009; 339: b2700. doi: 10.1136/bmj.b2700

12. Balaji S, DiLorenzo MP, Fish FA, et al. Risk factors for lethal arrhythmic events in children and adolescents with hypertrophic cardiomyopathy and an implantable defibrillator: An international multicenter study. *Heart Rhythm*. 2019; 16(10): 1462-1467. doi: 10.1016/j.hrthm.2019.04.040

13. Guerrier K, Anderson JB, Pratt J, et al. Correlation of precordial voltages to left ventricular mass on echocardiogram in ado-



- lescent patients with hypertrophic cardiomyopathy compared with that in adolescent athletes. *Am J Cardiol.* 2015; 115(7): 956-961. doi: [10.1016/j.amjcard.2015.01.025](https://doi.org/10.1016/j.amjcard.2015.01.025)
14. Calò L, Sperandii F, Martino A, et al. Echocardiographic findings in 2261 peri-pubertal athletes with or without inverted T waves at electrocardiogram. *Heart.* 2014; 101(3): 193-200. doi: [10.1136/heartjnl-2014-306110](https://doi.org/10.1136/heartjnl-2014-306110)
15. Takami Y, Takeshima Y, Awano, H, Okizuka Y, Yagi M, Matsuo M. High incidence of electrocardiogram abnormalities in young patients with duchenne muscular dystrophy. *Pediatr Neurol.* 2008; 39(6): 399-403. doi: [10.1016/j.pediatrneurol.2008.08.006](https://doi.org/10.1016/j.pediatrneurol.2008.08.006)
16. Ip JH, Lotvin A, Schweitzer P. Abnormal Q waves in a young asymptomatic patient. *Cardiovascular Reviews and Reports.* 1992; 13(6): 66-68.
17. Sapire DW. Sudden cardiac death in adolescents. *Tex Med.* 1985; 81(6): 55-59.
18. Shimizu M, Ino H, Yamaguchi M, et al. Chronologic electrocardiographic changes in patients with hypertrophic cardiomyopathy associated with cardiac troponin 1 mutation. *Am Heart J.* 2002; 143(2): 289-293. doi: [10.1067/mhj.2002.119760](https://doi.org/10.1067/mhj.2002.119760)
19. Thompson AJ, Cannon BC, Wackel PL, et al. Electrocardiographic abnormalities in elite high school athletes: Comparison to adolescent hypertrophic cardiomyopathy. *Br J Sports Med.* 2016; 50(2): 105-110. doi: [10.1136/bjsports-2015-094880](https://doi.org/10.1136/bjsports-2015-094880)
20. Dipchand AI, McCrindle BW, Gow RM, Freedom RM, Hamilton RM. Accuracy of surface electrocardiograms for differentiating children with hypertrophic cardiomyopathy from normal children. *Am J Cardiol.* 1999; 83(4): 628-30, A10. doi: [10.1016/s0002-9149\(98\)00933-3](https://doi.org/10.1016/s0002-9149(98)00933-3)
21. Morimoto Y, Miyazaki A, Tsuda E, Hayama Y, Negishi J, Ohuchi H. Electrocardiographic changes and long-term prognosis of children diagnosed with hypertrophic cardiomyopathy by the school screening program for heart disease in Japan. *J Cardiol.* 2020; 75(5): 571-577. doi: [10.1016/j.jcc.2019.10.008](https://doi.org/10.1016/j.jcc.2019.10.008)
22. Yetman AT, Hamilton RM, Benson LN, McCrindle BW. Long-term outcome and prognostic determinants in children with hypertrophic cardiomyopathy. *J Am Coll Cardiol.* 1998; 32: 1943-1950. doi: [10.1016/s0735-1097\(98\)00493-8](https://doi.org/10.1016/s0735-1097(98)00493-8)
23. Brosnan M, La Gerche A, Kalman J, et al. The seattle criteria increase the specificity of preparticipation ECG screening among elite athletes. *Br J Sports Med.* 2014; 48(15): 1144-1150. doi: [10.1136/bjsports-2013-092420](https://doi.org/10.1136/bjsports-2013-092420)
24. Ilg KJ, Lehmann MH. Importance of recognizing pseudo-septal infarction due to electrocardiographic lead misplacement. *Am J Med.* 2012; 125(1): 23-27. doi: [10.1016/j.amjmed.2011.04.023](https://doi.org/10.1016/j.amjmed.2011.04.023)
25. Banerjee A. Cardiovascular Emergencies. In: *Emergency Clinical Diagnosis.* New York, USA: Springer, Cham; 2017. doi: [10.1007/978-3-319-50718-7\\_1](https://doi.org/10.1007/978-3-319-50718-7_1)
26. Bent RE, Wheeler MT, Hadley D, Froelicher V, Ashley E, Perez MV. Computerized Q wave dimensions in athletes and hypertrophic cardiomyopathy patients. *J Electrocardiol.* 2015; 48(3): 362-367. doi: [10.1016/j.jelectrocard.2015.01.009](https://doi.org/10.1016/j.jelectrocard.2015.01.009)
27. Sharma S, Whyte G, Elliott P, Kaushal R, Mahon N, McKenna WJ. Electrocardiographic changes in 1000 highly trained junior elite athletes. *Br J Sports Med.* 1999; 33(5): 319-324. doi: [10.1136/bjism.33.5.319](https://doi.org/10.1136/bjism.33.5.319)
28. Pelliccia A, Di Paolo FM, Maron BJ. The athlete's heart: remodeling, electrocardiogram and preparticipation screening. *Cardiol Rev.* 2002; 10(2): 85-90. doi: [10.1097/00045415-200203000-00006](https://doi.org/10.1097/00045415-200203000-00006)
29. Lakdawala NK, Thune JJ, Maron BJ, et al. Electrocardiographic features of sarcomere mutation carriers with and without clinically overt hypertrophic cardiomyopathy. *Am J Cardiol.* 2011; 108: 1606-1613. doi: [10.1016/j.amjcard.2011.07.019](https://doi.org/10.1016/j.amjcard.2011.07.019)
30. Maron BJ. Q waves in hypertrophic cardiomyopathy: A reassessment. *J Am Coll Cardiol.* 1990; 16(2): 375-376. doi: [10.1016/0735-1097\(90\)90588-g](https://doi.org/10.1016/0735-1097(90)90588-g)
31. Akagawa D, Motoki N, Hachiya A, Akazawa Y. Transient Q-waves in an infant with asymptomatic myocardial infarction due to Kawasaki disease. *Cardiol Young.* 2019; 29(2): 231-234. doi: [10.1017/S1047951118001919](https://doi.org/10.1017/S1047951118001919)
32. Ma F, Zhou K, Shi X, et al. Misdiagnosed anomalous left coronary artery from the pulmonary artery as endocardial fibroelastosis in infancy: A case series. *Medicine (Baltimore).* 2017; 96(24): e7199. doi: [10.1097/MD.00000000000007199](https://doi.org/10.1097/MD.00000000000007199)
33. Hoffman JI. Electrocardiogram of anomalous left coronary artery from the pulmonary artery in infants. *Pediatr Cardiol.* 2013; 34(3): 489-491. doi: [10.1007/s00246-012-0599-7](https://doi.org/10.1007/s00246-012-0599-7)
34. Pelto H, Owens D, Drezner J. Electrocardiographic findings suggestive of cardiomyopathy: What to look for and what to do next. *Curr Sports Med Rep.* 2013; 12(2): 77-85. doi: [10.1249/JSR.0b013e3182874abb](https://doi.org/10.1249/JSR.0b013e3182874abb)
35. Davachi F, Lucas RV Jr, Moller JH. The electrocardiogram and vectorcardiogram in tricuspid atresia. Correlation with pathologic anatomy. *Am J Cardiol.* 1970; 25(1): 18-27. doi: [10.1016/0002-9149\(70\)90810-6](https://doi.org/10.1016/0002-9149(70)90810-6)
36. Goodacre S, McLeod K. ABC of clinical electrocardiography: Paediatric electrocardiography. *BMJ.* 2002; 324(7350): 1382-1385. doi: [10.1136/bmj.324.7350.1382](https://doi.org/10.1136/bmj.324.7350.1382)
37. Cortez D, Patel SS, Sharma N, Landeck BF, McCanta AC, Jone P-N. Repolarization vector magnitude differentiates Kawasaki

- Disease from normal children. *Ann Noninvasive Electrocardiol.* 2016; 21(5): 493-499. doi: [10.1111/anec.12338](https://doi.org/10.1111/anec.12338)
38. Arcilla RA, Gasul BM. Congenital dextrocardia. Clinical, angiographic, and autopsy studies on 50 patients. *J Pediatr.* 1961; 58: 251-262. doi: [10.1016/s0022-3476\(61\)80059-0](https://doi.org/10.1016/s0022-3476(61)80059-0)
39. Wisotzkey BL, Soriano BD, Albers EL, Ferguson M, Buddhe S. Diagnostic role of strain imaging in atypical myocarditis by echocardiography and cardiac MRI. *Pediatr Radiol.* 2018; 48(6): 835-842. doi: [10.1007/s00247-017-4061-0](https://doi.org/10.1007/s00247-017-4061-0)
40. Ozyilmaz I, Saygi M, Yildiz O, Ereğ E, Guzeltas A. Surgical repair of true left ventricular aneurysm in an infant: A rare complication after unsuccessful periventricular VSD closure. *World J Pediatr Congenit Heart Surg.* 2014; 5(4): 637-639. doi: [10.1177/2150135114541860](https://doi.org/10.1177/2150135114541860)
41. Wijngaarde CA, Blank AC, Stam M, Wadman RI, van den Berg LH, van der Pol WL. Cardiac pathology in spinal muscular atrophy: a systematic review. *Orphanet J Rare Dis.* 2017; 12: 67. doi: [10.1186/s13023-017-0613-5](https://doi.org/10.1186/s13023-017-0613-5)