

Editorial

*Corresponding author

Zhonghua Sun, PhD

Professor

Department of Medical Radiation
Sciences

School of Science

Curtin University

GPO Box, U1987, Perth

WA 6845, Australia

Tel. +61-8-9266 7509

Fax: +61-8-9266 2377

E-mail: z.sun@curtin.edu.au

Volume 2 : Issue 5

Article Ref. #: 1000HROJ2e005

Article History

Received: November 20th, 2015

Accepted: November 20th, 2015

Published: November 20th, 2015

Citation

Sun Z. The PLATFORM trial: an insight into the improved value of using FFR_{CT} for reduction of invasive angiographic procedures. *Heart Res Open J.* 2015; 2(5): e13-e17. doi: [10.17140/HROJ-2-e005](https://doi.org/10.17140/HROJ-2-e005)

Copyright

©2015 Sun Z. This is an open access article distributed under the Creative Commons Attribution 4.0 International License (CC BY 4.0), which permits unrestricted use, distribution, and reproduction in any medium, provided the original work is properly cited.

The PLATFORM Trial: An Insight into the Improved Value of Using FFR_{CT} for Reduction of Invasive Angiographic Procedures

Zhonghua Sun*

Department of Medical Radiation Sciences, Curtin University, GPO Box U1987 Perth, WA 6845, Australia

Coronary CT Angiography (CCTA) has been widely used as a reliable non-invasive modality for the diagnosis of Coronary Artery Disease (CAD) due to its improved spatial and temporal resolution.¹⁻⁵ For patients with low to intermediate pre-test probability of CAD, CCTA is used as an effective gatekeeper for determination of downstream testing, such as invasive coronary angiography or functional imaging.⁶ However, CCTA is mainly an anatomic test with excellent visualization of coronary anatomical structures and detection of coronary lumen stenosis, while providing little functional information of the coronary lesions. Despite high sensitivity and negative predictive value, CCTA has been reported to have moderate specificity and positive predictive value due to the high percentage of false positive rates, and this is especially apparent in the assessment of coronary arteries with heavy calcification. Studies have shown the limited diagnostic value of CCTA in diagnosing highly calcified coronary plaques.⁷⁻¹¹ Thus, an imaging technique able to detect ischemia-producing lesions is of paramount importance since coronary stenosis does not always translate to functional significance. Clinical decision making of whether patients should proceed to a revascularization procedure is based on the predictive functional effect of coronary stenosis, because no prognostic benefit of revascularization has been reported in the coronary lesions without functional significance.^{12,13}

In recent years, a great interest has been shown in the investigation of diagnostic performance of non-invasive Fractional Flow Reserve derived from coronary CT angiography (FFR_{CT}). The scientific basis for non-invasive quantification of FFR_{CT} has been well described in the literature.¹⁴ FFR_{CT} is computed by performing computational fluid dynamics modelling after image segmentation of coronary arteries and ascending aorta. The invasive FFR technique is conducted by using a pressure catheter to assess the rate of maximal myocardial blood flow through a coronary stenotic lesion in relation to the flow through the normal aorta in a hyperemic state.¹⁵⁻¹⁷ The FFR is a lesion-specific technique and is widely used as the reference test for assessment of the functional significance of a coronary stenosis. According to the Fractional Flow reserve *versus* angiography for multivessel evaluation (FAME) trials, FFR-guided percutaneous coronary intervention has been shown to result in lower rate of major adverse cardiac events when compared to visual estimation from invasive coronary angiography or best available medical therapy alone.^{18,19} However, invasive FFR is rarely performed in clinical practice, thus, a non-invasive method combining both anatomic and functional data to determine the hemodynamic significance of coronary lesions could serve as an alternative to invasive FFR for improvement of patient care and clinical outcomes.

In the PLATFORM prospective multicentre trial, Douglas, et al. compared the clinical outcomes of symptomatic patients with an intermediate likelihood of obstructive CAD, who were assigned to undergo either the planned usual care testing or CCTA/FFR_{CT} testing.²⁰ A total of 584 patients were recruited from 11 clinical sites with 287 receiving usual testing and 297 receiving CCTA/FFR_{CT} testing. The 90-day follow-up visits were reported in this study to

determine the cardiac event rates. The authors reported that non-obstructive CAD was found at Invasive Coronary Angiography (ICA) in 73% of the patients in the usual care group with intended ICA. In contrast, non-obstructive CAD was found at ICA in 12% of the patients in the CCTA/FFR_{CT} group, which is significantly lower than that observed in the usual care group ($p < 0.0001$) (Figure 1). Among those with planned non-invasive testing, no significant difference was found in the rates of non-obstructive CAD at ICA between the two groups (6.0 usual care vs. 12.5% CCTA/FFR_{CT}, $p = 0.95$) (Figure 1). There were no significant differences in cardiac events between these two groups. The authors concluded that use of CCTA/FFR_{CT} can be more effectively triage patients than the use care approach for invasive procedures since ICA was cancelled in 61% patients based on the results of CCTA/FFR_{CT}.

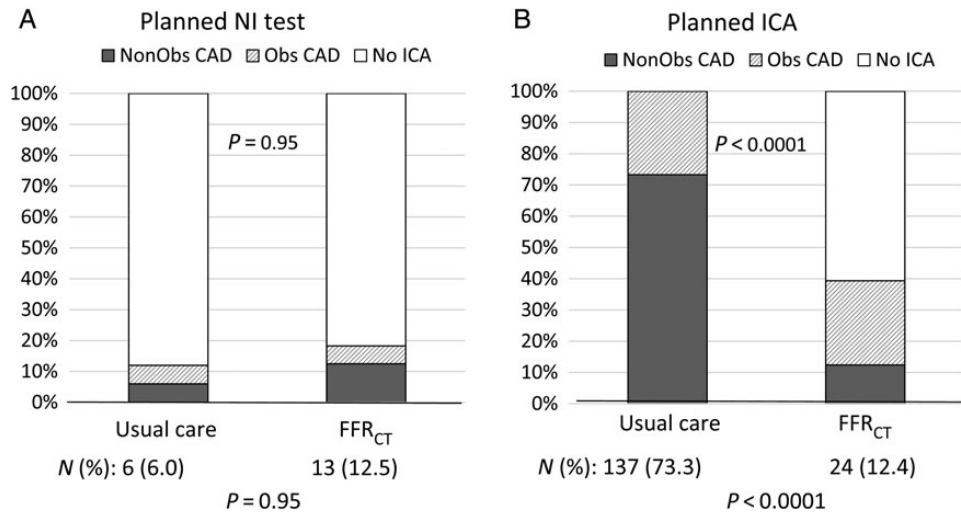


Figure 1: Determination of the rate of invasive catheterization without obstructive coronary artery disease. NI: Non-invasive; ICA: Invasive Coronary Angiography; Obs CAD: Obstructive Coronary Artery Disease; FFR_{CT}: Computation of fractional flow reserve from coronary computed tomographic angiography data.²⁰

There are 2 observations from Douglas’s study that bear discussion. First, improved diagnostic strategy has been achieved in patient managements based on analysis of CCTA/FFR_{CT} with a significantly low rate of ICA showing non-obstructive CAD. This further verifies the advantage of FFR_{CT} over CCTA in the diagnostic assessment of coronary stenosis. According to a recently published randomized controlled PROMISE trial, coronary CTA was found to increase the rate of invasive catheterization by 50% compared with functional testing.²¹ Clinical value of FFR_{CT} in comparison with CCTA has been reported in three multicenter trials, Diagnosis of Ischemia-Causing Coronary Stenoses by Non-invasive FFR Computed from Coronary Computed Tomographic Angiograms (DISCOVER-FLOW), Determination of Fractional Flow Reserve by Anatomic Computed Tomographic Angiography (DeFACTO), and NeXtSteps (NXT) trials.²²⁻²⁴ Findings of these trials confirm that FFR_{CT} is superior to CCTA for the diagnosis of ischemia-causing lesions on both per-patient and per-vessel analysis as determined by an invasive FFR the reference standard. Table 1 shows the diagnostic value of FFR_{CT} versus CCTA in stable patients with suspected CAD based on the analysis of these three trials.

Diagnostic value CCTA/FFR _{CT}	DISCOVER-FLOW ²²		NXT ²⁴		DeFACTO ²³
	Per-patient assessment	Per-vessel assessment	Per-patient assessment	Per-vessel assessment	Per-patient assessment
CCTA ≥ 50%					
Sensitivity	94	91	94	83	84
Specificity	25	40	34	60	42
PPV	58	47	40	33	61
NPV	80	89	92	92	72
FFR _{CT} ≤ 0.80					
Sensitivity	93	88	86	84	90
Specificity	82	82	79	86	54
PPV	85	74	65	61	67
NPV	91	92	93	95	84

PPV: Positive Predictive Value, NPV: Negative Predictive Value.

Table 1: Three multicenter trials comparing FFR_{CT} with CCTA with invasive FFR as the gold standard.

Second, ICA examination is associated with high rate of non-obstructive CAD as shown in Figure 1. Although physicians' angiographic interpretation of coronary stenosis has been reported to have substantial disagreement from quantitative coronary angiographic images,^{25,26} the visual readings in Douglas's study were low (57%) as the findings of determining non-obstructive CAD in ICA patients were determined by quantitative coronary angiography. This further highlights the limitation of ICA as an anatomic test or a luminogram. The role of ICA is gradually diminishing as compared to other imaging modalities such as CCTA or intravascular ultrasound,^{27,28} which are able to look beyond the lumen and characterize plaque morphology or vessel wall, thus, enabling detection of vulnerable coronary plaques responsible for development of adverse cardiac events. ICA remains the gold standard for the detection of coronary stenosis, however, according to the PROSPECT, the largest prospective study to investigate the natural history of CAD,²⁹ the majority of non-culprit lesions responsible for acute coronary syndrome at a median follow-up of 3.4 years were mild lesions with diameter stenosis of 32% at baseline angiographic examination. Therefore, combining anatomic with functional imaging modalities represents a future direction for determination of functional significance of coronary lesions.

In summary, the PLATFORM trial adds additional value to other two recently published randomized controlled trials involving diagnostic performance of CCTA in CAD, the PROMISE and SCOT-HEART trials.^{21,30} Like all large multicenter trials, PLATFORM has limitations. It is not a randomized controlled trial. Further, the sample size and short follow-up period (90 days) make it difficult to detect the impact on clinical outcomes. Further studies with inclusion of a large cohort at longer follow-up periods are warranted.

REFERENCES

1. Sun Z, Cao Y, Li HF. Multislice computed tomography angiography in the diagnosis of coronary artery disease. *J Geriatr Cardiol*. 2011; 8: 104-113. doi: [10.3724/SP.J.1263.2011.00104](https://doi.org/10.3724/SP.J.1263.2011.00104)
2. Sun Z. Cardiac CT imaging in coronary artery disease: current status and future directions. *Quant Imaging Med Surg*. 2012; 2: 98-105. doi: [10.3978/j.issn.2223-4292.2012.05.02](https://doi.org/10.3978/j.issn.2223-4292.2012.05.02)
3. Sun Z, Choo GH, Ng KH. Coronary CT angiography: current status and continuing challenges. *Br J Radiol*. 2012; 85: 495-510. doi: [10.1259/bjr/15296170](https://doi.org/10.1259/bjr/15296170)
4. Pelliccia F, Pasceri V, Evangelista A, et al. Diagnostic accuracy of 320-row computed tomography as compared with invasive coronary angiography in unselected, consecutive patients with suspected coronary artery disease. *Int J Cardiovasc Imaging*. 2013; 29: 443-452. doi: [10.1007/s10554-012-0095-4](https://doi.org/10.1007/s10554-012-0095-4)
5. Sun Z, Lin C. Diagnostic value of 320-slice coronary CT angiography in coronary artery disease: a systematic review and meta-analysis. *Curr Med Imaging Rev*. 2014; 10: 272-280. doi: [10.2174/157340561004150121140836](https://doi.org/10.2174/157340561004150121140836)
6. Sun Z, Abdul Aziz Y, Ng KH. Coronary CT angiography: how should physicians use it wisely and when do physicians request it appropriately? *Eur J Radiol*. 2012; 81: e684-e687. doi: [10.1016/j.ejrad.2011.06.040](https://doi.org/10.1016/j.ejrad.2011.06.040)
7. Sun Z, Xu L, Fan Z. Coronary CT angiography in calcified coronary plaques: comparison of diagnostic accuracy between bifurcation angle measurement and coronary lumen assessment for diagnostic significant coronary stenosis. *Int J Cardiol*. 2016; 203: 78-86. doi: [10.1016/j.ijcard.2015.10.079](https://doi.org/10.1016/j.ijcard.2015.10.079)
8. Xu L, Sun Z. Coronary CT angiography evaluation of calcified coronary plaques by measurement of left coronary bifurcation angle. *Int J Cardiol*. 2015; 182: 229-231. doi: [10.1016/j.ijcard.2014.12.114](https://doi.org/10.1016/j.ijcard.2014.12.114)
9. Chen CC, Chen CC, Hsieh IC, et al. The effect of calcium score on the diagnostic accuracy of coronary computed tomography angiography. *Int J Cardiovasc Imaging*. 2011; 27 (Suppl 1): 37-42. doi: [10.1007/s10554-011-9955-6](https://doi.org/10.1007/s10554-011-9955-6)
10. Palumbo A, Maffei E, Martini C, et al. Coronary calcium score as gatekeeper for 64-slice computed tomography coronary angiography in patients with chest pain: per-segment and per-patient analysis. *Eur Radiol*. 2009; 19: 2127-2135. doi: [10.1007/s00330-009-1398-2](https://doi.org/10.1007/s00330-009-1398-2)
11. Park MJ, Jung JI, Choi YS, et al. Coronary CT angiography in patients with high calcium score: evaluation of plaque characteristics and diagnostic accuracy. *Int J Cardiovasc Imaging*. 2011; 27: 43-51. doi: [10.1007/s10554-011-9970-7](https://doi.org/10.1007/s10554-011-9970-7)

12. Pijls NH, van Schaardenburgh P, Manoharan G, et al. Percutaneous coronary intervention of functionally nonsignificant stenosis: 5-year follow-up of the DEFER study. *J Am Coll Cardiol.* 2007; 49: 2105-2111. doi: [10.1016/j.jacc.2007.01.087](https://doi.org/10.1016/j.jacc.2007.01.087)
13. Tonino PA, De Bruyne B, Pijls NH, et al. Fractional flow reserve versus angiography for guiding percutaneous coronary intervention. *N Engl J Med.* 2009; 360: 213-224. doi: [10.1056/NEJMoa0807611](https://doi.org/10.1056/NEJMoa0807611)
14. Taylor CA, Fonte TA, Min JK. Computational fluid dynamics applied to cardiac computed tomography for noninvasive quantification of fractional flow reserve: scientific basis. *J Am Coll Cardiol.* 2013; 61: 2233-2241. doi: [10.1016/j.jacc.2012.11.083](https://doi.org/10.1016/j.jacc.2012.11.083)
15. De Bruyne B, Baudhuin T, Melin JA, et al. Coronary flow reserve calculated from pressure measurements in humans. Validation with positron emission tomography. *Circulation.* 1994; 89: 1013-1022. doi: [10.1161/01.CIR.89.3.1013](https://doi.org/10.1161/01.CIR.89.3.1013)
16. Berger A, Botman KJ, MacCarthy PA, et al. Long-term clinical outcome after fractional flow reserve-guided percutaneous coronary intervention in patients with multivessel disease. *J Am Coll Cardiol.* 2005; 46: 438-442. doi: [10.1016/j.jacc.2005.04.041](https://doi.org/10.1016/j.jacc.2005.04.041)
17. Pijls NH, van Son JA, Kirkeeide RL, De Bruyne B, Gould KL. Experimental basis of determining maximum coronary, myocardial, and collateral blood flow by pressure measurements for assessing functional stenosis severity before and after percutaneous transluminal coronary angioplasty. *Circulation.* 1993; 87: 1354-1367. doi: [10.1161/01.CIR.87.4.1354](https://doi.org/10.1161/01.CIR.87.4.1354)
18. Fearon WF, Bornschein B, Tonino PA, et al. Fractional flow reserve versus angiography for multivessel evaluation (FAME) study investigators. Economic evaluation of fractional flow reserve-guided percutaneous coronary intervention in patients with multivessel disease. *Circulation.* 2010; 122: 2545-2550. doi: [10.1136/heartjnl-2014-306578](https://doi.org/10.1136/heartjnl-2014-306578)
19. De Bruyne B, Pijls NH, Kalesan B, et al. FAME 2 Trial Investigators. Fractional flow reserve-guided PCI versus medical therapy in stable coronary disease. *N Engl J Med.* 2012; 367: 991-1001. doi: [10.1056/NEJMoa1205361](https://doi.org/10.1056/NEJMoa1205361)
20. Douglas PS, Pontone G, Hlatky MA, et al. Clinical outcomes of fractional flow reserve by computed tomographic angiography-guided diagnostic strategies vs. usual care in patients with suspected coronary artery disease: the prospective longitudinal trial of FFR_{CT}: outcome and resource impacts study. *Eur Heart J.* 2015. doi: [10.1093/eurheartj/ehv444](https://doi.org/10.1093/eurheartj/ehv444)
21. Douglas PS, Hoffmann U, Patel MR, et al. PROMISE Investigators. Outcomes of anatomical versus functional testing for coronary artery disease. *N Engl J Med.* 2015; 372: 1291-1300. doi: [10.1056/NEJMoa1415516](https://doi.org/10.1056/NEJMoa1415516)
22. Koo BK, Erglis A, Doh JH, et al. Diagnosis of ischemia-causing coronary stenoses by noninvasive fractional flow reserve computed from coronary computed tomographic angiograms. Results from the prospective multicenter discover-flow (diagnosis of ischemia-causing stenoses obtained via noninvasive fractional flow reserve) study. *J Am Coll Cardiol.* 2011; 58: 1989-1997. doi: [10.1016/j.jacc.2011.06.066](https://doi.org/10.1016/j.jacc.2011.06.066)
23. Min JK, Leipsic J, Pencina MJ, et al. Diagnostic accuracy of fractional flow reserve from anatomic CT angiography. *JAMA.* 2012; 308: 1237-1245. doi: [10.1001/2012.jama.11274](https://doi.org/10.1001/2012.jama.11274)
24. Norgaard BL, Leipsic J, Gaur S, et al. Diagnostic performance of non-invasive fractional flow reserve derived from coronary CT angiography in suspected coronary artery disease: the NXT trial. *J Am Coll Cardiol.* 2014; 63: 1145-1155. doi: [10.1016/j.jacc.2013.11.043](https://doi.org/10.1016/j.jacc.2013.11.043)
25. Nallamothu BK, Spertus JA, Lansky AJ, et al. Comparison of clinical interpretation with visual assessment and quantitative coronary angiography in patients undergoing percutaneous coronary intervention in contemporary practice: the assessing angiography (A2) project. *Circulation.* 2013; 127: 1793-1800. doi: [10.1161/CIRCULATIONAHA.113.001952](https://doi.org/10.1161/CIRCULATIONAHA.113.001952)
26. Patel MR, Peterson ED, Dai D, et al. Low diagnostic yield of elective coronary angiography. *N Engl J Med.* 2010; 362: 886-895. doi: [10.1056/NEJMoa0907272](https://doi.org/10.1056/NEJMoa0907272)
27. Chan KH, Ng MKC. Is there a role for coronary angiography in the early detection of the vulnerable plaque? *Int J Cardiol.* 2013; 164: 262-266. doi: [10.1016/j.ijcard.2012.01.027](https://doi.org/10.1016/j.ijcard.2012.01.027)

28. Colombo A, Panoulas VF. Diagnostic coronary angiography is getting old. *JACC Cardiovasc Imaging*. 2015; 8: 11-13. doi: [10.1016/j.jcmg.2014.11.003](https://doi.org/10.1016/j.jcmg.2014.11.003)
29. Stone G, Maehara A, Lansky A, et al. A prospective natural-history study of coronary atherosclerosis. *N Engl J Med*. 2011; 364: 226-235. doi: [10.1056/NEJMoa1002358](https://doi.org/10.1056/NEJMoa1002358)
30. Newby DE on behalf of the SCOT-HEART Investigators. CT coronary angiography in patients with suspected angina due to coronary heart disease (SCOT-HEART): an open-label, parallel-group, multicentre trial. *Lancet*. 2015; 385: 2383-2391. doi: [10.1016/S0140-6736\(15\)60291-4](https://doi.org/10.1016/S0140-6736(15)60291-4)