

Case Report

Corresponding author

Raúl González-García, MD, PhD, FEBOMFS
Consultant Surgeon
Department of Oral and Maxillofacial Surgery
University Hospital Infanta Cristina
Calle Los Yébenes 35, 8C
28047, Madrid, Spain
E-mail: raulmaxilo@gmail.com

Volume 3 : Issue 1

Article Ref. #: 1000SROJ3117

Article History

Received: July 20th, 2016

Accepted: August 17th, 2016

Published: August 17th, 2016

Citation

Villanueva-Alcojol L, Laza LR, González FG, González-García R, Monje F. Single-step primary reconstruction after complex fronto-orbital brown tumor resection using computed-designed peek implant. *Surg Res Open J.* 2016; 3(1): 13-19. doi: [10.17140/SROJ-3-117](https://doi.org/10.17140/SROJ-3-117)

Copyright

©2016 González-García R. This is an open access article distributed under the Creative Commons Attribution 4.0 International License (CC BY 4.0), which permits unrestricted use, distribution, and reproduction in any medium, provided the original work is properly cited.

Single-Step Primary Reconstruction After Complex Fronto-Orbital Brown Tumor Resection Using Computed-Designed Peek Implant

Laura Villanueva-Alcojol, MD, PhD¹; Luis Ruiz Laza, MD¹; Fernando González González, MD²; Raúl González-García, MD, PhD, FEBOMFS¹; Florencio Monje, MD, PhD¹

¹Department of Oral and Maxillofacial Surgery, University Hospital Infanta Cristina, Badajoz, Spain

²Department of Ophthalmology, University Hospital Infanta Cristina, Badajoz, Spain

ABSTRACT

The authors describe a patient with secondary hyperparathyroidism (HPT) who had development of a brown tumors (BTs) of the superior orbit and frontal calvarium with subsequent visual impairment. One-step surgery involving wide en-bloc resection of the entire tumor and immediate fronto-orbital reconstruction with a custom-made polyetheretherketone (PEEK) implant was planned. Using a PEEK implant a one-step reconstruction of the fronto-orbital region was achieved obtaining symmetry and good functional results, reducing operative time and avoiding donor site morbidity.

KEYWORDS: Oral squamous cell carcinoma; Management; Human papilloma virus; Sentinel node biopsy; Tissue shrinkage; Radiotherapy; Neck dissection; Salvage surgery; Prognosis, QoL; Iberic graft; Facial transplantation.

INTRODUCTION

Brown tumors are uncommon bony lesions caused by rapid osteoclastic activity and peritrabecular fibrosis. They are known to occur only in the setting of HPT, as a direct result of the effect of parathyroid hormone on bone tissue. For years, these lesions have been recognized in primary HPT. However, brown tumors have also been reported in patients with severe HPT secondary to chronic renal failure, especially those on long-term hemodialysis.¹

The ribs, clavicles, pelvic girdle, spine, tibia, humerus and mandible are their preferred location. While the mandible is the most frequently involved bone in the head and neck region,²⁻⁸ fronto-orbital involvement is extremely rare, with only a few cases in the literature.⁹⁻¹⁷ Moreover, reconstruction of this region is complex and remains a challenge for maxillofacial surgeon.

We describe a patient with secondary HPT who had development of a brown tumor of the superior orbit and frontal calvarium with subsequent visual impairment. One-step surgery involving wide en-bloc resection of the entire tumor and immediate fronto-orbital reconstruction with a custom-made PEEK implant was planned.

CASE REPORT

A 27-year-old white woman with medical history significant for chronic renal failure on hemodialysis presented with painful progressive proptosis, downward displacement and limited upgaze of her left globe, and a palpable fronto-temporal mass beneath the left frontal scalp. The swelling was firm and painless to the touch (Figure 1).

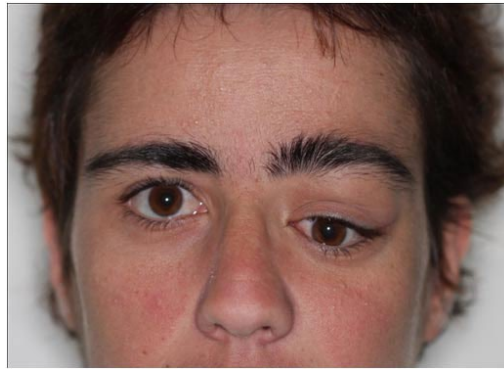

Figure 1: Pre-operative clinical photograph of patient.

On ophthalmic examination, visual acuity was 20/50 OD and 10/200 OI. Intraocular pressure was 14/16 mmHg. Left blepharoptosis and edema, proptosis of the globe, and an associated enlarging subcutaneous mass of the left frontal scalp were noted. Left hypotropia and restriction of left upgaze were present. The left macula demonstrated horizontal choroidal folds mainly in the superotemporal region. The left optic disc was pale with sharp margins more evident nasally. Pre-retinal haemorrhages secondary to compression were also evident.

Computed tomography (CT) revealed a heterogeneous mass of left frontal area with erosion of inner and outer table of the skull and roof of the orbit. The lesion extended into the superior orbit, causing depression of globe. No brain edema was present. Magnetic resonance imaging (MRI) showed a large heterogeneously enhancing extra-axial mass centered at the left frontal calvarium and roof of the left orbit. The mass showed areas of internal hemorrhage (Figure 2). CT and MRI also

demonstrated the presence of 2 more asymptomatic tumors with similar characteristics in maxilla and mandible.

The initial treatment involved the correction of hyperparathyroidism, which usually leads to tumor regression. The patient underwent a total parathyroidectomy identified in the usual location by scintigraphy, with auto-transplantation of parathyroid tissue. However, the orbital lesion progressively increased in size and there was not regression in the proptosis of the right eye, as confirmed by a CT performed 6 months after parathyroidectomy. We did not observe changes in maxilla and mandible lesions and they remained asymptomatic.

The resection of the fronto-orbital mass was planned with virtual pre-operative surgery that allowed manufacturing of a specific implant to accurately fit to the defect during the one stage surgery (Figure 3).

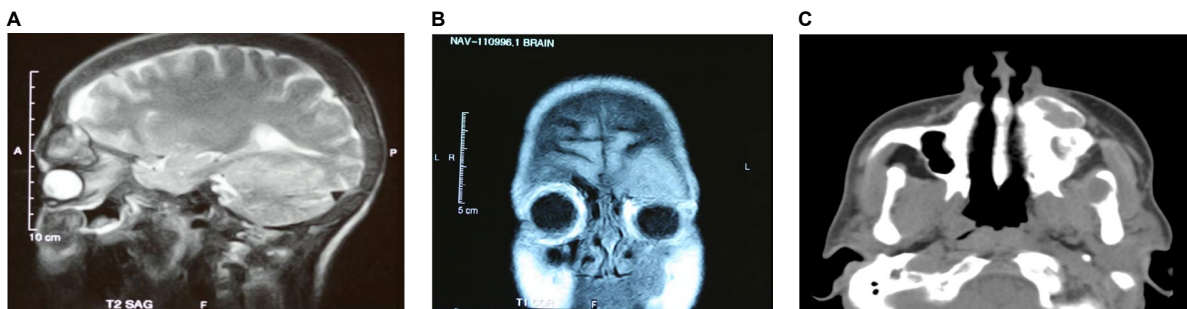

Figure 2: Sagittal (A) and coronal (B) MRI that shows a heterogeneous mass of the left frontal calvarium with erosion of inner and outer table of the skull and (C) roof of the orbit.

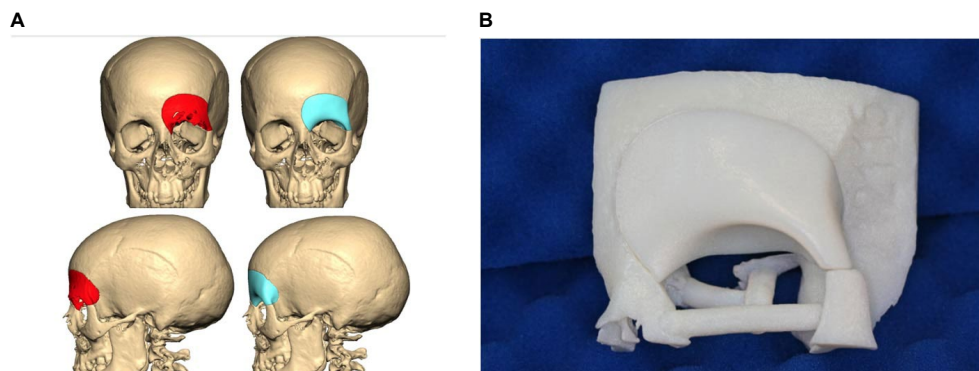


Figure 3: Planning of the resection (A) and implant design (B) sent by the manufacturer for approval.

A pre-operative high-resolution 3-D CT scan was first obtained from axial images. The images (DICOM format) were sent by CD to the manufacturer. An accurate delineation of the lesion was performed on the software, and based in our measurements, a PEEK prosthesis was manufactured. Implant models were sent to the surgeon for review, mark up and/or approval. The resulting implant had an accuracy to within 0.5 mm.

Surgery was performed *via* a coronal approach. A crano-orbitotomy allowed to completely excise the large, necrotic, heterogeneous mass. As planned, we performed primary reconstruction of the fronto-orbital defect with a custom-made

PEEK prosthesis, that was fixed with titanium plates and screws (Figures 4 and 5).

Histopathologic examination demonstrated groups of osteoclast type multinucleated giant cells in a well vascularized, cellular fibrous stroma. There was hemorrhage and cluster of hemosiderin laden macrophages. Reactive woven bone, which displayed osteoblastic activity, was seen in some áreas (Figure 6). Based on the thorough diagnostic work-up including medical history, clinical manifestations, radiographic findings and consecutive routine laboratory findings, the patient was diagnosed as having hyperparathyroidism with brown tumors of facial bones as a result of long-standing renal disease.

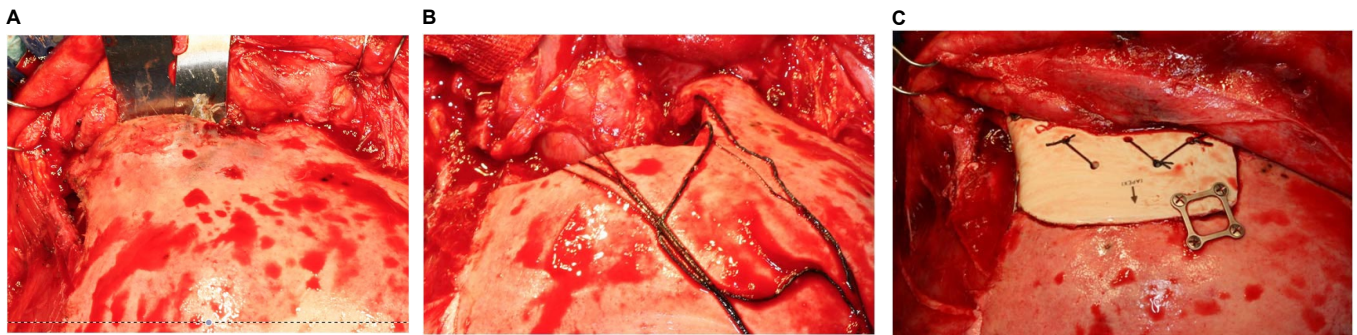


Figure 4: Intraoperative view showing the brown tumor (A), resection (B) and PEEK patient specific implant (PSI) perfectly fitting the bony defect (4C).

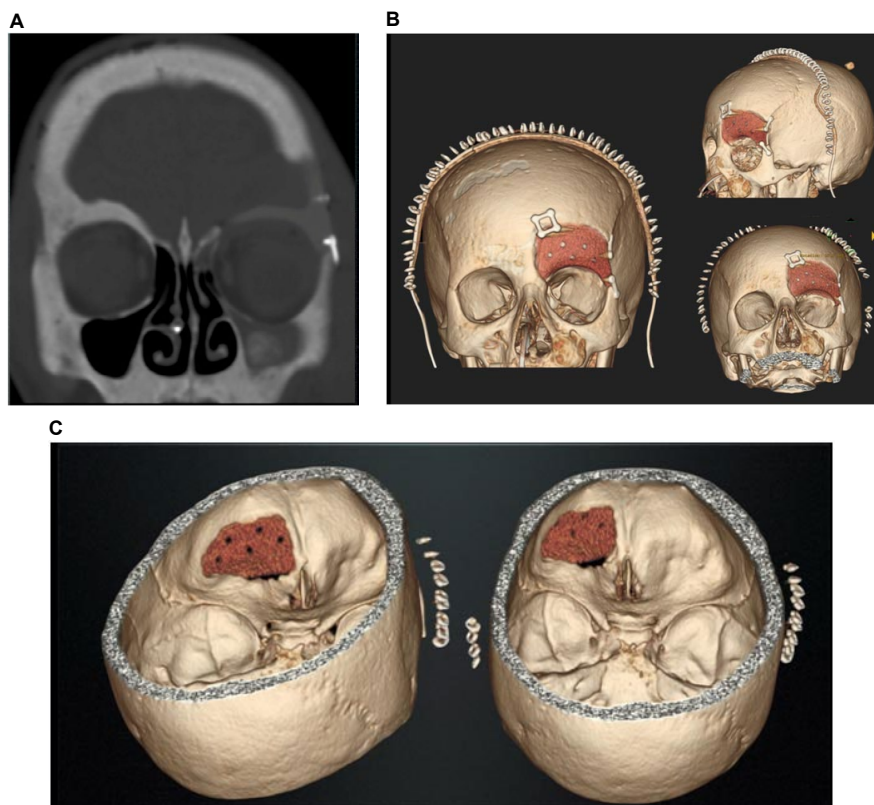


Figure 5: Immediate post-operative CT scan (A) and tridimensional reconstruction of the prosthesis (B and C).

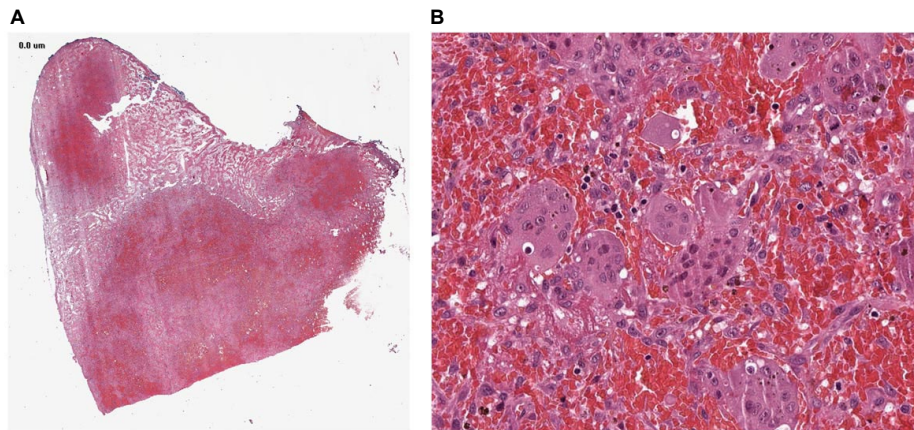


Figure 6: Histopathologic examination revealed a tumor composed of a uniform distribution of multinucleated giant cells in a background of oval to short-spindled stromal cells. These findings were consistent with a giant cell tumor and, in the setting of secondary HPT, the diagnosis of Brown tumor was made. (Figure 6A: H&E x1, Figure 6B: H&E x200)

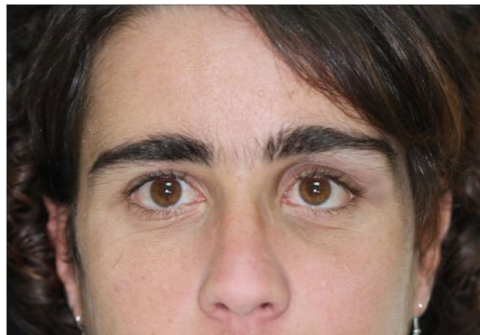

Figure 7: Post-operative image, 2 years after surgery, with good cosmetic and functional results.

Two years later, there was no recurrence of the brown tumor, exophthalmos correction and orbital contour symmetry (Figure 7).

DISCUSSION

Brown tumor or osteoclastomas are histologically benign focal lytic bone tumors caused by primary or secondary hyperparathyroidism.¹⁸ They are called brown tumors due to the high hemosiderin level of localized accumulation of osteoclasts, vascularity and hemorrhage, that gives characteristic brown color.¹⁹

These tumors arise secondary to both primary and secondary hyperparathyroidism. They have been reported to occur in 4,5% of patients with primary hyperparathyroidism and 1,5 to 1,7% of those with secondary disease.²⁰ Secondary HPT is an adaptive response to chronic kidney disease (CKD) as a result of a disruption in serum phosphorus, calcium, and vitamin D homeostasis. Chronic renal disease with secondary retention of phosphates leads to hyperphosphatemia. Deficient 1,25 (OH) vitamin D₃ related with renal failure and the resulting hypocalcemia induces to secondary hyperparathyroidism.²¹⁻²³ The increase of secretion of parathyroid hormone stimulates the osteoclastic activity with cortical thinning, subperiosteal resorption, bone cysts, and rarely, brown tumors. These

tumors represent a reparative cellular process rather than a true neoplasia.²¹

The reported prevalence of brown tumor is 0.1%.²⁴ They usually affect young people, particularly females. The ribs, clavicle, pelvic girdle, hand, and mandible are their preferred location. The most important complications of this neoformation are related to its position and size and the possible effects on nearby structures.²² Only few cases have been reported in the fronto-orbital region.⁹⁻¹⁷ When the orbit is affected, the presenting symptoms include a palpable mass, pain, proptosis, diplopia, impaired extrinsic ocular motility or decreased visual acuity.

Diagnosis of BTs depends on clinical, biochemical, radiological, and pathological factors.²⁵ These tumors do not have specific imaging characteristics; sarcomas as well as giant cell reparative granulomas, langerhans cell histiocytosis, aneurysmal bone cysts, metastases, multiple myeloma and non-ossifying fibromas are the other lesions that should be kept in mind as the differential diagnosis.²⁵⁻²⁷

Histologically there is no difference between a brown tumor and a central giant cell granuloma. They contain a mixed population of multinuclear giant cells, mononuclear cells, and osteoblasts. There is high nuclear activity without nuclear

atypia. Extravasated red blood cells (RBC), areas of hemorrhage and hemosiderin-loaded macrophages usually appear.²⁸

The treatment is initially based on the correction of hyperparathyroidism, which usually leads to tumor regression. Surgical excision of the diseased parathyroid gland to control parathyroid hormone (PTH) is the first choice of treatment for a brown tumor because the normalization of parathyroid function and should lead to a reduction in size or disappearance of the tumor.²⁹

However, persistent disease is defined and accepted by the authors as the reappearance of typical symptoms, laboratory abnormalities and radiological signs.³⁰ Surgical resection is indicated in cases of encroachment on neural structures, and when the mass continues for more than 6 months or even grows despite adequate metabolic control.^{10,20} In this case, the patient returned with an enlargement of the fronto-orbital lesion 6 months after parathyroidectomy.

Bony lesions in the fronto-orbital region often require extensive bone resections. Reconstructive cranioplasty of such defects remains a challenge for craniofacial surgeons and neurosurgeons. The anatomical complexity of this area requires restoration of the forehead and orbital walls with perfect symmetry to provide good functional and aesthetic results.

Several techniques for fronto-orbital reconstruction in this setting have been described. Autologous bone graft is the standard technique for craniofacial reconstruction in many settings. Donor site morbidity and increased operative time must be the considerations in this approach, and the rigidity of this material may increase the technical challenges of creating a conformational reconstruction of the bony orbital skeleton.³¹ Due in part to these limitations, some surgeons have advocated orbital reconstruction with the use of preoperative conformation of biomaterials.³²

In our case, a 3D CT-scan reconstruction and virtual surgery allowed planning of the appropriate resection, and helped design the implant. Consequently, an optimal custom-made implant could be used immediately following the surgical resection. We choose to use PEEK biomaterial for this type of craniofacial reconstruction because of numerous advantages: excellent mechanical and chemical properties, biocompatibility and radiographic translucency.³³ Moreover, thin parts can be manufactured on the implant to reconstruct orbital walls for example, and PEEK can be drilled for rigid plate fixation to the maxillofacial skeleton. These implants have the advantage of being preoperatively tailored to the exact size of the cranial defect, thus allowing a shortening of the operative time as well as the amount of the intraoperative modifications, hence guaranteeing post-operative stability and incomparable cosmetic results.³⁴ In our case, PEEK implant allowed one-step reconstruction of the fronto-orbital region achieving symmetry and functional results, reducing operative time and avoiding donor site morbidity.

CONFLICTS OF INTEREST

The authors declare that they have no conflicts of interest.

CONSENT

The patient has provided written permission for publication of the case details.

REFERENCES

1. Triantallidou K, Zouloumis L, Karakinaris G, et al. Brown tumours of the jaws associated with primary or secondary hyperparathyroidism. A clinical study and review of literature. *Am J Otolaryngol*. 2006; 27(4): 281-286. doi: [10.1016/j.amjoto.2005.11.004](https://doi.org/10.1016/j.amjoto.2005.11.004)
2. Lessa MM, Sakae FA, Tsuji RK, et al. Brown tumor of the facial bones: Case report and literature review. *Ear Nose Throat J*. 2005; 84: 432. Web site: <http://www.entjournal.com/sites/entjournal.com/files/archive/www.entjournal.com/Media/PublicationsArticle/LESSA-07-05.pdf>. Accessed July 19, 2016
3. Martinez-Gavidia EM, Bagan JV, Millan-Masanet MA, et al. Highly aggressive brown tumour of the maxilla as first manifestation of primary hyperparathyroidism. *Int J Oral Maxillofac Surg*. 2000; 29: 447-449. doi: [10.1016/S0901-5027\(00\)80079-X](https://doi.org/10.1016/S0901-5027(00)80079-X)
4. Kar DK, Gupta SK, Agarwal A, et al. Brown tumor of the palate and mandible in association with primary hyperparathyroidism. *J Oral Maxillofac Surg*. 2001; 59: 1352-1354. doi: [10.1053/joms.2001.27533](https://doi.org/10.1053/joms.2001.27533)
5. Yamazaki H, Ota Y, Aoki T, et al. Brown tumor of the maxilla and mandible: Progressive mandibular brown tumor after removal of parathyroid adenoma. *J Oral Maxillofac Surg*. 2003; 61: 719-722. doi: [10.1053/joms.2003.50142](https://doi.org/10.1053/joms.2003.50142)
6. Corbetta S, Rossi D, D'Orto O, et al. Brown jaw tumor: Today's unusual presentation of primary hyperparathyroidism. *J Endocrinol Invest*. 2003; 26: 675. doi: [10.1007/BF03347028](https://doi.org/10.1007/BF03347028)
7. Daniel JS. Primary hyperparathyroidism presenting as a palatal brown tumor. *Oral Surg Oral Med Oral Pathol Oral Radiol Endod*. 2004; 98(4): 409-413. doi: [10.1016/j.tripleo.2004.01.015](https://doi.org/10.1016/j.tripleo.2004.01.015)
8. Suarez-Cunqueiro MM, Schoen R, Kersten A, Klish J, Schmelzeisen R. Brown tumor of the mandible as first manifestation of atypical parathyroid adenoma. *J Oral Maxillofac Surg*. 2004; 62: 1024-1028. doi: [10.1016/j.joms.2004.02.011](https://doi.org/10.1016/j.joms.2004.02.011)
9. Park K, Mannor GE, Wolfley DE. Preoperative embolization of an orbital brown tumor. *Am J Ophthalmol*. 1994; 117(5): 679-680. doi: [10.1016/S0002-9394\(14\)70086-8](https://doi.org/10.1016/S0002-9394(14)70086-8)

10. Gonzalez-Martínez E, Santamarta-Gómez D, Varela-Rois P, et al. Brown tumor of the orbital roof as an initial and isolated manifestation of secondary hyperparathyroidism. *Orbit*. 2010; 29(5): 278-280. doi: [10.3109/01676830.2010.501947](https://doi.org/10.3109/01676830.2010.501947)
11. Levine MR, Chu A, Abdul-Karim FW. Brown tumor and secondary hyperparathyroidism. *Arch Ophthalmol*. 1991; 109(6): 847-849. doi: [10.1001/archophth.1991.01080060111036](https://doi.org/10.1001/archophth.1991.01080060111036)
12. Parrish CM, O'Day DM. Brown tumor of the orbit: Case report and review of the literature. *Arch Ophthalmol*. 1986; 104(8): 1199-1202. doi: [10.1001/archophth.1986.01050200105061](https://doi.org/10.1001/archophth.1986.01050200105061)
13. Zwick OM, Vagefi MR, Cockerham KP, et al. Brown tumor of secondary hyperparathyroidism involving the superior orbit and frontal calvarium. *Ophthal Plast Reconstr Surg*. 2006; 22(4): 304. doi: [10.1097/01.iop.0000225744.19613.3d](https://doi.org/10.1097/01.iop.0000225744.19613.3d)
14. Naiman J, Green WR, d'Heurle D, et al. Brown tumor of the orbit associated with primary hyperparathyroidism. *Am J Ophthalmol*. 1980; 90(4): 565-571. Web site: <http://europepmc.org/abstract/med/7424756>. Accessed July 19, 2016
15. Holzer NJ, Croft CB, Walsh JB, et al. Brown tumor of the orbit. *JAMA*. 1977; 238(16): 1758-1759. doi: [10.1001/jama.1977.03280170052029](https://doi.org/10.1001/jama.1977.03280170052029)
16. Zwick OM, Vagefi MR, Cockerham KP, et al. Brown tumor of secondary hyperparathyroidism involving the superior orbit and frontal calvarium. *Ophthal Plast Reconstr Surg*. 2006; 22(4): 304-306. doi: [10.1097/01.iop.0000225744.19613.3d](https://doi.org/10.1097/01.iop.0000225744.19613.3d)
17. Ribeiro Monteiro ML. Multiple brown tumors of the orbital walls: Case report. *Arq Bras Oftalmol*. 2009; 72 (1): 116-118. doi: [10.1590/S0004-27492009000100025](https://doi.org/10.1590/S0004-27492009000100025)
18. Vandenbussche E, Schmider L, Mutschler C, Man M, Jacquot C, Augereau B. Brown tumor of the spine and progressive paraplegia in a hemodialysis patient. *Spine*. 2004; 29(12): E251-E255. doi: [10.1097/01.BRS.0000127187.58944.FA](https://doi.org/10.1097/01.BRS.0000127187.58944.FA)
19. Noman Zaheer S, Byrne ST, Poonnoose SI, Vrodo NJ. Brown tumour of the spine in a renal transplant patient. *J Clin Neurosci*. 2009; 16(9): 1230-1232. doi: [10.1016/j.jocn.2008.11.009](https://doi.org/10.1016/j.jocn.2008.11.009)
20. Kanaan I, Ahmed M, Rifai A, Alwatban J. Sphenoid sinus Brown tumor of secondary hyperparathyroidism: Case report. *Neurosurgery*. 1998; 42(6): 1374-1377. Web site: <http://journals.lww.com/neurosurgery/pages/articleviewer.aspx?year=1998&issue=06000&article=00113&type=abstract>. Accessed July 19, 2016
21. Duran C, Ersoy C, Bolva N. Brown tumors of the maxillary sinus and patella in a patient with primary hyperparathyroidism. *Endocrinologist*. 2005; 15(6): 351-354. doi: [10.1097/01.ten.0000188456.73682.a8](https://doi.org/10.1097/01.ten.0000188456.73682.a8)
22. Di Daniele N, Condò S, Ferrannini M, et al. Brown tumour in a patient with secondary hyperparathyroidism resistant to medical therapy: Case report on successful treatment after subtotal parathyroidectomy. *Int J Endocrinol*. 2009; 2009: 827652. doi: [10.1155/2009/827652](https://doi.org/10.1155/2009/827652)
23. Monteiro ML. Multiple brown tumors of the orbital walls: Case report. *Arq Bras Oftalmol*. 2009; 72(1): 116-118. doi: [10.1590/S0004-27492009000100025](https://doi.org/10.1590/S0004-27492009000100025)
24. Keyser JS, Postma GN. Brown tumor of the mandible. *AM J Otolaryngol*. 1996; 17(6): 407-410. doi: [10.1016/S0196-0709\(96\)90075-7](https://doi.org/10.1016/S0196-0709(96)90075-7)
25. Grégoire C, Soussan M, Dumuis ML, et al. Contribution of multimodality imaging for positive and aetiological diagnosis of multiple brown tumours. *Ann Endocrinol*. 2012; 73(1): 43-50. doi: [10.1016/j.ando.2011.10.002](https://doi.org/10.1016/j.ando.2011.10.002)
26. Pavlovic S, Valyi-Nagy T, Proftirovic J, David O. Fine-needle aspiration of brown tumor of bone: Cytologic features with radiologic and histologic correlation. *Diagn Cytopathol*. 2009; 37(2): 136-139. doi: [10.1002/dc.20974](https://doi.org/10.1002/dc.20974)
27. Mateo L, Massuet A, Solà M, et al. Brown tumor of the cervical spine: A case report and review of the literature. *Clin Rheumatol*. 2011; 30(3): 419-424. doi: [10.1007/s10067-010-1608-y](https://doi.org/10.1007/s10067-010-1608-y)
28. de Ávila ED, de Molon RS, Cabrini Gabrielli MA, et al. Unusually rapid growth of brown tumour in the mandible after parathyroidectomy associated with the presence of a super numerary parathyroid gland. *J Cranio-Maxillo-Fac Surg*. 2012; 40: 19.
29. Pinto LP, Cherubini K, Salum FG, Yurgel LS, de Figueiredo MA. Highly aggressive brown tumour in the jaw associated with tertiary hyperparathyroidism. *Pediatr Dent*. 2006; 28(6): 543-546. Web site: <http://www.ingentaconnect.com/content/aapd/pd/2006/00000028/00000006/art00011?token=004e155756b705c5f3b3b474673487734447b516e755f6c4f582a2f4876753375686f49dd61efc>. Accessed July 19, 2016
30. Hindié E, Fregonara PZ, Just PA, et al. Parathyroid scintigraphy findings in chronic kidney disease patients with recurrent hyperparathyroidism. *Eur J Nucl Med Mol Imaging*. 2010; 37(3): 623. doi: [10.1007/s00259-009-1313-8](https://doi.org/10.1007/s00259-009-1313-8)
31. Chambless LB, Mawn LA, Forbes JA, et al. Porous polyethylene implant reconstruction of the orbit after resection of sphenoid-orbital meningiomas: A novel technique. *J CranioMaxilloFac Surg*. 2012; 40(1): e28-e32. doi: [10.1016/j.jcms.2011.01.016](https://doi.org/10.1016/j.jcms.2011.01.016)
32. Jalbert F, Lauwers F. Reconstruction de la voûte crânienne. *Ch Plast Rec*. 2009; 57.

33. Nieminen T, Kallela I, Wuolijoki E, Kainulainen H, Hiidenheimo I, Rantala I. Amorphous and crystalline polyetheretherketone: Mechanical properties and tissue reactions during a 3-year follow-up. *J Biomed Mater Res.* 2008; 84(2): 377-383. doi: [10.1002/jbm.a.31310](https://doi.org/10.1002/jbm.a.31310)

34. Scolozzi P, Martinez A, Jaques B. Complex orbito-fronto-temporal reconstruction using computer-designed PEEK implant. *J Craniofac Surg.* 2007; 18(1): 224-228. doi: [10.1097/01.scs.0000249359.56417.7e](https://doi.org/10.1097/01.scs.0000249359.56417.7e)