

## Case Report

### Corresponding author

Shreyas Saligram, MD, MRCP

Department of Gastrointestinal Oncology

Moffitt Cancer Center

12902 Magnolia Drive

Tampa, FL 33612, USA

E-mail: [drsaligram@yahoo.com](mailto:drsaligram@yahoo.com)

Volume 2 : Issue 1

Article Ref. #: 1000GOJ2123

### Article History

Received: June 24<sup>th</sup>, 2016

Accepted: August 3<sup>rd</sup>, 2016

Published: August 4<sup>th</sup>, 2016

### Citation

Saligram S. Salvage cryotherapy for treatment of persistent Barrett's esophagus. *Gastro Open J.* 2016; 2(1): 1-3. doi: [10.17140/GOJ-2-123](https://doi.org/10.17140/GOJ-2-123)

### Copyright

©2016 Saligram S. This is an open access article distributed under the Creative Commons Attribution 4.0 International License (CC BY 4.0), which permits unrestricted use, distribution, and reproduction in any medium, provided the original work is properly cited.

# Salvage Cryotherapy for Treatment of Persistent Barrett's Esophagus

Shreyas Saligram, MD, MRCP\*

Department of Gastrointestinal Oncology, Moffitt Cancer Center, 12902 Magnolia Drive, Tampa, FL 33612, USA

### ABSTRACT

**Background:** A dysplastic Barrett's esophagus can lead to cancer if not treated by endoscopic eradication therapy. The current consensus is to eradicate the entire residual Barrett's esophagus that is visible during endoscopy by ablation therapy. However, a section of patients are resistant to this ablation therapy. They may need a second line of ablation therapy to eradicate the visible residual Barrett's esophagus.

**Aims:** To evaluate the efficacy of treatment with salvage cryotherapy of persistent Barrett's esophagus who failed to respond for ablation by radio frequency ablation.

**Methods:** Barrett's esophagus with high-grade dysplasia was initially treated with radiofrequency ablation (RFA) for at least 6 sessions to achieve complete eradication of Barrett's esophagus. Barrett's esophagus patients who failed to respond to the radiofrequency ablation was then treated with a different ablation therapy modality like a cryotherapy to achieve complete eradication of Barrett's esophagus.

**Results:** Two patients with Barrett's esophagus and high-grade dysplasia were included in the case series. The Barrett's esophagus in both the patients was treated with a mean of 6.5 sessions of radiofrequency ablation. Both the patients had persistent Barrett's esophagus despite the treatment with radiofrequency ablation as demonstrated by surveillance endoscopic biopsies. They were then treated with a mean of 4.5 sessions of cryotherapy as a salvage therapy. Surveillance endoscopy showed persistent Barrett's esophagus in both the patients despite being treated with cryotherapy. None of the patients had high-grade dysplasia in the surveillance endoscopy.

**Conclusion:** Salvage cryotherapy is futile in persistent Barrett's esophagus that had prior treatment failure with a different ablation therapy.

**KEYWORDS:** Cryotherapy; Radiofrequency ablation; Barrett's esophagus.

### INTRODUCTION

Barrett's esophagus can predispose to esophageal adenocarcinoma after undergoing a histological transformation from non-dysplastic Barrett's esophagus to dysplastic Barrett's esophagus and subsequently into esophageal adenocarcinoma.<sup>1</sup> The annual incidence of esophageal adenocarcinoma arising from Barrett's esophagus is 0.12%-0.5%.<sup>2</sup>

The practice guidelines recommend eradication of the entire Barrett's esophagus with intra-mucosal adenocarcinoma, high-grade dysplasia and certain selective cases of low-grade dysplastic Barrett's esophagus. This is to prevent esophageal adenocarcinoma arising from Barrett's esophagus.<sup>3</sup> This is accomplished by endoscopic eradication therapy, which consists of initial endoscopic mucosal resection of all visible nodules in the Barrett's esophagus and subsequent eradication of residual Barrett's esophagus to achieve complete eradication of intestinal metaplasia (CE-IM). A CE-IM is defined as absence of endoscopic and histological evidence of intestinal metaplasia after treatment with ablation therapy. The risk of metachronous cancer is high if residual Barrett's esophagus is not completely eradicated.<sup>4</sup>

There are different therapies that are adopted for ablation of residual Barrett's esophagus.

gus like radio frequency ablation (RFA), cryotherapy, complete endoscopic mucosal resection, photodynamic therapy (PDT), argon plasma coagulation (APC) and multipolar electrocoagulation (MPEC). There are no randomized control trials between cryotherapy and RFA to treat Barrett's esophagus. The choice of ablative therapy to treat Barrett's esophagus depends on the preference of the endoscopist. However, RFA is being used predominantly due to its ease and low rate of post procedure complications.<sup>5-7</sup> A recent meta-analysis on 3802 patients showed efficacy of RFA in achieving CE-IM was 78% with a mean follow-up of 20.5 months and majority of these patients required 2-3 RFA sessions to achieve CE-IM.<sup>8</sup> Therefore, there is still 22% of the patients who will need a different ablation modality to achieve CE-IM in view of risk of metachronous cancer.

Cryotherapy is an option to use as salvage ablation therapy in patients who have failed to achieve CE-IM despite being treated with RFA. Two patients were treated with salvage cryotherapy and I would like to outline the experience of the outcomes of such a treatment.

#### Case 1

A 75-year-old male was initially diagnosed with a 10 cm Barrett's esophagus and a multifocal nodular high-grade dysplasia. His Prague score measured C10M10. He had no evidence of hiatus hernia. He underwent mucosal resection of the nodules in the Barrett's esophagus and his entire Barrett's esophagus was treated with RFA every 2 months for 1 year (Figure 1A). He was treated with 6 sessions of RFA in total over the course of 1 year. His surveillance endoscopy showed no evidence of nodules but there was persistent residual Barrett's esophagus of 8 cm. His Prague score was C7M8. He was considered to be having a persistent intestinal metaplasia due to failed RFA. His Barrett's esophagus was then treated with a liquid nitrogen cryotherapy every 2 months for 8 months (Figure 1B). He has been treated 4 times in total over the course of 8 months. His surveillance

endoscopy showed a persistent Barrett's esophagus of 8 cm. His surveillance biopsies showed persistent intestinal metaplasia but there was no evidence of high-grade dysplasia or cancer.

#### Case 2

A 60-year-old male was evaluated for persistent symptoms of gastro-esophageal reflux. His endoscopy revealed a 12 cm nodular Barrett's esophagus. His Prague score was C11M12. He had a 5 cm hiatus hernia. His nodule was resected by EMR and the histology showed high-grade dysplasia. His residual Barrett's esophagus was treated with RFA every 2 months for 14 months. He had a total of 7 sessions of RFA. His surveillance endoscopy showed a persistent Barrett's esophagus of 9 cm. His Prague score in surveillance endoscopy was C8M9. There was no evidence of nodules. It was decided that his RFA treatment had failed and he had a persistent Barrett's esophagus. He was referred for surgery in view of his 5 cm hiatus hernia. However, he was deemed to be a poor surgical candidate in view of his other medical co-morbidities and was not considered for surgery. He was then treated with a liquid nitrogen cryotherapy every 2 months for 10 months for a total of 5 treatments. His surveillance endoscopy showed a persistent Barrett's esophagus of 9 cm and his Prague score was C8M9. His surveillance biopsies from the Barrett's esophagus did not show any evidence of high-grade dysplasia or cancer but showed persistent intestinal metaplasia.

#### DISCUSSION

Cryotherapy uses the principle of mucosal necrosis caused by ischemia and subsequent apoptosis leading to cell death.<sup>9</sup> It is a non-contact method of ablating Barrett's esophagus by spraying liquid nitrogen. Initially a orogastric tube is inserted into the stomach through the mouth and is connected to a continuous suction, to suction all the gas that is produced by conversion of liquid nitrogen. The gastroscopie is then inserted alongside the

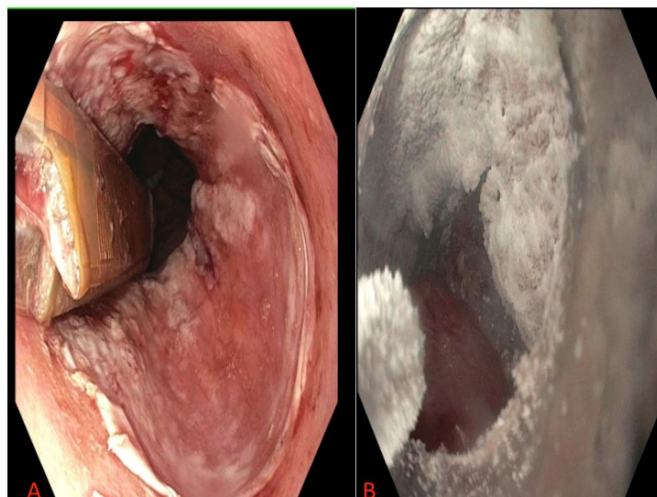


Figure 1: (A) Post-RFA treatment. (B) Post-cryotherapy treatment.

orogastric tube and is placed just proximal to Barrett's esophagus. A spray cryotherapy catheter is passed through the gastro-scope. The spray cryotherapy catheter is used to spray the liquid nitrogen onto the Barrett's esophagus. The lesion is frozen for 20 seconds at 196 °C and subsequently thawed for 60 seconds to ablate the Barrett's esophagus. This is done until the entire Barrett's esophagus is treated. This maneuver is then repeated 3 times for that session.

Cryotherapy has been predominantly used to treat residual Barrett's with no other prior ablative therapy.<sup>10</sup> A long-term follow-up of 2 years on 32 patients treated with cryotherapy reported a CE-IM in 84% and chronic eradication for dysplasia in 100% of the patients.<sup>10</sup> There has been one published literature of treating persistent Barrett's esophagus with a failed RFA. Sixteen patients with failed RFA were included in the study. Treatment with cryotherapy resulted in CE-IM in 31% and chronic eradication for dysplasia in 75% of the patients.<sup>11</sup> Three (19%) of these patients developed stricture, which responded to dilation.<sup>11</sup> Fortunately, there were no adverse events in our patient case series.

The above two cases highlights some of the challenges that are encountered during the ablation of Barrett's esophagus. Cryotherapy is a good ablation therapy based on available evidence.<sup>8</sup> However, it may not be a solution to salvage a prior failed ablation therapy of Barrett's esophagus. It is possible that the pathology of certain Barrett's esophagus is such that they do not respond to any ablation therapy, if they have already failed with one kind of ablation therapy. Failure of one ablation therapy predicted failure of second ablation therapy in the above set of patients. Reassuringly, none of our patients had recurrence of high-grade dysplasia or cancer. Therefore, continuous surveillance of persistent Barrett's esophagus is important to identify and treat metachronous cancers. This case series adds to the limited literature that is available. Further, larger multicenter studies with salvage cryotherapy is required to know if it is truly a futile option in the case of a prior failed ablation therapy. Also, longer follow-up is required to know the course of natural history of persistent Barrett's esophagus that has failed ablation therapy.

## REFERENCES

- Schlemper RJ, Riddell RH, Kato Y, et al. The Vienna classification of gastrointestinal epithelial neoplasia. *Gut*. 2000; 47: 251-255. doi: [10.1136/gut.47.2.251](https://doi.org/10.1136/gut.47.2.251)
- Hvid-Jensen F, Pedersen L, Drewes AM, et al. Incidence of adenocarcinoma among patients with Barrett's esophagus. *N Engl J Med*. 2011; 365: 1375-1383. doi: [10.1056/NEJMoa1103042](https://doi.org/10.1056/NEJMoa1103042)
- Spechler SJ, Sharma P, Souza RF, et al. American gastroenterological association technical review on the management of barrett's esophagus. *Gastroenterology*. 2011; 140(3): e18-e13. doi: [10.1053/j.gastro.2011.01.031](https://doi.org/10.1053/j.gastro.2011.01.031)
- Orman ES, Li N, Shaheen NJ. Efficacy and durability of radiofrequency ablation for Barrett's esophagus: Systematic review and meta-analysis. *Clin Gastroenterol Hepatol*. 2013; 11(10): 1245-1255.
- Saligram S, Chennat J, Hu H, et al. Endotherapy for superficial adenocarcinoma of the esophagus: An American experience. *Gastrointest Endosc*. 2013; 77(6): 872-876. doi: [10.1016/j.gie.2013.01.014](https://doi.org/10.1016/j.gie.2013.01.014)
- Saligram S, Tofteland N, Wani S et al. Long-term results of the mucosal ablation of Barrett's esophagus: Efficacy and recurrence. *Endosc Int Open*. 2015; 3(3): E189-E194. doi: [10.1055/s-0034-1391669](https://doi.org/10.1055/s-0034-1391669)
- Brown J, Alsop B, Gupta N et al. Effectiveness of focal vs. balloon radiofrequency ablation devices in the treatment of Barrett's esophagus. *United European Gastroenterol J*. 2016; 4(2): 236-241. doi: [10.1177/2050640615594549](https://doi.org/10.1177/2050640615594549)
- Pech O, Behrens A, May A, et al. Long-term results and risk factor analysis for recurrence after curative endoscopic therapy in 349 patients with high-grade intraepithelial neoplasia and mucosal adenocarcinoma in Barrett's oesophagus. *Gut*. 2008; 57(9): 1200-1206. doi: [10.1136/gut.2007.142539](https://doi.org/10.1136/gut.2007.142539)
- Halsey KD, Greenwald BD. Cryotherapy in the management of esophageal dysplasia and malignancy. *Gastrointest Endosc Clin N Am*. 2010; 20(1): 75-87. doi: [10.1016/j.giec.2009.07.009](https://doi.org/10.1016/j.giec.2009.07.009)
- Gosain S, Mercer K, Twaddell WS, et al. Liquid nitrogen spray cryotherapy in Barrett's esophagus with high-grade dysplasia: Long-term results. *Gastrointest Endosc*. 2013; 78(2): 260-265. doi: [10.1016/j.gie.2013.03.002](https://doi.org/10.1016/j.gie.2013.03.002)
- Sengupta N, Ketwaroo GA, Bak DM, et al. Salvage cryotherapy after failed radiofrequency ablation for Barrett's esophagus-related dysplasia is safe and effective. *Gastrointest Endosc*. 2015; 82(3): 443-448. doi: [10.1016/j.gie.2015.01.033](https://doi.org/10.1016/j.gie.2015.01.033)