

## Mini Review

### \*Corresponding author

Joy Sarkar, PhD

Department of Ophthalmology  
and Visual Sciences  
University of Illinois at Chicago  
Illinois Eye & Ear Infirmary  
Chicago, IL 60612, USA  
E-mail: [jsarkar1@uic.edu](mailto:jsarkar1@uic.edu)

Volume 2 : Issue 1

Article Ref. #: 1000OOJ2108

### Article History

Received: December 20<sup>th</sup>, 2016

Accepted: February 6<sup>th</sup>, 2017

Published: February 7<sup>th</sup>, 2017

### Citation

Sarkar J. Recent perspectives on corneal nerves: A short review. *Ophthalmol Open J.* 2017; 2(1): 12-19. doi: [10.17140/OOJ-2-108](https://doi.org/10.17140/OOJ-2-108)

### Copyright

©2017 Sarkar J. This is an open access article distributed under the Creative Commons Attribution 4.0 International License (CC BY 4.0), which permits unrestricted use, distribution, and reproduction in any medium, provided the original work is properly cited.

## Recent Perspectives on Corneal Nerves: A Short Review

Joy Sarkar, PhD\*

Department of Ophthalmology and Visual Sciences, University of Illinois at Chicago, Illinois Eye & Ear Infirmary, Chicago, IL 60612, USA

### ABSTRACT

This mini-review provides an overview of recent trends in our understanding of the general structure of the cornea, the importance of corneal nerves, their function and distribution in the different layers of the cornea based on reports obtained by imaging techniques such as *in vivo* confocal microscopy (IVCM) and immunohistochemistry (IHC) analysis. Recent data on corneal nerve status in conditions such as Dry Eye Disease (DED) and Diabetes is also discussed. There is additional emphasis on corneal nerve damage due to injury especially during surgical interventions and underlying disease states as well as translational research on corneal nerve regeneration. Information on recent clinical studies on the effect of laser corneal surgery and its impact on corneal nerves is also presented.

**KEY WORDS:** Corneal nerves; Immunohistochemistry (IHC); Dry Eye Disease (DED).

**ABBREVIATIONS:** IVCM: *In Vivo* Confocal Microscopy; IHC: Immunohistochemistry; Dry Eye Disease (DED); TEM: Transmission Electron Microscopy; LASIK: Laser-assisted *in situ* keratomileusis; PRK: Photorefractive keratectomy; ReLEx: Refractive Lenticule Extraction; SMILE: Small Incision Lenticule Extraction.

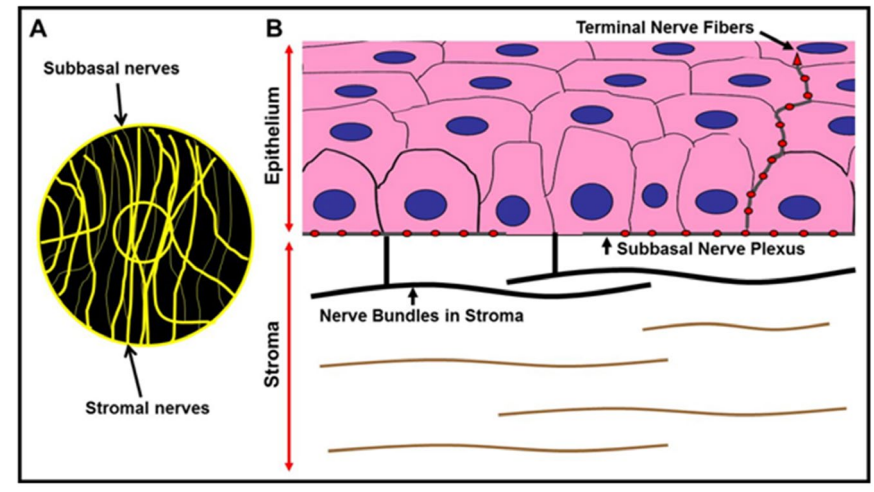
### INTRODUCTION

The eye is one of the most fascinating organs of the human body and has numerous parts each of which plays a critical role in providing vision (sight). As the well-known saying goes “the eyes are the window to the soul”, for the layman, the cornea is indeed that part of this window through which light enters the eye and along with the lens is focused onto the retina. The retina in turn absorbs and converts the light into electrochemical impulses which are then transferred to the brain *via* the optic nerve. The cornea is the outermost transparent, clear and avascular connective tissue layer that forms the front part of the eye. It is dome-shaped and covers the pupil, iris and the anterior chamber and acts as a structural barrier for primary infections to the eye. Structurally and anatomically the main layers of the human cornea include, the epithelial layer or epithelium, the Bowman’s membrane, the stromal layer or stroma, the recently identified Pre-Descemet’s layer known as Dua’s layer, the Descemet’s membrane and the endothelial layer or endothelium.<sup>1-3</sup> The cornea stands out as being one of the most densely innervated tissues in the body<sup>4</sup> and our current understanding of the cornea and corneal diseases in general is based on the seminal works of numerous scientists and clinicians in the field of ophthalmology. The purpose of this short review is to highlight some important studies and findings in the field of corneal nerve research.

### STRUCTURE AND FUNCTION OF CORNEAL NERVES

The organization of human corneal nerves has been investigated ever since Schlemm et al<sup>5</sup> discovered their presence in the limbus. Corneal nerves originate from the trigeminal nerve (ophthalmic branch) and enter the corneal stroma after which they form a subbasal plexus below the epithelium, and extend into thinner nerves containing nociceptors at the corneal surface.<sup>6,7</sup> The

**Figure 1:** Schematic Representation of Corneal Nerves. Panel A: Branched subbasal and stromal nerves are distributed throughout the cornea with the subbasal nerves visible on the corneal surface whereas the stromal nerve trunks are deeper. Panel B: Cross-sectional view of corneal stromal nerves and subbasal plexus in the cornea. The beaded nerves fibers separate from the subbasal plexus and obliquely/slantwise protrude upwards towards the epithelium and form terminal nerve fibers in the superficial layers of the corneal epithelium (schematic artwork done by Joy Sarkar and Ruth Zelkha based on Linda JM et al, 2003 and Tomas-Juan J et al, 2014).<sup>4,46</sup>



innervations of the cornea and bulbar conjunctiva is contributed mainly by the sensory fibers of the ophthalmic branch of the trigeminal nerve and by the less numerous sympathetic and parasympathetic nerve fibers.<sup>8</sup> In addition to their important sensory function, corneal nerves also play an important role in providing protection and are involved in trophic functions. Corneal nerves have also been known to be involved in the regulation of corneal epithelial integrity, wound healing and cell proliferation.<sup>9</sup> A renewed interest in corneal neurobiology arose recently because of the pivotal role these nerves play in maintaining a healthy ocular surface, which is especially important today due to the damage corneal nerves incur from refractive surgery, corneal transplants and herpetic infections (Figure 1).

### Corneal Nerves and Dry Eye Disease

One major condition that causes epithelial abnormalities is dry eye syndrome. It is has been estimated that nearly 10% of the U.S. population suffers from dry eye syndrome, which in turn significantly affects quality of life in these patients. Dry Eye Disease (DED) is considered to be a disease mainly of the tears and ocular surface causing symptoms of discomfort, disturbance in vision and instability of the tear film with possible damage to the ocular surface.<sup>1</sup> DED can also occur due to disturbance of the lacrimal glands, the ocular surface and eyelids, and the sensory and motor nerves that connect them.<sup>8,9</sup> A stimulation of corneal nerves followed by nerve alterations has been postulated as one of the core pathophysiological mechanisms in DED.

### Corneal Nerves and Aging

Aging has been implicated in the increased incidence of dry eye<sup>10</sup> and although some risk factors have been identified, not

much is known about the causes. The role of aging and how it affects nerve architecture of the cornea is a very important focus of recent research. Early studies on corneal nerves in animals and humans were purely based on light or electron microscopic evaluations. Schimmelpfennig et al<sup>11</sup> studied fresh central corneal buttons from keratoplasties and enucleations by staining with gold chloride and provided one of the first comprehensive descriptions of corneal epithelial nerves.<sup>11</sup> This has been followed by numerous fixation and staining methodologies and this gamut of analytical procedures have greatly contributed to enhancing our knowledge of the morphology, ultrastructural organization, density, and corneal nerve alterations after injury or death.<sup>4,6</sup> Studies by two prominent groups<sup>12,13</sup> mention that 'aging' is accompanied by structural and functional changes in the cornea involving corneal steepening and increased thickness of the Descemet's membrane.<sup>14</sup> Aging has also been shown to impact corneal wound healing as well as affect visual acuity and refractive outcomes after laser refractive surgery.<sup>15-18</sup>

### Imaging and Visualizing Corneal Nerves

For the longest time, visualization of the human cornea and the different layers within has remained a pipe-dream. In recent years, the introduction of *in vivo* confocal microscopy (IVCM) has provided a new method for high resolution corneal examination in living patients.<sup>19,20</sup> It has broadened the scope for non-surgical intervention and cellular examination of live corneas *in vivo*.<sup>21-26</sup> However, despite breakthroughs in imaging techniques, the distribution of corneal nerves is not completely deciphered as yet and the reasons for this lack of understanding is because of the difficulty in obtaining detailed innervations in the different corneal layers since conventional histology requires fresh corneas. Secondly, transmission electron microscopy (TEM) images are

restricted to very tiny areas of the corneal surface (0.1 mm<sup>2</sup>). Finally, IVCN images of the human cornea are captured from the corneal apex. Also these microscopes have a limitation in that they cannot image branching nerves and their terminals of diameters <0.5 mm.

In a recent paper published by Haydee Bazan's group at LSU, New Orleans, LA, USA,<sup>27</sup> the authors have introduced a novel tissue preparation technique to study and image the exact location of nerve fibers. Studies in the past used cross-sections which failed to show detailed corneal innervations. Studies by Müller et al have implicated nerve degeneration to be the main reason for lack of innervation data as seen *via* electron microscopy techniques demonstrating significant nerve degeneration within ~12-13.5 h of death.<sup>4,6</sup> The modified technique used by Bazan's team for this study allowed for observation of new nerve structure features and, for the first time, provided a complete view of the human corneal nerve architecture. Our study reveals that aging decreases the number of central epithelial nerve terminals, and increases the presence of irregular anomalies beneath the basal layer.

Linna et al<sup>28</sup> have shown that corneal areas with short, unconnected nerve fiber bundles are associated with lower sensitivities than corneal areas with long nerve fiber bundles with or without interconnections. Laser-assisted *in situ* keratomileusis (LASIK)-induced alterations of subbasal nerve morphology can be visualized *via in vivo* confocal microscopy. This allows the observer to make a direct comparison of corneal sensory innervation and sensitivity to touch, pain, heat, cold, etc.

### Imaging Corneal Nerves in Diabetes

These days, confocal microscopy is employed on a wide scale for studying and evaluating corneal changes in diabetic patients.<sup>23,29-32</sup> There are numerous reports of changes in the subbasal nerve plexus of diabetic patients due to epithelial loss and corneal hypoesthesia.<sup>30-32</sup> Increased light scattering due to abnormalities of the basement membrane has also been reported in a study by Morishige et al.<sup>31,32</sup> The importance of stromal nerve changes in diabetic patient corneas is unclear at the moment due to the lack of extensive studies using confocal microscopy. Since patients with diabetes have reduced corneal sensitivity,<sup>30</sup> they are more susceptible to corneal trauma. Studies by Müller et al in diabetic rats demonstrated altered morphology of corneal nerves using light and electron microscopy. In addition to the observation of polymorphism in epithelium and endothelium,<sup>33-35</sup> Busted et al<sup>36</sup> and Pierro et al<sup>37</sup> reported increased corneal thickness in diabetic patients.<sup>38</sup>

Early studies by Frueh et al<sup>39</sup> examined the corneas of 10 Type 1 Diabetes, 10 Type 2 Diabetes and 10 Non-diabetic patients by confocal microscopy and found epithelium and endothelium polymorphisms and abnormal stromal nerves in only two patients with Type 1 Diabetes. No specific observations on the subbasal nerves or corneal sensitivity were reported.<sup>40</sup> A cor-

relation between corneal light-scattering index and stages of diabetic retinopathy was published by Morishige et al<sup>31,32</sup> although nerve morphology was not described. Confocal microscopy studies on skin biopsy specimens have revealed that the number of epidermal nerve fibers per unit surface area in patients with diabetic polyneuropathy is reduced.<sup>41</sup> Confocal microscopy appears to allow early detection of beginning neuropathy, because decreases in nerve fiber bundle counts precede impairment of corneal sensitivity.<sup>42</sup>

Apparently, the cornea becomes thicker in a relatively early stage of diabetes but does not further change with the degree of neuropathy. A reduction in neurotrophic stimuli in severe neuropathy may induce a thin epithelium that may lead to recurrent erosions.<sup>30</sup>

### Corneal Nerves and Refractive Surgeries

In Photorefractive keratectomy (PRK), photoablation causes severing of the subbasal nerve plexus and anterior stromal nerves.<sup>43,44</sup> Tandem scanning confocal microscopy studies by Erie have shown that subbasal nerve fiber density was 98% less than pre-operatively<sup>43</sup> and the ablation zone center showed complete absence of branched nerve fibers, 3 months post-surgery. Both Moilanen and Erie have demonstrated that subbasal nerve density was reduced by 87%, 75% and 60%, (at 3, 6 and 12 months respectively) after PRK, and returned to preoperative levels at 2 and 3 years postoperatively.<sup>43,45</sup> In another study using confocal microscopy, Erie's team proved faster recovery of subbasal nerve density in the central cornea in PRK as compared to LASIK.<sup>44</sup> Hanneken's group have recently published an excellent review on corneal regeneration after PRK wherein they elucidate how corneal wounding develops following PRK. They also reviewed the influence of intra-operative application of mitomycin C, bandage contact lenses, anti-inflammatory and other drugs in preventing corneal haze post-PRK.<sup>46</sup> Laser *in situ* keratomileusis (LASIK) is a procedure that utilizes either a bladeless femtosecond laser (FS-LASIK or F-LASIK) or a traditional mechanical microkeratome (MS-LASIK) to create a corneal flap, followed by stromal ablation using an excimer laser.<sup>47</sup> Femtosecond laser technology was first developed in the early 1990s by Dr. Kurtz at the University of Michigan, Ann Arbor, MI, USA<sup>48,49</sup> and was extensively used in the surgical field of ophthalmology for its increased safety, precision and predictability over conventional microkeratomes and reduced dry eye symptoms. Femtosecond lasers emit light pulses of short duration (approximately 10-15 s) at 1053 nm wavelength that cause photodisruption of the tissue with minimum collateral damage.<sup>48-51</sup> This enables bladeless incisions to be performed within the tissue at various patterns and depth with high precision. A new corneal refractive procedure that does not require stromal ablation using an excimer laser called Refractive lenticule extraction (ReLEx) has been discussed by Ang et al.<sup>52</sup> In ReLEx, a femtosecond laser is used to create an intrastromal refractive lenticule to correct the refractive error. There are 2 versions of this. In the original ReLEx procedure, femtosecond lenticule

**Table 1:** Mean Corneal Sensation (in millimeters) at Baseline and after the Procedures.

Reference	Number of Eyes	Age (in years)	Location of Cornea	Surgery Group	Pre-op	1W post-op	1M post-op	3M post-op	6M post-op		
Wei and Wang <sup>57</sup>	FS-LASIK group (n=54)	25.44 ±7.15 (18 to 49)	Central	FS-LASIK	5.81±0.43	2.21±1.28*	2.62±1.72*	3.79±1.44*			
				ReLEx flex	5.88±0.22	2.95±1.41**,***	3.00±1.24**	4.52±0.96**,***			
	ReLEx flex group (n=40)	24.45 ±5.72 (18 to 37)		ReLEx smile	5.66±0.45	4.75±1.21**,***	5.11±1.05**,***	5.73±0.51***			
				ReLEx smile group (n=61)	27.44 ±6.52 (18 to 43)	Superior	FS-LASIK	5.25±0.69	3.61±1.35*	4.09±1.35*	4.63±1.05*
							ReLEx flex	5.21±0.85	4.43±1.16**,***	4.39±1.22**	4.98±1.03
	ReLEx smile	5.33±0.56	4.70±0.90**,***	5.19±0.61***	5.55±0.57***						
				Inferior	FS-LASIK	5.56±0.56	2.28±1.40*	2.81±1.80*	4.19±1.32*		
					ReLEx flex	5.39±0.68	2.46±1.31**	2.93±1.37**	4.95±0.99***		
					ReLEx smile	5.66±0.47	4.92±0.79**,***	5.37±0.66**,***	5.63±0.57***		
Demirok et al <sup>55</sup>	F-LASIK group (n=28)	26.2 ±4.4 (21 to 34)	Central	F-LASIK	56.2±5.0	30.3±15.3	31.2±14	37.5±14.8	53.7±5		
				SMILE	56.8±4.7	45.6±11.5	45.3±10.5	49.3±9.9	55.9±4.9		
	SMILE group (n=28)	26.2 ±4.4 (21 to 34)		Superior	F-LASIK	54.3±4.4	34.3±12.2	35±12	41.2±10.8	53.4±4.7	
					SMILE	55.3±4.6	44±9.1	44±10.2	48.7±9.5	55.3±4.9	
				Inferior	F-LASIK	55.0±4.8	29.0±15	30.6±14	36.2±15	53.1±6	
					SMILE	55.6±4.4	46.8±11.9	46.2±10.8	49.7±10	55.6±5.1	

All values are Mean±SD standard deviation  
 \* refers to changes of corneal sensitivity values post-op in the FS-LASIK group were significantly different from pre-op values with p<0.05,  
 \*\* refers to changes of corneal sensitivity values post-op in the ReLEx flex group were significantly different from pre-op values with p< 0.05  
 \*\*\*refers to changes of corneal sensitivity values post-op in the ReLEx flex group were significantly different from values in the FS-LASIK group with p< 0.05  
 W refers to week; M refers to month; pre-op refers to pre-surgery; post-op refers to post surgery

extraction (FLEx), mimics LASIK with the creation of an anterior hinged flap. The lenticule is peeled away after the flap is lifted. Small incision lenticule extraction (SMILE) is a refined version of ReLEx and does not need flap-creation. It involves lenticule dissection and extraction from a small curved bow-like incision (2.5-3 mm) positioned superiorly.<sup>52,53</sup> In a prospective, randomized clinical trial (contralateral-eye study), 28 patients with myopia or myopic astigmatism in both eyes were enrolled. One eye of each patient was treated by SMILE, and the fellow eye was treated by F-LASIK. One of the mean outcome measures for corneal sensation was Cochet-Bonnet esthesiometry<sup>54</sup> and patients were evaluated pre-operatively as well as 1 week, 1 month, 3 months, and 6 months after surgery. This study by Demirok et al<sup>55</sup> evaluated the effects of SMILE and F-LASIK on corneal sensation and dry eye parameters revealed that although the dry eye parameters were similar in both surgical groups, there was a significant decrease in corneal sensation measured using a Cochet-Bonnet corneal esthesiometer after both types of surgery with more pronounced effects after F-LASIK sur-

gery as compared to SMILE surgery. This difference could be attributed to the fact that LASIK disrupts both the dense sub-basal nerve plexus and stromal corneal nerves in the creation of the anterior stromal flap and excimer laser ablation of the cornea whereas in SMILE there is less damage to the corneal nerve since the refractive change in SMILE is not obtained by excimer laser-induced photoablation but rather by a femtosecond laser-induced refractive cut.<sup>56</sup> Another non-randomized clinical trial by Wei and Wang et al<sup>57</sup> evaluated corneal sensitivity between FS-LASIK and femtosecond lenticule extraction (ReLEx flex) or small-incision lenticule extraction (ReLEx smile) for myopic eyes. Twenty-seven subjects (54 eyes) underwent FSLASIK, 22 subjects (40 eyes) underwent ReLEx flex, and 32 subjects (61 eyes) underwent ReLEx smile surgery. Corneal sensitivity was evaluated by Cochet-Bonnet esthesiometry preoperatively as well as at 1 week and 1 and 3 months after surgery.<sup>58</sup> In both trials, randomized and non-randomized, better DRY Eye outcomes were observed after SMILE as compared to femtosecond LASIK (femto LASIK) and recovery to baseline corneal sensi-

**Table 2:** Mean Corneal Nerve Morphology (from *in-vivo* confocal microscopy; IVCM) and Corneal Sensation (in centimeters) at Baseline and after the Procedures.

Reference	Number of Eyes	Age (in years)	Parameters	Surgery Group	Pre-op	6M post-op
Vestergaard et al <sup>56</sup>	FLEX group (n=34)	35±7 (25 to 45)	Corneal nerve morphology (n=31 patients)	FLEX	19.00±5.51	4.78 ± 3.91
			Density (mm/mm <sup>2</sup> , mean±SD)	SMILE	17.62±5.27	8.41±7.01*
	SMILE group (n=34)	35±7 (25 to 45)	Number (/mm <sup>2</sup> , mean±SD)	FLEX	80.3±25.8	32.7±22.4
				SMILE	78.3±19.4	53.8±37.5**
			Tortuosity (grade, mean±SD)	FLEX	1.65±0.54	1.51±0.62
				SMILE	1.69±0.49	1.60±0.54
			Corneal sensation (n=34 patients)	FLEX	5.87±0.20	5.49±0.45
			Cochet-Bonnet esthesiometry (cm, mean±SD)	SMILE	5.88±0.19	5.78±0.34**

All values are Mean±SD (standard deviation)  
 \*refers to a statistically significant difference between femtosecond lenticule extraction (FLEX) and small-incision lenticule extraction (SMILE) with  $p<0.05$   
 \*\*refers to a statistically significant difference between femtosecond lenticule extraction (FLEX) and small-incision lenticule extraction (SMILE) with  $p<0.01$   
 W refers to week; M refers to month; pre-op refers to pre-surgery; post-op refers to post surgery

tivity was faster with SMILE as compared to both femto-LASIK and Femtosecond Lenticule Extraction (FLEX). Other studies by Jodhbir Mehta's group<sup>59</sup> have also evaluated corneal nerve changes after small incision lenticule extraction (SMILE) and laser *in situ* keratomileusis (LASIK). They found that more sub-basal nerves were disrupted and undergoing regeneration after LASIK as compared to the SMILE group which in comparison demonstrated greater subbasal nerve length and density and higher subbasal nerve recovery at different time-points post-surgery (Table 1 and 2).

## CORNEAL NERVE RESEARCH

New advances in imaging technology and disease models (*in vitro* cell and tissue-based as well as *in vivo* transgenic animal-based models) for studying corneal nerves and reinnervation after nerve injury or disease have further enhanced our knowledge of the corneal structure and architecture of corneal nerves in normal and diseased states.<sup>60</sup> The thyl-YFP transgenic mouse model developed by Joshua Sanes' group<sup>61</sup> which exhibits yellow fluorescent nerves in the cornea has provided an amazing tool to basic and translational scientists to study corneal nerves *in vivo* and studies using this model have yielded numerous breakthroughs and publications in the field of corneal nerve injury and regeneration research.<sup>7,62-64</sup> These studies have highlighted neurotoxicity in the eye due to preservatives like benzalkonium chloride and augmented the move towards non-neurotoxic preservative-free eye-drops,<sup>62</sup> the presence of inflammatory CD11b+GR1+myeloid-derived suppressor cells which play an important role in nerve regeneration,<sup>65</sup> the importance of VEGF-B in stimulating peripheral nerve growth, etc.<sup>63</sup>

This greater clarity and continued progress in our understanding of the functional and structural alterations of nerves in normal and disease states and their correlation with clinical signs and symptoms is crucial for the further development of targeted drug therapy and treatments for debilitating corneal diseases. The window to the future appears truly bright indeed!

## ACKNOWLEDGEMENTS

The author would like to thank Ruth Zekha from the UIC Ophthalmology Core for her help with artwork and schematic representations. Supported by National Eye Institute (NEI) Core Grant EY001792 and Research to Prevent Blindness.

## FINANCIAL DISCLOSURES

The author does not have any financial or proprietary interest in any material or method mentioned.

## REFERENCES

1. The definition and classification of dry eye disease: Report of the Definition and Classification Subcommittee of the International Dry Eye Work Shop. *Ocul Surf.* 2007; 5: 75-92.
2. Dua HS, Faraj LA, Said DG, Gray T, Lowe J. Human corneal anatomy redefined: A novel pre-Descemet's layer (Dua's layer). *Ophthalmology.* 2013; 120(9): 1778-1785. doi: [10.1016/j.ophtha.2013.01.018](https://doi.org/10.1016/j.ophtha.2013.01.018)
3. Dua HS, Faraj LA, Branch MJ, et al. The collagen matrix of



- the human trabecular meshwork is an extension of the novel pre-Desemet's layer (Dua's layer). *Br J Ophthalmol*. 2014; 95(5): 691-697. doi: [10.1136/bjophthalmol-2013-304593](https://doi.org/10.1136/bjophthalmol-2013-304593)
4. Muller LJ, Marfurt CF, Kruse F, Tervo TM. Corneal nerves: Structure, contents and function. *Exp Eye Res*. 2003; 76(5): 521-542. doi: [10.1016/S0014-4835\(03\)00050-2](https://doi.org/10.1016/S0014-4835(03)00050-2)
5. Schlemm TFW. Nerven der Cornea [In German]. *Ammon' Z Ophthalmol*. 1831; 1: 113-114.
6. Muller LJ, Vrensen GF, Pels L, Cardozo BN, Willekens B. Architecture of human corneal nerves. *Invest Ophthalmol Vis Sci*. 1997; 38(5): 985-994. Web site. <http://iovs.arvojournals.org/article.aspx?articleid=2161847>. Accessed December 19, 2016.
7. Yu CQ, Rosenblatt MI. Transgenic corneal neurofluorescence in mice: A new model for in vivo investigation of nerve structure and regeneration. *Invest Ophthalmol Vis Sci*. 2007; 48(4): 1535-1542. doi: [10.1167/iovs.06-1192](https://doi.org/10.1167/iovs.06-1192)
8. Stern ME, Beuerman RW, Fox RI, et al. The pathology of dry eye: The interaction between the ocular surface and lacrimal glands. *Cornea*. 1998; 17(6): 584-589. Web site. <https://www.pubfacts.com/detail/9820935/The-pathology-of-dry-eye-the-interaction-between-the-ocular-surface-and-lacrimal-glands>. Accessed December 19, 2016.
9. Marfurt CF, Cox J, Deek S, Dvorscak L. Anatomy of the human corneal innervation. *Exp Eye Res*. 2010; 90(4): 478-492. doi: [10.1016/j.exer.2009.12.010](https://doi.org/10.1016/j.exer.2009.12.010)
10. Smith JA. The epidemiology of dry eye disease: Report of the epidemiology subcommittee of the international dry eye workshop (2007). *Ocul Surf*. 2007; 5(2): 93-107.
11. Schimmelpfennig B. Nerve structures in human central corneal epithelium. *Graefes Arch Clin Exp Ophthalmol*. 1982; 218(1): 14-20. doi: [10.1007/BF02134093](https://doi.org/10.1007/BF02134093)
12. Niederer RL, Perumal D, Sherwin T, McGhee CNJ. Age-related differences in the normal human cornea: A laser scanning in vivo confocal microscopy study. *Br J Ophthalmol*. 2007; 91(9): 1165-1169. doi: [10.1136/bjo.2006.112656](https://doi.org/10.1136/bjo.2006.112656)
13. DelMonte DW, Kim T. Anatomy and physiology of the cornea. *J Cataract Refract Surg*. 2011; 37(3): 588-598. doi: [10.1016/j.jcrs.2010.12.037](https://doi.org/10.1016/j.jcrs.2010.12.037)
14. Faragher RG, Mulholland B, Tuft SJ, et al. Aging and the cornea. *Br J Ophthalmol*. 1997; 81: 814-817. doi: [10.1007/978-1-59745-507-7\\_4](https://doi.org/10.1007/978-1-59745-507-7_4)
15. Waring GO 3rd, Lynn MJ, Nizam A, et al. Results of the Prospective Evaluation of Radial Keratotomy (PERK) Study five years after surgery. The Perk Study Group. *Ophthalmology*. 1991; 98(8): 1164-1176. doi: [10.1016/S0161-6420\(91\)32156-0](https://doi.org/10.1016/S0161-6420(91)32156-0)
16. Dutt S, Steinert RF, Raizman MB, Puliafito CA. One-year results of excimer laser photorefractive keratectomy for low to moderate myopia. *Arch Ophthalmol*. 1994; 112(11): 1427-1436. doi: [10.1001/archophth.1994.01090230041018](https://doi.org/10.1001/archophth.1994.01090230041018)
17. Chatterjee A, Shah SS, Doyle SJ. Effect of age on final refractive outcome for 2342 patients following photorefractive keratectomy. *Invest Ophthalmol Vis Sci*. 1996; 37: S57.
18. Marre M. On the age dependence of the healing of corneal epithelium defects [In German]. *Albrecht Von Graefes Arch Klin Exp Ophthalmol*. 1967; 173(3): 250-255.
19. Cavanagh HD, Petroll WM, Alizadeh H, He Y-G, Mc Culley JP, Jester JV. Clinical and diagnostic use of in vivo confocal microscopy in patients with corneal disease. *Ophthalmology*. 1993; 100(10): 1444-1454. doi: [10.1016/S0161-6420\(93\)31457-0](https://doi.org/10.1016/S0161-6420(93)31457-0)
20. Bohnke M, Masters BR. Confocal microscopy of the cornea. *Prog Retinal Eye Res*. 1999; 18(5): 553-628.
21. Oliveira-Soto L, Efron N. Morphology of corneal nerves using confocal microscopy. *Cornea*. 2001; 20(4): 374-384.
22. Lee J-K, Ryu Y-H, Ahn J-I, Kim M-K, Lee T-S, Kim J-C. The effect of lyophilization on graft acceptance in experimental xenotransplantation using porcine cornea. *Artif Organs*. 2010; 37-45. doi: [10.1111/j.1525-1594.2009.00789.x](https://doi.org/10.1111/j.1525-1594.2009.00789.x)
23. Malik RA, Kallinikos P, Abbott CA, et al. Corneal confocal microscopy: A non-invasive surrogate of nerve fibre damage and repair in diabetic patients. *Diabetologia*. 2003; 46(5): 683-688. doi: [10.1007/s00125-003-1086-8](https://doi.org/10.1007/s00125-003-1086-8)
24. Patel DV, McGhee CN. Mapping of the normal human corneal sub-Basal nerve plexus by in vivo laser scanning confocal microscopy. *Invest Ophthalmol Vis Sci*. 2005; 46(12): 4485-4488. doi: [10.1167/iovs.05-0794](https://doi.org/10.1167/iovs.05-0794)
25. Stachs O, Zhivov A, Kraak R, Stave J, Guthoff R. In vivo three-dimensional confocal laser scanning microscopy of the epithelial nerve structure in the human cornea. *Graefes Arch Clin Exp Ophthalmol*. 2007; 245(4): 569-575. doi: [10.1007/s00417-006-0387-2](https://doi.org/10.1007/s00417-006-0387-2)
26. Scarpa F, Zheng X, Ohashi Y, Ruggeri A. Automatic evaluation of corneal nerve tortuosity in images from in vivo confocal microscopy. *Invest Ophthalmol Vis Sci*. 2011; 52(9): 6404-6408. doi: [10.1167/iovs.11-7529](https://doi.org/10.1167/iovs.11-7529)
27. He J, Bazan NG, Bazan HEP. Mapping the entire human corneal nerve architecture. *Experimental Eye Research*; 2010.

28. Linna TU, Vesaluoma MH, Perez-Santonja JJ, Petroll WM, Alio JL, Tervo TMT. Effect of Myopic LASIK on Corneal Sensitivity and Morphology of Subbasal Nerves. *Invest Ophthalmol Vis Sci.* 2000; 41(2): 393-439. Web site. <http://iovs.arvojournals.org/article.aspx?articleid=2199874>. Accessed December 19, 2016.
29. Mocan MC, Durukan I, Irkec M, Orhan M. Morphologic Alterations of Both the Stromal and Subbasal Nerves in the Corneas of Patients with Diabetes. *Cornea.* 2006; 25(7): 769-773. doi: [10.1097/01.icc.0000224640.58848.54](https://doi.org/10.1097/01.icc.0000224640.58848.54)
30. Rosenberg ME, Tervo TM, Immonen IJ, et al. Corneal structure and sensitivity in type 1 diabetes mellitus. *Invest Ophthalmol Vis Sci.* 2000; 41(10): 2915-2921. Web site. <http://iovs.arvojournals.org/article.aspx?articleid=2123743>. Accessed December 19, 2016.
31. Morishige N, Chikama T, Sassa Y, Nishida T. Correlation of corneal light scattering index measured by a confocal microscope with stages of diabetic retinopathy [ARVO Abstract]. *Invest Ophthalmol Vis Sci.* 1999; 40(4): S620.
32. Morishige N, Chikama TI, Sassa Y, et al. Abnormal light scattering detected by confocal biomicroscopy at the corneal epithelial basement membrane of subjects with type II diabetes. *Diabetologia.* 2001; 44(3): 340-345. doi: [10.1007/s001250051624](https://doi.org/10.1007/s001250051624)
33. Ruben ST. Corneal sensation in insulin dependent and non-insulin dependent diabetics with proliferative retinopathy. *Acta Ophthalmol.* 1994; 72(5): 576-580. doi: [10.1111/j.1755-3768.1994.tb07182.x](https://doi.org/10.1111/j.1755-3768.1994.tb07182.x)
34. Schultz RO, Matsuda M, Yee RW, Edelhauser HF, Schultz KJ. Corneal endothelial changes in type I and type II diabetes mellitus. *Am J Ophthalmol.* 1984; 98(4): 401-410. doi: [10.1111/aos.12064](https://doi.org/10.1111/aos.12064)
35. Schultz RO, Peters MA, Sobocinski K, Nassif K, Schultz KJ. Diabetic corneal neuropathy. *Trans Am Ophthalmol Soc.* 1983; 81: 107-124.
36. Busted N, Olsen T, Schmitz O. Clinical observations on the corneal thickness and the corneal endothelium in diabetes mellitus. *Br J Ophthalmol.* 1981; 65(10): 687-690. doi: [10.1136/bjo.65.10.687](https://doi.org/10.1136/bjo.65.10.687)
37. Pierro L, Brancato R, Zaganelli E. Correlation of corneal thickness with blood glucose control in diabetes mellitus. *Acta Ophthalmol.* 1993; 71(2): 169-172. doi: [10.1111/j.1755-3768.1993.tb04984.x](https://doi.org/10.1111/j.1755-3768.1993.tb04984.x)
38. McNamara NA, Brand RJ, Polse KA, Bourne WM. Corneal function during normal and high serum glucose levels in diabetes. *Invest Ophthalmol Vis Sci.* 1998; 39(1): 3-17. Web site. <http://iovs.arvojournals.org/article.aspx?articleid=2180804>. Accessed December 19, 2016.
39. Frueh BE, Koerner U, Boehnke M. Konfokale Mikroskopie der Hornhaut bei Patienten mit Diabetes mellitus [In German]. *Klin Monatsbl Augen-Heilkd.* 1995; 206(5): 317-319. doi: [10.1055/s-2008-1035450](https://doi.org/10.1055/s-2008-1035450)
40. Ishida N, Rao GN, del Gerro M, Aquavella JV. Corneal nerve alterations in diabetes mellitus. *Arch Ophthalmol.* 1984; 102(9): 1380-1384. doi: [10.1001/archophth.1984.01040031122038](https://doi.org/10.1001/archophth.1984.01040031122038)
41. Kennedy WR, Wendelschafer-Crabb G, Johnson T. Quantitation of epidermal nerves in diabetic neuropathy. *Neurology.* 1996; 47(4): 1042-1048. doi: [10.1212/WNL.47.4.1042](https://doi.org/10.1212/WNL.47.4.1042)
42. Nielsen NV, Lund FS. Diabetic polyneuropathy: Corneal sensitivity, vibratory perception and Achilles tendon reflex in diabetics. *Acta Neurol Scand.* 1979; 59(1): 15-22. doi: [10.1111/j.1600-0404.1979.tb02906.x](https://doi.org/10.1111/j.1600-0404.1979.tb02906.x)
43. Erie JC. Corneal wound healing after photorefractive keratectomy: A 3-year confocal microscopy study. *Trans Am Ophthalmol Soc.* 2003; 101: 293-333.
44. Erie JC, McLaren JW, Hodge DO, Bourne WM. Recovery of corneal subbasal nerve density after PRK and LASIK. *Am J Ophthalmol.* 2005; 140(6): 1059-1064. doi: [10.1016/j.ajo.2005.07.027](https://doi.org/10.1016/j.ajo.2005.07.027)
45. Moilanen JA, Vesaluoma MH, Müller LJ, Tervo TM. Long-term corneal morphology after PRK by in vivo confocal microscopy. *Invest Ophthalmol Vis Sci.* 2003; 44(3): 1064-1069. doi: [10.1167/iovs.02-0247](https://doi.org/10.1167/iovs.02-0247)
46. Juan JT, Larranaga AMG, Hanneken L. Corneal regeneration after photorefractive keratectomy: A review. *J Optom.* 2015; 8(3): 149-169. doi: [10.1016/j.optom.2014.09.001](https://doi.org/10.1016/j.optom.2014.09.001)
47. Shortt AJ, Allan BD. Photorefractive keratectomy (PRK) versus laser-assisted in-situ keratomileusis (LASIK) for myopia. *Cochrane Database Syst Rev.* 2006; 19: CD005135. doi: [10.1002/14651858.CD005135.pub2](https://doi.org/10.1002/14651858.CD005135.pub2)
48. Aristeidou A, Taniguchi EV, Tsatsos M, et al. The evolution of corneal and refractive surgery with the femtosecond laser: A review. *Eye and Vision.* 2015; 2: 12. doi: [10.1186/s40662-015-0022-6](https://doi.org/10.1186/s40662-015-0022-6)
49. Soong HK, Malta JB. Femtosecond lasers in ophthalmology. *Am J Ophthalmol.* 2009; 147: 189-197.
50. Stern D, Schoenlein RW, Puliafito CA, Dobi ET, Birngruber R, Fujimoto JG. Corneal ablation by nanosecond, picosecond, and femtosecond lasers at 532 and 625 nm. *Arch Ophthalmol.* 1989; 107(4): 587-592. doi: [10.1001/archophth.1989.01070010601038](https://doi.org/10.1001/archophth.1989.01070010601038)

51. Ratkay-Traub I, Ferincz IE, Juhasz T, Kurtz RM, Krueger RR. First clinical results with the femtosecond neodymium-glass laser in refractive surgery. *J Refract Surg.* 2003; 19(2): 94-103. doi: [10.3928/1081-597X-20030301-03](https://doi.org/10.3928/1081-597X-20030301-03)
52. Ang M, Chaurasia SS, Angunawela RI, et al. Femtosecond lenticule extraction (FLEX): Clinical results, interface evaluation, and intraocular pressure variation. *Invest Ophthalmol Vis Sci.* 2012; 53: 1414-1421. doi: [10.1167/iovs.11-8808](https://doi.org/10.1167/iovs.11-8808)
53. Sekundo W, Kunert KS, Blum M. Small incision corneal refractive surgery using the small incision lenticule extraction (SMILE) procedure for the correction of myopia and myopic astigmatism: Results of a 6 month prospective study. *Br J Ophthalmol.* 2011; 95(3): 335-339. doi: [10.1136/bjo.2009.174284](https://doi.org/10.1136/bjo.2009.174284)
54. Beuerman RW, McCulley JP. Comparative clinical assessment of corneal sensation with a new aesthesiometer. *Am J Ophthalmol.* 1978; 86(6): 812-815. doi: [10.1016/0002-9394\(78\)90127-7](https://doi.org/10.1016/0002-9394(78)90127-7)
55. Demirok A, Ozgurhan EB, Agca A, et al. Corneal sensation after corneal refractive surgery with small incision lenticule extraction. *Optom Vis Sci.* 2013; 90(10): 1040-1047. doi: [10.1097/OPX.0b013e31829d9926](https://doi.org/10.1097/OPX.0b013e31829d9926)
56. Vestergaard AH, Grønbech KT, Grauslund J, Ivarsen AR, Hjortdal JØ. Subbasal nerve morphology, corneal sensation, and tear film evaluation after refractive femtosecond laser lenticule extraction. *Graefes Arch Clin Exp Ophthalmol.* 2013; 251(11): 2591-2600. doi: [10.1007/s00417-013-2400-x](https://doi.org/10.1007/s00417-013-2400-x)
57. Wei S, Wang Y. Comparison of corneal sensitivity between FS-LASIK and femtosecond lenticule extraction (ReLEx flex) or small-incision lenticule extraction (ReLEx smile) for myopic eyes. *Graefes Arch Clin Exp Ophthalmol.* 2013; 251(6): 1645-1654. doi: [10.1007/s00417-013-2272-0](https://doi.org/10.1007/s00417-013-2272-0)
58. Tsubota K, Chiba K, Shimazaki J. Corneal epithelium in diabetic patients. *Cornea.* 1991; 10(2): 156-160.
59. Mohamed-Noriega K, Riau AK, Lwin NC, Chaurasia SS, Tan DT, Mehta JS. Early corneal nerve damage and recovery following small incision lenticule extraction (SMILE) and laser in situ keratomileusis (LASIK). *Invest Ophthalmol Vis Sci.* 2014; 55(3): 1823-1834. doi: [10.1167/iovs.13-13324](https://doi.org/10.1167/iovs.13-13324)
60. Shaheen BS, Bakir M, Jain S. Corneal nerves in health and disease. *Surv Ophthalmol.* 2014; 59(3): 263-285. doi: [10.1016/j.survophthal.2013.09.002](https://doi.org/10.1016/j.survophthal.2013.09.002)
61. Feng G, Mellor RH, Bernstein M, et al. Imaging neuronal subsets in transgenic mice expressing multiple spectral variants of GFP. *Neuron.* 2000; 28(1): 41-51. doi: [10.1016/S0896-6273\(00\)00084-2](https://doi.org/10.1016/S0896-6273(00)00084-2)
62. Sarkar J, Chaudhary S, Namavari A, et al. Corneal neurotoxicity due to topical benzalkonium chloride. *Invest Ophthalmol Vis Sci.* 2012; 53(4): 1792-1802. doi: [10.1167/iovs.11-8775](https://doi.org/10.1167/iovs.11-8775)
63. Guaiquil VH, Pan Z, Karagianni N, Fukuoka S, Alegre G, Rosenblatt MI. VEGF-B selectively regenerates injured peripheral neurons and restores sensory and trophic functions. *Proc Natl Acad Sci USA.* 2014; 111(48): 17272-17277. doi: [10.1073/pnas.1407227111](https://doi.org/10.1073/pnas.1407227111)
64. Namavari A, Chaudhary S, Sarkar J, et al. In vivo serial imaging of regenerating corneal nerves after surgical transection in transgenic thy1-YFP mice. *Invest Ophthalmol Vis Sci.* 2011; 52(11): 8025-8032. doi: [10.1167/iovs.11-8332](https://doi.org/10.1167/iovs.11-8332)
65. Sarkar J, Chaudhary S, Jassim SH, et al. CD11b+GR1+ myeloid cells secrete NGF and promote trigeminal ganglion neurite growth: Implications for corneal nerve regeneration. *Invest Ophthalmol Vis Sci.* 2013; 54(9): 5920-5936. doi: [10.1167/iovs.13-12237](https://doi.org/10.1167/iovs.13-12237)