

Case Report

Pneumocephalus Caused by an Epidural Ozone Injection for Treatment of Disc Prolapse

Surath Manimala Rao, DA, MD, FCCP, FICCM^{*1}; Laxmi Kotgire, DA¹; B.V. Savitr Sastri, MS, MCH²

¹Department of Critical Care Medicine, Yashoda Multi-Speciality Hospital, Somajiguda, Hyderabad 500082, India

²Department of Neurosurgery, Yashoda Multi-Speciality Hospital, Somajiguda, Hyderabad 500082, India

*Corresponding author

Surath Manimala Rao, DA, MD, FCCP, FICCM

Department of Critical Care Medicine, Yashoda Multi-Speciality Hospital, Somajiguda, Hyderabad 500082, India; Tel. 09676519111;

E-mail: manimalarao@hotmail.com

Article information

Received: March 6th, 2019; **Revised:** April 19th, 2019; **Accepted:** April 20th, 2019; **Published:** May 15th, 2019

Cite this article

Rao SM, Kotgire L, Sastri BVS. Pneumocephalus caused by an epidural ozone injection for treatment of disc prolapse. *Res Pract Anesthesiol Open J.* 2019; 4(1): 11-13.

doi: [10.17140/RPAOJ-4-124](https://doi.org/10.17140/RPAOJ-4-124)

ABSTRACT

Pneumocephalus is a complication seen either after head trauma or post-neurosurgical procedure. It can be life-threatening if it turns into tension pneumocephalus. The presence of intracranial air indicates the presence of an open communication of cerebrospinal fluid. Air enters dura matter even without connection. Thin air flows upstream along the cerebrospinal fluid (CSF) pathway. Herein, we report a case of pneumocephalus in a 62-year-old female after epidural injection of Bupivacaine and Ozone for the treatment of a prolapsed disc. She was shifted to our hospital post-epidural injection for the management of severe headache. Though it is a rare complication, keeping this in mind will help to quickly diagnose, if need arises.

Keywords

Pneumocephalus; Head trauma; CT; Thunderclap headache.

INTRODUCTION

Pneumocephalus occurs in the background of head trauma or neurosurgery. Ozone injections along with Bupivacaine are used for the treatment of prolapsed disc causing pain. The occurrence of pneumocephalus after epidural injection and also with ozone injections is rare. Understanding the pathophysiology and high degree of suspicion is the key to diagnose thunder clap headache after epidural injection. A case report is presented in this setting.

CASE REPORT

A 62-year-old female patient presented to our intensive care unit (ICU) with severe headache, nausea, vomitings 3-4 hours after she received an epidural injection of Bupivacaine 0.25%, Ozone 3 ml (30 mcg/ml) was injected at the L4-L5 disc space as a part of the treatment for pain relief. Localization of epidural space was done with a spring loaded epidural syringe.

The method involves direct approach was carried out by needle insertion followed by direct insufflation of the oxygen-ozone gas mixture (3-10 mL; ozone concentration about 30 µg/mL). She was suffering from low backache for past 10 years and was on multiple analgesics without significant pain relief.

She was admitted to our ICU after computed tomography (CT) head done at from emergency department. CT revealed multiple air foci in the frontal sulci, subdural space, supracellar and interpeduncular cisterns. She was reported to be haemodynamically stable, no neurological deficits were noted. The patient was fully awake; pupils were normal in size and reacting to light. She was put in supine position with a slight head down tilt and oxygen was given by facemask and later by nasal cannula. Her SpO₂ was 95-96% on room air. She was administered intravenous analgesics and fluids. After few hours the intensity of headache was found to be reduced. CT head was repeated next day which showed complete resorption of patchy pneumocephalus in frontal extraaxial space and anterior basal cistern (Figures 1 and 2). The patient was shifted to room for observation and discharged without any sequelae.

Figure 1. CT Image 1 Showing Air in the Cranium before Treatment

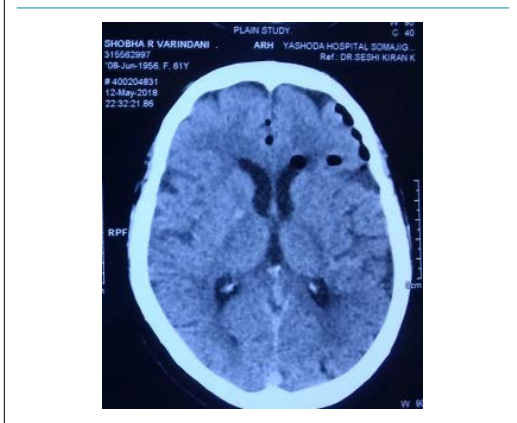
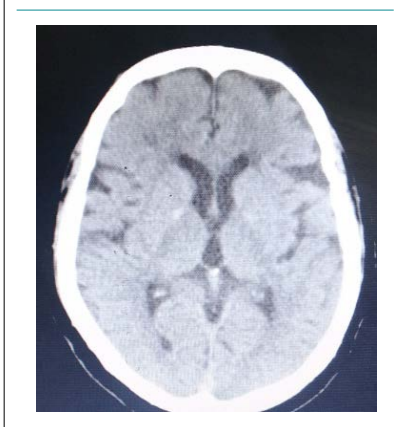


Figure 2. CT Image 2 Air Absorbed After Treatment



DISCUSSION

Pneumocephalus complicates 3.9-9.7% of head trauma cases.¹⁻⁵ It can also occur in the post-operative neurosurgical cases especially the supratentorial surgeries. It was previously seen in posterior fossa surgery in sitting position.^{6,7} Air enters cerebrospinal fluid (CSF) from dural site, with or without direct brain injury.^{8,9} It can be serious if it turns into tension pneumocephalus. Rarely it can lead to meningitis in rare cases.¹⁰⁻¹²

Epidural injection used in anaesthesia practice with loss of resistance technique accidentally injected air into the cranium has happened with failed epidurals.¹³⁻¹⁶ It is described as presence of air within the cranial cavity suggesting an association between the central nervous system and the outer environment which is identified by brain imaging.¹⁷

The differential diagnosis of patients with thunderclap headache should encompass subarachnoid hemorrhage, colloid cyst of third ventricle and intracranial hypotension.

Medical ozone therapy is one of the options for treatment of herniated disc. It exerts analgesia and anti-inflammatory effects.¹⁸ Ozone therapy is given from a specialized machine along with

oxygen at a fixed prepared concentration. It is administered with a polypropylene syringe and given for discolysis which is medical management for disc prolapse. Meta-analysis of many studies on ozone therapy indicated that this treatment is used mostly for patients with herniated discs or failed back syndrome even after surgical intervention. A success rate of 75-80% has been observed. Rare complications are vitreo-retinal hemorrhage, paresthesia associated with spinal nerve damage.¹⁹ Pneumocephalus has been reported in two cases.

Ozone and ozonated growth factors use in the treatment of disc prolapse has been carried out in 60 patients. 150 percutaneous discolysis were performed. Two patients reported pneumocephalus.^{20,21}

CONCLUSION

Thunder clap headache occurs in some cases of neurological abnormalities. Development of pneumocephalus is one of them. The cause of this can be determined by understanding the etiology and including rare causes followed by imaging. Rare events of pneumocephalus after epidural injection are presented. A high degree of suspicion is must in all these rare etiologies.

ACKNOWLEDGEMENTS

We gratefully acknowledge management of the hospital for their valuable support.

CONSENT

The patient has provided written permission for publication of the case details.

CONFLICTS OF INTEREST

The authors declare that they have no conflicts of interest.

REFERENCES

1. Komolafe EO, Faniran E. Tension pneumocephalus – a rare but treatable cause of rapid neurological deterioration in traumatic brain injury: A case report. *Afr J Neurosci.* 2010; 2: 9. doi: [10.4314/ajns.v29i2.70412](https://doi.org/10.4314/ajns.v29i2.70412)
2. Solomiichuk VO, Lebed VO, Drizhdov KI. Posttraumatic delayed subdural tension pneumocephalus. *Surg Neurol Int.* 2013; 4: 37. doi: [10.4103/2152-7806.109537](https://doi.org/10.4103/2152-7806.109537)
3. Chandran TH, Prepageran N, Philip R, Gopala K, Zubaidi AL, Jalaludin MA. Delayed spontaneous traumatic pneumocephalus. *Med J Malaysia.* 2007; 62: 411-412.
4. Cho HL, Han YM, Hong YK. Tension pneumocephalus after transsphenoidal surgery: Report of two cases. *J. Korean Neurosurg. Soc.* 2004; 35: 536-538.

5. Dandy WE. Pneumocephalus (intracranial pneumatocele or arocele). *Arch. Surg.* 1926; 12: 949-982. doi: [10.1001/arch-surg.1926.01130050003001](https://doi.org/10.1001/arch-surg.1926.01130050003001)
6. Pandit UA, Mudge BJ, Keller TS, et al. Pneumocephalus after posterior fossa exploration in the sitting position. *Anaesthesia.* 1982; 37: 996-1001. doi: [10.1111/j.1365-2044.1982.tb01711.x](https://doi.org/10.1111/j.1365-2044.1982.tb01711.x)
7. Nayak PK, Mahapatra AK. Tension pneumocephalus in lateral position following posterior fossa surgery. *Pan Arab J Neurosurg.* 2011; 15: 76-78.
8. Vikram A, Deb AK. Tension pneumocephalus secondary to a dural tear. *Appl. Radiol.* 2011; 40: 37-38.
9. Kozikowski GP, Cohen SP. Lumbar puncture associated with pneumocephalus: Report of case. *Anesth Analg.* 2004; 98: 524-526. doi: [10.1213/01.ANE.0000095153.75625.1F](https://doi.org/10.1213/01.ANE.0000095153.75625.1F)
10. Shaikh N, Masood I, Hanssens Y, Louon A, Hafiz A. Tension pneumocephalus as complication of burr-hole drainage of chronic subdural hematoma: A case report. *Surg Neurol Int.* 2010; 1: 27. doi: [10.4103/2152-7806.65185](https://doi.org/10.4103/2152-7806.65185)
11. Thapa A, Agrawal D. Mount Fuji sign in tension pneumocephalus. *Indian Journal of Neurotrauma.* 2009; 6: 161-163.
12. Vitali AM, le Roux AA. Tension pneumocephalus as a complication of intracranial pressure monitoring: A case report. *Indian Journal of Neurotrauma.* 2007; 4: 115-118. doi: [10.1016/S0973-0508\(07\)80025-6](https://doi.org/10.1016/S0973-0508(07)80025-6)
13. Nolan RB, Manseri DA, Pesce D. Pneumocephalus after epidural injections. *J Emerg Med.* 2008; 25: 416.
14. Katz Y, Markovits R, Rosenberg B. Pneumocephalus after inadvertent intrathecal air injection during epidural block. *Anesthesiology.* 1990; 73: 1277-1279.
15. Katz JA, Lukin R, Bridenbaugh PO, Gunzenhauser L. Subdural intracranial air: An unusual cause of headache after epidural steroid injection. *Anesthesiology.* 1991; 74: 615-617.
16. Ash KM, Cannon JE, Biehl DR. Pneumocephalus following attempted epidural anaesthesia. *Can J Anaesth.* 1991; 38: 772-774. doi: [10.1007/BF03008458](https://doi.org/10.1007/BF03008458)
17. Michel SJ. The Mount Fuji sign. *Radiology.* 2004; 232: 449-450. doi: [10.1148/radiol.2322021556](https://doi.org/10.1148/radiol.2322021556)
18. Gautam S, Rastogi V, Jain A, Singh AP. Comparative evaluation of oxygen-ozone therapy and combined use of oxygen-ozone therapy with percutaneous intradiscal radiofrequency thermocoagulation for the treatment of lumbar disc herniation. *Pain Pract.* 2011; 11: 160-166. doi: [10.1111/j.1533-2500.2010.00409.x](https://doi.org/10.1111/j.1533-2500.2010.00409.x)
19. Magaihaes FN, Dotta L, Sasse A, Teixeira MJ, Fonoff ET. Ozone therapy as a treatment for low back pain secondary to herniated disc: A systemic review and meta-analysis of randomised controlled trials. *Pain Physician.* 2012; 15: 115-129.
20. Toman H1, Özdemir U, Kiraz HA, Lüleci N. Severe headache following ozone therapy: Pneumocephalus. *Agri.* 2017; 29: 132-136. doi: [10.5505/agri.2016.36024](https://doi.org/10.5505/agri.2016.36024)
21. Liu H, Wang Y, An JX, Williams JP, Cope DK. Thunderclap headache caused by an inadvertent epidural puncture during oxygen-ozone therapy for patients with cervical disc herniation. *Chin Med J.* 2016; 129: 498-499.