

Case Report

Corresponding author

Solwayo Ngwenya, MBChB, DFRSH, MRCOG
Consultant Obstetrician and
Gynaecologist
Head of Department of Obstetrics and
Gynaecology
Mpilo Central Hospital, Vera Road;
Mzilikazi Founder and Chief Executive
Officer, Royal Women's Clinic
52A Cecil Avenue, Hillside
Bulawayo, Matabeleland, Zimbabwe
E-mail: drsolvingwe@yahoo.co.uk

Volume 3 : Issue 1

Article Ref. #: 1000GOROJ3130

Article History

Received: June 13th, 2016

Accepted: July 18th, 2016

Published: July 18th, 2016

Citation

Ngwenya S. Placental retention with accreta in a uterine anomaly. *Gynecol Obstet Res Open J.* 2016; 3(1): 16-18. doi: [10.17140/GOROJ-3-130](https://doi.org/10.17140/GOROJ-3-130)

Copyright

©2016 Ngwenya S. This is an open access article distributed under the Creative Commons Attribution 4.0 International License (CC BY 4.0), which permits unrestricted use, distribution, and reproduction in any medium, provided the original work is properly cited.

Placental Retention with Accreta in a Uterine Anomaly

Solwayo Ngwenya, MBChB, DFRSH, MRCOG*

Consultant Obstetrician and Gynaecologist, Head of Department of Obstetrics and Gynaecology, Mpilo Central Hospital, Vera Road; Founder and Chief Executive Officer Royal Women's Clinic, 52A Cecil Avenue, Hillside, Bulawayo, Matabeleland, Zimbabwe

ABSTRACT

A 32 year-old P₁G₂ went into spontaneous labour at 37 weeks gestation. Precipitate labour progressed to a normal vaginal delivery (NVD) of a baby boy within 2 hours of onset. She had a retained placenta. The patient was taken to theatre for an examination under anaesthesia and manual removal of placenta. It was discovered that she had uterine anomaly. A calcified accretic placenta was manually removed. The patient was kept on an oxytocin infusion overnight and given intravenous broad spectrum antibiotics. She made a good recovery and was discharged home after 3 days on oral antibiotics.

KEYWORDS: Retained placenta; Uterine anomalies; Life-threatening; Catastrophic haemorrhage; Reproductive outcomes; Maternal mortality.

INTRODUCTION

A retained placenta is a life-threatening condition as it can cause catastrophic haemorrhage and maternal mortality and morbidity. It complicates 2-3% of vaginal deliveries and causes postpartum haemorrhage. Its management must be prompt and effective. The prevalence of uterine anomalies in the general population is 1:201 (0.50%), the commonest types being septate (34%) and bicornuate (39%) of all cases of uterine anomalies.¹ Congenital uterine anomalies are associated with the highest incidence of reproductive failure and obstetric complications.² There is scanty data on uterine anomalies and retained placenta in the literature. A retained placenta in a rudimentary horn of a double uterus was described by Wilson in 1955.³ It is therefore important to document more cases as to alert clinicians and help save lives.

CASE REPORT

A 32 year-old P₁G₂ went into spontaneous labour at 37 weeks gestation. She had had a normal antenatal period. In her previous obstetric history, she had delivered NVD 8 years ago a baby boy birth weight 3000 g. The couple had struggled to conceive but had not consulted a clinician to undergo any investigations for subfertility. She had no other medical or surgical history.

Precipitate labour progressed to a NVD of a baby boy within 4 hours of onset. The baby's birth weight was 2710 g. The Apgar scores were 8, 9 and 10 at 1, 5 and 10 minutes respectively. The third stage of labor was managed actively by giving oxytocin 10 international unit (IU) at the delivery of the anterior shoulder. Gentle cord traction was attempted but there were no signs of placental separation after 15 minutes. There was minimum bleeding per vagina. An oxytocin infusion of 40 IU in a litre of normal saline was commenced. After 30 minutes post-delivery, there were still no signs of placental separation. Another attempt at gentle cord traction led to the cord snapping.

The patient was taken to theatre for an examination under anaesthesia and manual removal of placenta. There were second degree tears in the vulva and the cervical cervix or cervical os had contracted significantly. On insertion of the hand, it went right into the fundus

and no placenta was felt. The empty cavity was roomy. While moving the hand inside a second opening was felt (Figure 1). This was a case of uterine anomaly only detected in theatre. The newly discovered uterine cavity went right up to the costal margin. There at the fundus an accretic placenta was found. The placenta was sheared off and manually removed. It was a calcified placenta. The second degree tears were repaired. The patient was kept on an oxytocin infusion overnight and given intravenous broad spectrum antibiotics. She made a good recovery and was discharged home after 3 days on oral antibiotics.

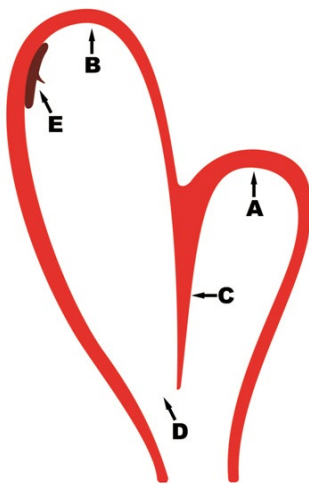


Figure 1: Showing the clinical impression of what was discovered in theatre during examination under anaesthesia. The hand first went into the fundus of the left uterine horn (A), there was a septum (C) another opening (D) was discovered leading the fundus of the right uterine horn (B). The placenta was found high up (E), accretic in the right uterine horn.

DISCUSSION

Retained placenta poses great danger to maternal health as it can lead to catastrophic haemorrhage, the risk is even higher with an adherent placenta. Prenatal diagnosis of abnormal placentation allows anticipation of multidisciplinary team⁴ management that prevents adverse outcomes. It is important that it is recognized early and prompt steps taken to have it manually removed under anaesthesia. An association of a retained placenta and uterine anomaly has not been described in the literature hence this case is to highlight this association. Uterine morphology can be ascertained outside pregnancy by hysterosalpingography and laparoscopy.⁵ Magnetic resonance imaging (MRI) can also be a useful tool to diagnosis. Some uterine anomalies may permit normal obstetric outcomes.⁵

Women with congenital uterine malformations usually have higher incidence of subfertility and complications during pregnancy and delivery.⁶ The risks include preterm pre-labour rupture of membranes, small for gestational age babies and preterm delivery.^{7,8} There are also risks of malpresentation and caesarean section (C-section) delivery,⁷ and rupture of rudimentary uterine horn.⁹ The complication of a retained placenta in uterine horn is not described in the literature. Uterine anomalies are associated with both normal and adverse reproductive outcomes.¹⁰

CONCLUSION

This case reminds clinicians of rare clinical associations that lurk underneath the surface undetected and yet pose significant danger to maternal health. When faced with unusual clinical findings, clinicians must explore other areas that may lead to the discovery of unexpected pathology. This can be life-saving.

REFERENCES

1. Nahum GG. Uterine anomalies: How common are they, and what is their distribution among subtypes? *J Reprod Med.* 1998; 43(10): 877-887. Web site. <http://europepmc.org/abstract/med/9800671>. Accessed June 12, 2016
2. Zhang Y, Zhao YY, Qiao J. Obstetric outcome of women with uterine anomalies in China. *Chin Med J (Engl).* 2010; 123(4): 418-422. Web site. http://124.205.33.103:81/ch/reader/view_abstract.aspx?file_no=201022059246370&flag=1. Accessed June 12, 2016
3. Wilson TM. Retained placenta incarcerated in the rudimentary horn of a double uterus. *Am J Obstet Gynecol.* 1955; 70(3): 669-671. Web site. <http://www.ncbi.nlm.nih.gov/pubmed/13238517>. Accessed June 12, 2016
4. Rao KP, Belogolovkin V, Yankowitz J, Spinnato JA. Abnormal placentation: Evidence-based diagnosis and management of placenta previa, placenta accrete, and vasa previa. *Obstet Gynecol Surv.* 2012; 67(8): 503-519. doi: 10.1097/OGX.0b013e3182685870
5. Raga F, Bauset C, Remohi J, Bonilla-Musoles F, Simon C, Pellicer A. Reproductive impact of congenital mullerian anomalies. *Hum Reprod.* 1997; 12(10): 2277-2281. doi: 10.1093/hum-rep/12.10.2277
6. Ma S, Bian X, Lang J. Pregnancy and its outcome in women with malformed uterus. *Zhonghua Yi Xue Za Zhi.* 2001; 81(7): 415-417. Web site. <http://europepmc.org/abstract/med/11798909>. Accessed June 12, 2016
7. Hirsch L, Yeoshoua E, Miremberg H, et al. The association between mullerian anomalies and short-term pregnancy outcome. *J Matern Fetal Neonatal Med.* 2016; 29(16): 2573-2578. doi: 10.3109/14767058.2015.1098613
8. Hua M, Odibo AO, Longman RE, Macones GA, Roehl KA, Cahill AG. Congenital uterine anomalies and adverse pregnancy outcomes. *Am J Obstet Gynecol.* 2011; 205(6): 558.e1-558.e5. doi: 10.1016/j.ajog.2011.07.022
9. Pal K, Majumdar S, Mukhopadhyay S. Rupture of rudimentary uterine horn pregnancy at 37 weeks gestation with fetal survival. *Arch Gynecol Obstet.* 2006; 274(5): 325-326. doi: 10.1007/s00404-006-0170-y

10. Rackow BW, Arici A. Reproductive performance of women with mullerian anomalies. *Curr Opin Obstet Gynecol.* 2007; 19(3): 229-237. doi: [10.1097/GCO.0b013e32814b0649](https://doi.org/10.1097/GCO.0b013e32814b0649)