

Review

Corresponding author*Vasantha H.S. Kumar, MD**

Clinical Associate Professor
 Department of Pediatrics
 Division of Neonatology
 The Women & Children's Hospital of
 Buffalo
 University at Buffalo
 219 Bryant Street, Buffalo
 NY 14222-2006, USA
 Tel. +1 716 878 7673
 Fax: +1 716 878 7945
 E-mail: vkumar@upa.chob.edu

Volume 2 : Issue 2

Article Ref. #: 1000PNNOJ2110

Article HistoryReceived: July 6th, 2015Accepted: July 24th, 2015Published: July 27th, 2015**Citation**

Kumar VHS. Pathogenesis and management of retinopathy of prematurity in premature infants. *Pediatr Neonatal Nurs Open J.* 2015; 2(2): 62-69. doi: [10.17140/PNNOJ-2-110](https://doi.org/10.17140/PNNOJ-2-110)

Copyright

©2015 Kumar VHS. This is an open access article distributed under the Creative Commons Attribution 4.0 International License (CC BY 4.0), which permits unrestricted use, distribution, and reproduction in any medium, provided the original work is properly cited.

Pathogenesis and Management of Retinopathy of Prematurity in Premature Infants

Vasantha H.S. Kumar, MD*

Clinical Associate Professor, Department of Pediatrics, Division of Neonatology, The Women & Children's Hospital of Buffalo, University at Buffalo, 219 Bryant Street, Buffalo, NY 14222-2006, USA

ABSTRACT

Retinopathy of Prematurity (ROP) continues to be a major cause of preventable blindness in considerable parts of the world, including developing countries. The incidence of ROP varies with the level of neonatal care; adequate screening and follow-up of these infants is essential for intervention to occur at the appropriate time. Even though the pathophysiology is not certain, oxygen and its interaction with angiogenic factors plays a central role in the development of the disease. Despite the role of oxygen in the pathogenesis of ROP, optimal oxygen saturation in the first few weeks of life in the premature infant remains unclear. Current treatment strategies include ablation of the peripheral avascular retina, management of abnormal vasoproliferation in late stages of disease and visual rehabilitation. A team effort involving neonatologists, ophthalmologists and excellent nursing care will go a long way in not only decreasing the incidence of ROP but also in building a strong screening and follow-up program, which is critical in the management of these patients.

KEYWORDS: ROP; Prematurity; VEGF; O₂ Saturation; Neonate.

ABBREVIATIONS: ROP: Retinopathy of Prematurity; NeOProm: Neonatal Oxygenation Prospective Meta-analysis Study; BOOST: Benefits of Oxygen Saturation Targeting; STOP-ROP: Supplemental Therapeutic Oxygen for Prethreshold Retinopathy of Prematurity; VEGF-A: Vascular Endothelial Growth Factor A; BEAT-ROP: Bevacizumab Eliminates the Angiogenic Threat of Retinopathy of Prematurity; PROP-ROP Propranolol in Newborns with Retinopathy of Prematurity; PUFAs: Poly Unsaturated Fatty Acids; EPA: Eicosapentaenoic acid; DHA: Docosahexaenoic acid; AA: Arachidonic acid; VEGF: Vascular Endothelial Growth Factor; IGF-1: Insulin Growth Factor-1; SUPPORT: Surfactant, Positive Airway Pressure, Pulse Oximetry Randomized Trial; COT: Canadian Oxygen Trial; ET-ROP: Early Treatment for Retinopathy of Prematurity.

INTRODUCTION

Retinopathy of prematurity (ROP) is a leading cause of preventable blindness worldwide, associated with abnormal retinal vascular development that occurs only in premature infants. Low birth weight and prematurity are strongly associated with an increased disease risk. The incidence of ROP in the United States is 68% in premature infants weighing <1251 grams; among the affected, severe ROP developed in almost 37% of the infants.¹ The incidence of premature births is increasing throughout the world, and with it, ROP is now appearing in countries with the technology to save premature infants. Consequently ROP has become a leading cause of childhood blindness worldwide.² The management of ROP include screening of at-risk preterm infants by frequent retinal examinations followed by treatment interventions if necessary, such as laser treatment of the peripheral avascular retina in eyes with severe ROP and visual rehabilitation.³

PATHOGENESIS

The pathogenesis of ROP is related to disruption of normal retinal neuronal and vascular development. The inner parts of the eye including the retina are supported metabolically by the hyaloid vasculature in the first trimester and retina remains avascular during this period.⁴ However, the switch from hyaloid to retinal vasculature begins at around 16 weeks of gestation with the development of the vascular plexus beginning at the optic nerve head and spreading centrifugally. Retinal vessels growing out of the optic nerve head reach the ora serrata nasally at approximately 32 week gestation and temporally by 2 months of postnatal age.⁵ As glial cells such as the astrocytes cover much of the retina during development, they may act as a template for endothelial cell migration to occur promoting vasculogenesis. This is facilitated by the release of growth factors such as Vascular Endothelial Growth Factor (VEGF) from the astrocytes and retinal ganglion cells in the presence of hypoxic *in utero* environment. Tissue hypoxic gradients generated in the retina facilitate the formation of endothelial tubes and blood vessels centrifugally from the optic nerve under the influence of VEGF and other factors such as Insulin Growth Factor-1 (IGF-1).^{3,4} After premature birth, disruption of normal angiogenesis and vascularization of the retina occur secondary to reduced VEGF and IGF-1 in the retinal tissue due to relative hyperoxia resulting in vaso-obliteration (Figure 1). This is followed by relative ischemia and tissue hypoxia secondary to growth and high metabolic rates of the underlying neurons such as astrocytes and the retinal ganglion cells. Retinal tissue hypoxia will eventually produce high levels of VEGF and other growth factors ultimately leading to the vasoproliferative phase of ROP characterized by pathologic vascularization beginning at 32-34 weeks gestational age.^{3,4} Pathologic vascularization is dysregulated as aberrant vessels grow into the vitreous; they are excessive and of minimal

function to the avascularized retina. Normal retinal development driven by hypoxic tissue gradients is at first disrupted resulting in dysregulated angiogenesis and this is followed by abnormal vascular development culminating in ROP. Of the many risk factors for ROP, low birth weight and lower gestational age are the most important risk factors. Other factors include extremely low birth weight, duration of ventilation,⁶ high volume of blood transfusion⁷ and candida sepsis.⁸

OXYGEN SUPPLEMENTATION & RETINOPATHY OF PREMATURITY

Supplemental oxygen exposure, an important risk for the development of ROP in premature infants has been extensively studied. Historical role of oxygen in the pathogenesis of ROP has been confirmed by clinical trials, demonstrating definitively the relationship between elevated oxygen and ROP and further that, by restricting supplemental oxygen use, could lead to increased mortality.⁹⁻¹¹ Pulse oximetry monitors oxygenation in infants non-invasively and continuously in infants, allowing titration of inspired oxygen to maintain desired oxygen saturations (SpO₂). In one of the earlier studies, higher SpO₂ (88-98%) in the first 8 weeks of life in infants born between 24 to 28 weeks gestational age, had four times higher rates of surgery for ROP compared to lower SpO₂ (70-90%) group.¹² In a meta-analysis of five studies by Chen, et al. the relative risk for ROP was significantly lower in the lower saturation (70-96%) group.¹³ However, the conclusion was confounded by the studies not being randomized and being mostly retrospective. The Surfactant, Positive Airway Pressure, Pulse Oximetry Randomized Trial (SUPPORT), assigned infants born between 24 weeks and 28 weeks gestation to low O₂ saturations (85-89%) or high O₂ saturations (91-95%) within one hour of birth. Severe ROP occurred less frequently in the lower O₂ saturations group;

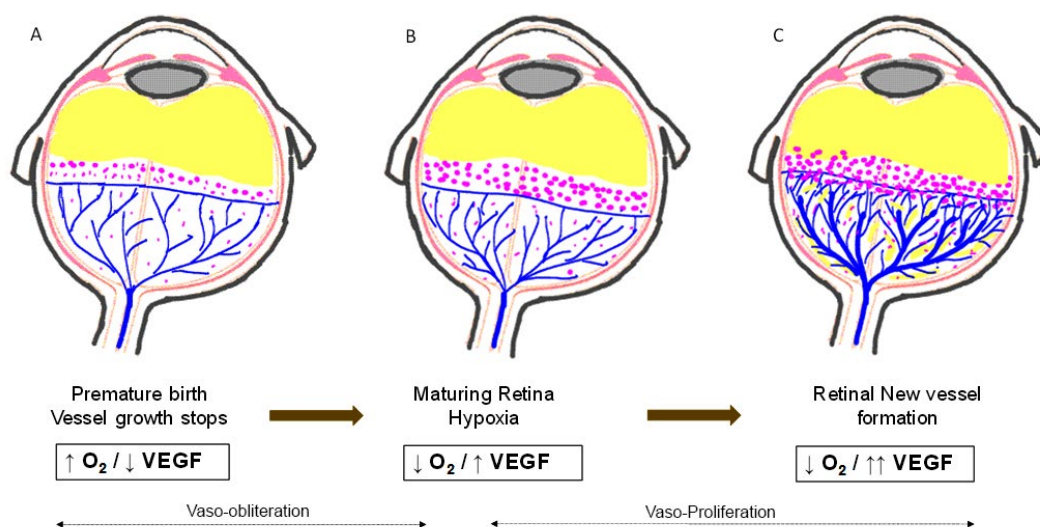


Figure 1: Pathogenesis of Retinopathy of Prematurity (ROP). The figure illustrates the interactions of oxygen and angiogenic factors, particularly vascular endothelial growth factor (VEGF) in the development of ROP. Vessel growth stops following birth due to relative hyperoxia in premature neonates resulting in decreased VEGF (A); this is followed by pathological hypoxia inducible factor (HIF) signaling and increasing VEGF over time from hypoxia (B) resulting in retinal new vessel formation and stage III ROP by 36 weeks gestation (C). Multiple other factors are involved in the development of retinal vasculature including Insulin growth factor (IGF-1) and other cell signaling molecules.

however death occurred more frequently in the lower saturation group (RR-1.27; CI: 1.01-1.60), raising concerns for practical implications.¹⁴ Two other trials have also published the data as part of the NeOProm (Neonatal Oxygenation Prospective Meta-analysis Study) collaboration initiative. The Benefits of Oxygen Saturation Targeting (BOOST) II assessed 1224 infants with similar study design. The incidence of ROP were lower in the pooled data for the lower O₂ saturation group (RR-0.79; CI: 0.63-1.00) with the higher incidence of death in the same saturation group (Revised algorithm – RR-1.45; CI: 1.15-1.84).¹⁵ The Canadian Oxygen Trial (COT) with similar study design did not demonstrate significant difference in death or disability at 18 months or in secondary outcome measures such as ROP or brain injury.¹⁶ These studies suggest that targeting SpO₂ of 91-95% is reasonable in the first few weeks of life, and that would decrease death, however it might increase the risk for ROP and high saturations in the first few weeks do not worsen neuro-developmental outcome. It was hypothesized from animal studies that oxygen supplementation during the disease process would reduce the severity of ROP by reducing the hypoxia induced release of angiogenic factors believed to be responsible for the vasoproliferation seen in severe ROP.^{17,18} This hypothesis was tested in the Supplemental Therapeutic Oxygen for Prethreshold Retinopathy of Prematurity (STOP-ROP) study, wherein infants supplemented with oxygen to maintain higher saturations (96-98%) were compared to 89-94% SpO₂ group and assessed for progression to threshold ROP.¹⁹ These infants had a mean gestational age of 35.4 weeks and had pre-threshold ROP at enrollment. Supplemental oxygen did not decrease significantly the number of infants with pre-threshold ROP progressing to threshold ROP requiring treatment. However, in the subset of infants without plus disease, fewer infants progressed to threshold in the oxygen supplemented group. Also higher rate of pulmonary complications were noted in the oxygen supplemented group.

CLASSIFICATION OF ROP

The severity of acute ROP is determined by the zone, presence or absence of plus disease, the stage and the clock-hour extent of the worst stage of the disease (Figure 2).²⁰

Zones

Zone I: This represents the least amount of retinal vascular development and includes retinal vascularization limited to a circular area centered on the optic nerve. The radius is equivalent to two times the distance from the optic nerve to the fovea. *Zone I ROP is a strong predictor for severe ROP* and can be estimated visually with indirect ophthalmoscopy.

Zone II: Vascularization limited to the circular area outside zone I with the optic nerve as the center. Its radius is equivalent to the distance from the optic nerve to the nasal horizontal oraserrata.

Zone III: Vascularization within the remaining temporal, crescent-shaped area. Once vascularization extends to the nasal oraserrata and into zone III, there is little risk of a poor visual outcome from ROP.

Plus Disease

Defined as two quadrants of dilated and tortuous vessels and is a strong predictor of severe ROP.

Stages of ROP

Stage 1: A demarcation line between vascularized and avascular retina.

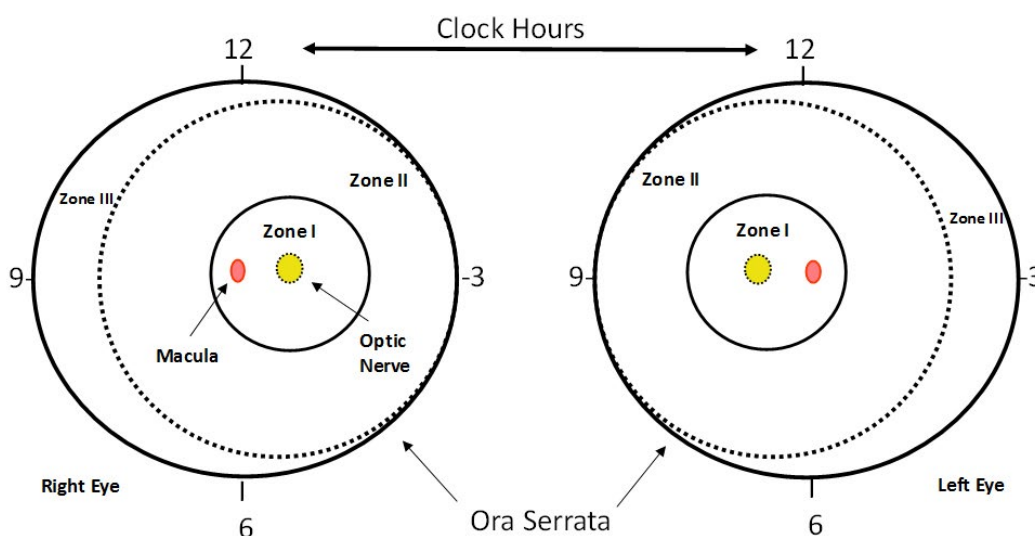


Figure 2: Scheme of retina of the right and left eyes demonstrating zone borders and clock hours used to describe the location and extent of ROP. Diagrammatic representation of the potential total area of the premature retina, with zone 1 (most posterior) symmetrically surrounding the optic nerve-head (the earliest to develop). A larger retinal area is present temporally (laterally) rather than nasally (medially) (zone II). Only zones I and II are present nasally.

Stage 2: A ridge with volume in the region of the demarcation line.

Stage 3: Neovascularization growing into the vitreous at the ridge. Stage 3 is a strong predictor of severe ROP and a poor outcome.

Stage 4: A partial retinal detachment. Treatment of progressive stage 4 ROP can preserve and improve visual outcomes by preventing stage 5 ROP.

Stage 4 is further classified by whether the macula is involved (4A without macular involvement and 4B with macular involvement) and by whether it is predominantly exudative or tractional. Exudative ROP that occurs after treatment with laser or cryotherapy may resolve spontaneously.

Stage 5: Total retinal detachment.

Prethreshold and Threshold Disease

- **Prethreshold ROP, Type 1:** Zone I, any stage with plus disease; zone I, stage 3 without plus disease; zone II, stage 2 or 3 with plus disease.
- **Prethreshold ROP, Type 2:** Zone I, stage 1 or 2 without plus disease; zone II, stage 3 without plus disease.
- **Threshold ROP:** Zone I or II, stage 3 (five contiguous or eight total clock hours with plus disease).

SCREENING FOR ROP

The progressive nature of the ROP demands that timely treatment is essential in reducing the risk of visual loss. Effective care now requires that at-risk infants receive carefully timed retinal examinations by an ophthalmologist who is experienced in the examination of preterm infants for ROP on a scheduled basis according to their gestational age at birth and their subsequent disease severity and that all pediatricians who care for these at-risk preterm infants be aware of this schedule.²¹ Because unchecked ROP can lead to permanent blindness, it is important that all infants be screened in a timely fashion, recognizing that not all infants require treatment. It is important to recognize that screening parameters vary in countries across the globe.

1. Infants with a birth weight of ≤ 1500 grams or $GA \leq 30$ weeks and selected infants with a birth weight between 1500-2000 grams or $GA > 30$ weeks with an unstable clinical course, including those requiring cardiorespiratory support are at high risk for ROP and should have retinal screenings performed.
2. The initiation of acute-phase ROP screening should be based on the infant's postmenstrual age. The onset of seri-

ous ROP correlates better with postmenstrual age (gestational age at birth plus chronologic age) rather than with postnatal age. That is, the more premature the infant at birth, the longer it takes to develop serious ROP. Table 1 shows the timing of first eye exam based on gestational age at birth.

3. Infants born before 25 weeks GA should be considered for earlier screening on the basis of severity of co-morbidities (6 weeks chronological age), to enable earlier identification and treatment of aggressive posterior ROP that is more likely to occur in this population.
4. Follow up exams are recommended on the basis of retinal findings as per the international classification and the schedule is outlined by the AAP.²¹
5. Plus disease is defined as abnormal dilation and tortuosity of the posterior retinal blood vessels in 2 or more quadrants of the retina in zones I or II. Presence of plus disease suggests that peripheral ablation, rather than observation, is the most appropriate therapy.
6. ROP treatment should be initiated for the following retinal findings – Zone I ROP of any stage with plus disease; Zone I ROP: stage 3 – no plus disease; Zone II: stage 2 or 3 ROP with plus disease.

Gestational Age at Birth (Wks)	Age at Initial Exam (Weeks)	
	Postmenstrual Age	Chronological Age
22 ^a	31	9
23 ^a	31	8
24	31	7
25	31	6
26	31	5
27	31	4
28	32	4
29	33	4
30	34	4
Older GA; high risk factors ^b		4

^aThis guideline should be considered tentative rather than evidence based for infants with a gestational age of 22 to 23 wk because of the small number of infants of survivors in these post menstrual age categories.

^bConsider the timing on severity of comorbidities

Table 1: Timing of first eye examination based on Gestational age at birth.²¹

MANAGEMENT OF ROP

The practicality of performing screening exams and rigorous follow-up is difficult in the best of circumstances and the hurdles to effective screening in developing countries can only increase, as they are difficult to perform and the *treatment 'window' for intervention is brief – within 2 to 3 days of decision to treat*. Management includes screening with a dilated fundus examination, treatment of acute severe ROP with ablation of the

peripheral avascular retina, surgery for tractional retinal detachment resulting from progressive stage 4 or stage 5 ROP and visual rehabilitation.

CRYO-THERAPY & PHOTOCOAGULATION (LASER)

Trans-scleral cryotherapy to the avascular peripheral retina of premature infants with ROP has been used clinically since 1970's. For the first time in 1988, the preliminary results of the Multicenter Trial of Cryotherapy for Retinopathy of Prematurity (CRYO-ROP) demonstrated that cryotherapy is effective in reducing ROP-induced blindness.²² The follow-up of the CRYO-ROP study cohort has shown that the beneficial effect of cryotherapy is maintained long-term; however 10 years after treatment 45.4% of the treated eyes had a visual acuity of 20/200 or worse.²³ Since then, laser photo-coagulation has gained widespread acceptance and has largely replaced cryotherapy and is currently the standard of care for the treatment of ROP. In a randomized trial, at 5.8 years of follow-up, the odds that an eye treated with laser had a good clinical outcome were 6.91 times greater than for eyes treated with cryotherapy. Additionally, the laser-treated eyes were less myopic with a mean SE of -3.05 diopters compared to a mean SE of -5.08 diopters for the cryotherapy-treated eyes. The study concluded that laser photocoagulation for threshold ROP was more likely to result in a good clinical outcome with better final visual acuity and less myopia compared to cryotherapy treatment.²⁴

The indication for treatment in CRYO-ROP was threshold ROP, when the risk for blindness was 50%. *Threshold was defined as 5 or more continuous or 8 cumulative clock hours of stage 3 ROP in zone I or zone II in the presence of plus disease (dilation and tortuosity of posterior pole retinal vessels in at least two quadrants).* This remained unchanged for 15 years until the Early Treatment for Retinopathy of Prematurity (ET-ROP) study in 2003, which concluded that early treatment of high-risk pre-threshold ROP significantly reduced unfavourable outcomes to a clinically important degree.²⁵ The preliminary report of the ETROP identifies characteristics that predict which eyes are most likely to benefit from early peripheral retinal ablation. As per the clinical algorithm, peripheral retinal ablation should be considered for any eye with *type 1 ROP* – Zone I, any stage of ROP with plus disease; Zone I, stage 3 ROP, with/without plus disease; Zone II, stage 2 or 3 ROP with plus disease. Plus disease requires at least 2 quadrants (6 or more clock hours) of dilation and tortuosity of the posterior retinal vessels and the presence of significant disease. The algorithm also indicates that *continued serial exams are indicated as opposed to treatment for any of the type 2 ROP* – Zone 1, stage 1 or 2 ROP without plus disease; Zone II, stage 3 ROP without plus disease. *The presence of plus disease (retinal arteriolar tortuosity and venous congestion) is one of the key differences between type 1 and type 2 pre-threshold ROP as defined by ETROP that requires treatment.* Treatment should be considered for an eye with type 2 ROP when progression to type 1 status or threshold ROP occurs.²⁵

ANTI VEGF TREATMENT

Bevacizumab (Avastin, Genentech/Roche, San Francisco, CA) is a 150-kD, recombinant humanized monoclonal immunoglobulin G1 antibody that binds to all isoforms of Vascular Endothelial Growth Factor A (VEGF-A). The advantage of bevacizumab is its inability to cross the blood retina barrier due to the relatively large size of the molecule and hence may decrease systemic complications. Case reports have demonstrated its benefits in the regression of stage 3/zone I ROP with no adverse events.

The largest study examining the use of anti-VEGF therapy to date is the Bevacizumab Eliminates the Angiogenic Threat of Retinopathy of Prematurity (BEAT-ROP) Trial.²⁶ This study enrolled 150 infants with Zone I or Zone II posterior stage 3 ROP and randomly assigned each to receive bilateral intravitreal bevacizumab (0.625 mg) or laser photocoagulation with a primary outcome measure being need for retreatment before 54 weeks GA. The rate of recurrence in Zone I disease was significantly higher with laser therapy (42% recurrence rate) than with intravitreal bevacizumab (6% recurrence rate). In contrast, a difference in the recurrence rate noted between Zone II disease treated with laser therapy (12% recurrence) versus intravitreal bevacizumab (5%) did not reach statistical significance suggesting that it may be used in the treatment of zone I disease.

Bevacizumab has to be used with caution in selected patients as the study does not address some of the concerns of the medication including safety issues. Complications of bevacizumab related to intravitreal injection include endophthalmitis, retinal hemorrhage, cataracts and retinal detachment. The drug has to be given at the right time, as, if given too late may lead to retinal detachment. Knowledge of the anatomy of the eye in a premature infant is essential to give an injection safely. Although the potential systemic effects of intravitreal bevacizumab use in preterm infants are of greatest concern and they are hardest to determine.

INSULIN GROWTH FACTOR-1 (IGF-1)

IGF-1 and VEGF interactions have been proposed to mediate endothelial cell survival and proliferation and by extension control blood vessel development in infants. Specifically, IGF-1 is likely necessary for VEGF signaling, most likely through the stimulation of the mitogen-activated protein kinase pathway.²⁷ A current clinical trial investigating the administration of IGF-1 to preterm infants is under way to determine if restoring *in utero* levels of the protein can prevent ROP through normalizing vascular growth in phase I (vaso-obliteration) and thus circumvent the pathologic neovascularization of phase II (vaso-proliferation).²⁸

PROPRANOLOL

Propranolol, a non-selective β -adrenergic blocker has been used in the treatment of infantile hemangiomas for its ability to reduce VEGF and hence vascularization. As hypoxia induced neovascularization may be mediated through the β -adrenergic receptor, propranolol is now being evaluated in the treatment of ROP. In mouse models of ROP, propranolol reduced VEGF production only in the hypoxic retina of mice without affecting VEGF levels in normoxic retina of control mice, suggesting distinct mechanisms of VEGF regulation in normoxic and hypoxic conditions.²⁹ In a pilot study, oral propranolol (0.25 mg/kg q6 or 0.5 mg/kg q6) added to standard treatment in infants with stage 2/zone 2 ROP was effective in reducing the progression of ROP compared to standard treatment alone, however safety was a concern.³⁰ The Propranolol in Newborns with Retinopathy of Prematurity (PROP-ROP) clinical trial is currently underway to evaluate the effectiveness of propranolol in infants with stage 2 ROP in zone II/III without plus disease.³¹ The primary goal of this study is to evaluate the safety of the drug including side effects such as bradycardia, hypoglycemia, hypotension and dyslipidemia.

POLYUNSATURATED FATTY ACIDS

The retina requires ω -3 long chain Poly Unsaturated Fatty Acids (PUFAs) for normal structure and function and has the highest concentration of these fatty acids of all bodily tissues. The major PUFA found in the retina are Eicosapentaenoic acid (EPA) the precursor to Docosahexaenoic acid (DHA) and Arachidonic acid (AA) found primarily in neural and vascular cell membranephospholipids.³² Emerging knowledge of lipid mediators and epidemiologic data linking PUFA and neovascular age-related macular degeneration indicate that EPA, DHA and AA may function *in vivo* to regulate retinal vaso-obliteration and neovascularization.^{32,33} Premature infants lack the essential transfer of ω -3-PUFA from the mother to the infant that normally occurs in the third trimester of pregnancy and total parental nutrition fail to compensate for the losses that occur from *in utero* transfer. In a recent study in mice, increasing ω -3-PUFA tissue levels decreased the avascular area of the retina by increasing vessel regrowth after injury, thereby reducing the hypoxic stimulus for neovascularization.³⁴ The bioactive ω -3-PUFA-derived mediators' neuroprotectinD1, resolvinD1 and resolvinE1 protected against neovascularization and the protective effect of ω -3-PUFAs and their mediators was mediated in part, through suppression of tumor necrosis factor- α .³⁴ Supplementing ω -3-PUFA may be of benefit in preventing retinopathy and clinical trials to examine the effect of supplementing neonatal diet with ω -3-PUFA are being investigated.

CONCLUSIONS

New pharmacologic interventions are on the horizon and are only expanding. However, the treatments need to be

studied in rigorous clinical trials so that safety concerns are addressed before put into practice in premature neonates. In the meantime, sick premature infants between 32 weeks and 44 weeks gestational age are to be followed very closely as they at risk for ROP and need immediate treatment if necessary.

CONFLICTS OF INTEREST

The authors declare that they have nothing to disclose.

REFERENCES

1. Good WV, Hardy RJ, Dobson V, et al. The incidence and course of retinopathy of prematurity: findings from the early treatment for retinopathy of prematurity study. *Pediatrics*. 2005; 116(1): 15-23. doi: [10.1542/peds.2004-1413](https://doi.org/10.1542/peds.2004-1413)
2. Gilbert C. Retinopathy of prematurity: a global perspective of the epidemics, population of babies at risk and implications for control. *Early human development*. 2008; 84(2): 77-82.
3. Hartnett ME, Penn JS. Mechanisms and management of retinopathy of prematurity. *N Engl J Med*. 2012; 367(26): 2515-2526. doi: [10.1056/NEJMra1208129](https://doi.org/10.1056/NEJMra1208129)
4. Fruttiger M. Development of the retinal vasculature. *Angiogenesis*. 2007; 10(2): 77-88. [10.1007/s10456-007-9065-1](https://doi.org/10.1007/s10456-007-9065-1)
5. Ashton N. Retinal angiogenesis in the human embryo. *British medical bulletin*. 1970; 26(2): 103-106.
6. Shah VA, Yeo CL, Ling YL, Ho LY. Incidence, risk factors of retinopathy of prematurity among very low birth weight infants in Singapore. *Annals of the Academy of Medicine, Singapore*. 2005; 34(2): 169-178.
7. Dani C, Reali MF, Bertini G, Martelli E, Pezzati M, Rubaltelli FF. The role of blood transfusions and iron intake on retinopathy of prematurity. *Early human development*. 2001; 62(1): 57-63. doi: [10.1016/S0378-3782\(01\)00115-3](https://doi.org/10.1016/S0378-3782(01)00115-3)
8. Mittal M, Dhanireddy R, Higgins RD. Candida sepsis and association with retinopathy of prematurity. *Pediatrics*. 1998; 101(4 Pt 1): 654-657.
9. Kinsey VE. Retrolental fibroplasia; cooperative study of retrolental fibroplasia and the use of oxygen. *AMA archives of ophthalmology*. 1956; 56(4): 481-543.
10. Lanman JT, Guy LP, Dancis J. Retrolental fibroplasia and oxygen therapy. *Journal of the American Medical Association*. 1954; 155(3): 223-226. [10.1001/jama.1954.03690210001001](https://doi.org/10.1001/jama.1954.03690210001001)
11. Patz A, Hoeck LE, De La Cruz E. Studies on the effect of high oxygen administration in retrolental fibroplasia. I. Nursery

- observations. *American journal of ophthalmology*. 1952; 35(9): 1248-1253.
12. Tin W, Milligan DW, Pennefather P, Hey E. Pulse oximetry, severe retinopathy, and outcome at one year in babies of less than 28 weeks gestation. *Archives of disease in childhood Fetal and neonatal edition*. 2001;84(2): F106-F110. doi: [10.1136/fn.84.2.F106](https://doi.org/10.1136/fn.84.2.F106)
13. Chen ML, Guo L, Smith LE, Dammann CE, Dammann O. High or low oxygen saturation and severe retinopathy of prematurity: a meta-analysis. *Pediatrics*. 2010; 125(6): e1483-e1492. doi: [10.1542/peds.2009-2218](https://doi.org/10.1542/peds.2009-2218)
14. Network SSGotEKSNNR, Carlo WA, et al. Target ranges of oxygen saturation in extremely preterm infants. *N Engl J Med*. 2010; 362(21): 1959-1969. doi: [10.1056/NEJMoa0911781](https://doi.org/10.1056/NEJMoa0911781)
15. Group BIUKC, Group BIAC, Group BINZC, et al. Oxygen saturation and outcomes in preterm infants. *N Engl J Med*. 2013; 368(22): 2094-2104. doi: [10.1056/NEJMoa1302298](https://doi.org/10.1056/NEJMoa1302298)
16. Schmidt B, Whyte RK, Asztalos EV, et al. Effects of targeting higher vs lower arterial oxygen saturations on death or disability in extremely preterm infants: a randomized clinical trial. *JAMA: the journal of the American Medical Association*. 2013; 309(20): 2111-2120. doi: [10.1001/jama.2013.5555](https://doi.org/10.1001/jama.2013.5555)
17. Phelps DL. Reduced severity of oxygen-induced retinopathy in kittens recovered in 28% oxygen. *Pediatr Res*. 1988; 24(1): 106-109. doi: [10.1203/00006450-198807000-00024](https://doi.org/10.1203/00006450-198807000-00024)
18. Phelps DL, Rosenbaum AL. Effects of marginal hypoxemia on recovery from oxygen-induced retinopathy in the kitten model. *Pediatrics*. 1984; 73(1): 1-6.
19. The STOP-ROP Multicenter Study Group. Supplemental Therapeutic Oxygen for Prethreshold Retinopathy Of Prematurity (STOP-ROP), a randomized, controlled trial. I: primary outcomes. *Pediatrics*. 2000; 105(2): 295-310.
20. International Committee for the Classification of Retinopathy of Prematurity. An international classification of retinopathy of prematurity. The Committee for the Classification of Retinopathy of Prematurity. *Archives of ophthalmology*. 1984; 102(8): 1130-1134. doi: [10.1001/archophth.1984.01040030908011](https://doi.org/10.1001/archophth.1984.01040030908011)
21. Fiererson WM, American Academy of Pediatrics Section on O, American Academy of O, American Association for Pediatric O, Strabismus, American Association of Certified O. Screening examination of premature infants for retinopathy of prematurity. *Pediatrics*. 2013; 131(1): 189-195. doi: [10.1542/peds.2012-2996](https://doi.org/10.1542/peds.2012-2996)
22. Multicenter trial of cryotherapy for retinopathy of prematurity. Preliminary results. Cryotherapy for Retinopathy of Prematurity Cooperative Group. *Archives of ophthalmology*. 1988; 106(4): 471-479.
23. Cryotherapy for Retinopathy of Prematurity Cooperative G. Multicenter Trial of Cryotherapy for Retinopathy of Prematurity: ophthalmological outcomes at 10 years. *Archives of ophthalmology*. 2001; 119(8): 1110-1118.
24. Connolly BP, McNamara JA, Sharma S, Regillo CD, Tasman W. A comparison of laser photocoagulation with trans-scleral cryotherapy in the treatment of threshold retinopathy of prematurity. *Ophthalmology*. 1998;105(9): 1628-1631. doi: [10.1016/S0161-6420\(98\)99029-7](https://doi.org/10.1016/S0161-6420(98)99029-7)
25. Early Treatment For Retinopathy Of Prematurity Cooperative G. Revised indications for the treatment of retinopathy of prematurity: results of the early treatment for retinopathy of prematurity randomized trial. *Archives of ophthalmology*. 2003; 121(12): 1684-1694. doi: [10.1001/archophth.121.12.1684](https://doi.org/10.1001/archophth.121.12.1684)
26. Mintz-Hittner HA, Kennedy KA, Chuang AZ, Group B-RC. Efficacy of intravitreal bevacizumab for stage 3+ retinopathy of prematurity. *N Engl J Med*. 2011; 364(7): 603-615. doi: [10.1056/NEJMoa1007374](https://doi.org/10.1056/NEJMoa1007374)
27. Mantagos IS, Vanderveen DK, Smith LE. Emerging treatments for retinopathy of prematurity. *Seminars in ophthalmology*. 2009; 24(2): 82-86. doi: [10.1080/08820530902800322](https://doi.org/10.1080/08820530902800322)
28. Lofqvist C, Niklasson A, Engstrom E, et al. A pharmacokinetic and dosing study of intravenous insulin-like growth factor-I and IGF-binding protein-3 complex to preterm infants. *Pediatr Res*. 2009; 65(5): 574-579. doi: [10.1203/PDR.0b013e31819d9e8c](https://doi.org/10.1203/PDR.0b013e31819d9e8c)
29. Ristori C, Filippi L, Dal Monte M, et al. Role of the adrenergic system in a mouse model of oxygen-induced retinopathy: antiangiogenic effects of beta-adrenoreceptor blockade. *Investigative ophthalmology & visual science*. 2011; 52(1): 155-170. doi: [10.1167/iovs.10-5536](https://doi.org/10.1167/iovs.10-5536)
30. Filippi L, Cavallaro G, Bagnoli P, et al. Oral propranolol for retinopathy of prematurity: risks, safety concerns, and perspectives. *The Journal of pediatrics*. 2013; 163(6): 1570-1577 e6. doi: [10.1016/j.jpeds.2013.07.049](https://doi.org/10.1016/j.jpeds.2013.07.049)
31. Filippi L, Cavallaro G, Fiorini P, et al. Study protocol: safety and efficacy of propranolol in newborns with Retinopathy of Prematurity (PROP-ROP): ISRCTN18523491. *BMC pediatrics*. 2010; 10: 83. doi: [10.1186/1471-2431-10-83](https://doi.org/10.1186/1471-2431-10-83)
32. SanGiovanni JP, Chew EY. The role of omega-3 long-chain polyunsaturated fatty acids in health and disease of the retina. *Progress in retinal and eye research*. 2005; 24(1): 87-138. doi: [10.1016/j.preteyeres.2004.06.002](https://doi.org/10.1016/j.preteyeres.2004.06.002)

33. Kermorvant-Duchemin E, Sennlaub F, Sirinyan M, et al. Trans-arachidonic acids generated during nitrate stress induce a thrombospondin-1-dependent microvascular degeneration. *Nature medicine*. 2005; 11(12): 1339-1345. doi: [10.1038/nm1336](https://doi.org/10.1038/nm1336)

34. Connor KM, SanGiovanni JP, Lofqvist C, et al. Increased dietary intake of omega-3-polyunsaturated fatty acids reduces pathological retinal angiogenesis. *Nature medicine*. 2007; 13(7): 868-873. doi: [10.1038/nm1591](https://doi.org/10.1038/nm1591)