

## Case Report

**\*Corresponding author**  
**Evanthia G. Tsalkidou, MD**  
 Department of Surgical  
 General Hospital of Komotini  
 "Sismanoglio"  
 Komotini 69100, Greece  
 Tel. 00302531351132  
 E-mail: [tsalkevi77@gmail.com](mailto:tsalkevi77@gmail.com)

**Volume 2 : Issue 5**  
**Article Ref. #: 1000GOROJ2123**

### Article History

**Received:** November 30<sup>th</sup>, 2015  
**Accepted:** January 27<sup>th</sup>, 2016  
**Published:** January 28<sup>th</sup>, 2016

### Citation

Tsalkidou EG, Memet IH, Chasan GM, et al. Ovarian cystectomy for huge mature cystic teratoma developed in less than five years: a case report. *Gynecol Obstet Res Open J.* 2016; 2(5): 99-101. doi: [10.17140/GOROJ-2-123](https://doi.org/10.17140/GOROJ-2-123)

### Copyright

©2016 Tsalkidou EG. This is an open access article distributed under the Creative Commons Attribution 4.0 International License (CC BY 4.0), which permits unrestricted use, distribution, and reproduction in any medium, provided the original work is properly cited.

# Ovarian Cystectomy for Huge Mature Cystic Teratoma Developed in Less than Five Years: A Case Report

**Evanthia G. Tsalkidou<sup>1\*</sup>, Ilker H. Memet<sup>1</sup>, Giasar M. Chasan<sup>1</sup>, Apostolos-Kyriakos Zolotas<sup>1</sup>, Achmet T. Achmet<sup>1</sup>, Paris Poursanidis<sup>2</sup> and Dimitrios Babalis<sup>1</sup>**

<sup>1</sup>Department of Surgical, General Hospital of Komotini "Sismanoglio", Komotini 69100, Greece

<sup>2</sup>Department of Radiology, General Hospital of Komotini "Sismanoglio", Komotini 69100, Greece

## BACKGROUND

Cystic ovarian teratomas, also known as dermoid cysts, are the most common benign ovarian germ cell tumors. They typically occur during reproductive age. Due to the readable accessibility to ultrasonography, the finding of large cystic teratomas over 10 cm is an unusual event.

We report a huge mature ovarian cystic teratoma developed in less than five years and was successfully treated by cystectomy.

## CASE REPORT

A 26-year-old woman was admitted due to progressive abdominal distension and discomfort, five years after delivery. Symptoms, such as severe abdominal pain, nevertheless other symptoms, such as vomiting, change in bowel habits, urinary symptoms or change in menstrual pattern were denied. Physical examination on admission demonstrated a distended abdomen more obvious at the right side, soft with no area of tenderness. In laboratory testing haemoglobin was 12.6 g/dL, white cell count was 7.170  $\mu$ /L, and urinalysis was normal. Serum tumor markers, CEA, CA 125, CA 19-9,  $\alpha$ -fetoprotein (AFP) and  $\beta$ -subunit of Human chorionic gonadotropin ( $\beta$ -hCG) levels included, were also normal. Abdominal ultrasonography revealed a large unilocular cystic mass 14 $\times$ 20 $\times$ 18 cm rather than 12.58 $\times$ 21.26 $\times$ 19.38 cm with fat attenuation within the cyst and calcificated areas in the wall, found in abdominal contrast computed tomography (Figures 1 and 2). This cystic mass not existed five years ago on transvaginal ultrasound performed forty days after delivery.

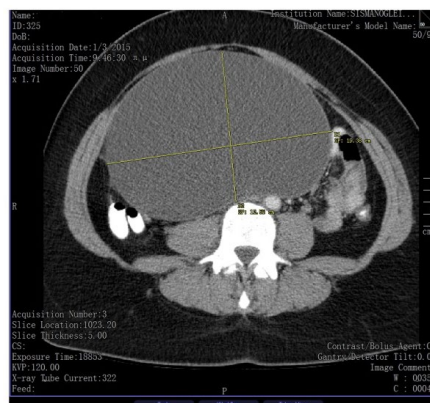


Figure 1: Computed tomography.

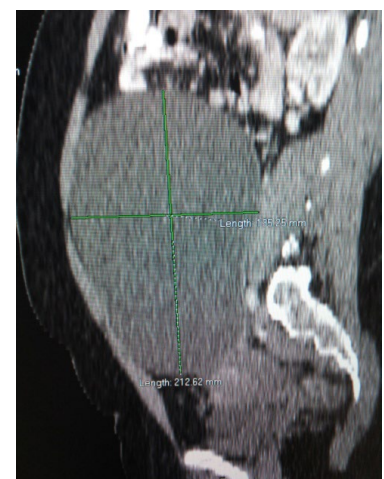

Figure 2: Computed tomography.

The patient underwent a median incisional exploratory laparotomy. Pelvic and abdominal organs were closely inspected. The cystic mass originated from the left ovary, was predominantly located in the right abdomen and no organ was infiltrated. The right ovary was not affected grossly and the uterus was normal in size. An ovarian cystectomy was performed. Histopathological examination of the excised cyst showed that it was a benign cystic teratoma. Her postoperative recovery was uneventful and she was discharged on the 5<sup>th</sup> postoperative day. Three months after operation there was functioning left ovarian tissue on follow-up transvaginal ultrasound.

## DISCUSSION

Cystic ovarian teratomas, especially mature cases (dermoid cysts), constitute 10-13% of all ovarian tumors and are the most common benign ovarian germ cell tumors.<sup>1</sup> They are composed of well-differentiated tissues derived from three germ cell layers: endoderm, mesoderm and ectoderm. They may contain skin, hair follicle, and sweat gland, bones, nail and teeth. Dermoid cysts may be asymptomatic or present with abdominal swelling, discomfort, and pain<sup>2,3</sup> and typically occur during reproductive age (mean age, 27 years).<sup>4</sup>

Ovarian cysts are labelled as large when they are over 5 cm in diameter and giant voluminous when they exceed 15 cm. According to bibliography mature cystic teratomas grow slowly at a mean average rate of 1.77±3.86 each year for the premenopausal women.<sup>5</sup> A significant point in this case is the fact that although the cyst was large, it had not developed over a long period. No cystic mass existed five years ago, on transvaginal ultrasound performed forty days after the patient's delivery.

Ovarian teratomas can be associated with various complications, including torsion (16%), rupture (1-4%), infection (1%), and autoimmune hemolytic anemia (<1%). Malignancy reported in teratomas ranges between 1-2%.<sup>6-8</sup>

The typical imaging finding of an ovarian teratoma is a cystic mass with intratumoral fat. At ultrasound, the most common finding of an ovarian teratoma is the Rokitansky nodule, i.e. a cystic mass with a densely echogenic tubercle projecting into the cystic lumen. The Rokitansky nodule or dermoid plug is described as a protrusion arising from the inner surface of a cyst, which may contain hair, teeth and fat causing acoustic shadowing.<sup>7</sup> Negative attenuation of this intratumoral fat at Computed Tomography (CT) and the combination of T1-weighted imaging and fat-saturated T1-weighted imaging for fat diagnosis at Mental Retardation (MR), rend these two diagnostic modalities fairly straightforward.<sup>7,10-12</sup>

Advanced surgical techniques have established the use of ovarian cystectomy as a safe method for tumor removal in the adult and pediatric population and as the first line of treatment in lesions that are preoperatively consistent with teratoma, i.e. without malignant characteristics in radiological and laboratory

evaluation.<sup>13,14</sup>

Taking under consideration the patient's age and cyst's characteristics, cystectomy *versus* oophorectomy was preferred. Contrary to appearances, the thinned cortical tissue that remains after cystectomy contains numerous viable follicles which can serve for future hormonal production and oocytes for reproduction. After laparoscopic ovarian biopsy in women 11-34 years old each was found that in 1 mm<sup>2</sup> of surface ovarian tissue contained approximately 35 primordial follicle.<sup>14</sup> Functioning ovarian tissue on follow-up supported our surgical approach.

## CONCLUSION

A mature cystic teratoma could grow at an average rate of up to 4 cm per year. Despite dimension, cystectomy should be the recommended surgical approach in women of reproductive age with negative pre-operative indications of malignancy.

## CONFLICTS OF INTEREST

The authors declare that they have no conflicts of interest.

## CONSENT

The patient has provided written permission for publication of the case details.

## REFERENCES

1. Koonings PP, Campbell K, Mishell DR Jr, Grimes DA. Relative frequency of primary ovarian neoplasms: a 10-year review. *Obstet Gynecol.* 1989; 74: 921-926.
2. Sah SP, Uprety D, Rani S. Germ cell tumors of the ovary: a clinicopathologic study of 121 cases from Nepal. *Journal of Obstetrics and Gynaecology Research.* 2004; 30(4): 303-308. doi: [10.1111/j.1447-0756.2004.00198.x](https://doi.org/10.1111/j.1447-0756.2004.00198.x)
3. Wu RT, Torng PL, Chang DY, et al. Mature cystic teratoma of the ovary: a clinicopathologic study of 283 cases. *Zhonghua Yi Xue Za Zhi.* 1996; 58(4): 269-274.
4. Stella F, Davoli F. Giant mediastinal mature teratoma with increased exocrine pancreatic activity presenting in a young woman: a case report. *J Med Case Reports.* 2011; 5: 238. doi: [10.1186/1752-1947-5-238](https://doi.org/10.1186/1752-1947-5-238)
5. Caspi B, Appelman Z, Rabinerson D, Zalel Y, Tulandi T, Shoham Z. The growth pattern of ovarian dermoid cysts: a prospective study in premenopausal and postmenopausal women. *Fertil Steril.* 1997; 68: 501-505. doi: [10.1016/S0015-0282\(97\)00228-8](https://doi.org/10.1016/S0015-0282(97)00228-8)
6. Comerci JT, Licciardi F, Berghi PA, Gregori C, Breen JL. Mature cystic teratoma: a clinicopathologic evaluation of 517 cases and review of the literature. *Obstet Gynecol.* 1994; 84: 222-288.

7. Outwater EK, Siegelman ES, Hunt JL. Ovarian teratomas: tumor types and imaging characteristics. *Radiographics*. 2001; 21: 475-490. doi: [10.1148/radiographics.21.2.g01mr09475](https://doi.org/10.1148/radiographics.21.2.g01mr09475)
8. Kido A, Togashi K, Konishi I, et al. Dermoid cysts of the ovary with malignant transformation: MR appearance. *AJR Am J Roentgenol*. 1999; 172: 445-449. doi: [10.2214/ajr.172.2.9930800](https://doi.org/10.2214/ajr.172.2.9930800)
9. Templeman C, Fallat M, Lam A, et al. Managing mature cystic teratomas of the ovary. *Obstet Gynecol Surv*. 2000; 55: 738-745.
10. Guinet C, Ghossain MA, Buy JN, et al. Mature cystic teratomas of the ovary: CT and MR findings. *Eur J Radiol*. 1995; 20: 137-143.
11. Occhipinti KA, Frankel SD, Hricak H. The ovary: computed tomography and magnetic resonance imaging. *Radio Clin North Am*. 1993; 31: 1115-1132.
12. Togashi K, Nishimura K, Itoh K, et al. Ovarian cystic teratomas: MR imaging. *Radiology*. 1987; 162: 669-673. doi: [10.1148/radiology.162.3.3809479](https://doi.org/10.1148/radiology.162.3.3809479)
13. Cass D, Hawkins E, Brandt M, et al. Surgery for ovarian masses in infants, children, and adolescents: 102 consecutive patients treated in a 15-year period. *J Pediatr Surg*. 2001; 36: 693-699. doi: [10.1053/jpsu.2001.22939](https://doi.org/10.1053/jpsu.2001.22939)
14. Meirow D, Fasouliotis M, Nugent D, et al. A laparoscopic technique for obtaining ovarian cortical biopsy specimens for fertility conservation in patients with cancer. *Fertil Steril*. 1999; 71: 948-951. doi: [10.1016/S0015-0282\(99\)00067-9](https://doi.org/10.1016/S0015-0282(99)00067-9)