Openventio PUBLISHERS

ISSN 2470-4059

OTOLARYNGOLOGY

Open Journal

| August 2018 | Volume 4 | Issue 1 |

www.openventio.org

ISSN 2470-4059

OTOLARYNGOLOGY

Open Journal

Openventio PUBLISHERS

CONTENTS

ISSN 2470-4059

OTOLARYNGOLOGY

Open Journal

Openventio PUBLISHERS

Original Research

Facial Paralysis after Trauma: A Simplified Method to Find and Repair the Facial Nerve

Yavuz Uyar, MD; Berk Gürpınar, MD*; Ahmet Arslanoğlu, MD; Zıya Saltürk, MD; Tolgar Lütfı Kumral, MD; Yavuz Atar, MD; Kamıl Akdag, MD; Belgın Tutar, MD; Güler Berkıten, MD

Department of Otolaryngology, Okmeydani Training and Research Hospital, Kaptan Pasa Mahallesi, Darulaceze Cad. No:25, 34384 Okmeydani Istanbul, Turkey

***Corresponding author**
Berk Gürpınar, MD
Department of Otolaryngology, Okmeydani Training and Research Hospital, Istanbul, Turkey; Tel. +90 212 314 55 55, Fax: +90 212 221 78 00
E-mail: b_gurpinar@yahoo.com

Article information
Received: January 18th, 2018; **Revised:** February 18th, 2018; **Accepted:** February 20th, 2018; **Published:** February 21st, 2018

Cite this article
Uyar Y, Gürpınar B, Arslanoğlu A, et al. Facial paralysis after trauma: A simplified method to find and repair the facial nerve. *Otolaryngol Open J*. 2018; 4(1): 1-5. doi: 10.17140/OTLOJ-4-144

ABSTRACT

Objective
This study aims to identify the digastric nerve as an alternative to access the facial nerve in case of post-traumatic facial nerve paralysis.

Study design
Retrospective study.

Setting
Tertiary care hospital.

Subjects and Methods
Eleven peripheric facial paralysis cases between 2005-2016 following trauma to the parotid gland are presented. Initial emergency treatments were done elsewhere but all returned back to treat facial paralysis after 11-18 months to our institute. The digastric nerve was identified and a facial-hypoglossal nerve anastomosis was performed.

Results
Pre-operative House-Brackmann scores were 6 for all cases. Post-operative scores were between 3 and 4. Pre-operative needle electromyography revealed no motor unit action potentials; after 7 months post-operatively, we had motor unit action potentials in every case.

Conclusion
In cases of trauma and secondary approaches of the parotid gland, a safe step for finding the facial nerve is to find the digastric nerve and follow it through the main trunk.

Keywords
Facial nerve; Wound and injury; Hypoglossal-facial nerve anastomosis (HFNA).

Abbreviations
HFNA: Hypoglossal-Facial Nerve Anastomosis ; TMJ: Temporomandibular Joint; MUPs: Motor Unit Potentials;
HB: House-Brackmann.

Otolaryngol Open J. 2018; 4(1): 1-5. doi: 10.17140/OTLOJ-4-144

INTRODUCTION

The facial nerve lies beneath the parotid gland and a thick glandular capsule serves as a protection against blunt trauma. The mandible is the second barrier for protection. The force required to injure the parotid gland is mostly more than the force required to fracture the mandible or temporomandibular joint (TMJ). In severe cases, the soft tissues are usually more affected than the adjacent structures, making surgical intervention necessary.[1-3]

Blunt trauma or gunshot injuries to the parotid gland may cause acute or delayed facial paralysis. Delayed treatment of the nerve is almost always difficult because the scar formation prevents visual identification or stimulation of the facial nerve or its branches.[4]

Postero-anterior or antero-posterior facial nerve dissections are the two common methods to find the facial nerve in the parotid surgery.[5] The tragal pointer or the tympanomastoid suture are the landmarks of the first method while the peripheral branches of the nerve are followed by the parotid gland in the latter one. Locating the nerve may be troublesome even in elective cases, whereas it is almost impossible in the delayed trauma cases because of extreme fibrosis. Hypoglossal-facial nerve anastomosis (HFNA) is a common method to repair the nerve once a long period of time has been passed from the onset of the trauma. Identification and access to both the facial and the hypoglossal nerves are mandatory in this procedure.[6]

We, in this study, present eleven cases of post-traumatic facial nerve paralysis that had end-to-end HFNA in our institute. To best of our knowledge, the digastric nerve is used as a referral point for the facial nerve but its importance in delayed trauma and fibrotic cases are underestimated. In this study, our aim is to emphasize the importance of identification of the digastric nerve in traumatic surgical cases as the first step of the facial neural surgery. Also a brief review of the literature and comparison of the pre-operative and post-operative facial nerve functions are introduced.

MATERIALS AND METHODS

Eleven peripheric facial paralysis cases between 2005-2016 following trauma to the parotid gland are presented. Institutional review board (IRB) approval was obtained from our institute. Initial emergency treatments were done elsewhere but all returned back to treat facial paralysis after 11-18 months. None of them received surgical intervention for the treatment of facial paralysis before or after the trauma. All cases underwent a thorough otolaryngologic examination and the pre-operative House-Brackmann (HB) scores were noted (Table 1). All cases received needle electrode electromyography to evaluate the motor function of the facial nerve (Table 1). The stimulus was given from the pretragal point and both the frontalis muscle and the *levator labii superioris/levator labii alaque nasi* muscles. After electrophysiological tests, all subjects were planned to receive surgical intervention.

All clinical subjects were operated under the condition of general anesthesia. Each patient received a dose of midazolam 1.5 mg intravenously for premedication. Nitrous oxide, oxygen, and remifentanil were used for induction of general anesthesia. No ad-

Table 1. *Subject Characteristics*

	Age/Gender	Duration of Facial Paralysis (Months)	Main Injury	Cause of Injury	Initial HB Score	Initial MUAP	Planned Surgery	Post-operative 7th month HB Scores	Post-operative 7th month MUAP
1	27 Male	16	Mandible fracture	Car accident	6	-	CN 7-12 Anastomosis	3	+
2	34 Male	11	Temporomandibular fracture	Gunshot	6	-	CN 7-12 Anastomosis	4	+
3	22 Female	13	Temporal bone fracture	Car accident	6	-	CN 7-12 Anastomosis	3	+
4	26 Male	18	Mandible fracture	Car accident	6	-	CN 7-12 Anastomosis	4	+
5	28 Male	16	Parotid region hematoma	Assault	6	-	CN 7-12 Anastomosis	4	+
6	29 Female	17	Mandible fracture	Car accident	6	-	CN 7-12 Anastomosis	4	+
7	31 female	15	Parotid region hematoma	Assault	6	-	CN 7-12 Anastomosis	4	+
8	22 Male	14	Mandible fracture	Gunshot	6	-	CN 7-12 Anastomosis	3	+
9	24 Female	15	Temporomandibular fracture	Car accident	6	-	CN 7-12 Anastomosis	4	+
10	28 Male	12	Temporomandibular fracture	Car accident	6	-	CN 7-12 Anastomosis	3	+
11	29 Male	12	Mandible fracture	Car accident	6	-	CN 7-12 Anastomosis	3	+

HB: House-Brackmann
CN: Cranial nerve
MUAP: Needle Electrode Electromyography Motor Unit Action Potentials

ditional muscle relaxant was given to enhance nerve stimulation. As a standard protocol, each patient was placed in the supine position with a shoulder support to the trauma side to facilitate surgery. Modified Blair incision was the type of incision we preferred to expose the parotid gland. Skin and subcutaneous tissues were elevated and the flap over the parotid gland was prepared. The anterior edge of the sternocleidomastoid muscle was identified and followed-up reaching the digastric muscle posterior belly and the mastoid apex. We preferred to use 2.5x surgical binoculars to ensure adequate magnification. Digastric nerve was identified on the posterior belly of the digastric muscle and under the parotid gland (Figure 1). It was followed-up until the main facial nerve trunk was reached. Meticulous dissection was carried out to remove all possible fibrous tissue or adhesions. In all our cases presented in this study, the facial nerve was transected near the main truncus. Therefore, end-to-end HFNA was planned for all patients. The hypoglossal nerve was found under the digastric muscle and sutured to the facial nerve trunk with 10/0 non-absorbable sutures. In the extreme fibrosis of the parotideal region, submandibulary fossa dissection was carried out to identify the neural structures.

Post-operative medications were considered as the standard for antibiotic regimens (cefuroxime axetil 500 mg b.i.d, 7 days), oral analgesics (acetazolamide 500 mg t.i.d, 7 days) and corticosteroids (prednisolone 1 mg/kg initially for 7 days and then decreased till completion).

All subjects were followed monthly for the first year, electromyographic evaluations were done in every three months and the HB scores were noted.

RESULTS

Seven cases were male and 4 cases were female. They were between 22-34 years old (Table 1). Seven cases were after car accidents, two were due to gunshot and two were after the assault. Eight had acute facial paralysis and the rest had delayed paralysis. All of them initially suffered from edema and hematoma.

Pre-operative HB scores were 6 for all cases. Post-operative scores were between 3 and 4 (average 3,54). Pre-operative needle electromyography revealed no motor unit action potentials; after 7 months post-operatively, we had motor unit action potentials in every case. All cases are monitored in the first year after the surgery and no complications have occurred.

DISCUSSION

Trauma to the parotideal region rarely requires treatment. The extreme force that causes injury usually also causes penetration. Blunt trauma requiring emergency treatment may be caused by traffic accidents, severe falls, and criminal cases. Facial paralysis is the most important clinical presentation for cases of blunt trauma.[1]

The facial neural treatment plan is based on several factors. The timing of the surgery creates major differences. If the time elapsed from the transsection of the nerve is long enough to create fibrosis and neural degeneration, primary repair of the nerve may not be succeeded.[7] Secondly, physical examination of the neural integrity is crucial for optimal surgery, the HB scoring system is developed to uniform the function of the nerve; however, subjective judgment may not give enough or objective information on the paralysis status, especially with regard to the treatment and prognosis. Therefore, electrophysiological tests are supportive for the diagnosis of the neural-muscular system but not a method to diagnose the disease or confirm the etiology.[8] The aim of electrophysiological tests is to localize the lesion, determine the severity of the injury, and differentiate whether an injured nerve is still degenerating or regenerating. Cases with fibrillation potential and degeneration more than 90% should be treated surgically. The regenerative and repair processes of the nerve begin almost immediately, but nerve regeneration begins only after Wallerian degeneration. In severe cases; transection of the axon divides the nerve into proximal segment connecting to a cell body and a distal one. Two segments retract in the direction opposite to the transection site. The endoneurial tube is disrupted and axon cannot regenerate into its original sheath. Axonal regrowth begins as early as 24 hours post-injury. During regeneration, axonal regrowth may be impeded by fibrous tissues. Within 3 days post-injury, axonal sprout starts to grow from the proximal stump and the rate of axonal regeneration is generally estimated to be 1 mm per day. By 48 to 96 hours post-injury, axonal continuity is lost and nerve conduction is

Figure 1. *Intraoperatif view of the anatomic landarks. Black arrow: Facial nerve; White arrow: Digastric nerve*



lost. Myelin disintegration lags slightly behind that of axons but is well advanced by 36 to 48 hours. Disintegrated debris of axon and myelin sheath is removed by phagocytosis of macrophages within 12-14 days post-injury.[9]

In all of our cases, the earliest interventional time after the trauma was 11 months. Histologically, this is adequate for neural and structural fibrosis to occur. The HB scores and the neurophysiological tests revealed complete transection of the facial nerve on the trauma side. Therefore, once we confirmed the diagnosis by the physical examination and neurophysiological tests, we planned termino-terminal HFNA. The idea of HFNA is not to gain the facial muscular function completely but to gain the muscular tonus to some extent, although the cosmetic and functional results may not be satisfactory. Urgent surgical intervention on the time of the trauma, on the other hand, provides a better surgical field without no fibrosis or synechiae and primary repair or cable grafting of the facial nerve brings out better cosmesis and functional results.[10,11]

The middle deep temporal nerve branches can be identified on the deep side of the temporalis, within 9 to 12 mm posterior to the jugal point of the zygoma and utilized for facial reanimation. This technique may reanimate the facial muscles with independent activation.[12]

Experimentally, biodegradable metallic magnesium filaments, placed inside hollow nerve conduits, supported nerve repair by providing contact guidance support for axonal regeneration. With a nerve gap of 6 mm and 6 weeks post-repair, magnesium filaments had partially resorbed. Regenerating cells had attached to the filaments and axons were observed in distal stumps in all animals. Magnesium filaments were completely resorbed and no evidence of scarring was seen.[13]

Flasar et al studied 11 cases after HFNA; first movements were seen between 6 and 10 months after surgery in individual patients. The maximal improvement was achieved at 18 months. Motor unit potentials (MUPs) were first recorded after the 2nd month and present in all 11 patients 8-10 months post-surgery. Polyphasic regeneration potentials first appeared at 4-10 months post-surgery. The MUP amplitudes increased between the 3rd and 15th months after surgery to values of control muscles. The MUP duration was significantly increased above normal values between the 3rd and 24th months after surgery.[14]

Our electrophysiological results were consistent with the published previous data. However, we were unable to obtain the long-term results. The electrophysiological results were not totally parallel to the physical examination and HB scores, we were unable to achieve House-Brachmann scores higher than 3.

For treatment plan, we always preferred HFNA in late cases. The trauma was in the parotideal region, so we expected dense fibrosis in this region only. We found the digastric nerve over the digastric muscle, which could be accessed in several sites including the submandibular region, and as a step of the HFNA, also the hypoglossal nerve could easily be identified in this area of the neck and be prepared as well. These steps usually took 30 minutes; which we believe, is not a long time for safe and clear surgery. We did not attempt to use the other nerve finding methods because of the long duration of the paralysis and dense fibrosis. The posterior belly of the digastric muscle is innervated by the digastric branch of the facial nerve. The digastric nerve is the second branch of the facial truncus, following the posterior auricular nerve; it is also located on the surface of the digastric muscle.[10] Few studies have detailed methods to identify the facial truncus by following the digastric nerve. A study by Kanatas and McCaul[10] described this method, but no patient information was provided. In another study by Saha et al.,[11] this technique was introduced on cadavers and living patients. They reported that the facial truncus was 3.50-3.87 mm from the tympanomastoid suture line and 16.61-16.36 mm from the tragal pointer, whereas 7.41-8.03 mm from the digastric muscle. The authors claimed that the posterior belly of the digastric muscle was the point farthest from the truncus, making manipulation easier.

Experimentally, end-to-end and end-to-side HFNA neurorrhaphy methods are compared but all techniques resulted in partial functional recovery, but complete restoration was not obtained. There were no significant differences between the experimental groups in axon diameter or myelin thickness. The hypoglossal nerve fiber count after end-to-side was markedly more than that after end-to-end neurorrhaphy corresponding to the electrophysiological examination.[15] We preferred end-to-end (termino-terminal) method in all our surgeries, this may explain why the HB scores were no better than 3 post-operatively. We believe further research is needed to compare the long-term results of end-to-end or end-to-side HFNA.

The facial nerve truncus and its branches are in the most accessible state immediately after the trauma, and it is also possible to use primary suturing or nerve grafting to repair the nerve. As time passes, it is almost impossible to locate or repair the nerve, so mostly after the first year, a facial-hypoglossal nerve anastomosis required. After this surgery, hemiparalysis or paresis of the tongue and facial asymmetry occurs frequently.[9]

We have some limitations in this study; firstly, all cases have initially been treated elsewhere, it would notably be better if we could have assessed the cases from the onset of the trauma till the end of the post-operative first year. Secondly, we do not have the electrophysiological tests of the patients before they have applied to our institute. Finally, we monitored all cases for one year. Nevertheless, the aim of this manuscript is to present an easy method of facial nerve identification, so we believe, these limitations should be considered for further studies.

CONCLUSIONS

Access to the facial nerve is crucial in facial neural injury and parotid surgery. In cases of trauma and secondary approaches of the parotid gland, dense fibrosis and synechiae block the vision and the surgical field is vague. Alternatively, an unaffected site is chosen to find a branch of the facial nerve, which is the digastric nerve and

is followed by the main facial trunk. This method is not hard, the learning curve is easy and does not increase the overall operative time but a safe and clean dissection and structural identification could be performed.

CONFLICTS OF INTEREST

The authors declare that they have no conflicts of interest.

REFERENCES

1. Smith OD, McFerran DJ, Antoun N. Blunt trauma to the parotid gland. *Emerg Med J*. 2001; 18: 402-403. doi: 10.1136/emj.18.5.402

2. Ohlson NR. Traumatic lesions of the salivary glands. *Otolaryngol Clin North Am*. 1977; 10: 345-350.

3. Shetty DK, Rink B. Effects of direct blunt trauma on the salivary glands. *Deutsch Zahn Mund Kieferheilk*. 1974; 62(2): 148-157.

4. Lewis G, Knottenbelt JD. Parotid duct injury: Is immediate surgical repair necessary? *Injury*. 1991; 22(5): 407-409. doi 10.1016/0020-1383(91)90107-P

5. Davis RA, Anson BJ, Budinger JM, Kurth LR. Surgical anatomy of the facial nerve and parotid gland based upon a study of 350 cervicofacial halves. *Surg Gynecol Obstet*. 1956; 102: 385-412.

6. Rea PM, McGarry G, Shaw-Dunn J. The precision of four commonly used surgical landmarks for locating the facial nerve in anterograde parotidectomy in humans. *Ann Anat*. 2010; 192: 27-32. doi 10.1016/j.aanat.2009.09.005

7. Ozdemir B, Celbis O, Kaya A. Cut throat injuries and honor killings: Review of 15 cases in eastern Turkey. *J Forensic Leg Med*. 2013; 20: 198-203. doi: 10.1016/j.jflm.2012.09.011

8. Atteberry LR, Dennis JW, Menawat SS, Frykberg ER. Physical examination alone is safe and accurate for evaluation of vascular injuries in penetrating Zone II neck trauma. *J Am Coll Surg*. 1994; 179: 657-662.

9. Le Clerc N, Herman P, Kania R, et al. Comparison of 3 procedures for hypoglossal-facial anastomosis. *Otol Neurotol*. 2013; 34(8): 1483-1488. doi: 10.1097/MAO.0b013e31828dac62

10. Kanatas AN, McCaul JA. Use of digastric branch of the facial nerve for identification of the facial nevre itself in parotidectomy: technical note. *Br J Oral Maxillofac Surg*. 2011; 49(6): 493-494.

11. Saha S, Pal S, Sengupta M, et al. Identification of facial nerve during parotidectomy: A combined anatomical & surgical study. *Indian J Otolaryngol Head Neck Surg*. 2014; 66(1): 63-68. doi: 10.1007/s12070-013-0669-z

12. Mahan MA, Sivakumar W, Weingarten D, Brown JM. Deep temporal nerve transfer for facial reanimation: Anatomic dissections and surgical case report. *Oper Neurosurg (Hagerstown)*. 2017; 8. [Epub ahead of print].

13. Hopkins TM, Little KJ, Vennemeyer JJ, et al. Short and long gap peripheral nerve repair with magnesium metal filaments. *J Biomed Mater Res A*. 2017; 105(11): 3148-3158. doi: 10.1002/jbm.a.36176

14. Flasar J, Volk GF, Granitzka T, et al. Quantitative facial electromyography monitoring after hypoglossal-facial jump nerve suture. *Laryngoscope Investig Otolaryngol*. 2017; 25; 2(5): 325-330. doi: 10.1002/lio2.95

15. Liu P, Liao C, Zhong W, et al. Comparison of four different methods for direct hypoglossal-facial nerve anastomosis in rats. *World Neurosurg*. 2018. [Epub ahead of print].

ISSN 2470-4059

OTOLARYNGOLOGY
Open Journal

Openventio PUBLISHERS

Case Report

Giant Parathroid Adenoma With Thoracic Extension: A Case Report

Hejer Mbarek, MD*; Hadhemi Belaid, MD; Khaled Khamassi, MD; Ines Riahi, MD; Habib Jaafoura, MD; Sondes Mannoubi, MD; Rim Lahiani, MD; Mamia Ben Salah, MD

Department of Otorhinolaryngology-Head and Neck Surgery, Charles Nicolle Hospital, Tunis, Tunisia

***Corresponding author**
Hejer Mbarek, MD
Department of Otorhinolaryngology-Head and Neck Surgery, Charles Nicolle Hospital, Tunis, Tunisia; Tel. +216 52181495; E-mail: hejer.mbarek@gmail.com

Article information
Received: January 16th, 2018; **Revised:** March 2nd, 2018; **Accepted:** March 5th, 2018; **Published:** March 5th, 2018

Cite this article
Mbarek H, Belaid H, Khamassi K, et al. Giant parathroid adenoma with thoracic extension: A case report. *Otolaryngol Open J*. 2018; 4(1): 6-8.
doi: 10.17140/OTLOJ-4-145

ABSTRACT

A 31-year-old female patient was addressed to our consultation for management of hypercalcemia secondary to primary hyperparathyroidism. The physical examination results were normal. The technetium sestamibi (^{99m}Tc MIBI) parathyroid scintigraphy showed a large fixation area next to the inferior pole of the left lobe of the thyroid. Cervical computed tomography (CT) scan showed a 6 cm tissue lesion in the inferior pole of the thyroid's left lobe. The patient was operated through a classical cervical incision, extracting successfully a 6 cm brown lesion. The histopathological study has confirmed the diagnosis of a giant parathyroid adenoma weighing 84 g.

Keywords
Giant parathyroid adenoma; Pancreatitis; Primary hyperparathyroidism.

Abbreviations
PTH: Parathyroid Hormone; CT: Computed Tomography; SICU: Surgical Intensive Care Unit; MRI: Magnetic Resonance Imaging.

INTRODUCTION

Primary hyperparathyroidism is the third most common endocrine disease. It is associated with hypercalcemia due to oversecretion of parathyroid hormone (PTH). Parathyroid adenoma is the leading cause of this disorder (80% of cases); however, hyperplasia and carcinoma are found in 15% and less than 1% of cases respectively.[1] Giant parathyroid adenoma is an extremely rare entity, especially in developed countries, with sporadic reports of masses attaining 70 g or more.[1,2] The surgical management is a challenge. We report a case of giant parathyroid adenoma in a 31-year-old female patient diagnosed after an episode of pancreatitis.

CLINICAL CASE PRESENTATION

A 31-year-old female patient has presented a couple of months before an episode of acute pancreatitis, which was treated successfully in a surgical intensive care unit (SICU). Test results have concluded that the pancreatitis was caused by hypercalcemia secondary to primary hyperparathyroidism. The physical examination results were normal. Blood tests showed that the PTH was twice the normal level and the renal function was normal. The technetium sestamibi (^{99m}Tc MIBI) parathyroid scintigraphy showed a large fixation area next to the inferior pole of the left lobe of the thyroid, related to a huge parathyroid adenoma. Cervical computed tomography (CT) scan showed a 6 cm tissue lesion in the inferior pole of the thyroid's left lobe, repressing backward the subclavian artery, and forward the common carotid artery. This lesion circumvents the left common carotid artery reaching the mediastinum orifice (Figure 1).

The patient was operated by a classical cervical incision,

Otolaryngol Open J. 2018; 4(1): 6-8. doi: 10.17140/OTLOJ-4-145

extracting successfully a 6 cm brown lesion next to the inferior pole of the left thyroid lobe (Figures 2 and 3). Intra-operative PTH test confirmed the total resection of parathyroid adenoma. In post-operative period, our patient had neither dysphonia nor paresthesia. Blood test control showed the normalization of the PTH and calcemia levels. The histopathological study showed a composite tissue arranged in sheets, trabeculae and acini formed of cells with round to ovoid fine nuclei, tiny nucleoli and moderate amounts of clear and eosinophilic cytoplasm, with no capsular nor vascular invasion, consistent with a parathyroid adenoma weighting 84 g.

DISCUSSION

Primary hyperparathyroidism is the result of an excessive and inappropriate production of parathyroid hormone. It is most commonly caused byadenoma.[2] The parathyroid adenoma's weight ranges usually from 1 to 70 mg. Giant parathyroid adenomas are extremely rare.[1,2] They are defined according to their weight; however, there is a controversy concerning their definition. Spanheimer characterized giant parathyroid adenoma by an increased weight >3.5 g.[3] The greatest giant adenoma described in the literature was reported by Çakmak (145 g).[2]

Over the years, the clinical presentation of primary hyperparathyroidism has changed from a severe disease to a disease with subtle symptoms and physiologic perturbations.[4] The examination of the cervical region is usually with no particularities. The elevated levels of serum calcium is at the origin of skeletal, renal, gastrointestinal, cardiac, and neurological symptoms. Patients suffer from neuromuscular weakness, memory loss and decreased concentration. The main symptoms are acute abdominal pain, constipation, vomiting and nausea.[5] In our case, the hypercalcemia due to primary hyperparathyroidism was diagnosed after an episode of pancreatitis. This association is reported in <10% of cases in the literature.[6] Krishnamurthy reported the same circumstance of discovery in a patient presenting recurrent episodes of acute pancreatitis.[4]

Blood tests showed, in our case, hypercalcemia with high level of PTH confirming the diagnosis of a primary hyperparathyroidism. Normocalcemic hyperparathyroidism can also be seen and should not be confused with secondary hyperparathyroidism.[5]

The diagnostic of primary hyperparathyroidism is based on biochemical criteria; however, the localization of the pathologic parathyroid gland and the planning of the surgical management require imaging methods.

The technetium sestamibi (^{99m}Tc MIBI) parathyroid is the most widely used modality for localization of parathyroid adenomas.[7] It uses the absorption of radiotracer from hyperactive parathyroid tissue, in order to localize abnormal parathyroid glands.[5] Technetium-99m (^{99m}Tc) sestamibi has been introduced for parathyroid imaging in 1989 and the technique has been subject to several changes with an important improvement of its efficiency.

Figure 1. *Axial (A) and Coronal (B,C) CT Scan Images Showing a 6 cm Tissue Lesion in the Inferior Pole of the Thyroid's Left Lobe, Repressing Backward the Sub Clavian Artery, and Forward the Common Carotid Artery and Reaching the Mediastinum Orifice*

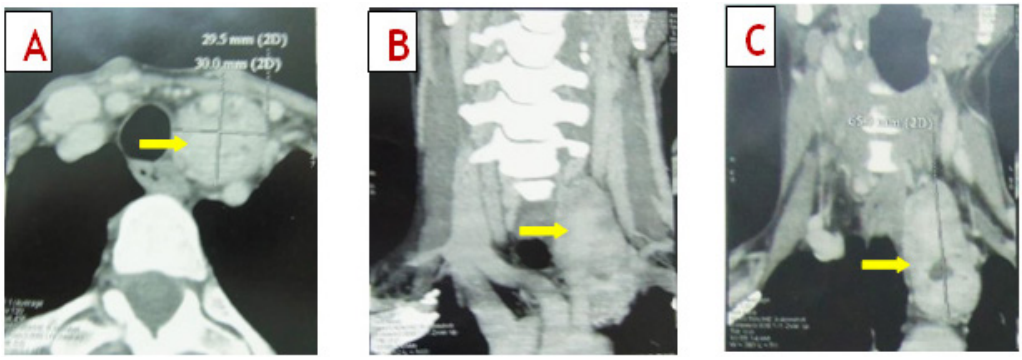

Figure 2. *Intra-Operative View of the Giant*

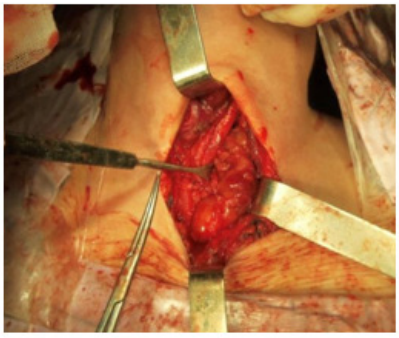

Figure 3. *Giant Parathyroid Adenoma after Resection Parathyroid Adenoma Via Transcervical Incision*

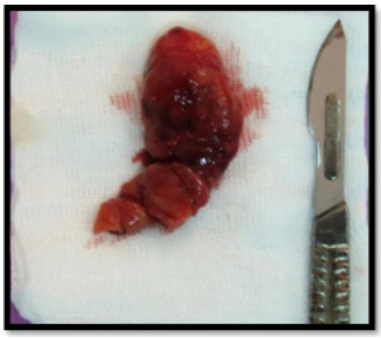

Alabdulkarim found in his study evaluating this imaging method, a sensitivity and specificity of 98.1 and 97%, respectively.[8] The principal limitation of the scintigraphy is its conventional planar view. The incorporation of single-photon emission computed tomography-computed tomography (SPECT-CT) as a component of hybrid imaging enables a high spatial resolution three-dimensional (3D) image.[4,7]

In the ultrasounds, parathyroid adenoma appears as hypoechoic mass with smooth borders and homogeneous echogenicity.[9] However, this modality used alone, especially in giant adenomas, can underestimate the size as only a part of the adenoma may be visualised transcervically.[1]

Pre-operative cross-sectional imaging such as CT-scan or magnetic resonance imaging (MRI) delineates the anatomy of the entire adenoma, precises the site, the size, the relation with surrounding structures, and thus facilitates surgical management and prevents unplanned conversion to a thoracic approach.[1]

Surgical excision of the hyperfunctioning gland is the main treatment for parathyroid adenoma. The standard surgical approach is transcervical through a low anterior cervical incision. Radionucleotide-guided localization with technetium injection can also be used intra-operatively.[10] Median sternotomy and thoracotomy are of great interest in cases of large inaccessible masses.[11] Our case showed that a trans-cervical excision of giant parathyroid adenoma is a viable approach for resection and should be considered prior to more aggressive approachs.

Intra-operative PTH testing, practiced in our case, confirms the parathyroid adenoma resection when PTH levels fall >50%.[10] Clinical and biological follow-up is necessary for post-operative period. Giant parathyroid adenomas are associated with higher rates of post-operative hypocalcemia and may need infusion of calcium and oral calcitriol supplementation.[1] In our case, the post-operative values of calcium and PTH were normalized.

CONCLUSION

Giant parathyroid adenoma is a rare entity that can be a troublesome cause for primary hyperparathyroidism. Precise pre-operative localization and evaluation of the size and the relation to surrounding structures, based on ^{99m}Tc MIBI parathyroid scintigraphy and CT scan or MRI, is vitally important prior to surgical management. The treatment consists on the resection of the pathologic parathyroid tissue. The excision can be safely performed *via* a collar incision, as in our case. Thoracotomy or sternotomy are reserved for inaccessible adenomas.

CONFLICTS OF INTEREST

The authors declare that they have no conflicts of interest.

CONSENT

An informed consent has been obtained from the patient.

REFERENCES

1. Garas G, Poulasouchidou M, Dimoulas A, Hytiroglou P, Kita M, Zacharakis E. Radiological considerations and surgical planning in the treatment of giant parathyroid adenomas. *Ann R Coll Surg Engl*. 2015; 97: 64-66. doi: 10.1308/003588415X14181254789682

2. Çakmak H, Tokat AO, Karasu S, Özkan M. Giant mediastinal parathyroid adenoma. *Tüberküloz ve Toraks Dergisi*. 2011; 59(3): 263-265.

3. Spanheimer PM, Stoltze AJ, Howe JR, Sugg SL, Lal G, Weiger RJ. Do giant parathyroid adenomas represent a distinct clinical entity? *Surgery*. 2013; 154(4): 714-718. doi: 10.1016/j.surg.2013.05.013

4. Krishnamurthy A, Raghunandan GC, Ramshankar V. A rare case of giant parathyroid adenoma presenting with recurrent episodes of pancreatitis. *Indian J Nucl Med*. 2016; 31(1): 36-38. doi: 10.4103/0972-3919.172355

5. Sahsamanis G, Gkouzis K, Samaras S, Pinialidis D, Dimitrakopoulos G. Surgical management of a giant parathyroid adenoma through minimal invasive parathyroidectomy. A case report. *Int J Surg Case Rep*. 2017; 31: 262-265. doi: 10.1016/j.ijscr.2017.01.064

6. Tun-Abraham ME, Obregón-Guerrero G, Romero-Espinoza L, Valencia-Jiménez J. Acute pancreatitis associated with hypercalcaemia. *Cir Cir*. 2015; 83(3): 227-231. doi: 10.1016/j.circen.2015.09.026

7. Krishnamurthy A, Majhi U, Rangarajan GK, Ramshankar V, Kumar RK. The diagnostic and therapeutic challenges in the management of a double giant parathyroid adenoma. *Indian J Nucl Med*. 2016; 31(4): 301-304. doi: 10.4103/0972-3919.187450

8. Alabdulkarim Y, Nassif E. Sestamibi (99mTc) scan as a single localization modality in primary hyperparathyroidism and factors impacting its accuracy. *Indian J Nucl Med*. 2010; 25(1): 6-9. doi: 10.4103/0972-3919.63591

9. Araujo Castro M, López AA, Fragueiro LM, García NP. Giant parathyroid adenoma: Differential aspects compared to parathyroid carcinoma. *Endocrinol Diabetes Metab Case Rep*. 2017; 2017. pii: 17-0041. doi: 10.1530/EDM-17-0041

10. Pecheva M, Mahendran k, Kadlec J, Lofthouse M, Van Tornout F. Mediastinal giant parathyroid adenoma—a minimally invasive mediastinal surgical approach for an emergency presentation. *Ann Cardiothorac Surg*. 2016; 5(1): 70-73. doi: 10.3978/j.issn.2225-319X.2015.08.12

11. Haldar A, Thapar A, Khan S, Jenkins S. Day-case minimally invasive excision of a giant mediastinal parathyroid adenoma. *Ann R Coll Surg Engl*. 2014; 96: e21-e23. doi: 10.1308/003588414X13946184900480

ISSN 2470-4059

OTOLARYNGOLOGY

Open Journal

Openventio PUBLISHERS

Editorial

The Origin of Facial Palsy in Multiple Sclerosis

Arianna Di Stadio, MD, PhD[1*]; Evanthia Bernitsas, MD[2]

[1]*Department of Neurology, San Camillo Hospital IRCCS, Venice, Italy*
[2]*Multiple Sclerosis Center, Wayne State University School of Medicine, Detroit, MI, USA*

***Corresponding author**
Arianna Di Stadio, MD, PhD
Assistant Professor, Department of Neurology, San Camillo Hospital IRCCS, Venice, Italy; E-mail: ariannadistadio@hotmail.com

Article information
Received: April 16th, 2018; **Accepted:** April 27th, 2018; **Published:** April 30th, 2018

Cite this article
Di Stadio A, Bernitsas E. the origin of facial palsy in multiple sclerosis. *Otolaryngol Open J.* 2018; 4(1): e1-e4. doi: 10.17140/OTLOJ-4-e006

Multiple Sclerosis (MS) is an autoimmune neurodegenerative disease that affects several people especially in North America and Canada. In 2013, 33 individuals over 100,000 were affected from MS; the estimated increase for 5 years of observation ranged from an average of 4.7 per 100,000 in high-income countries to just 0.04 per 100,000 in the low-income countries.[1]

Women are more affected than men (2.3-3.5:1), but in men, the disease is usually more aggressive and has a worse prognosis than in women.[2]

MS is a demyelinating disorder in which the immune system attacks the neural structures in the central nervous system (CNS)[3]; this mechanism is determined by a particular class of cells-*Microglia*- thathave been identified as responsible of the degenerative process. These cells, that belong to the macrophage family, have the ability to move and they can easily migrate in different part of CNS[4] and due to their two different phenotypes, an aggressive one, called M1, that induce neurodegeneration and, a protective phenotype (M2) that has neuroprotective ability[3] they may be induce demyelination and regeneration in different phases of MS, as for example, in the relapsing and remitting disease.

In the active (relapsing) stage of MS, microglia M1 induces demyelination in the area of CNS where they currently are located. If the area interested is a motor one, the patient manifests movement disorders as stiffness or motor fatigue, in case of an attack in a sensory area the sensorial perception will be the affected one.

The facial pathway, that starts in the periphery with the terminal branch of the facial nerve and ends up to the M1 area of cortex (Figure 1), may be attacked by microglia and a demyelinating process that involves one or more areas of this pathway may be symptomatic as facial palsy (FP).

Figure 1. *The Image Summarizes the Facial Pathway from Periphery (Terminal Branch of Facial Nerve) to the Brain Motor Cortex Area (M1)*

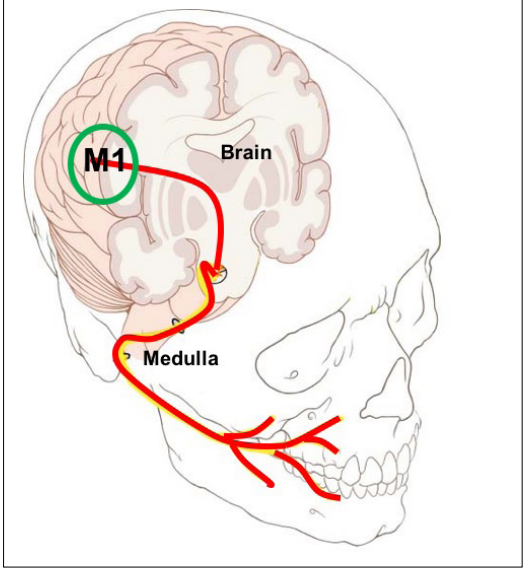

Authors report that around 7% of patients affected by MS experienced one episode of FP at least once in their life, but some controversies are still open about the origin of this symptom.

How many of these FPs are central and how many may arise from a peripheral involvement of facial nerve?

We reviewed the literature from 1997 to 2014 and we identified from a total of 16 articles, that most of the MS patients suffered from central facial involvement when they presented with a FP (Table 1).

Three authors, unfortunately, did not report details about the site of the lesions so we were not able to completely under-

Table 1. *Summary of Papers that Cite Facial Palsy in Patients with MS*

Authors	Year	Study type	Sex	Facial	MRI results
Saleh[7]	2016	Case Report	Man	yes Right side	Three lesions in the supratentorial, periventricular region. Two on the right side, one on the left (sizes between 8-13 mm). In spine small lesion at the level of the right caudal pons, inferior to the facial nucleus
Jens[8]	2015	Case Report	Woman	yes Right side started with numbness	Lesion in the floor of 4th ventricle at the pons and two in the right cerebral white matter and cerebellum
Sarigul[9]	2014	Case Report	Woman	yes Left side	Lesions in right parietal and left fronto-parietal areas
Lassemi[10]	2014	Cross-Sectional	73% women, 27% men (400 patients)	17% of sample	Not available
Danesh-Sani[11]	2013	Prospective	32% men, 68 % women (500 patients)	yes 19% of subjects	Lesion in the brain
Lee[12]	2013	Case Report	Man	yes Right side	Lesion in the midline of dorsal pons
Renard[13]	2012	Case Report	Woman	yes Left side	Lesions in the left pontine tegmentu
Uzawa[14]	2011	Case Report	Woman	yes Left side	Lesion in the left facial colliculus
Ivankovic[15]	2011	Case Report	Woman	yes Right side	Lesions in the supra and infratentorial region of the brain (periventricular, corpus callosum, pons, cerebellum
Lin[16]	2010	Case Report	Man	yes Left side	Lesion in the lateral walls of the lateral ventricles
Soltanzadeh[17]	2008	Prospective	41 Women, 12 men	yes	Not available
Kwon[18]	2008	Case Report	Woman	yes Right side started with numbness	Lesion in the right cerebellopontine angle involving the Roof Entry Zone (REZ)
Zadro[19]	2008	Retrospective	18 not defined	yes not defined	66% of the subject presented brain lesions
Critchley[20]	2004	Case Report	Man	yes Right side	Lesions diffused in the brain
Thomke[21]	1997	Prospective	2 men, 1 woman	yes not defined	No identify cablevision in MRI
Fukazawa[22]	1997	Prospective	25 subjects (men *vs.* women: 1: 2.7)	yes not defined	Lesions in the pontine tegmentum ipsilateral to the facial palsy (21 with multi nerve involvement); no lesions in the two with pure facial palsy

stand the origin of the FP.

In two cases (a man and a woman) the authors reported vestibular and auditory symptoms associated with the onset of facial palsy, while another author reported a woman that showed only vertigo complicating his facial paralysis.

In only 1 case, as reported by Kwon et al[18], the origin of facial palsy may be directly correlated with the presence of a lesion in the roof entry zone (REZ).

Overall, none of the authors reported cases of FP linkable with a peripheral demyelination process as for example an involvement of the facial nerve external to the stylus-mastoid foramen, where the nerve comes out from the fallopian canal.

It is also important to remember that a peripheral demyelination in MS patients is rarely described[5] and the most of the authors believe that the motor disease observed in MS is related to the lesion in brain, pons, and medulla more than a peripheral involvement.

In case of MS-related vestibule-cochlear involvement, instead, a peripheral involvement of inner ear might happen[4] in fact the presence of macrophages/microglia has been identified in patients affected from auto-immune diseases in human temporal bone study.[6]

We are trying to understand the reason which, in presence of a MS-related facial palsy, the central lesion mimics a peripheral involvement presenting with a complete involvement of all facial muscles.

Is it possible the majority of the lesions are located in the medulla or, the lesion in the central pathway are associated with a peripheral involvement of facial nerve in its bone tract that is not visible in the magnetic resonance imaging (MRI)?

The particular anatomy of the facial pathway supports the hypothesis of the central involvement, in fact, both cerebral hemispheres (area of motor cortex with the posterior limb of internal capsule and the corticobulbar tract) are responsible for the movement of the frontalis muscle, while only the contralateral cortex innervates the lower motor neurons that drive the muscles under the frontalis. So, due to the wide diffusion of MS lesions in the brain, is very uncommon to observe the typical "central facial palsy" in those patients (Figure 2), while is more common to observe a "peripheral facial palsy".

The action of the microglia supports the concept of superior facial pathway involvement in the MS-related facial palsy, in fact, these cells (responsible of demyelization phenomena) are

Figure 2. *The Image Illustrates the Differences between a Central Facial Palsy with Normal Frontalis Muscle Movement and a Peripheral Form in which all Muscles are Affected from Paralysis*

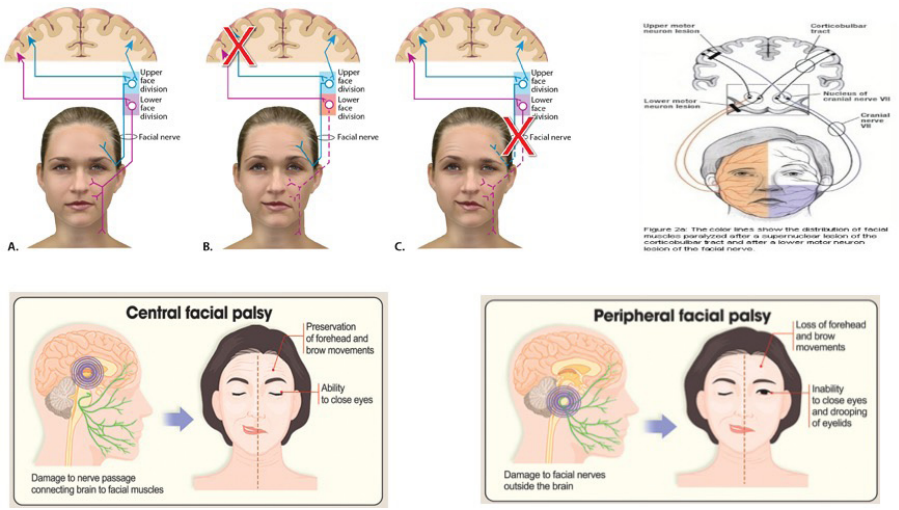

commonly found in the brain and they may migrate in other structures, as for example the inner ear, but they are rarely identified in peripheral nerves when they come out from their bone tract.

The involvement of facial nerve may be plausible in the internal auditory canal (IAC) but an attack of microglia outside this area is very improbable; furthermore, by reviewing the literature none of the authors reported lesion in the IAC in patients affected from FP so, we could deduct that the central lesions only, are responsible for the onset of facial disease.

We may conclude that the central facial pathway is responsible for the manifestations of MS-related facial paralysis.

In our opinion, additional studies are needed to evaluate the prevalence of peripheral *versus* central involvement in MS-related facial palsy, and to shed light on its pathophysiology.

CONFLICTS OF INTEREST

The authors declare that they have no conflicts of interest.

FUNDING

None.

REFERENCES

1. Browne P, Chandraratna D, AngoodC, et al. Atlas of Multiple Sclerosis 2013: A growing global problem with widespread inequity. *Neurology*. 2014; 83(11): 1022-1024. doi: 10.1212/WNL.0000000000000768

2. Harbo HF, Gold R, Tintoré M. Sex and gender issues in multiple sclerosis. *Ther Adv Neurol Disord*. 2013; 6(4): 237-248. doi: 10.1177/1756285613488434

3. Luo C, Jian C, Liao Y, et al. The role of microglia in multiple sclerosis. *Neuropsychiatr Dis Treat*. 2017; 13: 1661-1667. doi: 10.2147/NDT.S140634

4. Di Stadio A, Ralli M. Inner ear involvement in multiple sclerosis: An underestimated condition? *Mult Scler*. 2018: 1352458518750010. doi: 10.1177/1352458518750010

5. Misawa S, Kuwabara S, Mori M, Hayakawa S, Sawai S, Hattori T. Peripheral nerve demyelination in multiple sclerosis. *Clin Neurophysiol*. 2008; 119(8): 1829-1833. doi: 10.1016/j.clinph.2008.04.010

6. O'Malley JT, Nadol JB Jr, McKenna MJ. Anti CD163+, Iba1+, and CD68+ Cells in the adult human inner ear: Normal distribution of an unappreciated class of macrophages/microglia and implications for inflammatory otopathology in humans. *Otol Neurotol*. 2016; 37(1): 99-108.

7. Saleh C, Patsi O, Mataigne F, Beyenburg S. Peripheral (Seventh) nerve palsy and multiple sclerosis: A diagnostic dilemma - A case report. *Case Rep Neurol*. 2016; 8(1): 27-33. doi: 10.1159/000443681

8. Jens W, Ahmed A. Eight and a Half Syndrome from Multiple Sclerosis. *J Neurol Stroke*. 2015; 3(4): 00099. doi: 10.15406/jnsk.2015.03.00099

9. Sarigül A, Akça S, Evin B, Singar E, Pınarcı EY. A case of multiple sclerosis presented with 5th, 6th and 7th cranial nerve paralysis. *Turk J Ophthalmol*. 2015; 45: 81-83

10. Lassemi E, Sahraian MA, Motamedi MHK, et al. Oral and facial manifestations of patients with multiple sclerosis. *Dentistry* . 2014; 4: 194. doi: 10.4172/2161-1122.1000194

11. Danesh-Sani SA, Rahimdoost A, Soltani M, Ghiyasi M, Haghdoost N, Sabzali-Zanjankhah S. Clinical assessment of orofacial manifestations in 500 patients with multiple sclerosis. *J Oral Maxil-*

lofac Surg. 2013; 71(2): 290-294. doi: 10.1016/j.joms.2012.05.008

12. Lee H, de Kort PLM. 16 Syndrome in a Patient with Multiple Sclerosis. *J Neuroophthalmol*. 2013; 33(2): 203-204. doi: 10.1097/WNO.0b013e318284240d

13. Renard D, Poalelungi A, Collombier L, Labauge P. Cranial neuropathies in multiple sclerosis defined by magnetic resonance imaging and fludeoxyglucose f 18 positron emission tomography. *Arch Neurol*. 2012; 69(4): 541-542. doi: 10.1001/archneurol.2011.1936

14. Uzawa A, Mori M, Ito S, Kuwabara S. Neurological picture. Isolated abducens and facial nerve palsies due to a facial collicular plaque in multiple sclerosis. *J Neurol Neurosurg Psychiatry*. 2011; 82(1): 85-86. doi: 10.1136/jnnp.2010.206870

15. Ivanković M, Demarin V. From recurrent peripheral facial palsy to multiple sclerosis. *Acta Clin Croat*. 2011; 50(3): 419-421.

16. Lin Catherine J, Goodman Robert I. Isolated central facial nerve palsy as presentation of multiple sclerosis. *Proceedings of UCLA Healthcare*. 2010; 14: 1-4.

17. Soltanzadeh A, Sharifi M, Ilkhchoui Y, Sikaroodi H. Isolated facial palsy in Iranian multiple sclerosis patients. *Neurology Asia*. 2008; 13: 73-75.

18. Kwon JY, Kim JY, Jeong JH, Park KD. Multiple sclerosis and peripheral multifocal demyelinating neuropathies occurring in a same patient. *J Clin Neurol*. 2008; 4(1): 51-57. doi: 10.3988/jcn.2008.4.1.51

19. Zadro I, Barun B, Habek M, Brinar VV. Isolated cranial nerve palsies in multiple sclerosis. *Clin Neurol Neurosurg*. 2008; 110(9): 886-888. doi: 10.1016/j.clineuro.2008.02.009

20. Critchley EP. Multiple sclerosis initially presenting as facial palsy. *Aviat Space Environ Med*. 2004; 75(11): 1001-1004.

21. Thömke F, Lensch E, Ringel K, et al. Isolated cranial nerve palsies in multiple sclerosis. *J Neurol Neurosurg Psychiatry*. 1997; 63: 682-685. doi: 10.1136/jnnp.63.5.682

22. Fukazawa T, Moriwaka F, Hamada K, Hamada T, Tashiro K. Facial palsy in multiple sclerosis. *J Neurol*. 1997; 244(10): 631-633.

ISSN 2470-4059

OTOLARYNGOLOGY
Open Journal

Openventio PUBLISHERS

Systematic Review

Surgıcal Techniques for the Treatment of Concha Bullosa: A Systematic Review

Esmail Abdulahi Ahmed, MD[1*]; Deniz Hanci, MD[2]; Onur Üstün, MD[3]; Imran Aydogdu, MD[4]; Erdi Özdemir, MD[5]; Semih Karaketir, MD[6]; Yavuz Uyar, MD[7]; Tolgar Lütfi Kumral, MD[8]

[1]*Resident, Department of Otorhinolaryngology-Head and Neck Surgery, Okmeydanı Training and Research Hospital, Darulaceze Cad. No: 25 Posta Kodu: 34400 Okmeydanı, Sisli, Istanbul, Turkey*
[2]*Specialist, Okmeydanı Training and Reseacrh Hospital ENT Clinic, Sisli, Istanbul, Turkey*
[3]*Resident, Okmeydanı Training and Reseacrh Hospital ENT Clinic, Sisli, Istanbul, Turkey*
[4]*Specialist, Bahçelievler Hospital ENT Clinic, Sisli, Istanbul, Turkey*
[5]*Specialist, Okmeydanı Training and Reseacrh Hospital ENT Clinic, Sisli, Istanbul, Turkey*
[6]*Resident, Okmeydanı Training and Reseacrh Hospital ENT Clinic, Sisli, Istanbul, Turkey*
[7]*Professor, Okmeydanı Training and Reseacrh Hospital ENT Clinic, Sisli, Istanbul, Turkey*
[8]*Associate Professor, Okmeydanı Training and Reseacrh Hospital ENT Clinic, Sisli, Istanbul, Turkey*

***Corresponding author**
Esmail abdulahi Ahmed, MD
Resident, Department of Otorhinolaryngology-Head and Neck Surgery, Okmeydanı Training and Research Hospital, Darulaceze Cad. No: 25 Posta Kodu: 34400 Okmeydanı, Sisli/Istanbul, Turkey; E-mail: ismodho@gmail.com

Article information
Received: February 20th, 2018; **Revised:** April 26th, 2018; **Accepted:** May 3rd, 2018; **Published:** May 4th, 2018

Cite this article
Ahmed EA, Hanci D, Üstün O, et al. Surgıcal techniques for the treatment of concha bullosa: A systematic review. *Otolaryngol Open J*. 2018; 4(1): 9-14. doi: 10.17140/OTLOJ-4-146

ABSTRACT

Objectives
As there is no defined technique for surgery of concha bullosa the aim of this article is to review the literature and compare different techniques used for concha bullosa reduction.

Methods
A structured review of the PubMed, Embase and Cochrane Collaboration databases (Cochran Central Register of Controlled Trials, Cochran Database of Systemic Reviews) was undertaken, using the terms: conchabullosa, turbinoplasty, partial middle turbinectomy and pneumatized middle turbinate.

Results
Total of 142 articles were found and only articles addressing surgical procedures of concha bullosa with available full-text articles were included, and only 16 articles were eligible for our criteria.

Conclusion
A variety of surgical techniques are described to deal with symptomatic concha bullosa. According to this review, the most preferred technique is lateral laminectomy of the middle turbinate. There is a need for larger populated and objectively evaluated comparison studies to be done.

Keywords
Conchabullosa; Middle turbinectomy; Turbinoplasty.

Abbreviations
FESS: Functional Endoscopic Sinus Surgery; MTHS: Middle Turbinate Headache Syndrome.

Otolaryngol Open J. 2018; 4(1): 9-14. doi: 10.17140/OTLOJ-4-146

INTRODUCTION

Concha bullosa, a pneumatized middle turbinate, is one of the most common anatomic variants of the lateral wall of the nose. As previously described in literature the most common anatomical variations are ager nasi, septal deviation and concha bullosa respectively.

The incidence of concha bullosa was reported of 49.3% by Fadda et al,[1] 42.6% by Maru and Gupta,[2] 53.6 % by Bolger et al.[3] Due to the difference of criteria used among investigators the reported prevalence of concha bullosa varies among studies. Concha bullosa causes crowded nose and obstruction of middle meatus. This can result in obstruction of the ventilation and mucociliary drainage of the maxillary, anterior ethmoid, and frontal sinuses or of nasal airflow. Additionally, the concha bullosa itself may cause a rhinogenic headache. There is no clear definition for pneumatization of concha[3] and also there is no clear consensus on surgical indication for concha bullosa. The main purpose of this review is concha bullosa and its surgical intervention.

METHODS

A structured review of the PubMed, EMBASE and Cochrane Collaboration databases (Cochran Central Register of Controlled Trials, Cochran Database of Systemic Reviews) was undertaken, using the terms: "*conchabullosa*", "*turbinoplasty*", "*partial middle turbinectomy*" and "*pneumatized middle turbinate*".

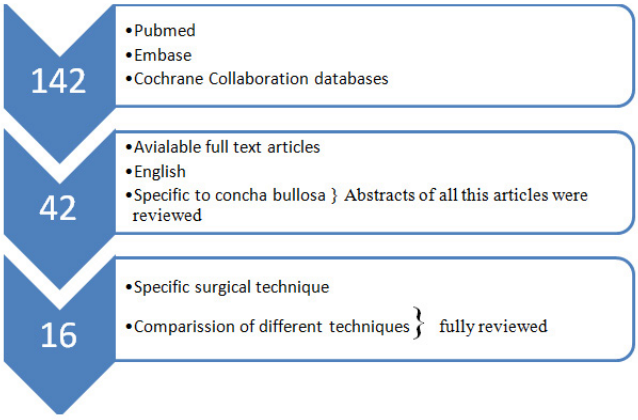

RESULTS

Total of 142 articles was found in the first step, only abstracts of 42 articles in English and available full-text articles were selected. In the second step describing surgical procedures of concha bullosa were included in this review article and fully reviewed. The main criteria for inclusion were the article must be describing the specific surgical technique or comparing different techniques, only 16 articles were eligible for our criteria and included in this review.

DISCUSSION

Structurally, the middle turbinate can be divided into three segments. The anterior third attaches vertically to the skull base just lateral to the cribriform plate. The middle segment, the ground or basal lamella, turns laterally, attaching to the orbital plate of the ethmoid bone (lamina papyracea) and divides the ethmoid sinus into an anterior and a posterior group of cells. The posterior segment of the middle turbinate is oriented horizontally and inserts onto the perpendicular process of the palatine bone. The anterior superior portion of the middle turbinate is an important surgical landmark and forms the medial boundary of the frontal recess. The only used classification is described by Bolger et al and classified them into three types of concha bullosa: 1) lamellar type concha bullosa; pneumatization is localized to the vertical lamella of the middle turbinate. 2) bulbous type concha bullosa; pneumatization of the inferior bulbous part of the middle turbinate. 3) true or extensive type concha bullosa is pneumatization of both the vertical lamella and the inferior part of the middle turbinate (Figure 1).[3]

Middle turbinate can lead to structural narrowing of the frontal sinus outflow tract and frontal sinusitis. Middle turbinate is part of osteomeatal complex which is a key area for chronic rhinosinusitis.

There is a separate function of the middle turbinate, mainly deflection of inspired air superiorly towards olfactory epithelium, providing moisture to inspired air and aeration of sinuses, and mucociliary transport. Enlargement of middle turbinate has a negative consequence on nasal physiology such as obstruction and impaired mucociliary clearance which leads to local inflammation and eventually chronic inflammation. It is known that middle

Figure 1. *a) Lamellar Type Concha Bullosa. b) Bulbous Concha Bullosa. c) Extensive Type Concha Bullosa*

Otolaryngol Open J. 2018; 4(1): 9-14. doi: 10.17140/OTLOJ-4-146

turbinate has a role in the olfactory function and the precise anatomical distribution of olfactory neuroepithelium is unknown. Although, there are many studies on the olfactory epithelium of nasal cavity, only Apuhan et al[4] studied olfactory epithelium of concha bullosa and found more nerve tissues on a lateral surface of concha. Recent studies show that olfactory mucosa is distributed more anteriorly and inferiorly than previously described dorsoposterior and also is presented in the surface epithelium of the lower medial surface of the middle turbinates.[5]

There are studies pointing out that the size of concha bullosa is important for the presence of symptoms. Although, there was no significant relationship detected between nasal septal deviation, concha size and rhinosinusitis, several studies reported that rhinosinusitis was detected more frequently in cases with extensive type concha bullosa.[6] Unlu et al[7] did not detect any relationship between concha bullosa and disease of ostiomeatal complex. However, they found that the bulbous type of concha bullosa had more effect on osteomeatal complex disease than other types of concha bullosa.

Bolger and Lloyd described specifically that recurrent sinus disease occurred through concha bullosa's compressing the uncinate process or through narrowing or obstructing the middle meatus and infundibulum.[3] The mucociliary transport of concha bullosa is most frequently in the frontal recess and rarely to the adjacent air cells and hiatus semilunaris. However, Yousem et al[8] put forward that concha bullosa was not one of the elements that led to rhinosinusitis and also reported that its size was significant. Nevertheless, Stallman et al reported that there was no significant relationship between the concha bullosa size and development of rhinosinusitis.[9] Zinreich et al and Calhoun et al[10,11] stated that concha bullosa is found more frequently in a symptomatic group of patients with sinusitis compared with the asymptomatic group.

The other pathological condition of concha bullosa is when it causes contact points that can trigger a rhinogenic headache. The nerve supply of middle turbinate derives from the sphenopalatine ganglion and its branches, except for the anterior extremity, which is supplied by the anterior and ethmoidal nerves. This indicates the role of concha bullosa on rhinogenic headache. Morgenstein and Krieger[12] described a middle turbinate headache syndrome (MTHS) that produces a typical pain pattern without being associated with any infectious process in the facial sinuses. Morgenstein and Krieger used the term middle turbinate syndrome and categorized as a pain and obstruction syndromes caused by middle turbinate also they used this for surgical indication criteria.

As it is seen, no consensus on this matter has been achieved yet. Also, there is no described absolute indication for surgery. It depends on the clinic and radiologic symptoms of the patient. Surgical management is recommended if concha bullosa is felt to be contributing to the patient's symptoms or the patient's disease. The main aim of surgery is to remove the pathology caused by enlarged middle turbinate. And to alleviate the nasal obstruction in extremely large concha cases. Sometimes it becomes necessary to facilitate visualization of the osteomeatal complex during endoscopic sinus surgery. Besides, concha bullosa surgery is done for a rhinogenic headache, unfortunately, information about this concept is very limited due to the diagnostic and therapeutic difficulty and mostly this surgery is done together with septoplasty and functional endoscopic sinus surgery.[13]

SURGICAL TECHNIQUES

Today there are many different approaches for the surgical treatment of concha bullosa, such as lateral or medial partial resection, total resection, turbinoplasty, crushing and crushing with intrinsic stripping but there is no clear consensus for the best surgical technique yet. (Summarized in Table 1).

Total middle turbinectomy was not used specifically for concha bullosa. Medial excision of the concha bullosa was first described by Pirsig[14] and Huizing[15], removing only the medial lamella of the middle turbinate. As described by Canon et al[16] the rationale for this was to leave a mucosal covered surface to face the middle meatus of the nose when functional endoscopic sinus surgery (FESS) is performed and this technique is best used for cases of nasal obstruction without sinus disease. One advantage of this technique is nasal packing is not used unless concomitant septal surgery is done. Kumral et al compared the functional outcomes of medial and lateral turbinectomy and did not find any significant difference between the two techniques. They evaluated the patient's olfactory function and postoperative synechia. Medial excision of concha bullosa has the advantage of preventing the development of frontal sinusitis by preventing the formation of frontal recess synechia.[17]

Lateral excision of the middle turbinate is the most used technique in isolated concha bullosa. The concha bullosa has been described to drain the frontal sinus recess. Braun and Stammberger[18] supported lateral excision of concha bullosa and crushing if necessary rather than medial excision because of middle turbinate is attached to the skull base medially and medial excision causes destabilization of the middle turbinate. All concha bullosa have an ostium and their own mucociliary transport, this ostium should always be included in the resection of the lateral lamella to avoid persisting circular transport of the mucus. In their study on different techniques of endoscopic concha bullosa surgery Canon et al preferred this technique because of lateral excision technique has the advantage of facilitating drainage from the frontal sinus recess into the middle meatus.[19] The disadvantage of this technique is a risk of synechia formation especially when FESS is performed. The rate of synechia for isolated concha bullosa reduction surgery is very low; Canon et al and kumral et al reported no synechia while Doğru et al reported synechia rate of 27%.[13] But this was not isolated concha bullosa surgery same patients had the extra intervention of osteomeatal complex. The rates of synechia are low when the mucosa is preserved (Table 2). Har-el and H slavit[20] described a new technique by removing only medial lamella of the concha while preserving mucosa, their focus was preventing the formation of synechia, with synechia rate of 6.9% (3 of 43 cases) in their four years follow-up. Singston et al[21] described a similar technique by preserving posteroinferior pedicled flap and reported that this significantly reduces adhesions, may be because it covers the main potential contact surface. Similarly, Dogru et al[13] compared later-

Table 1. *Summarry of Surgical Techniques*

Eren et al[27]	42 patients and 55 concha	Prospective	Long-term outcomes of crushing and crushing with intrinsic stripping.	Intrinsic stripping with crushing showed significant reduction according to the other group.
Mandour and Kalza[31]	42 patients	Prospective	Using crusher (Kressner turbinate crushing forceps (4 mm wide, 21 cm, InkaTM Surgical Instruments))	The technique is best used when the air cells within the turbinates are large. Resective techniques, on the other hand, may be used when enlargement of the turbinates is due to hypertrophy of its tissues rather than the presence of air cells.
Kocak et al[26]	71 patients	Prospective study	Is it effective to use the crushing technique in all types of concha bullosa	Crushing technique in an effective method in all types of concha bullosa and it appears to be more potent in volume reduction on bulbous type. Compliance
Song et al[32]	4 patients	Case report	Concha bullosa crusher	After a one year follow up, there has been no regrowth of the middle turbinate, no evidence of mucocele formation, and no clinical evidence of sinus disease or nasal obstruction
Har-el and H slavit[20]	36 patients	Prospective	Turbinoplasty for concha bullosa: A non-synechiaeforming alternative to middle turbinectomy	A 4-year experience with this procedure showed almost complete elimination of the synechiae problem.
Dogru H et al[13]	131 patients	Prospective	Turbinoplasty was performed by a modified Har-El and Slavit technique	Advantageous because it results in minimal mucosal injury, plus it evenly brings the conchal walls together.
Kumral et al[17]	72 patients	Randomized controlled trail	Comparison of medial and lateral laminectomy group 1: medial laminectomy (n=34) and group 2: lateral laminectomy (n=38).	This study revealed that medial laminectomy for aeration of the middle turbinate was as effective as lateral laminectomy.
Sigston et al[21]	47 patients	Prospective controlled	A mucosa-preserving posterior pedicled flap.	A mucosa-preserving posterior pedicled flap is a minor modification to partial lateral turbinectomy for concha bullosa reduces adhesions while speeding recovery.
Canon et al[16]	242 patients	Retrospective	Endoscopic management of conchabullosa	The only study comparing different techniques. But being retrospective and small number of patients are greatest handicaps but the author prefers excision of the lateral portion of the pneumatized turbinate. Procedure can be carried concomitantly with septal or FESS procedures, and has been free of any significant complications.
Mehta and Kaluskar[28]	36 patients	Prospective	Endoscopic turbinoplasty of Concha Bullosa: Long Term Results	States that endoscopic turbinoplasty is safe and effective procedure for concha bullosa. It preserves middle turbinate anatomically and physiologically and treats the concha with negligible complications.
Morgenstein and Kreiger[12]	36 patients	Prospective	Experience in middle turbinectomy	Good to excellent with no long-term adverse sequel. There has been no crusting, drying, or infection as a result of our middle turbinectomies. Careful patient selection is critical.
Tanyeri et al[24]	22 patients	Prospective study	Endoscopically and radiologically evaluated whether a surgically crushed concha bullosa can form again	Concha bullosa crushing technique is an easy, conservative treatment modality. As the concha bullosa does not appear toreform after crushing, this technique can be considered a definitive treatment. Nevertheless, these patients should be followedfor the long-term.

Table 2. *Rate of Synechia Reported in Turbinectomy and Turbinoplasty*

Author	Lateral turbinectomy	Turbinoplasty
Dogru et al[13]	27 %	9.7%
Shih et al[29]	16%	12.9%
Ramadan and Allen[30]	5.3%	9.3%

al turbinectomy and turbinoplasty by modified Har-El and Slavit technique by cutting the concha both superiorly and inferiorly to allow the lamella adhere evenly and preventing the formation of mucocele.

The least used technique is the transverse excision of the turbinate. This technique is reported by Canon et al for only middle turbinate that attached to the skull base with the narrow pedicle. There is no specific study describing the use of transverse excision of concha bullosa. Choby et al reported in their systematic meta-analysis on clinical effects of middle turbinate resection, that no significant difference was found in total resection of middle turbinate and partial resection of the middle turbinate.[22] Studies in favor of middle turbinate resection believe that it leads to decreased post-operative synechia formation and improved sinus outflow tract patency. Middle turbinate resection may allow for better intra-operative and post-operative visualization of the paranasal sinuses. Its biggest drawback is the loss of surgical landmarks.

In recent years several studies report that olfactory dysfunction is encountered less with the crushing technique than with

other techniques. However, crushing is not applied for large concha bullosa, which requires partial resection. In performing the crushing technique, several instruments are used.[23] While the technique is easy and conservative, there are studies which reported recurrence. Tanyeri et al did prospective study enrolled 14 adults with concha bullosa and did not find any recurrence of pneumatization of concha bullosa.[24] Most studies expressed short time follow-up. Only one study with long-term follow-up reported that the middle concha pneumatized again. Kieff and Busaba[25] have reported concha bullosa recurrence after crushing. They reported 10 cases of recurrence between 2 and 15 years after the initial surgery. However, their data was limited to re-pneumatization after crushing, they didn't mention about whether the patients' symptoms recurred again, also they did not state the total number of patients who underwent crushing. Kocak et al applied crushing to 95 concha bullosa cases and followed them for approximately 2 years and have not encountered a reformation in any of the cases. Also according to the other types of concha bullosa they concluded that bulbous type has more effective result than other types of concha bullosa.[26] Most of the recent studies documented that in none of the cases the concha bullosa regressed to its original form in short-term follow-ups after crushing.

Eren SB et al[27] compared crushing technique with crushing with intrinsic stripping and stated that faces of their conchae completely adhered to each other. These findings may be due to the excision of the inner lamella, thus allowing the two mucosal surfaces to come together. Mehta R et al also described a similar technique by removing bony lamella and preserving mucosa of middle turbinate and reported very low rate of synechia 7.6% according to other studies and also healing is quicker without usual postoperative crusting.[28] This technique is more manipulative and time-consuming according to the other techniques.

CONCLUSION

Because of development of diagnostic tools nowadays the importance of concha bullosa in rhinology is rising and surgical intervention is easier and favorable than it was before. But there is no clear consensus about criteria for surgical indication of concha bullosa and lack of more objectively evaluated and a long period followed-up studies comparing the surgical procedure of concha bullosa. Preference of which technique to use is dependent more on surgeon's experience. There is no specific study comparing all techniques and as is seen in this literature review most preferred technique is lateral laminectomy of the middle turbinate. There are several modified techniques of lateral excision of middle turbinate to reduce the rate of synechia. The crushing technique of concha bullosa with traumatizing instruments is effective in nonextensive types of concha bullosa. There is a need for larger populated objectively evaluated comparison studies to be done.

CONFLICTS OF INTEREST

We affirm that there is no actual or potential conflict of interest including any financial, personal or other relationships with other people or organizations.

REFERENCES

1. Fadda G, Rosso S, Aversa S, Ondolo C, Succo G. Multiparametric statistical correlations between paranasal sinus anatomic variations and chronic rhinosinusitis Correlazione statistica multiparametrica tra variazioni anatomiche rinosinusali e rinosinusite cronica. *ACTA Otorhinolaryngol Ital.* 2012; 32: 244-251.

2. Maru YK, Gupta Y. Concha bullosa: Frequency and appearances on sinonasal CT. *Indian J Otolaryngol Head Neck Surg.* 1999; 52: 40-44. doi: 10.1007/BF02996431

3. Bolger WE, Butzin CA, Parsons DS. Paranasal sinus bony anatomic variations and mucosal abnormalities: CT analysis for endoscopic sinus surgery. *Laryngoscope.* 1991; 101(1): 56-64.doi: 10.1288/00005537-199101000-00010

4. Apuhan T, Yıldırım YS, Şimşek T, Yılmaz F, Yılmaz F. Concha bullosa surgery and the distribution of human olfactory neuroepithelium. *Eur Arch Otorhinolaryngol.* 2013; 270: 953-957. doi: 10.1007/s00405-012-2173-6

5. Richtsmeier WJ, Cannon CR. Endoscopic management of concha bullosa. *Otolaryngol Neck Surg.* 1994; 110(4): 449-454. doi: 10.1177/019459989411000419

6. Tunçyürek Ö. The relationship among concha bullosa, septal deviation and chronic rhinosinusitis. *J Med Updat.* 2013; 3(1): 1-7. doi: 10.2399/jmu.2013001002

7. Unlu HH, Akyar S, Caylan R. Concha bullosa. *J Otolaryngol.* 1994; 23(1): 23-27.

8. Yousem DM, Kennedy DW, Rosenberg S. Ostiomeatal complex risk factors for sinusitis: CT evaluation. *J Otolaryngol.* 1991; 20: 419-424.

9. Stallman JS, Lobo JN, Som PM. The incidence of concha bullosa and its relationship to nasal septal deviation and paranasal sinus disease. *AJNR Am J Neuroradiol.* 2004; 25(9): 1613-1618.

10. Zinreich SJ, Mattox DE. Concha bullosa: CT evaluation. *J Comput Assist Tomogr.* 12(5): 778-784.

11. Calhoun KH, Waggenspack GA, Simpson CB, Hokanson JA, Bailey BJ. CT evaluation of the paranasal sinuses in symptomatic and asymptomatic populations. *Otolaryngol Head Neck Surg.* 1991; 104(4): 480-483. doi: 10.1177/019459989110400409

12. Morgenstein KM, Krieger MK. Experiences in middle turbinectomy. *Laryngoscope.* 1980; 90(10): 1596-1603. doi: 10.1288/00005537-198010000-00002

13. Doğru H, Tüz M, Uygur K, Cetin M. A new turbinoplasty technique for the management of concha bullosa: Our short-term outcomes. *Laryngoscope.* 2001; 6: 172-174. doi: 10.1097/00005537-200101000-00030

14. Pirsig W. Reduction of the middle turbinate. *Rhinology*. 1972; 10: 103-108.

15. Huizing EH. Functional surgery in inflammation of the nose and paranasal sinuses. *Rhinol Suppl*. 1988; 5: 5-15.

16. Cannon CR. Endoscopic management of concha bullosa. *Otolaryngol Neck Surg*. 1994; 110(4): 449-454. doi: 10.1177/019459989411000419

17. Kumral TL, Yıldırım G, Çakır O, et al. Comparison of two partial middle turbinectomy techniques for the treatment of a concha bullosa. *Laryngoscope*. 2015; 125(5): 1062-1066. doi: 10.1002/lary.25065

18. Braun H, Stammberger H. Pneumatization of turbinates. *Laryngoscope*. 2003; 113(4): 668-672. doi: 10.1097/00005537-200304000-00016

19. Richtsmeier WJ, Cannon CR. Endoscopic management of concha bullosa. *Otolaryngol Neck Surg*. 1994; 110: 449-454. doi: 10.1177/019459989411000419

20. Har-el G, Slavit DH. Turbinoplasty for concha bullosa: A non-synechiae-forming alternative to middle turbinectomy. *Rhinology*. 1996; 34(1): 54-56.

21. Sigston EAW, Iseli CE, Iseli TA. Concha bullosa: Reducing middle meatal adhesions by preserving the lateral mucosa as a posterior pedicle flap. *J Laryngol Otol*. 2004; 118(10): 799-803. doi: 10.1258/0022215042450814

22. Choby GW, Hobson CE, Lee S, Wang EW. Clinical effects of middle turbinate resection after endoscopic sinus surgery: A systematic review. *Am J Rhinol Allergy*. 2014; 28(6): 502-507. doi: 10.2500/ajra.2014.28.4097

23. Dogru H, Uygur K, Tuz M. Concha bullosa squeezer for turbinoplasty (Doğru forceps). *J Otolaryngol*. 2004; 33(2): 111-113.

24. Tanyeri H, Aksoy EA, Serin GM, Polat S, Türk A, Unal OF. Will a crushed concha bullosa form again? *Laryngoscope*. 2012; 122(5): 956-960. doi: 10.1002/lary.23234

25. Kieff DA, Busaba NY. Reformation of concha bullosa following treatment by crushing surgical technique: Implication for balloon sinuplasty. *Laryngoscope*. 2009; 119(12): 2454-2456. doi: 10.1002/lary.20640

26. Kocak I, Gokler O, Dogan R. Is it effective to use the crushing technique in all types of concha bullosa. *Eur Arch Oto-Rhino-Laryngology*. 2016; 273(11): 3775-3781. doi: 10.1007/s00405-016-4097-z

27. Eren SB, Kocak I, Dogan R, Ozturan O, Yildirim YS, Tugrul S. A comparison of the long-term results of crushing and crushing with intrinsic stripping techniques in concha bullosa surgery. *Int Forum Allergy Rhinol*. 2014; 4: 753-758. doi: 10.1002/alr.21360

28. Mehta R, Kaluskar SK. Endoscopic turbinoplasty of concha bullosa: Long term results. *Indian J Otolaryngol Head Neck Surg*. 2013; 65(Suppl 2): 251-254. doi: 10.1007/s12070-011-0368-6

29. Shih C, Chin G, Rice DH. Middle turbinate resection: Impact on outcomes in endoscopic sinus surgery. *Ear Nose Throat J*. 2003 [cited 2018 May 2]; 82: 796-797.

30. Ramadan HH, Allen GC. Complications of endoscopic sinus surgery in a residency training program. *Laryngoscope*. 1995; 105: 376-379. doi: 10.1288/00005537-199504000-00007

31. Mandour Z, Kalza R. A simple minimally invasive technique to reduce the size of pneumatized middle turbinate (Concha Bullosa). *Otolaryngology*. 2016; 6: 3-5. doi: 10.4172/2161-119X.1000242

32. Song B, Tang C, Campano R, et al. The concha bullosa crusher: A novel technique. 2013; 27: 2454.

ISSN 2470-4059

OTOLARYNGOLOGY

Open Journal

Openventio PUBLISHERS

Case Report

Post-Radiation Sphenoidal Mucocele in a Patient Treated for Nasopharyngeal Cancer

Makram Tbini, MD*; Souheil Jbali, MD; Skander Kedous, MD; Mohamed Abderraouf Harhira, MD; Sawssen Dhambri, MD; Zied Attia, MD; Slim Touati, MD; Said Gritli, MD

Otorhinolaryngology-Head and Neck Surgery Department, Salah Azaiez Institute of Oncology, Tunis, Tunisia

***Corresponding author**
Makram Tbini, MD
Otorhinolaryngology-Head and Neck Surgery Department, Salah Azaiez Institute of Oncology, Tunis, Tunisia; Tel. +216 21266616; E-mail: makramtb@yahoo.com

Article information
Received: March 28th, 2018; **Revised:** April 26th, 2018; **Accepted:** June 21st, 2018; **Published:** July 18th, 2018

Cite this article
Tbini M, Souheil J, Kedous S, et al. Post-radiation sphenoidal mucocele in a patient treated for nasopharyngeal cancer. *Otolaryngol Open J*. 2018; 4(1): 15-17. doi: 10.17140/OTLOJ-4-147

ABSTRACT

The paranasal sinus mucoceles are epithelial-lined cystic lesions containing mucus or mucopurulent fluid. Several theories have been advanced to explain their occurrence. Previous trauma and sinus surgery are the most common cause. Mucoceles following radiotherapy are rare.

We report the case of a sphenoidal mucocele in a 62-year-old woman who had received radiotherapy 13 years ago for a nasopharyngeal carcinoma. Marsupialisation through an endoscopic transnasal approach was performed. No evidence of recurrence seen after 12 months of follow-up.

Keywords
Mucocele, Sphenoid sinus, Nasopharyngeal cancer, Radiotherapy.

INTRODUCTION

Mucoceles are benign rare cystic tumours which may originate from any sinus cavities when their natural ostia are blocked. As there is no drainage pathway in these closed sacs, the mucocele expands as the secretions collect. As a result, it exerts pressure on the surrounding structures.[1] Previous trauma and sinus surgery are the most common cause. Mucoceles following radiotherapy are rare. They occur usually after irradiation for a nasopharyngeal cancer in the sphenoid sinus. Few cases have been reported in literature.[2]

The aim of this article is to report the importance of clinical and radiological follow-up in patients treated from nasopharyngeal cancer, not only to detect tumour recurrences but also complications such as mucoceles.

CASE REPORT

A 62-year-old woman with a history of undifferentiated nasopharyngeal carcinoma (T2 N0 M0), treated with radiotherapy 13-years-ago, was referred to our department with the complaint of bilateral nasal obstruction and headaches for 11 months.

Ears, nose and throat (ENT) examination and nasal fibroendoscopy revealed no abnormalities. Neurological and ophthalmological examination were normal.

So magnetic resonance imaging (MRI) was performed looking for tumour recurrence and showed a cystic lesion with a high signal intensity on T1-weighted image and a low signal intensity on T2-weighted image, limited in the sphenoid sinus (Figures 1 and 2).

Therefore, the sphenoid sinus was approached under general anaesthesia through an endoscopic approach. A biopsy of the sphenoid sinus and marsupialisation of the mucocele were performed. But no malignant cells were found in histological examination.

Patient had an uneventful post-operative course with no evidence of recurrence seen after 12 months of follow-up.

Otolaryngol Open J. 2018;4(1):15-17. doi: 10.17140/OTLOJ-4-147

Figure 1. *MRI, Axial Cut Showing a Cystic Lesion in the Sphenoid Sinus with a High Signal Intensity on T1-Weighted Image*

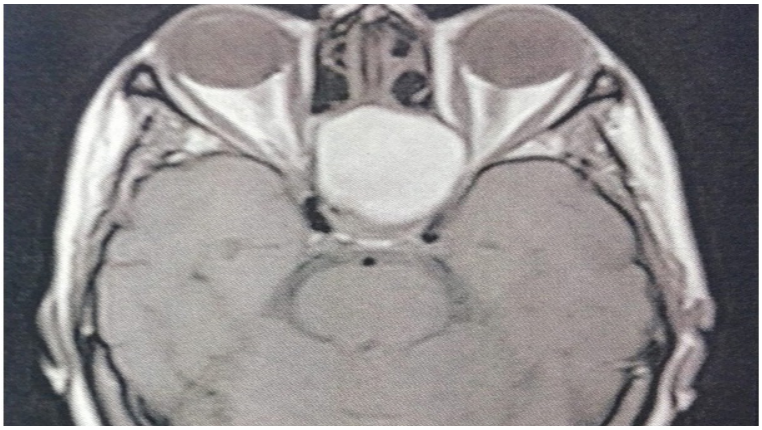

Figure 2. *MRI, Sagittal Cut Showing a Cystic Lesion in the Sphenoid Sinus with a High Signal Intensity on T1-Weighted Image*

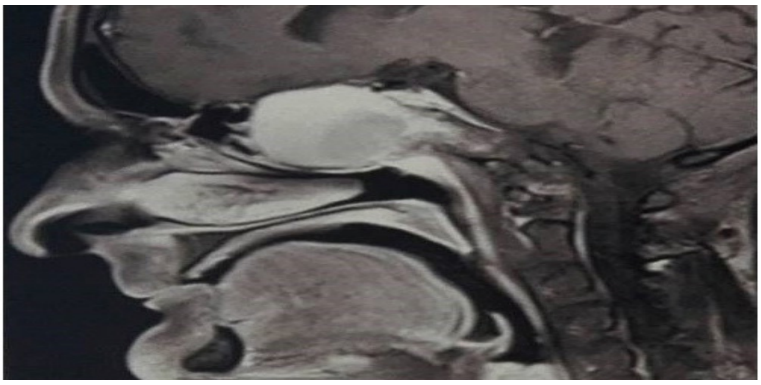

DISCUSSION

Paranasal sinusmucoceles are benign pseudocystictumors, they have an expansive and destructive tendency and a slow evolution.[1]

All locations are possible; they are frequently found in the frontal sinus, the anterior ethmoidal sinus, the maxillary sinus, while posterior ethmoidal sinus and sphenoid sinus are rarely affected (less than 1%).[3]

Ostial obstruction have been advanced to explain their etiopathogenesis. Mucocele predisposing factors include chronic rhinosinusitis, allergic rhinitis, cranio-facial trauma, sinus surgery, nasosinusaltumors, and radiotherapy.[4,5]

Mucoceles have been reported to be more frequent in men, with a peak incidence in the third or fourth decade of life.[6]

Few cases of mucocele occurring after radiation therapy for tumors of the head and neck region were reported in the literature. Irradiation for nasopharyngeal carcinoma and sphenoidal seat are the most frequently reported.[2,5,7-9]

Radiotherapy can cause obstruction of the sinus ostium by induced fibrosis.[5,7,8]

Mucoceles can cause various signs and symptoms, depending on the affected area; those symptoms can be rhinological, ophthalmic or neurological.[10]

Imaging is essential for the diagnosis and management of paranasal sinusmucoceles, it is based on computerized tomography (CT) scan and MRI.[11,12]

On CT-scan, mucoceles can be hypodense, isodense or hyperdense with peripheral enhancement after injection of contrast agents, bone erosion can be found. This variability on densities is due to their protein content, inspissation and possible surinfection. At MRI, the signal of the mucocele is also variable depending on the viscosity and protein content. Mucocele generally presents a low signal intensity on T1-weighted image, a high signal intensity on T2-weighted image with enhancement of its wall after injection of gadolinium. For old forms, mucoceles present a low signal intensity on T1 and T2, but other forms of signal intensity can be found.[11,13]

Therefore, imaging is useful to rule outother lesions in the sphenoid sinus and the skull base that may mimic sphenoidal mucocele such as necrotic primary adenoma with significant in-

trasellar extension, craniopharyngioma, chordoma, plasmacytoma, osteoma, osteoblastoma, basal cell and squamous cell carcinoma, rhinolitis, polyps, and fibrous dysplasia.[14]

In all cases, mucoceles treatment must be surgical and depends on the location of the mucocele and its extension, and can be through endoscopic, external or combined approach. Nevertheless, endoscopic marsupialization has become the surgical approach of choice given its low morbidity, short time procedure, reduced damage to the nasal structure and physiology, good functional results and rapid patient discharge.[12,15]

Finally, a regular clinical and radiological follow-up after surgery is essential in order to look for tumor or mucocele recurrence and for complications such synechiae.[4,14]

CONCLUSION

Sphenoidal mucocele is a possible complication of radiotherapy in patients with nasopharyngeal carcinoma that can mimic recurrence. Computerized tomography scan and magnetic resonance imaging can confirm the diagnosis. Endoscopic approach is the optimal method of treatment.

CONFLICTS OF INTEREST

The authors have no conflict of interest.

CONSENT

An informed consent has been obtained from the patient.

REFERENCES

1. Zukin LM, Hink EM, Liao S, Getz AE, Kingdom TT, Ramakrishnan VR. Endoscopic management of paranasal sinus mucoceles: Meta-analysis of visual outcomes. *Otolaryngol Head Neck Surg.* 2017; 157(5): 760-766. doi: 10.1177/0194599817717674

2. Mnejja M, Hammami B, Achour I, et al. Post-radiation mucocele in two patients treated for nasopharyngeal cancer [In French]. *Cancer radiother.* 2011; 15(3): 254-256. doi: 10.1016/j.canrad.2010.12.004

3. Morita S, Mizoguchi K, Iizuka K. Paranasal sinus mucoceles with visual disturbance. *Auris Nasus Larynx.* 2010; 37(6): 708-712. doi: 10.1016/j.anl.2010.04.002

4. Devars du Mayne M, Moya-Plana A, Malinvaud D, Laccourreye O, Bonfils P. Sinus mucocele: natural history and long-term recurrence rate. *Eur Ann Otorhinolaryngol Head Neck Dis.* 2012; 129(3): 125-130. doi: 10.1016/j.anorl.2011.10.002

5. Wong CS, Luk SH, Leung TW, Yuen KK, Sze WK, Tung SY. Sphenoid sinus mucocoele and cranial nerve palsies in a patient with a history of nasopharyngeal carcinoma: May mimic local recurrence. *Clin Oncol (R Coll Radiol).* 2001; 13(5): 353-355.

6. Capra GG, Carbone PN, Mullin DP. Paranasal sinus mucocele. *Head Neck Pathol.* 2012; 6(3): 369-372. doi: 10.1007/s12105-012-0359-2

7. Lin JY, Lin SL, Chang YL, Lo SH, Chuang FS, Lin SY. Sphenoid sinus mucocoele presenting with optic neuropathy and abducens palsy: A late complication of radiotherapy to the head and neck. *Eye.* 2005; 19(6): 697-699. doi: 10.1038/sj.eye.6701581

8. Rejab E, Said H, Saim L, Thim L. Sphenoid sinus mucocoele: A possible late complication of radiotherapy to the head and neck. *J Laryngol Otol.* 1991; 105(11): 959-960.

9. Sharouny H, Narayanan P. Maxillary Sinus Mucopyocele in a fifty-eight-year-old man: A possible late complication of irradiation to head and neck. *Iranian Red Crescent Med J.* 2014; 16(7): e17133. doi: 10.5812/ircmj.17133

10. Santos PLD, Chihara LL, Alcalde LFA, Masalskas BF, Sant'Ana E, Faria PEP. Outcomes in surgical treatment of mucocele in frontal sinus. *J Craniofac Surg.* 2017; 28(7): 1702-1708. doi: 10.1097/SCS.0000000000003224

11. Marrakchi J, Nefzaoui S, Chiboub D, et al. Imaging of paranasal sinus mucoceles. *Otolaryngol Open J.* 2016; 2(3): 94-100. doi: 10.17140/OTLOJ-2-121

12. Topdag M, Iseri M, Sari F, Erdogan S, Keskin IG. Paranasal sinus mucoceles: Our clinical experiments. *Int J Clinical Exp Med* 2015; 8(10): 18518-18522.

13. Kosling S, Hintner M, Brandt S, Schulz T, Bloching M. Mucoceles of the sphenoid sinus. *Eur J Radiol.* 2004; 51(1): 1-5.

14. Caballero Garcia J, Giol Alvarez AM, Morales Perez I, Gonzales Gonzales N, Hidalgo Gonzales A, Cruz Perez PO. Endoscopic treatment of sphenoid sinus mucocele: Case report and surgical considerations. *Case Rep Otolaryngol.* 2017; 2017: 7567838.

15. Waizel-Haiat S, Díaz-Lara IM, Vargas-Aguayo AM, Santiago-Cordova JL. Experience in the surgical treatment of paranasal sinus mucoceles in a university hospital. *Cirugía y Cirujanos.* [English Edition]. 2017; 85(1): 4-11.