ISSN 2470-4059

Openventio PUBLISHERS

OTOLARYNGOLOGY

Open Journal

| December 2021 | Volume 7 | Issue 1 |

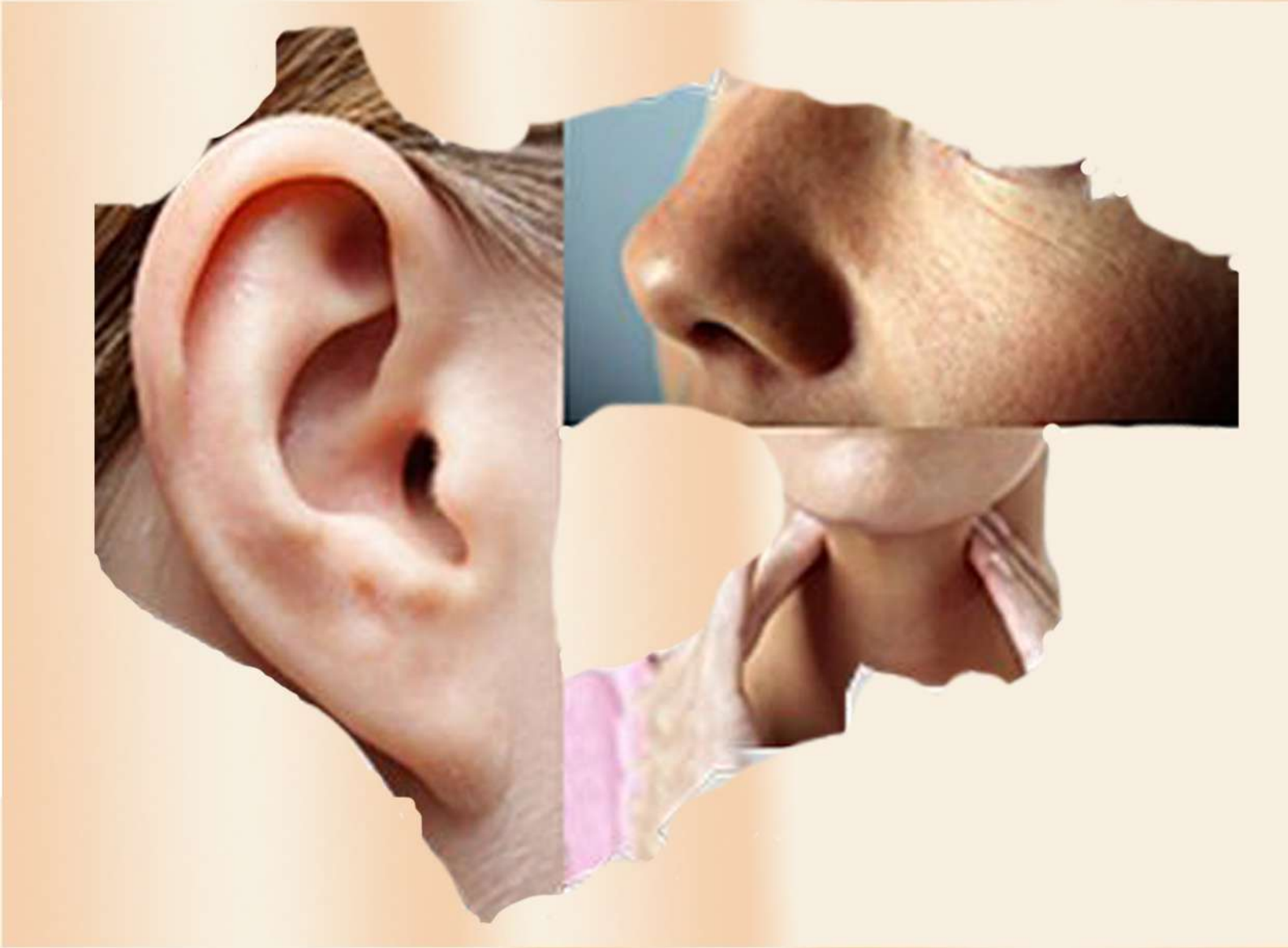

www.openventio.org

ISSN 2470-4059

OTOLARYNGOLOGY
Open Journal

Openventio
PUBLISHERS

CONTENTS

ISSN 2470-4059

OTOLARYNGOLOGY

OpenJournal

Openventio PUBLISHERS

Case Report

A Case of Glomus Tympanicum During Stapedotomy Surgery for Otosclerosis

Leonardo Ordoñez-Ordoñez, MD[1*]; Fabio Leon, MD[2]; Juanita Beltran, MD[1]

[1]*Department of Otolaryngology, Hospital Militar Central, Bogota, Colombia*
[2]*Department of Pathology, Clinica Universitaria Colombia, Bogota, Colombia*

[*]***Corresponding author***
Leonardo Ordoñez-Ordoñez, MD
Department of Otolaryngology. Hospital Militar Central. Bogota, Colombia; E-mail: otoleor@gmail.com

Article information
Received: December 1st, 2020; **Accepted:** February 6th, 2021; **Published:** February 16th, 2021

Cite this article
Ordoñez-Ordoñez L, Leon F, Beltran J. A case of glomus tympanicum during stapedotomy surgery for otosclerosis. *Otolaryngol Open J*. 2021; 7(1): 1-3.
doi: 10.17140/OTLOJ-7-162

ABSTRACT

Glomus tympanicum is a tumor classified as a paraganglioma. We report a case of a 66-year-old female with two middle ear pathologies: an incidental finding of a glomus tympanicum during stapedotomy surgery for otosclerosis.

Keywords
Glomus tympanicum; Otosclerosis; Paraganglioma; Stapedotomy.

INTRODUCTION

Paragangliomas are benign tumors of neural crest origin arising from paraganglia (glomus body) cells and occur most often in the temporal bone and neck. They are referred to according to their site of origin in the glomus jugular, tympanicum, carotid body, or vagale. Glomus tympanicum (GT) is highly vascular tumor and arises from the paraganglia of the middle ear usually originating along the tympanic (Jacobson's) or auricular (Arnold's) nerves. Glomus that arise from the Jacobson nerve originate at the cochlear promontory and surgical treatment is the treatment of choice. It is the most common primary neoplasm of the middle ear, and the second most common tumor of the temporal bone.[1]

Early stage paragangliomas present with symptoms related to the involvement of the middle ear. Unilateral pulsatile tinnitus and conductive hearing loss due to its highly vascular nature and mass effect in the middle ear are usually present. Glomus tympanicum is seen as a retrotympanic red mass on the promontory.[2]

On high resolution computed tomography of the temporal bone, glomus tympanicum are seen as a soft tissue mass confined to the middle ear centered either over the promontory, the hypotympanum, or both,[2] and there may be bony destruction and erosion. Magnetic resonance imaging (MRI) is usually better than computerized tomography (CT) for delineating tumor edges and intracranial extent.[3]

The management involves a particular challenge because of the hypervascular nature. The therapeutic goal is to control the disease with minimal resulting morbility.[2]

CASE REPORT

The following case report description was authorized by the patient. We present the case of a 66-year-old female patient presented to us with a history of progressive, diminished, left-sided hearing of more than 20-years. There was no history of ear discharge, ear pain, or any other symptoms.

Clinical examination revealed a normal external ear canal and healthy tympanic membrane bilaterally. Turning fork test revealed a conductive hearing loss of the left ear. Pure tone audiometry revealed a mild to severe mixed hearing loss pattern mainly conductive, in the left ear (Figure 1).

The patient was sent for CT of the temporal bone in which initially no abnormalities where found. The original diagnosis that was made was otosclerosis *versus* ossicular chain disruption based upon history and pure tone audiometry. The patient

Openventio PUBLISHERS

Figure 1. *Pure Tone Audiometry. Mild to Severe Mixed Hearing Loss*

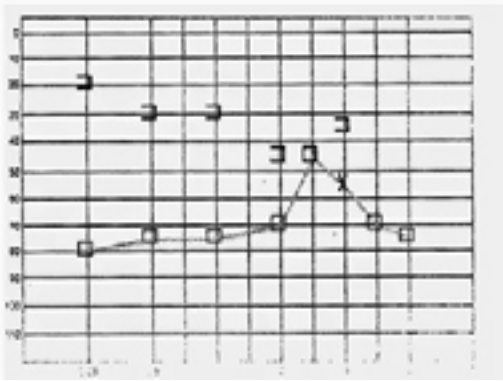

Figure 2. *Tumor Composed of Ccuboidal Cells with Minimal Salt and Pepper Chromatid Atypia. The Tumor Nests are Separated by Thin Wall Blood Vessels. The Chief Cells are Small with Basophilic Cytoplasm and have Round, Granular Nuclei. A and B: Hematoxylin Eosin Stain 10x and 40x respectively, C: Chromogranin 40x*

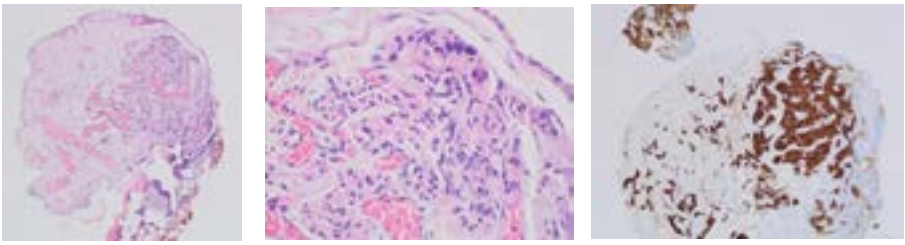

A B C

was considered candidate for stapedotomy. During the procedure, we found a highly vascular mass originating from the promontory with a size of 6 mm. The stapedotomy was paused, and we began the resection using blue laser (2.0 VAT). The mass was completely removed and was sent to pathology to assess the histological nature. The pathology report confirmed a glomus tympanicum (Figure 2). The initial CT scan was then revised and demonstrated a soft tissue density mass occupying the middle ear originating from the promontory (Figure 3). One-year CT follow-up shows absence of the glomus tympanicum recurrence, with prothesis in adequate position and with an improvement on air conduction hearing thresholds.

Figure 3. *Temporal CT Scan Showing (A) The Left Middle Ear Space Partially Accupied by a Soft Tissue Density Mass Originating from the Promontory (red arrow) and (B) The Abscense of this Mass after Laser Resection One -Year after with Adequate Prothesis Position (red arrorw)*

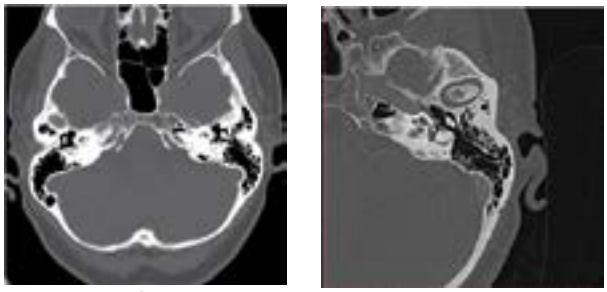

A B

Figure 2 shows tumor composed of cuboidal cells with minimal salt and pepper chromatid atypia. The tumor nests are separated by thin wall blood vessels. The chief cells are small with basophilic cytoplasm and have round, granular nuclei. A and B: hematoxylin eosin stain 10× and 40× respectively, C: chromogranin 40×.

DISCUSSION AND CONCLUSION

Paragangliomas in the head and neck can be differentiated into cervical paragangliomas a temporal bone paragangliomas. The cervical group includes carotid body tumors and glomus vagale tumors, while the jugulo tympanic comprises glomus jugulare and glomus tympanicum tumors. Glomus tympanicum tumors are more common than glomus jugulare tumors.[4]

Patients present with complaints of pulsatile tinnitus (81.4%), subjective hearing loss (77.1%), and aural fullness (70.2%), otalgia is uncommon.[5]

A histologic analysis of glomus tympanicum tumors reveals many similarities to paragangliomas that occur elsewhere in the body. Tumors are solid and encapsulated, and microscopically there are conglomerations of chief cells surrounded by sustentacular cells and an extensive capillary network that creates a reticular appearance. Chief cells are characterized by a polyhedral shape, roundnuclei, and eosinophilic cytoplasm that can contain granular structures.[6]

Surgery remains the only option for definitive tumor management. Tumor diagnosis begins clinically with the visualization of a red mass behind the intact ear drum, but computed tomography and MRI have become essential for identifying the tumor origin and defining the extent of the disease.[7]

Neurosecretory function in glomus tympanicum tumors is rare, but screening for functional tumors remains an important part of tumor management.[8] Despite being prone to locally aggressive behavior, they are benign histologically. Malignancy is identified in 5% of temporal bone paragangliomas.[9] The evident association of some glomus tumors to a genetic origin may also have implications on its malignant potential.[10]

The surgical approach should be chosen according to the extension to surrounding structures and the size of the glomus.[11] Surgery has side effects and risks like changes in taste, dizziness, and tinnitus. Stereotactic radiation has also been described as a palliative measure for GT tumors.[7]

Cases of two middle ear pathologies in one symptomatic patient are not common. Even though in this particular case, hearing loss was due to the stapes fixation, if the tumor continues growing as usual, a progressive hearing loss could have been diagnosed posteriorly, with a completely different causal pathology.

CONSENT

The authors have received written informed consent from the patient.

CONFLICTS OF INTEREST

The authors declare that they have no conflicts of interest.

REFERENCES

1. Hinerman RW, Amdur RJ, Morris CG, Kirwan J, Mendenhall WM. Definitive radiotherapy in the management of paragangliomas arising in the head and neck: A 35-year experience. *Head Neck*. 2008; 30(11): l431-1438. doi: 10.1002/hed.20885

2. Semaan MT, Megerian CA. Current assessment and management of glomus tumors. *Curr Opin Otolaryngol Head Neck Surg*. 2008; 16(5): 420-426. doi: 10.1097/MOO.0b013e32830c4595

3. Vogl TJ, Mack MG, Juergens M, Bergman C, Grevers G, Jacobsen TF, et al. Skull base tumours gadodiamide injection-enhanced MR imaging. *Radiology*. 1993; 188: 339-346. doi: 10.1148/radiology.188.2.8327675

4. O'Leary MJ, Shelton C, Giddings NA, Kwartler J, Brackmann DE. Glomus tympanicum tumours: A clinical perspective. *Laryngoscope*. 1991; 101: 1038-1043. doi: 10.1288/00005537-199110000-00002

5. Carlson ML, Sweeney AD, Pelosi S, Wanna GB, Glasscock ME, Haynes DS. Surgical management of glomus tympanicum: a review of 115 cases over four decades. *Otolaryngol Head Neck Surg*. 2015; 152: 136-1342. doi: 10.1177/0194599814555849

6. Sennaroglu L, Sungur A. Histopathology of paragangliomas. *Otol Neurotol*. 2002; 23: 104-105. doi: 10.1097/00129492-200201000-00023

7. Sweeney A, Carlson M, Wanna G, Bennett M. Glomus tympanicum tumors. *Otolaryngol Clin North Am*. 2015; 48(2): 293-304. doi: 10.1016/j.otc.2014.12.004

8. Kouzaki H, Fukui J, Shimizu T. Management of a catecholamine-secreting tympanicum glomus tumour: Case report. *J Laryngol Otol*. 2008; 122: 1377-1380. doi: 10.1017/S0022215108001801

9. Manolidis S, Shohet JA, Jackson CG, Glasscock ME. Malignant glomus tumors. *Laryngoscope*. 1999; 109: 30-34. doi: 10.1097/00005537-199901000-00007

10. Martin TP, Irving RM, Maher ER. The genetics of paragangliomas: A review. *Clin Otolaryngol*. 2007; 32(1): 7-11. doi: 10.1111/j.1365-2273.2007.01378.x

11. Carlson M, Sweeney A, Pelosi S, Wanna G, Glasscock M, Haynes D. Glomus tympanicum: A review of 115 cases over 4 decades. *Otolaryngology–Head and Neck Surgery*. 2014; 152(1): 136-142. doi: 10.1177/0194599814555849

ISSN 2470-4059

OTOLARYNGOLOGY

OpenJournal

Openventio PUBLISHERS

Case Report

Pinna Swelling an Angiolymphoid Hyperplasia with Eosinophilia: A Rare Case Report

Sambhaji G. Chintale, MS[1*]; Vilas R. Kirdak, MS[2]; Swati S. Chintale, MD[3]; Kaleem A. Shaikh, MBBS[2]; Sonali P. Jatale, MS[4]

[1]*Department of Otolaryngology, Cosmo ENT Super Speciality Hospital and Research Center, Aurangabad 431 0055, MH, India*
[2]*Department of Otolaryngology, JIIUS IIMSR Warudi TQ, Badnapur. Warudi 431 202, MH, India*
[3]*Department of Community Medicine, Government Medical College, Aurangabad 431 001, MH, India*
[4]*Department of Otorhinolaryngology, Government Medical College, Aurangabad 431 001, MH, India*

***Corresponding author**
Sambhaji G. Chintale, MS
Director, Department of Otolaryngology, Cosmo ENT Super Speciality Hospital and Research Center, Aurangabad 431 0055, MH, India; Mobile. 9970323030; E-mail: drsamchinto@gmail.com

Article information
Received: February 21st, 2021; **Revised:** March 20th, 2021; **Accepted:** April 15th, 2021; **Published:** April 28st, 2021

Cite this article
Chintale SG, Kirdak VR, Chintale SS, Shaikh KA, Jatale SP. Pinna swelling an angiolymphoid hyperplasia with eosinophilia: A rare case report. *Otolaryngol Open J*. 2021; 7(1): 4-6. doi: 10.17140/OTLOJ-7-163

ABSTRACT

Pinna swelling that is angiolymphoid hyperplasia is a benign lesion that needs to be discussed. Most of the time it affects the face in that preauricular area involved, where it appears as a tiny erythematous lesion. Here we reported a case of a 24-years female patient who presented to us at the hospital with left ear pinna swelling for 7-years.

Keywords
Pinna; Swelling; Angiolymphoid; Hyperplasia; Eosinophilia.

INTRODUCTION

A Angiolymphoid hyperplasia with eosinophilia (ALHE) is a benign, locally proliferating lesion, which usually affects middle-aged women. Which most of the time affects the preauricular area and scalp. Other common sites include oral mucosa, pharynx, and orbit lesions present as an erythematous and hyperpigmented lesions. ALHE is a rare benign tumor which is clinically manifested by the presence of dermal papules or nodules measuring about 2-3 cm, varying in color from light brown to pink. The lesions occur preferentially on the face, scalp, auricular region, and neck. There seems to be a higher incidence in females and lesions are more common in patients aged 20-50-years. Its pathogenesis remains unknown. Some authors believe that the damage would be due to a vascular tumor. Others claim that they could represent a reaction to vascular tissue injuries such as skin trauma, infections (human T-cell leukemia-lymphoma virus (HTLV) or herpes virus 8), or hormonal imbalance. Some recent studies tend to consider it as a vascular malformation secondary to a subcutaneous arterio-venous shunt, but the hypothesis most widely accepted is that it is a reactive vascular hyperplasia to various stimuli.

CASE REPORT

A twenty-four-year-old female patient reported to our ear, nose and throat (ENT) hospital out-patient department (OPD) with chief complaints of left pinna swelling since 7-years. and intermittent itching present over pinna swelling with getting relieved on medications and topical application of steroids. Initially, swelling was very small started as papule 7-years back gradually it gets increased to present size. The patient visited many general practitioners for the swelling but after giving primary treatment of medications and steroid ointment for applications swelling get regressed for some time but later on it recurs. Therefore, on detailed history no history of ear trauma, no history of ear discharge, and no history of any previous ear surgery on the left ear. No history of diabetes mellitus (DM), no history of hypertension (HT), and no history of any known communicable disease.

In the past, the patient had taken antihistamines, anti-inflammatory drugs, and steroids for a few weeks to relieve the swelling, yet it had not decreased in scale.

On palpation tenderness, the swelling was approximately 3 cm×3 cm in size, soft in consistency, and reddish in color, as

shown in Figure 1. The swelling spreads to the postural area and to the external auditory canal; there is no bleeding when touched, and the swelling is not fixed to the underlying structure. On palpations, pulsation is felt. There were no palpable lymph nodes in the cervical region, as well as in the preauricular and postauricular areas.

Figure 1. *Showing External Auditory Canal Swelling*

Endoscopic examination of the left ear revealed a swelling in the conchal region that extended a few millimetres into the external auditory canal, but the tympanic membrane of the left ear was normal, as shown in Figure 2.

Figure 2. *Endoscopic Picture of Left Tympanic Membrane*

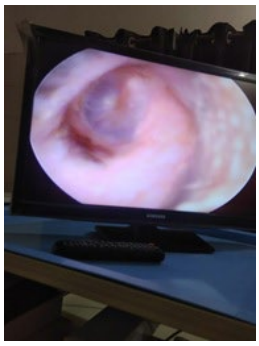

We recommended fine needle aspiration cytology (FNAC) of the swelling after a thorough examination. All routine blood investigations of the patients done for the surgical purpose required under general anesthesia revealed haemoglobin (HB) of 11 gm/dL and eosinophil count raised above normal range by 7%/cumm. 800 UI/mL IgE level raised Blood sugar 100 mg/dL, blood urea 20 mg/dL, Sr creatine 1.0 mg/dL, Hepatitis B Surface Antigen (HBsAg) test non-reactive, human immunodeficiency virus (HIV) test non-reactive, and blood group rhesus (RhB) positive. The reports of electrocardiogram (ECG), 2D echocardiography (2DECHO), and X-ray chest post-eroanterior (PA) view were all normal.

Computerized tomography angiography (CTA) of this swelling revealed a soft density lesion measuring 4 cm×3 cm in preauricular, infra-auricular, and extending to the external auditory canal, triggering luminal stenosis of the left ear's external auditory canal. CTA was performed to rule out any arteriovenous malformation and intracranial communication of this swelling. CTA is used to rule out any possible interaction between brain and swelling.

The arterial phase shows no obvious feeders within swelling while the venous phase shows the venous draining channels venules into the left external jugular vein.

Since the results of the fine needle aspiration cytology were inconclusive, we performed a punch biopsy of the swelling, which revealed Angiolymphoid hyperplasia with eosinophilia of the ear (Figure 3).

Figure 3. *A and B Showing Blood Vessels Endothelial Proliferation with Eosinophilia*

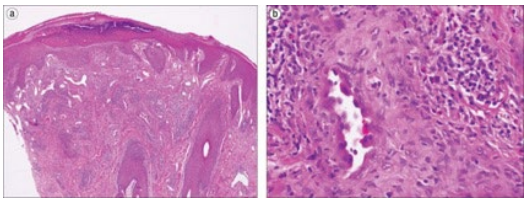

We advised the patient to have the swelling surgically removed after checking all of the blood tests and histopathology reports and explaining all of the complications and chances of the swelling returning after excision. Since the patient refused to undergo surgery, we recommended a different course of treatment i.e., pulsed dye laser therapy, which she accepted. She has taken it as 15 mm circular beam for every 2-months for 3 settings in 6-months where the swelling gets regressed in size but not fully. The patient was pleased with it and has been following-up with it for the last two years with good results.

DISCUSSION

Angiolymphoid hyperplasia with eosinophilia first time described by Wells et al.[1] The tumor is characterized by the proliferation of blood vessels lined by plump endothelial cells and admixed with a dense inflammatory infiltrate of lymphocytes, eosinophils, and mast cells. Weiss and Enzinger argued with the name of the diseases, for they wanted to differentiate the lesion from the malignant vascular tumor, epitheloid hemangioendothelioma. For this, they introduced the term epithelioid hemangioma (EH) in 1982.[2]

The argument that ALHE/EH may represent a monoclonal T-cell process which is supported insome cases.[3] In 2015, statistical analysis yielded no sex 908 patients.[4] Over fifty percent of the patients presented with a single lesion and the most common locations were the ear, and preauricular area, faces, and scalp. Considering age, statistics have shown a wide prevalence range (0.7-months to 91-years) and the mean age of presentation was 37.6-years.

According to the literature ALHE is a benign, locally proliferating lesion, which usually affects middle-aged women and tends to have affects the periauricular area and scalp. Other

common involved areas are oral mucous membranes, pharynx, and orbit[4] lesion present as anerythematous and hyperpigmented lesion.[2,3] The nodules are normally 2 to 3 cm in diameter, with rare cases of larger and deeper neoplasms.[2,3] It is unclear whether ALHE is a reactive or neoplastic disease.[4] In its active phase, it can be misdiagnosed as an angiosarcoma; however, eosinophilia is not a usual feature of malignant angiosarcoma.[5]

The main differential diagnosis of ALHE was put forward as Kimura's disease.[5] These two conditions are histologically described as lymphoid infiltration, vascular proliferation, and tissue eosinophilia. However, the clinical appearance of Kimura's disease is consistent with subcutaneous swelling and may not involve erythematous papules or nodules.[5,6]

Angiolymphoid hyperplasia with eosinophilia may also be confused with lymphomatoid papulosis, which is a form of primary cutaneous CD30+ T-cell lymph proliferative disorder.[7]

Few theories suggest ALHE may occur due to insect bite, injury, and administration of tetanus injection.[8]

No definitive treatment is reported for this condition. Complete excision can be curative, but recurrences are common. Moh's micrographic surgery with excision of abnormal vessels at the base of the lesion may be more effective in reducing recurrences.[3] Intraregional injections of corticosteroids, interferon α-2a, and cytotoxic agent's are effective.[2] Other methods of treatment used for such cases are cryotherapy, laser treatment with carbon dioxide, and pulse dye.[2]

The laser treatment is given for the Vasoformative component of the disease. There are almost many chances of recurrence in such diseases when existed with Kimura disease, we have to excise by surgery and followed by the full thickness skin graft.[9]

Though this lesion described in previous study as presentation to the head and neck and few cases of ear presentation, this case is different as its present at external auditory canal opening with diffuse base and spread to postauricualr region few millimeter deep to skin extending towards the tympanic membrane. Its clinically different with previous case reported findings.

CONCLUSION

This type of lesion is very uncommon in the presentation to the ear. What is distinctive to this case is the external appearance and site to the pinna and external ear and high-levels of immunoglobulin E (IgE) and eosinophilia. Taking into consideration the highly aggressive and cosmetically destructive nature of the disease, more progress should be targeted towards creating a standardized and effective therapeutic approach that could help physicians treat such a recurring disease.

ACKNOWLEDGMENTS

This study is conducted at the ENT Department of our hospital thanks to all my seniors and entire colleague for their kind support.

FUNDING

No funding sources

ETHICAL APPROVAL

This study approved by the institutional ethical committee

CONSENT

The authors have received written informed consent from the patient.

CONFLICTS OF INTEREST

The authors declare that they have no conflicts of interest.

REFERENCES

1. Wells GC, Whimster IW. Subcutaneous angiolymphoid hyperplasia with eosinophilia. *Br J Dermatol.* 1969; 81(1): 1-14. doi: 10.1111/j.1365-2133.1969.tb15914.x

2. Guo R, Gavino AC. Angiolymphoid hyperplasia with eosinophilia. *Arch Pathol Lab Med.* 2015; 139(5):683-686. doi: 10.5858/arpa.2013-0334-RS

3. Asadi AK. Angiolymphoid hyperplasia with eosinophilia. *Dermatol Online J.* 2002; 8(2): 10.

4. Olsen TG, Helwig EB. Angiolymphoid hyperplasia with eosinophilia.A clinicopathologic study of 116 patients. *J Am Acad Dermatol.* 1985; 12(5 Pt 1): 781-796. doi: 10.1016/s0190-9622(85)70098-9

5. Chong WS, Thomas A, Goh CL. Kimura's disease and angiolymphoid hyperplasia with eosinophilia: Two disease entities in the same patient: case report and review of the literature. *Int J Dermatol.* 2006; 45(2): 139-145. doi: 10.1111/j.1365-4632.2004.02361.x

6. Reed RJ, Terazakis N. Subcutaneous angioblastic lymphoid hyperplasia with eosinophilia (Kimura's disease). *Cancer.* 1972; 29(2): 489-497. doi: 10.1002/1097-0142(197202)29:2<489::aid-cncr2820290239>3.0.co;2-x

7. Diamantidis MD, Myrou AD. Perils and pitfalls regarding differential diagnosis and treatment of primary cutaneous anaplastic large-cell lymphoma. *Scientific World Journal.* 2011; 11: 1048-1055. doi: 10.1100/tsw.2011.80

8. Akosa AB, Ali MH, Khoo CT, Evans DM. Angiolymphoid hyperplasia with eosinophilia associated with tetanus toxoid vaccination. *Histopathology.* 1990; 16(6): 589-593. doi: 10.1111/j.1365-2559.1990.tb01164.x

9. Jun R, Liu XK, Zeng K. Successful treatment of angiolymphoid hyperplasia with eosinophilia and Kimura's disease in the same patient with surgery. *Dermatol Ther.* 2014; 27(1): 36-38. doi: 10.1111/dth.12040

ISSN 2470-4059

OTOLARYNGOLOGY

OpenJournal

Openventio PUBLISHERS

Systematic Review

Effectiveness of Endoscopic Pitch Raising Surgery in Male to Female Transsexual Individuals

Ziya Saltürk, MD[1*]; Esin Avcı, PHD[2]; Yavuz Atar, MD[3]; Belgin Tutar, MD[3]; Güler Berkiten, MD[3]; Tolgar L. Kumral, MD[3]; Sertaç Yetişer, MD[1]

[1]*Anadolu Medical Center ENT Department, Gebze/Kocaeli, Turkey*
[2]*Department of Statistic, Giresun University Statistical, Giresun, Turkey*
[3]*Cemil Tascioglu City Hospital ENT Clinic, Istanbul, Turkey*

[*]***Corresponding author***
Ziya Saltürk, MD
Associate Professor, Anadolu Medical Center ENT Department, Gebze/Kocaeli, Turkey; E-mail: ziyasalturk@gmail.com

Article information
Received: March 29th, 2021; **Revised:** May 1st, 2021; **Accepted:** May 13th, 2021; **Published:** May 30th, 2021

Cite this article
Saltürk Z, Avcı E, Atar Y, et al. Effectiveness of endoscopic pitch raising surgery in male to female transsexual individuals. *Otolaryngol Open J*. 2021; 7(1): 8-12. doi: 10.17140/OTLOJ-7-164

ABSTRACT

Aim
This study was performed to investigate the effectiveness of two endoscopic techniques for transsexual females.

Method
Web of Science, Google Scholar, and PubMed databases were searched for studies suitable for inclusion in this meta-analysis. Studies in which Wendler's glottoplasty or laser-assisted voice adjustment were analysed for the data criteria. Studies which included pre-operative and post-operative fundamentals frequency values were selected. Five articles were included in the present study (total of 94 cases). As dependent groups were used in these studies, standardized mean differences were obtained using a random effect model. Analyses were performed using the meta for package for the R-statistical program.

Results
Standardized mean values before and after operations were very different and post-operative mean values were significantly higher than the pre-operative mean values.

Conclusion
Endolaryngeal surgical techniques are valuable for pitch elevation.

Keywords
Transgender; Phonosurgery; Voice; Gender and the voice; Endoscopy US version.

INTRODUCTION

Transsexualism is a complex condition characterized by inconsistency between psychological and anatomical gender, and may lead to serious stress in the event of gender dysphoria.[1-3] Individuals can undergo a series of surgeries and hormone therapy to change their gender characteristics.[4] The voice is not only a means of communication, but is also important in the psychological perception of gender, being accepted as a secondary sexual characteristic.[5-7]

The fundamental frequency (F0) is the main parameter responsible the perceived gender of the voice, and is related to the length, mass, and stiffness of the vocal folds.[8-10] Adult male and female F0 ranges from 80-165 Hz and 145-275 Hz,[11] respectively. Thus, there is an overlap in the range 145-165 Hz,[11-14] in which other parameters should be added to determine voice gender; intonation is also important tin this regard.[15] Unlike transsexual males, transsexual females do not achieve satisfactory F0 values with hormone therapy.[12,16,17] Therefore, phonosurgery and voice therapy are suitable options for these patients.[18] The main advantage of voice therapy is that it can address parameters other than the F0.[19] However, laughing, crying, coughing, and other situations where voluntary control is lost can be unpleasant for patients. Phonosurgical options include cricothyroid approximation (CTA), laser assisted voice adjustment, and Wendler's glottoplasty.[18] CTA was

the first of these methods to be introduced, and has been used to achieve the desired feminine voice in many cases. However, it may not always able to create a voice that is sufficiently feminine.[20-22]

This study was performed to investigate the effectiveness of two endoscopic techniques for transsexual females.

MATERIALS AND METHODS

This study was approved by the ethical committee of Cemil Tascioglu City Hospital. Database search in October 2020, the Web of Science, Google Scholar, and PubMed databases were searched for studies suitable for inclusion in this meta-analysis.

The following keywords were searched for: "*transgender*", "*transgendered*", "*transgendered person*", "*transgendered female*", "*transsexual person*", "*transsexual female gender dysphoria*", "*endoscopic surgery*", "*Wendler's glottoplasty*", "*Laser-assisted voice adjustment*", "*laser reduction glottoplasty*", "*laser-assisted pitch raising*", "*pitch raising surgery*" and "*fundamental frequency*".

Data Analysis

Two independent referees reviewed the articles in accordance with the inclusion criteria. A third referee then checked the articles nominated for inclusion. Forty-nine studies were identified.

Forty studies were related to surgical techniques, but only those reporting endoscopic surgery and providing F0 values before and after surgery were included. Nine articles were identified that matched these criteria; three provided the complete data set, so we could calculate correlation coefficients and mean values if they were missing. One article presented mean values but no correlation coefficients, so these were obtained from the authors by e-mail. The entire data set for one article was obtained from the authors by e-mail and all relevant calculations were performed. Thus, five articles were finally included in the present study (total of 94 cases; Table 1. As dependent groups were used in these studies, standardized mean differences were obtained using a random effect model. Analyses were performed using the metafor package for the R statistical program (R Development Core Team, Vienna, Austria).

RESULTS

Kocak et al[23] described cases of CTA at least 12-months before laser reduction glottoplasty, although three patients were not transsexual. Orloff et al[24] included previously operated patients. Yılmaz et al[25] reported 27 cases, including 21 transsexual patients.

Table 1. *Pre-operative and Post-operative Fundamental Frequencies of the Studies*

Authors	Technique	N	Pre-operative F0	SD	Post-operative F0	SD	Correlation Co-efficient
Orloff et al[24]	Laser-assisted voice adjustment	31	141,94	38,89	167,88	35,69	0,65
Kocak et al[23]	CTA+laser reduction glottoplasti	6	158,33	12,14	203,50	13,34	0,93
Yılmaz et al[25]	Wendler's glottoplasty	27	152	12	195	14	0,42
Casado et al[26]	Wendler's glottoplasty	10	137,32	9,81	243,22	18.35	0,71
Paltura et al[5]	Wendler's glottoplasty	20	143,64	18,47	229,66	55,05	-0.21

Fo: Fundamental frequency, SD: standard deviation, CTA: cricothyroid approximation

Figure 1. *Forest Plot*

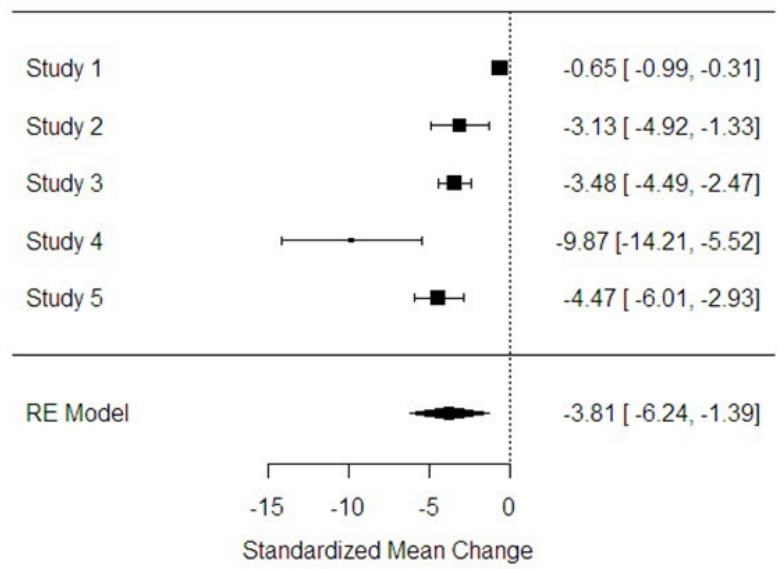

Figure 2. *Forest Plot for Wendler's Glottoplasty*

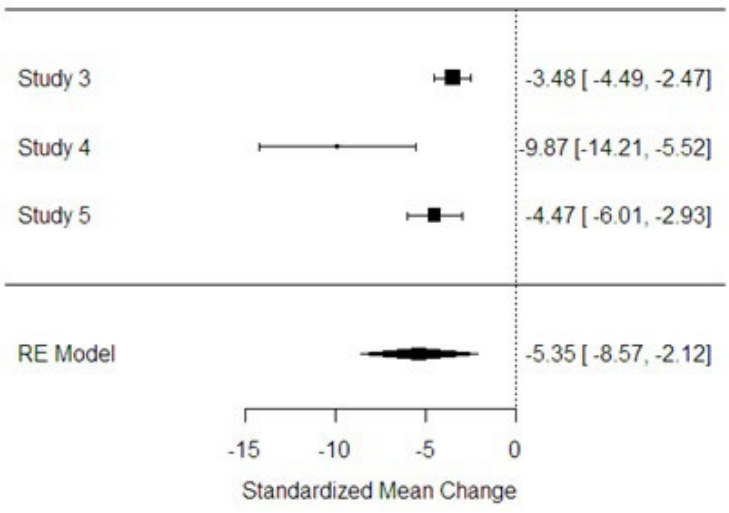

As shown by the forest plot in Figure 1, the study performed by Orloff et al[24] had the greatest contribution to the meta-analysis. The general effect range did not include 0 (zero) so the general effect was statistically significant. Standardized mean values before and after operations were very different and post-operative mean values were significantly higher than the pre-operative mean values.

Figure 2 shows a forest plot for Wendler's glottoplasty. The general effect range did not include 0 (zero) so the general effect was statistically significant. Standardized mean values before and after operations were very different and post-operative mean values were significantly higher than the pre-operative mean values.

DISCUSSION AND CONCLUSION

The voice is a major facet of human identity, particularly with respect to the perception of gender. Therefore, an appropriate voice is of special importance in transgender individuals to avoid psychosocial problems.[4] The production of a feminine voice requires coordination of respiration, vibration, resonation, and articulation, where these aspects are controlled by feedback mechanisms.[27] For voice feminization, retraining of phonophysiological mechanisms and phonatory patterns is needed.

Pitch raising surgical procedures alter vocal fold tension, length, and mass.[28] Laser-assisted voice adjustment and Wendler's glottoplasty, two commonly used methods, are both performed endoscopically.

To our knowledge, this is the third meta-analysis of the English literature on pitch raising surgery in male to female transsexuals, after the studies of Schwarz et al[16] and Song et al.[18] Similar to these previous studies, we were also unable to find any randomized controlled trials, but we did find four prospective studies.[5,23,26] Unlike these studies, we did not include procedures that were not performed endoscopically. All of the studies reported significant pitch elevation in their patients.[5,23-26]

Although CTA is accepted as a form of pitch raising surgery, it is not a true voice feminization surgery because there are no morphological or physiological changes; it only causes a persistent cricothyroid muscle response.[24] In addition, CTA does not change the acoustic tube dimensions, which are different between males and females; moreover, tension after CTA is high after surgery but decreases over time.[23,29-31] Mora et al[22] compared CTA and glottoplasty, and concluded that glottoplasty led to a greater and more persistent F0 increase. Kocak et al[23] performed laser reduction glottoplasty as corrective surgery in cases of CTA failure.

Endolaryngeal procedures affect the vibration length, mass, and tension of the vocal folds. Paltura et al[5] reported that the vocal fold dimensions after Wendler's glottoplasty are closely related to the postoperative F0 value. They also emphasized that an increase in F0 alone was not sufficient for the voice to be perceived as female, and that formant frequencies had an influence on voice gender perception. Their results showed that F1, F3, and F4 were significantly higher after surgery in comparison to the preoperative values.[5]

Yılmaz et al[26] analyzed voice handicap index (VHI) scores and found that patients' emotional distress as it pertained to the voice decreased after surgery; but functional scores increased. They suggested that increased functional VHI score could be attributable to need for increased subglottic pressure required to phonate. However, they emphasized that the vocal range was permanently decreased, while the phonatory effort required for vocalization was increased, such that voice therapy is still needed to ensure that the preoperative voice loudness is retained. As surgery can cause problems in singers and voice professionals, voice therapy may be more suitable in such individuals.

The main limitations of our meta-analysis were the small number of studies included and the heterogeneity of the analyzed data. Two studies included female patients with hormone disorders and ambiguous genitalia.[23,25] Orloff et al[24] included patients who had previously undergone various different surgeries, while Kocak et al[23] included patients who had CTA. Also, none of the studies used a randomized controlled design, while only Paltura et al[5] included a control group. Voice therapy was applied in all patients in the studies of Kocak et al[23] and Casado et al[26] but in none of those in the studies of Yılmaz et al[25] and Paltura et al.[5] Due to the paucity of studies, we could not statistically compare the two techniques. Also, as the authors used different selfreport instruments, it was not possible to analyze quality of life after treatment.

FUNDING

No financial support has been received at any stage of sthe study.

CONFLICTS OF INTEREST

The authors declare that they have no conflicts of interest.

REFERENCES

1. Nolan IT, Morrison SD, Arowojolu O, Crowe CS, Massie JP, Adler RK, et al. The role of voice therapy and phonosurgery in transgender vocal feminization. *J Craniofacial Surg*. 2019; 30: 1368-1375. doi: 10.1097/SCS0000000000005132

2. Dhejne C, Lichtenstein P, Boman M, Johansson ALV, Långström N, Landén M, et al. Long term follow up of transsexual person undergoing sex reassignment surgery: Cohort study in Sweden. *PLoS One*. 2011; 6: e16885. doi: 10.1371/journal.pone.0016885

3. Van Borsel J, Janssens J, De Bodt M. Breathiness as a feminine voice characteristic: A perceptual approach. *J Voice*. 2009; 23: 291-294. doi: 10.1016/j.jvoice.2007.08.002

4. Kelly V, Hertegard S, Eriksson J, Nygren U, Södersten M. Effects of gender confirming pitch-raising surgery, n transgender women a long term follow up study of acoustic and persistent reported data. *J Voice*. 2019; 33: 781-791. doi: 10.1016/j.jvoice.2018.03.005

5. Paltura C, Yelken K. An examination of vocal tract following Wendler's glottoplasty. *Folia Phoniatr Logop*. 2019; 71: 24-28. doi: 10.1159/000494970

6. Wolfe VI, Ratusnik DL, Smith FH, Northrop G. Intonation and fundamental frequency in male-to-female transsexuals. *J Speech Hear Disord*. 1990; 55: 43-50. doi: 10.1044/jshd.5501.43

7. Owen K, Hancock AB. The role of self- and listener perceptions of femininity in voice therapy. *Int J Transgend*. 2011; 12: 272-284. doi: 10.1080/15532739.2010.550767

8. Hillenbrand JM, Clark MJ. The role of f (0) and formant frequencies in distinguishing the voices of men and women. *Atten Percept Psychophys*. 2009; 71: 1150-1166. doi: 10.3758/APP.71.5.1150

9. Titze IR. Physiologic and acoustic differences between male and female voices. *J Acoust Soc Am*. 1989; 85: 1699-707. doi: 10.1121/1.397959

10. Wu K, Childers DG. Gender recognition from speech. Part I: Coarse analysis. *J Acoust Soc Am*. 1991; 90: 1828-1840. doi: 10.1121/1.401663

11. Meister J, Hagen R, Shehata-Dieler W, Kühn H, Kraus F, Kleinsasser N. Pitch elevation in male-to-female transgender persons-the Würzburg approach. *J Voice*. 2017; 31: 244e7. doi: 10.1016/j.jvoice.2016.07.018

12. Gelfer MP, Schofield KJ. Comparison of acoustic and perceptual measures of voice in male-to-female transsexuals perceived as female versus those perceived as male. *J Voice*. 2000; 14: 22-33. doi: 10.1016/s0892-1997(00)80092-2

13. Gelfer MP, Mikos VA. The relative contributions of speaking fundamental frequency and formant frequencies to gender identification based on isolated vowels. *J Voice*. 2005; 19: 544-554. doi: 10.1016/j.jvoice.2004.10.006

14. Whiteside SP. The identification of a speaker's sex from synthesized vowels. *Percept Mot Skills*. 1998; 87: 595-600. doi: 10.2466/pms.1998.87.2.595

15. Dacakis G. Long-term maintenance of fundamental frequency increases in male-to-female transsexuals. *J Voice*. 2000: 14; 549-556. doi: 10.1016/s0892-1997(00)80010-7

16. Schwarz K, Vaitses AM, Schneider MA, Soll BMB, da Silva DC, Spritzer PM, et al. Laryngeal surgical treatment in transgender women: A systematic review and meta-analysis. *Laryngoscope*. 2017; 127: 2596-2603. doi: 10.1002/lary.26692

17. Cosyns M, Borsel J, Wierckx K, Dedecker D, de Peer FV, Daelman T, et al. Voice in female to male transsexual persons after long term androgen therapy. *Laryngoscope*. 2014; 124; 1409-1414. doi: 10.1002/lary.24480

18. Song TE, Jiang N. Transgender phonosurgery systematic review and meta-analysis. *Otolaryngol Head and Neck Surg*. 2017; 156: 803-808. doi: 10.1177/0194599817697050

19. Daviers S, Goldber JM. Clinical aspects of transgender speech feminization and masculinization. *Int J transgenderism*. 2006; 9: 167-196. doi: 10.1300/J485v09n03_08

20. Mastronikos NS, Remacle M, Biagini M, Kiagiadaki D, Lawson G. Wendler glottoplasty: An effective pitch raising surgery in male-to-female transsexuals. *J Voice*. 2013; 27: 516-522. doi: 10.1016/j.jvoice.2013.04.004

21. Neumann K, Welzel C. The importance of the voice in male-to-female transsexualism. *J Voice*. 2004; 18: 153-167. doi: 10.1016/S0892-1997(03)00084-5

22. Mora E, Cobeta I, Ecerra A, Lucio MJ. Comparison of cricothyroid approximation and glottoplasty for surgical voice feminization in male-to-female transsexuals. *Laryngoscope*. 2018; 128: 2101-2109. doi: 10.1002/lary.27172

23. Koçak I, Akpınar ME, Çakır ZA, Doğan M, Bengisu S, Celikoyar MM. Laser reduction glottoplasty for managing andronophonia after failed cricothyroid approximation surgery. *J Voice*. 2010; 24: 758-764. doi: 10.1016/j.jvoice.2009.06.004

24. Orloff LA, Mann AP, Damrose JP, Goldman SN. Laser assisted voice adjustment (LAVA) in transsexuals. *Laryngoscope*. 2006; 116: 655-660. doi: 10.1097/01.mlg.0000205198.65797.59

25. Yılmaz T, Kuscu O, Sozen T, Süslü AE. Anterior glottic web fotmation for voice feminization: Experience of 27 patients. *J Voice*. 2017; 31: 757-762. doi: 10.1016/j.jvoice.2017.03.006

26. Casado JC, O'Connor C, Angulo MS, Adrián JA. Glotoplastia de Wendler y tratamiento logopédico en lafeminización de la voz en transexuales: Resultados dela valoración pre- vs. poscirugía [In: Spanish]. *Acta Otolaryngologica Espanola*. 2016; 67(2): 83-92. doi: 10.1016/j.otorri.2015.02.003

27. Schmidt RF, Thews G. *Humöan Physiology*. Berlin Germany: Springer; 1983.

28. Kim H-T. A new conceptual approach for voice feminization: 12 years of experience. *Laryngoscope*. 2017; 127: 1102-1108. doi: 10.1002/lary.26127

29. Wagner I, Fugain C, Monneron-Girard L, Cordier B, Chabolle F. Pitch-raising surgery in fourteen male-to-female transsexuals. *Laryngoscope*. 2003; 113: 1157-1165. doi: 10.1097/00005537-200307000-00011

30. Gross M. Pitch-raising surgery in male-to-female transsexuals. *J Voice*. 1999; 13: 246-250. doi: 10.1016/s0892-1997(99)80028-9

31. Kanagalingam J, Georgalas C, Wood GR, Ahluwalia S, Sandhu G, Cheesman AD. Cricothyroid approximation and subluxation in 21 male-to-female transsexuals. *Laryngoscope*. 2005; 115: 611-618. doi: 10.1097/01.mlg.0000161357.12826.33