Openventio PUBLISHERS

ISSN 2470-4059

OTOLARYNGOLOGY

Open Journal

| December 2019 | Volume 5 | Issue 2 |

www.openventio.org

ISSN 2470-4059

OTOLARYNGOLOGY
Open Journal

Openventio
PUBLISHERS

CONTENTS

ISSN 2470-4059

OTOLARYNGOLOGY

Open Journal

Openventio PUBLISHERS

Original Research

The Effectiveness of Inferior Turbinoplasty in Children with Nasal Obstruction

Balegh H. Abdelhak, MD*; Ahmed A. Sadek, MD; Rasha A. Abdel Moneim, MD; Zein A. Saad, Msc

Department of ENT, Minia University Hospital, Minia 611111, Egypt

***Corresponding author**
Balegh H. Abdelhak, MD
Professor, Department of ENT, Minia University Hospital, HoriyaStreet ,Kornesh El Nil, Minia 611111, Egypt; Tel. 00201145099994; Fax. 00208632342505;
E-mail: balegh@hotmail.com

Article information
Received: June 14th, 2019; **Accepted:** June 20th, 2019; **Published:** June 27th, 2019

Cite this article
Abdelhak BH, Sadek AA, Moneim RAA, Saad ZA. The effectiveness of inferior turbinoplasty in children with nasal obstruction. *Otolaryngol Open J*. 2019; 5(2): 22-25. doi: 10.17140/OTLOJ-5-155

ABSTRACT

Objective
To evaluate the effectiveness of medial flap inferior turbinoplasty for the treatment of nasal obstruction in children.

Patients and Methods
This study was conducted at the ear nose throat (ENT) Department at Minia University Hospital, Minia, Egypt which include 40 children with bilateral nasal obstruction due to bilateral hypertrophied inferior turbinates that did not respond to medical treatment for 3 successive months in the form of (systemic antihistamines, systemic and local decongestant drugs and local corticosteroid spray) who attended the ENT outpatient clinic. All patients were subjected to turbinate reduction through medial flap inferior turbinoplasty.

Results
Forty patients with bilateral hypertrophied inferior turbinates were assessed. Ninety days after surgery, 90% of patients transformed from severe or moderate degrees of nasal obstruction "pre-operatively" to mild degree or completely with no nasal obstruction; 80% of patients had grade I improvement in nasal obstruction and 14 patients had only grade II improvement; only 10% of patients had crustation.

Conclusion
Medial flap inferior turbinoplasty is safe and effective in the treatment of nasal obstruction in children with almost no complications was recorded.

Keywords
Inferior turbinate hypertrophy; Inferior turbinoplasty; Nasal obstruction; Children.

INTRODUCTION

Nasal obstruction caused by inferior turbinate hypertrophy is a common complaint among the pediatric population. Symptoms include mouth breathing, snoring or obstructive sleep apnea, and nasal drainage.[1,2]

Medical treatments include inhaled nasal corticosteroids, nasal irrigation, systemic medications (eg, leukotriene receptor antagonists, second-generation antihistamines), and immunotherapy. When medical therapy has failed, surgical reduction of the inferior turbinates has become a popular option.[3,4]

Goals for the ideal inferior turbinoplasty (IT) include maximizing nasal airflow while limiting crusting and synechiae formation by preserving the turbinate mucosa.[2,4]

Current surgical techniques for IT include radiofrequency ablation (RFA), microdebridement, and partial turbinectomy, although no consensus on a superior method or device has been established.[3]

In our study, all children patients underwent medial flap inferior turbinoplasty to explore the success and failure of rates of this procedure in the treatment of nasal obstruction in children.

Otolaryngol Open J. 2019; 5(2): 22-25. doi: 10.17140/OTLOJ-5-155

PATIENTS AND METHODS

This study was conducted at the ear nose throat (ENT) department at Minia University Hospital, Minia, Egypt which include 40 children with bilateral nasal obstruction due to bilateral hypertrophied inferior turbinates that did not respond to medical treatment for 3 successive months in the form of (systemic antihistamines, systemic and local decongestant drugs and local corticosteroid spray) who attended the ENT outpatient clinic. All patients were subjected to turbinate reduction through medial flap inferior turbinoplasty.

Technique

Medial flap turbinoplasty: The procedure commences with the creation of a window to the inferior meatus, at the anterior inferior turbinate in the axilla between the inferior turbinate medially and the pyriform aperture laterally. The posterior soft tissue tail is removed with the microdebrider, and a medial flap is created by removal of the inferior border. The remaining mucosal flap is elevated in a subperiosteal plane using a cottle dissector as shown in Figure 1. The turbinate bone and lateral mucosa are then removed along the vertex of the inferior meatus. The arterial supply, the medial and lateral branches of the inferior turbinate artery, is then identified and cautery is applied using a bayonet bipolar forceps. Attention is then directed at sculpting the anterior head, undermining the soft tissue with microdebrider or ensuring bone removal is flush to the pyriform. The medial flap is then rotated laterally onto itself and surgical dressing is placed to support the flap as shown in Figure 2.

Figure 1: *Right Nasal Cavity: (A) Creation of Window, (B) Inferior Meatus, (C) Medial Flap Creation, and (D) Elevation of Medial Flap*

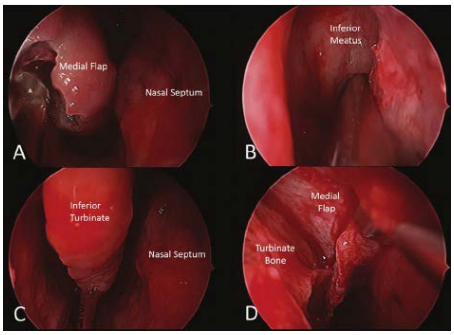

Figure 2: *Right Nasal Cavity: (A) Bone Removal Along Vertex Of Inferior Meatus, (B) Inferior Turbinate Artery, (C) MFinal Positioning Of Medial Flap, and (D) 10-Day Post Operative Appearance*

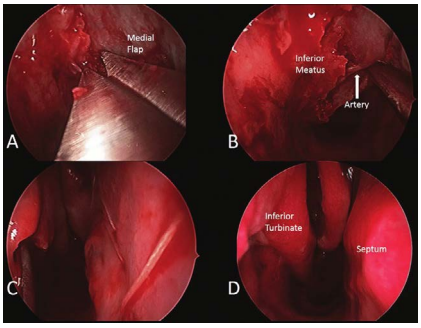

The patients were given oral antibiotics, local nasal decongestant for 1 week and nasal douche with sodium bicarbonate for 2 weeks post-operatively.

In all patients follow-up was carried-out on two weeks, one month and three months post-operatively to assess the previous parameters.

Statistical Analysis

Categorical data were presented as counts and proportions (percentages). Normal distribution of continuous data was tested using a Kolmogorov-Smirnov test. Continuous and normally distributed data are presented as mean ±1 standard deviation and were compared by two-tailed unpaired *t*-test. Student *t*-test and one-way ANOVA were used to compare continuous variables. statistical significance was defined if $p<0.05$. All analyses were performed with SPSS version 24.0 statistical software (SPSS, Inc., Chicago, Illinois, USA).

RESULTS

The study was done on 40 patients, 17 (42.5%) were females and 23 (57.5%) were males. Patients were in the age range of 6-16 years (mean 12.1±2.6) with no significant difference regarding the age and sex distribution (Table 1).

Table 1. *Shows Baseline Characteristic Data in the Study Group*

	Number	Percentage
Sex:		
Males	23	57.5%
Females	17	42.5%
	Mean	SD
Age (years)	12.1	2.6

Degree of Nasal Obstruction

In our study, all the 40 patients (100%) had some degrees of nasal obstruction pre-operatively, it was severe in 12 (30%) cases, moderate in 28 (70%) cases.

In 2nd week following the surgery, there is mild improvement in nasal obstruction as it became no obstruction in 7 (17.5%), mild in 11 (27.5%), moderate in 17 (42.5%), severe in 5 (12.5%).

After the 2nd week there was gradual & statistically significant (p-value<0.001) improvement in nasal obstruction started mostly at 1 month and persisted for 3 months where in the 1st month post-operative visit, only 2 patients (5%) have severe obstruction & on the 3rd month post-operative visit 29 patients (72.5%) had subjectively no nasal obstruction, 7 patients (17.5) had mild obstruction, 3 patients (7.5%) had moderate obstruction and 1 patient (2.5%) had severe obstruction (Table 2).

Table 2. *Degree of Nasal Obstruction Pre and Post-Operative (At 2 weeks, 1 Month and 3 Months)*

Parameter	Pre-operative	2nd Week	1st Month	3th Month	*p value*
No	0(0%)	7(17.5%)	20(5%)	29(72.5%)	<0.01
Mild	0(0%)	11(27.5%)	9(22.5%)	7(17.5%)	
Moderate	28(70%)	17(42.5%)	9(22.5%)	3(7.5%)	
Severe	12(30%)	5(12.5%)	2(5%)	1(2.5%)	

Endscopic Grading of Inferior Turbinate Hypertrophy (ITH)

In our study, we used a freidman grading system for scoring turbinate hypertrophy and all the patients were in grade 2 and 3 pre-operatively, grade 2 in 23 (57.5%) and grade 3 in 17 (42.5%).

There was significant improvement ($p<0.001$) in turbinate hypertrophy grades (inferior turbinate size) in different periods after the procedure where in the 3rd month most of patients (32/80%) had grade I inferior turbinate hypertrophy, only (8/20%) of patients had grade II and no patient had grade III (Table 3).

Table 3. *Inferior Turbinate Hypertrophy Grading Pre and Post-Operative (at 2 Weeks, 1 Month and 3 Months)*

Parameter	Pre-operative	2nd Week	1st Month	3th Month	*p value*
Grade I	0(0%)	3(7.5%)	20(50%)	32(80%)	<0.01
Grade II	23(57.5%)	25(62.5%)	16(40%)	8(20%)	
Grade III	17(42.5%)	12(30%)	4(10%)	0(0%)	

Complications After Surgery

In our study, the surgery was well tolerated by most of patients with low rate of minor complications & no major or significant complications like severe epistaxis or intranasal adhesion were reported during or after the operation.

At the 2nd week following surgery, we observed crustations in all of patients which was mild crustations in 27 (67.5%), severe in 13 (32.5%) & then gradually reduced with time where present in only 17 (42.5%) at 1st post-operative month and after 3 months only 4 patients (10%) had mild crustations (Table 4).

Table 4. *Degree of Crustations Post-Operative (At 2 weeks, 1 Month and 3 Months)*

Parameter		2nd Week	1st Month	3th Month	*p value*
Crustation	No	0(0%)	23(57.5%)	36(90%)	<0.01
	Mild	27(67.5%)	12(30%)	4(10%)	
	Severe	13(32.5%)	5(12.5%)	0(0%)	

DISCUSSION

Nasal obstruction is a common complaint in children and it can impair normal breathing, forcing patients to breathe through the mouth and often affects their daily activities, it is often caused by inferior turbinate enlargement or hypertrophy.[5]

Inferior turbinoplasty (IT) in pediatric patients is a common procedure used to treat childhood nasal obstruction, the goals for the ideal inferior turbinoplasty include maximizing nasal airflow while limiting crusting and synechiae formation by preserving the turbinate mucosa.[6]

This is a prospective study included a total of 40 children patients with bilateral nasal obstruction due to bilateral hypertrophied inferior turbinates. Patients did not respond to medical treatment for 3 successive months and all these patients were subjected to turbinate reduction through inferior turbinoplasty.

Post-operative Follow-up (Outcomes)

Degree of nasal obstruction: The present results revealed that there was a significant improvement in the degree of nasal obstruction at 1 and 3 months post-operatively, this was evidenced by that the majority of patients transformed from severe or moderate degrees of nasal obstruction "pre-operatively" to mild degree or completely with no nasal obstruction ($p<0.001$). These results are in agreement with one study who assessed the efficacy of inferior turbinoplasty in patients with nasal obstruction. They found that after 3 months post-operative, 94.7% of patients had good improvement in breathing, either grades IV or V.[7]

One study studied the long-term outcomes in medial flap inferior turbinoplasty in patients with nasal obstruction. They found that the procedure improved obviously nasal obstruction degree (the outcome was 90.2%) and they concluded that medial flap inferior turbinoplasty provided consistent, robust results. Long-term relief of obstructive symptoms without additional risk of complication.[8]

Another study studied the clinical outcomes of inferior turbinoplasty in the management of inferior turbinate hypertrophy. They assessed pre-operatively and 1st week, 1st month and 3rd month post-operatively depending on subjective visual analogue scale scores for nasal obstruction. They found that there was significant improvement in nasal obstruction. Pre-operatively, nasal obstruction was moderate to severe in all patients, at the first post-operative week 18 patients (60.0%) had no obstruction, and 12 (40.0%) had mild obstruction, on the 1st post-operative month 23 (76.7%) patients had no obstruction and 7 patients still had mild nasal obstruction while on the 3rd post-operative month the total number of patients with no obstruction was 26 (86.7%) and only 4 patients remained with mild one.[9]

Turbinate hypertrophy grades: The present results demonstrated that there was a significant improvement ($p<0.001$) in turbinate hypertrophy grades at different follow up periods post-operatively (at 2nd week post-operative, 3 patients (7.5%) had grade I , 25 patients (62.5%) had grade II and 12 patients (30%) had grade III . However, after 1 month, 20 patients (50%) had grade I, 16 patients (40%) had grade II and 4 patients (10%) had grade III. After 3 months, 32 patients (80%) had grade I and 8 patients (20%) had grade II. one study who studied the clinical outcomes of inferior turbinoplasty

in the management of inferior turbinate hypertrophy agreed with our results. They found that regarding the grading of turbinate hypertrophy, pre-operatively, 11 patients (36.7%) had grade 2 and the remaining 19 patients (63.3%) had grade 3 while none had grade 1, post-operatively all the patients had grade 1. This improvement was statistically significant.[9]

Another study who studied inferior turbinoplasty technique for the treatment of nasal obstruction. They found that this procedure affected significantly the degree of turbinate hypertrophy and is effective in the improvement of the complaint of nasal obstruction post-operative.[10]

Post-operative complications: Regarding degree of crustations, the present results showed that degree of crustations was significantly improved ($p<0.001$) at 3 months post-operatively (at the 2nd week following surgery, all of patients had crustations, however, only 4 patients (10%) had mild crustations). However, the results showed that there were no intranasal adhesions or bleeding at 2nd weeks, 1 month, 3 months after surgery.

Similar to our findings, one study found that more than 85% of patients who usually had itching, sneezing, and rhinorrhea achieved moderate or complete recovery 3 months after the surgery and the degree of crustations was significantly improved.[8] Also another study, found that medial flap inferior turbinoplasty resulted in long-term relief of obstructive symptoms without additional risk of complication (The technique was associated with low rates of nasal crusting and troublesome primary hemorrhage or intranasal adhesions.[8]

Also, our results are confirmed by another study who studied the clinical outcomes of inferior turbinoplasty in the management of inferior turbinate hypertrophy. They found that crusting was reported in 26 (86.7%) patients at the first post-operative week and the number changed to 5 (16.7%) patients at the first month while at the end of follow-up period, (3rd month) no patient had crusting. Also, bleeding occurred post-operatively where only 2 (6.7%) patients developed bleeding at the first post-operative week and none at the next follow up periods. In the present study, the gradual decrement in crusting might be due to mucosal preservation of the medial surface of IT and meticulous treatment that was given to the patients during the post-operative period.[9]

CONCLUSION

Medial flap inferior turbinoplasty is safe and effective in the treatment of nasal obstruction in children with almost no complications was recorded. The removal of both the lateral mucosa and the bone, as well as a controlled reduction of the medial mucosa, is less likely to lead re-expansion of the turbinate with the passage of time.

FUNDING SOURCES

This study was supported by personal funds and funds from Minia University.

ETHICAL APPROVAL

All procedures performed in this study followed the 1964 Helsinki declaration and its later amendments and was approved by the local research ethics committee at Minia Faculty of Medicine. Informed consent was obtained from all the study participants.

CONFLICTS OF INTEREST

The authors declare that they have no conflicts of interest.

REFERENCES

1. Segal S, Eviatar E, Berenholz L, Kessler A,Shlamkovitch N. Inferior turbinectomy in children. *Am J Rhinol.* 2003; 17(2): 69-73. doi: 10.1177/194589240301700201

2. O'Connor-Reina C, Garcia-Iriarte MT, Angel DG, Morente JC, Rodrguez-Diaz A. Radio frequency volumetric tissue reduction for treatment of turbinate hypertrophy in children. *Int J Pediatr Otorhinolaryngol.* 2007; 71(4): 597-601. doi: 10.1016/j.ijporl.2006.12.009

3. Jiang ZY, Pereira KD, Friedman NR,Mitchell RB. Inferior turbinate surgery in children: A survey of practice patterns. *Laryngoscope.* 2012; 122(7): 1620-1623. doi: 10.1002/lary.23292

4. Chen YL, Liu CM, Huang HM. Comparison of microdebrider assisted turbinoplasty and submucosal resection for children with hypertrophic inferior turbinates. *Int J pediatr otolaryngol.* 2007; 1: 921-927. doi: 10.1016/j.ijporl.2007.03.002

5. Nurse L, Duncavage J. Surgery of the inferior and middle turbinates. *Otolaryngol Clin North Am.* 2009; 42: 295-309. doi: 10.1016/j.otc.2009.01.009

6. Arganbright JM, Jensen EL, Mattingly J, Gao D, Chan KH. Utility of inferior turbinoplasty for the treatment of nasal obstruction in children. *JAMA Otolaryngol Head Neck Surg.* 2015; 141(10): 901-904. doi: 10.1001/jamaoto.2015.1560

7. Hamerschmidt R, Hamerschmidt R, Moreira AT, Tenório SB, Timi JR. Comparison of turbinoplasty surgery efficacy in patients with and without allergic rhinitis. *Braz J Otorhinolaryngol.* 2016; 82(2): 131-139. doi: 10.1016/j.bjorl.2015.10.010

8. Barham HP, Knisely A, Harvey RJ, Sacks R. How I do it: Medial flap inferior turbinoplasty: With illustration and video. *American Journal of Rhinology and Allergy.* 2015; 29(4): 314-315. doi: 10.2500/ajra.2015.29.4168

9. Al-Helo S, Falih H, Jumma A. Powered endoscopic inferior turbinoplasty: clinical study. *Int J Otorhinolaryngol Head Neck Surg.* 2018; 4: 24-31. doi: 10.18203/issn.2454-5929.ijohns20175608

10. Rodrigues MM, Dibbern RS, de Oliveira LF, et al. Comparison between turbinoplasty and endoscopic turbinectomy: Efficacy and clinical parameters. *Intl Arch Otorhinolaryngol.* 2011; 15(4): 426-430. doi: S1809-48722011000400004

ISSN 2470-4059

OTOLARYNGOLOGY

Open Journal

Openventio PUBLISHERS

Letter to the Editor

Coexistence of Tuberculosis and Metastatic Undifferentiated Carcinoma of Nasopharynx in Cervical Lymph Node

Sameh Mezri, MD[1*]; Sameh Sayhi, MD[2]; Marwa Ben Amira, MS[1]; Issam Msakni, PhD[3]; Besma Laabidi, MD[3]; Rania Ben M'hamed, PhD[1]; Khemaies Akkeri, PhD[1]

[1]*ENT Department, Military Hospital of Tunis, Montfleury 1008, Tunisia*
[2]*Internal Department of Medicine, Military Hospital of Tunis, Montfleury 1008, Tunisia*
[3]*Anatomopathology Department, Military Hospital of Tunis, Montfleury 1008, Tunisia*

***Corresponding author**
Sameh Mezri, MD
ENT Department, Military Hospital of Tunis, Montfleury 1008, Tunisia; Tel. 0021693395662; ORCID. 0000-0002-6889-4181; E-mail: mezrisameh@gmail.com

Article information
Received: May 25th, 2019; **Revised:** June 21st, 2019; **Accepted:** June 27th, 2019; **Published:** June 28th, 2019

Cite this article
Mezri S, Sayhi S, Ben Amira M, et al. Coexistence of tuberculosis and metastatic undifferentiated carcinoma of nasopharynx in cervical lymph node. *Otolaryngol Open J*. 2019; 5(2): 26-28. doi: 10.17140/OTLOJ-5-156

ABSTRACT

The coexistence of a head and neck cancer and a lymph node tuberculosis is rarely described. The problem is essentially diagnostic. We report the case of a patient with cervical lymphadenopathy and non suspect swelliing of nasopharynx. Histopathological study of lymph node reveled an association of a tubercular adenitis and a metastasis of a squamous cell carcinoma.

Keywords
Lymph nodes tuberculosis; Undifferentiated nasopharyngeal carcinoma (UCNT); Lymph nodes metastasis.

TO THE EDITOR

The association of a cancer and a tuberculosis infection has been frequently described. However, the coexistence of metastasis and tuberculosis in the same lymph node is rare. Warthin[1] described, in 1899, the first two cases of breast cancer with histological discovery of axillary lymph node tuberculosis during axillary curage. Since then, rare cases of metastasis of face and neck cancer associated with tuberculosis adenitis have been reported.[2,3] To our knowledge, only one case of coexistence of cervical tubercular lymphadenitis with metastatic cervical lymph nodes of nasopharynx cancer has been reported.[4] The objective of our study is to insist on the importance of mentioning this association especially in endemic countries.

CASE REPORT

We report the case of a 34-year-old patient, with a history of lung tuberculosis treated and cured 11-years ago. He has been addressed to us for a left lateral cervical swelling evolving for seven months and gradually increasing in size. Interrogation was poor, with no signs of tuberculous impregnation or rhinological complaints.

Clinical examination revealed left subdigastral adenopathy, 4 cm long, painful and fixed to the superficial and deep planes with healthy-looking skin.

Nasal endoscopy noted a thickening of the left side wall of nasopharynx considered not suspect. The tuberculin incidence density ratio (IDR) was positive. Cervical ultrasound noted the presence of bilateral hypoechogenic adenomegalies, with preserved echostructure, well limited. On the cervico-thoracic computed tomography (CT), the adenomegalies had a necrotic center (Figure 1), a sequelae of an old pulmonary tuberculosis, bronchiectasis and a respiratory collapse of the right upper lobe.

In front of this clinical presentation, we evoked the diagnosis of lymph node tuberculosis and we opted for a cervicotomy with excision of the left subdigastric adenopathy. Anatomopathological examination concluded that a coexistence of tuberculosis adenitis and lymph node metastasis of an undifferentiated squamous cell carcinoma that nasopharyngeal origin is more likely (Figures 2,3 and 4).

Otolaryngol Open J. 2019; 5(2): 26-28. doi: 10.17140/OTLOJ-5-156

Figure 1: *Cervical CT Objectifying Group II Heterogeneous and Necrosed Adenomegalies*

Figure 2: *HE*250: Association of Undifferentiated Carcinomatous Proliferation with Epithelioid Granuloma Centered by Caseous Necrosis*

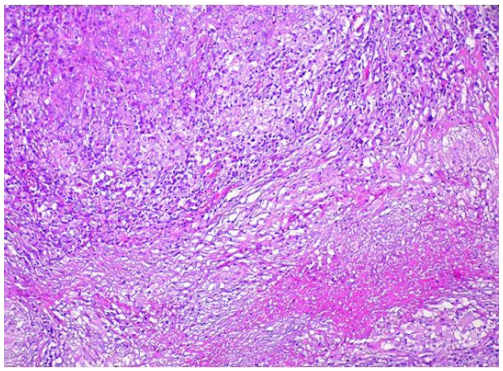

Figure 3: *HE*400: Undifferentiated Carcinomatous Proliferation with Lymphoid Stroma Suggestive of Undifferentiated Nasopharyngeal Carcinoma (UCNT).*

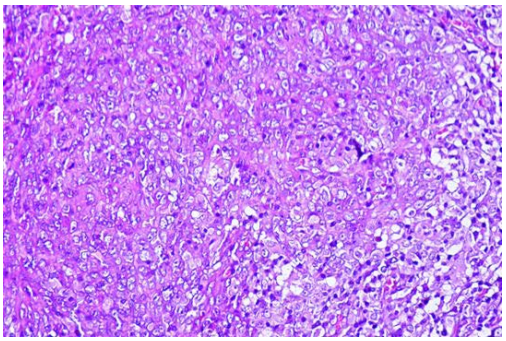

Figure 4: *HE*400: Epithelioid and Gigantocellular Granuloma Centered by Caseous Necrosis*

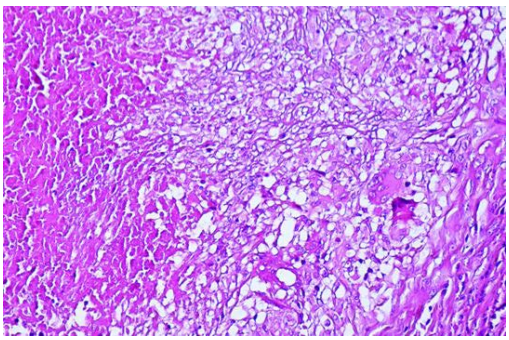

A new cavum CT objectivated an irregular thickening of the nasopharynx filling the Rosen Muller fossa and necrotic adenomegalies of all the cervical and retropharyngeal chains. Anatomopathological study of the biopsy curettage of the cavum confirmed the diagnosis of the undifferentiated nasopharyngeal carcinoma (UCNT) of nasopharynx.

No other location of tuberculosis was found and UCNT was classified T2N2M0 stage.

Treatment was provided in collaboration with infectious disease specialists and oncologists. The patient received combined TB treatment with a standard protocol for a total of nine months (two months of isoniazid (H), rifampicin (R), pyrazinamide (Z) and ethambutol (E) (HRZE) quadritherapy and seven months of heartbeats (HR) bitherapy). The anti-cancer protocol was started fifteen days after the initiation of antituberculous treatment with neo-adjuvant chemotherapy, followed by concomitant chemoradiotherapy.

After a follow-up of 18-months, the clinical and radiological examination (cervical ultrasound and facial magnetic resonance imaging (MRI)) do not find any tumour or tuberculosis recurrence.

DISCUSSION

Chronic cervical adenopathies are a common reason for ears, nose, and throat (ENT) consultation. The etiology may be infectious, including tuberculosis, or malignant (hemopathy, metastasis of solid cancer). The diagnostic approach depends on clinical and epidemiological context.

Tunisia remains, like the third world countries, endemic of tuberculosis, especially in its cervical lymph node location which represents the most frequent localization of extra-pulmonary tuberculosis. On the other hand, we are also a country of intermediate endemicity for the UCNT of the nasopharynx which is frequently revealed by the presence of cervical adenopathies.

However, the association of tuberculosis and cancer has been described by several authors,[5] who suggest that the simultaneous or secondary existence of both disorders in the same patient is favored by a state of chronic immunosuppression. However, the presence in the same adenopathy of a tuberculosis infection and a neoplasia is rare, commonly described in patients with breast cancer or lung cancer or lymphoma[5-7] than in patients with a squamous cell carcinoma of the head and neck.[2,3,8] To our knowledge, the case that we report, of coexistence of cervical tubercular lymphadenitis and cervical metastatic lymph nodes of undifferentiated cavum cancer, is the second case described in the literature.[4]

Physiopathologically, the *Mycobacterium Tuberculosis* can escape the immune response and develop persistent chronic inflammation by producing nitric oxide and oxygen-derived reagents (free radicals, oxygen ions, peroxides). This chronic inflammation with apoptosis inhibition and resulting deoxyribonucleic acid (DNA) alterations are responsible for mutations preceding dysplasia and thus carcinogenesis.[9,10] In addition to that, latent tuberculosis reactivation in patients with cancer may occur because of immunosuppression.[7]

The simultaneous occurrence of tuberculosis and cancer in the same lymph node leads to a diagnostic dilemma. For our patient, the personal history of tuberculosis, the context of tuberculosis in his brother and the radiological data made that the diagnosis of lymph node tuberculosis was evoked in the first place. But it was thanks to the anatomopathological examination of the adenectomy piece that a concomitant UCNT of the cavum was discovered.

Besides, the initial discovery of lymph node metastases allows to make the diagnosis of the cancer, especially if the lymphadenopathies are on the drainage area of the cancer, as the UCNT of the cavum known for its high lymphophilia which reaches 60 to 80% of the cases. So a heavier treatment would be prescribed because of the over-estimation of the cancer stage which would also lead to the dissemination of tuberculous disease secondary to the immunosuppression generated by cancer chemotherapy.

However, therapeutic failure in the treatment of cervical lymph node tuberculosis, was the mode of revealing of synchronous involvement with head and neck cancer in most published cases[2-4,8]; In all this cases, the diagnosis of tuberculosis was based on cytopunction data, which did not identify cancer cells.

Otherwise, it was a histological discovery during a systematic lymph node curage for malignant neoplasia.[6,7]

CONCLUSION

Coexistence of cervical lymph node tuberculosis and head and neck cancer, particularly the nasopharynx cancer, must always be present in the mind of the practitioner especially in an endemic country for both affections. Diagnostic delay in one of the pathologies can worsen the patient's clinical condition and make therapeutic management more difficult.

CONSENT

The authors have received written informed consent from the patient.

CONFLICTS OF INTEREST

The authors declare that they have no conflicts of interest.

REFERENCES

1. Warthin AS. The coexistence of tuberculosis and carcinoma of the mammary gland. *Am J Med Sci*. 1899; 118: 125. doi: 10.1097/00000441-189907000-00003

2. Gheriani H, Hafidh M, Smyth D, O'Dwyer T. Coexistent cervical tuberculosis and metastatic squamous cell carcinoma in a single lymph node group: A diagnostic dilemma. *Ear Nose Throat J*. 2006; 85 :397-399. doi: 10.1177/014556130608500621

3. Barwad A, Gowda KK, Dey P. Co-existent of tuberculosis and squamous cell carcinoma in a lymph node diagnosed by fine needle aspiration cytology. *Cytopathology*. 2012; 23: 276-277. doi: 10.1111/j.1365-2303.2011.00878.x

4. Choukry C, Benouhoud J. Association de lymphadénites tuberculeuses cervicales et de ganglions métastatiques cervicaux d'un cancer du nasopharynx (à propos d'un cas) [In: French]. *Médecine Nucléaire*. 2018; 42: 176-177. doi: 10.1016/j.mednuc.2018.03.116

5. Falagas ME, Kouranos VD, Athanassa Z, Kopterides P. Tuberculosis and malignancy. *Q J Med*. 2010; 103: 461-487. doi: 10.1093/qjmed/hcq068

6. Pandey M, Abraham EK, K C, Rajan B. Tuberculosis and metastatic carcinoma coexistence in axillary lymph node: A case report. *World J Surg Oncol*. 2003; 1: 3. doi: 10.1186/1477-7819-1-3

7. Centkowski P, Sawczuk-Chabin J, Prochorec M, Warzocha K. Hodgkin's lymphoma and tuberculosis coexistence in cervical lymph nodes. *Leuk Lymphoma*. 2005; 46: 471-475. doi: 10.1080/10428190400019891

8. Caroppo D, Russo D, Merolla F, et al. A rare case of coexistence of metastasis from head and neck squamous cell carcinoma and tuberculosis within a neck lymph node. *Diagn Pathol*. 2015; 10: 197. doi: 10.1186/s13000-015-0430-x

9. Shin DM, Yang CS, Lee JY, et al. Mycobacterium tuberculosis lipoprotein-induced association of TLR2 with protein kinase C zeta in lipid rafts contributes to reactive oxygen species-dependent inflammatory signalling in macrophages. *Cell Microbiol*. 2008; 10: 1893-1905. doi: 10.1111/j.1462-5822.2008.01179.x

10. Kawanishi S, Hiraku Y, Pinlaor S, Ma N. Oxidative and nitrative DNA damage in animals and patients with inflammatory diseases in relation to inflammation-related carcinogenesis. *Biol Chem*. 2006; 387: 365-372. doi: 10.1515/BC.2006.049

ISSN 2470-4059

OTOLARYNGOLOGY
Open Journal

Openventio PUBLISHERS

Retrospective Study

Outcomes of Vocal Fold Immobility After Pediatric Cardiovascular Surgery

Anatoli F. Karas, MD[1]; Aniruddha Patki, MD[1]; Marisa A. Ryan, MD, MPH[1]; Patrick A. Upchurch, MD[2]; Rose J. Eapen, MD[1]; Eileen M. Raynor, MD[1*]

[1]*Department of Surgery, Division of Head and Neck Surgery & Communication Sciences, Duke University Medical Center, DUMC 3805, Durham, NC 27710, USA*
[2]*Department of Surgery, Boston Children's Hospital, 300 Longwood Avenue, Fegan 3, Boston, MA 02115, USA*

***Corresponding author**
Eileen M. Raynor, MD
Associate Professor, Department of Surgery, Division of Head and Neck Surgery & Communication Sciences, Duke University Medical Center, DUMC 3805, Durham, NC 27710, USA; Tel. 919-613-4573; Fax. 919-668-3103; E-mail: eileen.raynor@duke.edu

Article information
Received: June 30th, 2019; **Accepted:** July 11th, 2019; **Published:** July 17th, 2019

Cite this article
Karas AF, Patki A, Ryan MA, Upchurch PA, Eapen RJ, Raynor EM. Outcomes of vocal fold immobility after pediatric cardiovascular surgery. *Otolaryngol Open J*. 2019; 5(2): 29-33. doi: 10.17140/OTLOJ-5-157

ABSTRACT

Objectives
Cardiovascular surgery is increasingly performed in children for congenital malformations of the heart and great vessels. Observed as vocal fold immobility, recurrent laryngeal nerve injury is a well-described complication. As overall outcomes improve and patients live longer, the sequelae of vocal fold immobility amplify insignificance. Families are often unaware of the long-term issues related to vocal fold immobility especially with regard to need for alternative alimentation routes. We report on the incidence of use of feeding tubes, the timing of vocal fold function return and need for additional aerodigestive interventions.

Methods
We reviewed 65 patients <2-years who underwent cardiovascular surgery at a tertiary center from 2008-2013 and were diagnosed post-operatively with vocal fold immobility by fiberoptic examination.

Results
Patent ductus arteriosus and hypoplastic left heart syndrome were the most common of the cardiovascular anomalies included. The majority (92%) had unilateral left immobility. Recovery of motion was observed in 29% ranging from 1-month to 3-years. Hypoplastic left heart syndrome had a significant negative correlation with recovery. Forty-six percent required gastrostomy tube placement either to supplement their oral intake or to completely meet their nutritional needs. Forty-eight percent required subsequent aerodigestive surgery including direct laryngoscopy/bronchoscopy (22%), tracheostomy (8%) and vocal fold injection (5%).

Conclusion
Counseling of families and primary care providers regarding the impact of pediatric vocal fold immobility after cardiac surgery should include the high potential requirement for supplemental alimentation as well as the need for feeding and speech therapy. Longitudinal otolaryngology and speech pathology care is imperative with vocal fold immobility since the majority of these patients do not experience functional recovery and may require further interventions over time.

Keywords
Vocal cord paralysis; Pediatric cardiovascular surgery; Pediatric aerodigestive disorders; Voice; Swallow; Gastrostomy.

INTRODUCTION

Cardiovascular surgery is increasingly performed in infants to correct congenital malformations of the heart and great vessels. Due to the anatomic course of the recurrent laryngeal nerve, it is especially prone to injury during procedures requiring aortic arch manipulation and/or reconstruction. These malformations range in both incidence and complexity. Patent ductus arteriosus (PDA) represents up to 10% of all congenital heart disease with an incidence of up to 2.8 per 1000 live births.[1] Surgical PDA ligation

Otolaryngol Open J. 2019; 5(2): 29-33. doi: 10.17140/OTLOJ-5-157

can be performed without cardiopulmonary bypass and requires limited dissection around the aortic arch. Conversely, hypoplastic left heart syndrome (HLHS) is a single ventricle lesion that occurs in approximately 0.18 per 1000 live births and requires staged palliation and extensive aortic arch reconstruction under deep hypothermic circulatory arrest or regional cerebral perfusion.[2]

Observed post-operatively as vocal fold immobility, recurrent laryngeal nerve injury is a well-described complication of these surgeries. Prolonged or traumatic intubations, which can also occur in this patient population, can also cause post-extubation vocal fold immobility. The reported incidence of vocal fold immobility after pediatric cardiovascular surgery varies in the literature from 8.7% to 39%.[3] The use of extracorporeal membranous oxygenation (ECMO) also increases the risk of recurrent laryngeal nerve (RLN) injury, primarily on the right side.[4] Multiple factors have been reported to predispose to vocal fold immobility, including low birth weight, younger age at surgery, and use of electrocautery during dissection around the aorta.[5-7] However, data is lacking on long-term outcomes of vocal fold immobility in pediatric patients after cardiovascular surgery. As techniques and overall outcomes improve, these patients live longer and the sequelae of vocal fold immobility amplify in significance. We report on the incident need for supplemental alimentation *via* surgical feeding tube, the timing of vocal fold motion return and the requirement for additional aerodigestive interventions in a series of these children from a single tertiary academic medical center.

METHODS

Population

We performed a retrospective chart review of all 65 patients <2-years-old who underwent cardiovascular surgery at Duke University Medical Center (DUMC) from 2008 to 2013 and were diagnosed post-operatively with vocal fold immobility by awake, bedside fiberoptic examination (FOE). The FOE was performed by otolaryngology resident and viewed by an otolaryngology attending either directly or on video recording.

Inclusion criteria were: less than 2-years-old at the time of their first corrective cardiovascular surgery; primary surgery performed at Duke and assigned international classification of diseases-9 (ICD-9) codes for vocal fold immobility and congenital cardiovascular abnormality. At DUMC, a diagnosis of vocal fold immobility is only made by otolaryngology and, therefore, all included patients were evaluated by the otolaryngology service.

Data Collection and Analysis

Patient charts were reviewed to determine the date of surgery and dates of subsequent follow-up with otolaryngology. Follow-up was defined as any inpatient evaluation or outpatient clinic visit, regardless of whether or not FOE was performed. The dates of post-operative follow-up visits were measured from the patient's surgery and used to determine the time to recovery. Recovery was defined by either a FOE documenting the return of vocal fold mobility, or documentation of a normal cry, completely oral feeding status, and breathing if FOE was not performed.

Secondary measures collected included the dates and types of operative procedures on the airway, including direct laryngoscopy/bronchoscopy, vocal fold injection, and tracheostomy. We also determined the proportion of patients requiring surgical placement of a feeding tube. The numbers in each category were evaluated with the Pearson's Chi-squared test for count data (more than two categories) assuming equal probability for each category. The significance level for assessing the statistical test was set to $\alpha=0.05$. All analyses were conducted using excel 2010. This study was approved by the Duke Institutional Review Board (Pro00045147).

RESULTS

A total of 65 patients met the inclusion criteria. Of these, 18 patients had a patent ductus arteriosus (PDA), 17 had HLHS, 13 had aortic coarctation, 12 had an interrupted aortic arch, two had transposition of great vessels, one had pulmonary atresia, one had atrioventricular canal defect and one had Tetralogy of Fallot. The median follow-up was 131-days after surgery. The majority of patients (92%) had unilateral immobility of the left vocal fold. There were also four cases of right vocal fold immobility and one with bilateral vocal fold immobility.

All diagnoses of vocal fold immobility were made by FOE while still an inpatient after their initial cardiovascular surgery in all cases. The most common indication for otolaryngology consult was a weak cry following extubation. At DUMC, if there is a clinical concern for vocal fold immobility, the Pediatric Cardiothoracic Intensive Care Unit will withhold oral feeding until after the vocal fold function is assessed, so swallow function was very infrequently known prior to the initial FOE.

Aerodigestive Interventions

During subsequent follow-up, the majority of patients (58%) only underwent one additional FOE. However, one underwent none, 14 (21%) had two, eight (12%) had three, three (4%) had four, and a single patient had five. The most common indication for FOE was it being the first outpatient examination since the diagnosis of vocal fold immobility was made while an inpatient. Another common indication was plateauing of symptoms, such as continued difficulty with oral intake or continued weak cry. The third reason for performing FOE was parental request or anxiety about the prior diagnosis of immobility. The most common reason for not performing a FOE in the office was that parents reported significant improvement in swallowing ability or cry. A less common reason for deferring FOE in the office was an upcoming surgical procedure for the child with a plan to perform direct laryngoscopy/bronchoscopy in the operating room.

Out of all the patients, 31 (48%) underwent a secondary surgical procedure either involving the airway or for a surgical feeding tube placement. The most common airway procedure

performed was direct laryngoscopy/bronchoscopy performed in 14 (22%) patients. Eight of those 14 underwent a single direct laryngoscopy/bronchoscopy whereas four underwent two direct laryngoscopy/bronchoscopies and two patients underwent three direct laryngoscopy/bronchoscopies. Placement of a tracheostomy was necessary for 5 (8%) patients. It was performed for airway obstruction in the setting of bilateral vocal fold paralysis in one patient, respiratory failure in the setting of laryngomalacia and left vocal fold immobility in one patient, tracheobronchomalacia in one patient and ventilator dependence in two patients. Injection medialization of the immobile vocal fold was performed in three (5%) patients.

Surgical placement of a feeding tube was necessary for 30 (46%) of patients. Three of these patients had a surgical feeding tube placed prior to otolaryngology consultation. The most common indication for feeding tube placement was severe reflux in 17 (58%) followed by feeding intolerance in 12 (41%). One patient required a surgical feeding tube for failure to thrive. All of the patients were seen by speech pathology for feeding evaluation and treatment. Of the patient's with surgical feeding tubes, 14 (46%) had at least one videofluoroscopic swallow study (VFSS) for feeding evaluation during initial admission or in follow-up as an outpatient. Seven (23%) of the patients had VFSS prior to surgical feeding tube placement. Four of these showed aspiration. The other three showed no aspiration but continued with gastrostomy tube placement secondary to oral feeding intolerance. Of patients with surgical feeding tubes, 5 (17%) were noted to be transitioning to full oral feeds but their feeding tube remained in place at the end of the study period. Three (10%) children had their surgical feeding tube ultimately removed at a mean of 16-months after placement. Twenty (67%) remained dependent on the feeding tube with little or no significant oral intake at the end of the study period and 2 (7%) expired with the feeding tube in place (Figure 1). Of the 31 patients who underwent subsequent airway procedures or feeding tube placement, 19% exhibited vocal fold recovery. In comparison 13/34 (38%) of children who did not require a second surgical procedure to address their airway, voice or feeding had vocal fold movement recovery. This was not a statistically significant different distribution (p=0.09).

Figure 1. *Feeding Tube Status by End of Study Period*

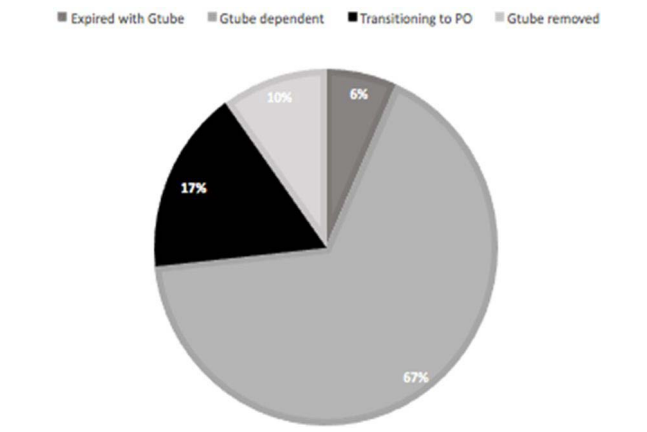

Recovery of Vocal Fold Mobility

Among the 65 patients, 19 (29%) exhibited recovery of vocal fold mobility while 46 (71%) did not. Of the 19 patients with documented return of vocal fold mobility, eight (42%) were based on FOE and 11 (58%) were based clinically on return of normal cry and completely oral feeding status. Among the 19 patients who had recovered vocal fold motion, time to recovery varied widely, with a median of 6-months and range between 1-month to 3-years (Figure 2). In the patients with return of vocal fold motion, 14 (74%) had return of motion documented by 1-year. When patients were stratified by diagnosis, only HLHS exhibited a statistically significant negative correlation with recovery; only one of the 17 patients with HLHS exhibited recovery whereas the remaining 16 did not (Figure 3). This distribution was significantly different from the remainder of the patients (p=0.03).

Figure 2. *Days After Cardiovascular Surgery to Recovery of Vocal Fold Movement with Quartiles*

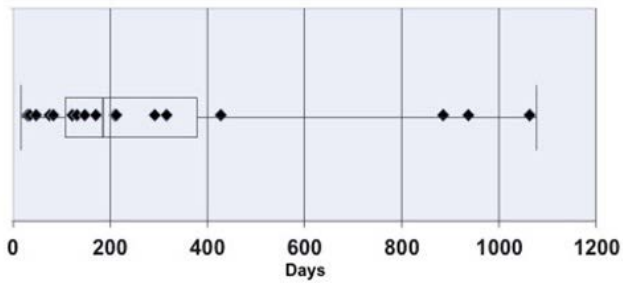

Figure 3. *Recovery of Vocal Fold Movement Stratified by Cardiovascular Diagnosis*

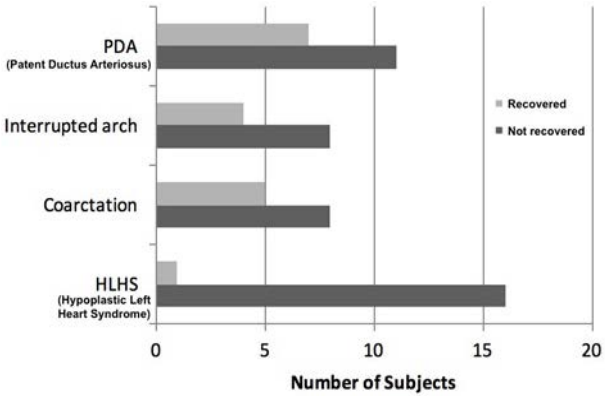

DISCUSSION

Iatrogenic injury to the recurrent laryngeal nerve is the most likely presumed etiology of vocal fold immobility after cardiovascular surgery, but other factors that may contribute include extended periods of intubation, vagal injury from ECMO cannulation or underlying neurologic abnormality. Wilson et al reported that younger age, complex structural abnormality as opposed to a sim-

pler PDA, need for pre-operative intubation, median sternotomy with delayed closure, and palliative surgery were all associated with longer intubation times following pediatric cardiothoracic surgery.[8] In our series, 47/65 (72%) of patients underwent cardiovascular surgery for a structural cardiac defect other than PDA. Furthermore, 17 of these patients underwent aortic arch reconstruction as part of the staged palliation of HLHS. A high proportion of our patients were therefore at risk for prolonged intubation as they recovered from their cardiovascular surgery. Since FOE for vocal fold mobility can only be performed after the child is extubated, it is possible that intubation-related injury was a contributing factor to cases of vocal fold immobility in our study. It was not possible from a retrospective review to differentiate between these potential causes. However, the significant preponderance of left-sided vocal fold paralysis in this study suggests that intra-operative recurrent laryngeal nerve injury was the most common etiology, as we would expect intubation injury, ECMO or an underlying neurologic problems to affect both vocal folds more equally.

Recovery of Function

In this series, 19 patients (29%) exhibited recovery of function over the duration of follow-up. This is a similar to previously reported recovery of 28% and 35%.[9,10] We found a median time to recovery of 6-months with a wide range from 1-month to 3-years (Figure 1). This median is slightly longer than the 130-days found by Jabbour et al.[10] Of the 19 patients who had recovery of function, 13 achieved this by 7-months after their cardiovascular surgery. The remaining six patients exhibited recovery over 1-year from their cardiovascular surgery. Although recovery this long after surgery has been reported, these patients may have actually regained vocal fold movement earlier, but it was documented at a later date when the next clinical follow-up occurred. This measurement error likely falsely increased the recorded duration to recovery for some of the subjects as well as the median time to recovery. An additional limitation of the retrospective nature of this study is that 11 (58%) of the vocal fold mobility recoveries were based clinically on voice and swallow normalization and not visually confirmed with FOE. Some of these symptom-based recoveries may be due to a medially positioned immobile vocal fold or compensatory functions. Therefore, our overall incidence of recovery may be artificially high without confirmatory FOEs on all patients. It should be noted that parents often decline follow-up FOE if the patient is asymptomatic or has improved, which is one reason not all recoveries were documented with FOE.

Recovery in Patients with Hypoplastic Left Heart Syndrome

In our analysis, the only predictive factor for recovery of vocal fold movement was the negative association of recovery with a diagnosis of HLHS. This may be due to several reasons. First, patients with HLHS undergo multiple staged procedures as part of their treatment. These are generally performed around 1-week of life, 4-6-months-old, and 3-4-years-old. There is a very wide range of incidence of vocal fold immobility reported after the first stage, from 9% to 58.7%.[6,11] The method of aortic dissection used may explain some of this variation as Averin et al reported a significant drop in the incidence of vocal fold immobility after this procedure when their group started using a blunt dissection technique rather than electrocautery.[6] Incidence of vocal fold paralysis after the 2nd and 3rd staged procedures has not been well reported, but it is plausible that repeat surgical procedures in the chest may increase the risk of vocal fold immobility. Additionally, although the average period of mechanical ventilation is between three and seven days following the first stage of Norwood reconstruction,[12] potential acute post-operative complications including drastic lability in pulmonary blood flow, derangement of coronary blood flow, myocardial edema, myocardial dysfunction, seizures, stroke, chylothorax, and phrenic nerve injury could contribute to prolonged periods of intubation. It is also possible that the severity of congenital heart disease in these children relegates the sequelae of vocal cord immobility to a lower priority. Consequently, referral to otolaryngology may be delayed or deferred. In our study, patients with HLHS had significantly shorter median follow-up time which may account for their poor outcome with respect to vocal fold function, because they may have been more likely to follow-up before a natural return of vocal fold movement.

Aerodigestive Interventions

We noted a high incidence (46%) of surgical feeding tube placement in these children. This is likely multifactorial in nature. Vocal fold immobility certainly predisposes to aspiration and placement of a feeding tube may be undertaken as a protective measure. In a systematic review, Strychowsky et al identified an odds ratio of 7.3 (95% CI: 1.6, 32.8) for gastrostomy tube usage at the time of discharge in children who had a known vocal fold immobility after cardiothoracic surgery.[3] Sachdeva et al also found in their study of 36 infants with vocal fold immobility after cardiovascular surgery that 55.2% were on a tube feed only regimen at discharge.[4] Skinner et al reported that 48% of neonates undergoing the Norwood procedure had abnormalities on a modified barium swallow study post-operatively, with 24% showing frank aspiration.[11] However, Pereira et al reported that out of seven infants with left vocal fold immobility after PDA ligation, none required placement of a supplemental feeding tube.[13] The contrast between Sachdeva's and Skinner's results compared to Pereira's may be because the first two studies examined infants and neonates undergoing correction of large structural defects with much longer operative times and more extensive dissection near the recurrent laryngeal nerve. In Pereira's study, 5/7 infants had adequate compensation by the contralateral vocal fold whereas the contralateral vocal fold status was not specifically addressed in the two other studies.[13] It is possible that the contralateral vocal fold may not be compensating as well in children who have undergone more significant procedures and this may leave them at higher risk for requiring tube feeds. This could either be due to more extensive surgical dissection putting both recurrent laryngeal nerves at risk, longer post-operative intubation affecting laryngeal and pharyngeal function or general deconditioning. Prolonged and traumatic intubation and congenital immobility are also possible in these patients. These patients do not routinely have pre-operative FOEs to diagnose pre-operative vocal fold immobility.

CONCLUSION

In conclusion, children who have congenital heart disease requiring aortic arch manipulation and/or reconstruction are at risk of persistent vocal fold immobility after their surgical repair. These children require prolonged post-operative monitoring by otolaryngology and speech pathology to verify that they regain vocal fold function and there are no persistent voice or swallowing deficits. Parents and primary care providers should be counseled that their child has an approximately 46% chance of requiring a surgical feeding tube if a vocal fold immobility occurs after cardiovascular surgery, especially in HLHS. Once a surgical feeding tube is placed, the majority retain the tube for several years. Additionally, there is a high likelihood of requiring further operative airway interventions such as laryngoscopy/bronchoscopy or vocal fold medializations along with the need for feeding and speech therapy. They should also be counseled that if the vocal fold movement returns, it will likely be within one year, but in some cases recovery may still occur later.

ACKNOWLEDGEMENTS

This research was supported by a NIDCD training grant to the Division of Head and Neck Surgery & Communication Sciences at Duke University (T32 DC013018-03).

CONFLICTS OF INTEREST

The authors declare that they have no conflicts of interest.

REFERENCES

1. Egbe A, Uppu S, Lee S, Stroustrup A, Ho D, Srivastava S. Temporal variation of birth prevalence in congenital heart disease in the United Sates. *Congenit Heart Dis*. 2015; 10: 43-50. doi: 10.1111/chd.12176

2. Fyler DC, Buckley LP, Hellenbrand WE. Report of the New England regional infant cardiac program. *Pediatrics*. 1980; 65: 375-461.

3. Strychowsky JE, Rukholm G, Gupta MK, Reid D. Unilateral vocal fold paralysis after congenital cardiothoracic surgery: A meta-analysis. *Pediatrics*. 2014; 133: e1708-e1723. doi: 10.1542/peds.2013-3939

4. Sachdeva R, Hussain E, Moss MM, et al. Vocal cord dysfunction and feeding difficulties after pediatric cardiovascular surgery. *J Pediatr*. 2007; 151: 312-315. doi: 10.1016/j.jpeds.2007.03.014

5. Zbar RI, Chen AH, Behrendt DM, Bell EF, Smith RJ. Incidence of vocal fold paralysis in infants undergoing ligation of patent ductus arteriosis. *Ann Thorac Surg*. 1996; 61: 814-816. doi: 10.1016/0003-4975(95)01152-8

6. Averin K, Uzark K, Beekman RH 3rd, Willging JP, Pratt J, Manning PB. Manning, Postoperative assessment of laryngopharyngeal dysfunction in neonates after Norwood operation. *Ann Thoracic Surg*. 2012; 94: 1257-1261. doi: 10.1016/j.athoracsur.2012.01.009

7. Carpes LF, Kozak FK, Leblanc JG, et al. Assessment of vocal fold mobility before and after cardiothoracic surgery in children. *Arch Otolaryngol Head Neck Surg*. 2011; 137: 571-575. doi: 10.1001/archoto.2011.84

8. Wilson MN, Bergeron LM, Kakade A, et al. Airway management following pediatric cardiothoracic surgery. *Otolaryngol Head Neck Surg*. 2013; 149(4): 621-627. doi: 10.1177/0194599813498069

9. Truong MT, Messner AH, Kerschner JE, et al. Pediatric vocal fold paralysis after cardiac surgery: Rate of recovery and sequelae. *Otolaryngol Head Neck Surg*. 2007; 137: 780-784. doi: 10.1016/j.otohns.2007.07.028

10. Jabbour J, Martin T, Beste D, Robey T. Pediatric vocal fold immobility: Natural history and the need for long-term follow-up. *JAMA Otolaryngol Head Neck Surg*. 2014; 140: 428-433. doi: 10.1001/jamaoto.2014.81

11. Skinner ML, Halstead LA, Rubinstein CS, Atz AM, Andrews D, Bradley SM. Laryngopharyngeal dysfunction after the Norwood procedure. *J Thorac Cardiovasc Surg*. 2005; 130: 1293-1301. doi: 10.1016/j.jtcvs.2005.07.013

12. Wernovsky G, Kuijpers M, Van Rossem MC, et al. Postoperative course in the cardiac intensive care unit following the first stage of Norwood reconstruction. *Cardiol Young*. 2007; 17: 652-665. doi: 10.1017/S1047951107001461

13. Pereira KD, Webb BD, Blakely ML, Cox CS Jr, Lally KP. Sequelae of recurrent laryngeal nerve injury after patent ductus arteriosis ligation. *Int J Pediatr Otorhinolaryngol*. 2006; 70: 1609-1612. doi: 10.1016/j.ijporl.2006.05.001

ISSN 2470-4059

OTOLARYNGOLOGY

Open Journal

Openventio PUBLISHERS

Case Report

A Case of Pleomorphic Adenoma Metastasising to Contralateral Supraclavicular Lymph Node

Esmail Abdulahi Ahmed, MD[1*]; Kamil Akdag, MD[1]; Onur Üstün, MD[1]; Ayça Başkadem Yılmazer, MD[1]; Pınar Özay Nayır, MD[2]; Zeynep Aydodu, MD[1]; Yavuz Uyar, MD[1]

[1]*Department of Otorhinolaryngology-Head and Neck Surgery, Okmeydani Training and Research Hospital, Istanbul, Turkey*
[2]*Department of Pathology, Okmeydani Training and Research Hospital, Istanbul, Turkey*

***Corresponding author**
Esmail Abdulahi Ahmed, MD
Department of Otorhinolaryngology-Head and Neck Surgery, Okmeydani Training and Research Hospital, Darulaceze Cad. No:25 Okmeydani-Sisli, Istanbul, Turkey; Tel. 0090 507 711 32 91; E-mail: ismodho@gmail.com

Article information
Received: February 18th, 2019; **Revised:** July 23rd, 2019; **Accepted:** July 24th, 2019; **Published:** August 3rd, 2019

Cite this article
Ahmed EA, Akdag K, Üstün O, et al. A case of pleomorphic adenoma metastasising to contralateral supraclavicular lymph node. *Otolaryngol Open J*. 2019; 5(2): 34-38. doi: 10.17140/OTLOJ-5-158

ABSTRACT

Introduction
Pleomorphic adenomas are the most common benign parotid tumours in all populations. Management always consists of a curative superficial parotidectomy. However, rare cases described, in which these histological benign tumors metastasize to distant sites. We present an example of a recurrent parotid pleomorphic adenoma with a contralateral supraclavicular lymph node metastasis after several surgical interventions.

Case report
In this case, we reported reported a case of 29-years male with extensive metastasis in submandibular, submental and also very rarely seen contralateral supraclavicular lymph node metastasis. Parotidectomy with preservation of facial nerve and radiotherapy was given to the patient since the lesions were very aggressive.

Conclusion
The patient had several surgical interventions, so it is essential to do meticulous resection in the first surgery to prevent local recurrence and distant metastasis.

Keywords
Pleomorphic adenoma; Metastasizing pleomorphic adenoma; Salivary gland benign neoplasia.

INTRODUCTION

Pleomorphic adenoma is a benign tumour that has elements of both epithelial and mesenchymal tissues. Pleomorphic adenoma is a tumour of variable capsulation characterized microscopically by architectural rather than cellular pleomorphism, most commonly with a tissue of mucoid, myxoid or chondroid appearance which consists of the salivary glands.

It consists of approximately 3% of all head and neck tumours and about 70-80% of these neoplasms occur in the major salivary glands.[1] The tumour most commonly found in the parotid or submandibular glands. Incidence of pleomorphic adenoma varies from 2 to 3.5% with a female preponderance, 3rd and 6th decades are peak ages for pleomorphic adenoma. Neck irradiation is a very strong predisposing factor while the link between the development of pleomorphic adenoma and a simian virus is not clear yet.[2]

Although pleomorphic adenoma is a benign tumour sometimes it shows recurrence and also transformation to malign tumour with an incidence of 2 to 7%.[2] This makes pleomorphic adenoms challenging to manage compared to other salivary gland tumours. On the other hand, pleomorphic adenoma shows malignant behavior with benign histology. This is a very rare entity and its incidence is not clear. There are no studies done on this form of pleomorphic except case reports.[3]

Otolaryngol Open J. 2019;5(2):34-38. doi: 10.17140/OTLOJ-5-158

In this article, we present a very unique case of metastasizing pleomorphic adenoma having contralateral supraclavicular non symptomatic metastatic lesions. This will be first case in the literature with contralateral supraclavicular metastasis.

CASE REPORT

A 29-years-old male patient with complaints of a mass in left submandibular gland was referred to our hospital. The patient was not having any other significant complaints.

Clinical examination exhibited a relatively mobile, soft mass located in the left submandibular and submental neck region. Magnetic resonance imaging (MRI) revealed extensive left submandibular and submental subcutaneous mobile conglomerate lesions but what was unique for this case was a single lesion on the right supraclavicular region similar to the main lesion found incidentally on MRI (Figures 1A and 1B).

Figure 1A. *Coronal Section of MRI also Showing Single Contralateral Supraclavicular Metastasiss*

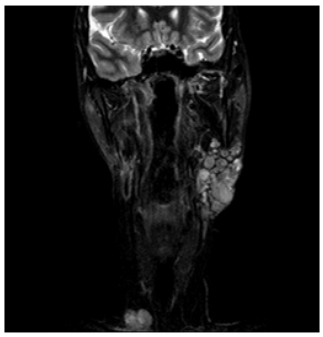

Figure 1B. *Sagittal Section of MRI Showing Extensive Submental and Submandibular Metastasis*

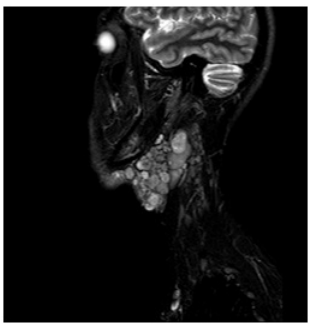

The patient was operated in another hospital in 2003 and his first pathologic report after the surgery showed pleomorphic adenoma, unfortunately, surgical margins were very near to a tumour. After an extended period of irregular follow-up in 2013, the patient came up with painless swelling on the left neck just next to the scar of the previous incision. Fine needle aspiration resulted showed a pleomorphic adenoma and local excision was performed. The patient discontinued the follow-up until 2017. He applied to our clinic with extensive submental and submandibular round and soft subcutaneous masses (Figures 2A and 2B). All other otorhinolaryngology examination and systematic examination was regular.

Figure 2A. *Submandibular and Submental Subcutaniouse Nodules and Previouse Insicion Scar*

Figure 2B. *Single Supraclavicular Lesion*

Originally tumour was in the submandibular gland but in the last recurrence, the tumour was extending to the inferior part of the parotid gland. The patient underwent total parotidectomy with facial nerve preservation and ipsilateral neck dissection.

Pathologic examination revealed a timorous lesion in a transparent, nodular structure with a white color in different sizes, holding the entire cross-sectional surface in sections of the left parotid and neck dissection with a size of 15.5×5.5×3.5 cm with an ellipsoid skin of 7.5×1.3 cm in size, macroscopically.

On the other hand, there were some white-colored pieces in the right supraclavicular region with 3×3×1 cm size, transparent material with nodular structure and some fat tissue.

Microscopic examination of the left parotid and neck dissection showed that the chondromyxoid stroma composed of fibroblasts and epithelioid types of cells in some areas of the abortive ducts. Also in some areas, there were a more solid cellular atyp-

Otolaryngol Open J. 2019;5(2):34-38. doi: 10.17140/OTLOJ-5-158

ia and no mitotic tumour proliferation. In the histopathological examination of the material from the right supraclavicular region, there was nodular tumour proliferation with similar microscopic features observed in the fatty tissue of the expansive parent material (Figures 3A, 3B and 3C).

Figure 3A. *Pleomorphic Adenoma Nodules Under the Skin (HEx40)*

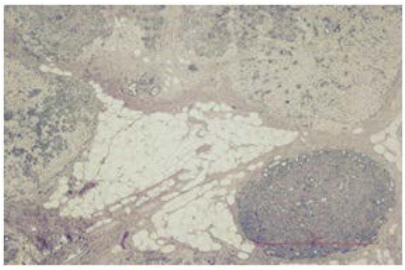

Figure 3B. *Pleomorphic Adenomatous Nodules in Fatty Tissue (HEx40)*

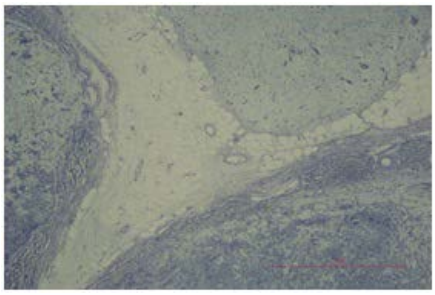

Figure 3C. *Pleomorphic Adenomal Nodules Some with Lymphoid Rim Inside Adpose Tissue of Right Supraclavicular Region (HEx40)*

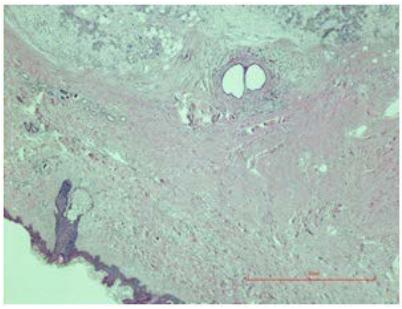

In the immunohistochemical study performed, GFAP focal positivity, BCL2 focal positivity and S100 positivity were found. Ki 67 proliferation index was 1%. Histopathologically, there was no evidence of malignancy in both materials, and the findings were consistent with benign pleomorphic adenoma.

DISCUSSION

Pleomorphic adenoma is a benign tumour that has elements of both epithelial and mesenchymal tissues. Pleomorphic adenomas tend to transform to malignancy. Also in very rare cases, pleomorphic adenomas show clinically malignant behaviour while histologically remaining benign. This kind of tumours is called metastasizing pleomorphic adenomas (MPA).[1,4]

World Health Organization (WHO) classifies neoplasms that show malignant transformation as malignant epithelial tumours.[1] However, controversy still exists on rare occasions in which metastasis occurs without malignant transformation. Previously it was considered as benign neoplasia; however, the WHO new classification on head and neck tumours found as a malignant.[1] The high mortality rate of around 50% makes them considered as malignant tumours.

The exact incidence of metastising pleomorphic adenomas is not known. However, many cases of metastasizing pleomorphic adenoma have been reported since the early 1940s. McGarry et al[5] analysed 52 cases, while Knight et al[6] performed a systemic review of case reports from 1942 to 2014 and found 80 cases. LiVolsi and Perzin reviewed 47 cases of metastasizing pleomorphic adenoma.[7] Sites of metastasis were bone 36.6%, lung 33.8 and cervical lymph nodes 20.1%.[6]

There are several hypotheses about the mechanism of metastasis of pleomorphic adenomas: which are incomplete enucleation, direct seeding, hematogenic and lymphatic routes. Nourai et al[8] reported a series of 42 cases with (MPA), that incomplete excision of the primary pleomorphic adenoma was the most influential factor associated with local recurrence and distant metastasis. In this case, two previous surgical interventions were performed, and the surgical margins of the first surgery were very close to the tumour. Having previous operations supports the hypothesis that inadequate surgical excision is the primary cause of recurrence in this case. But single contra-lateral supraclavicular metastasis shows that incomplete surgery is not the only reason for metastasis.

Chen et al[9] reported 20 of 24 tumours metastases hematogenously, whereas 4 of 24 spread *via* the lymphatic route, while Wenig et al[10] also reported that 8 of 11 tumours metastasizing hematogenously and the remaining three spreading *via* lymphatic channels to nearby cervical and submandibular lymph nodes. Knight et al[6] found in their review of 80 cases of metastatic pleomorphic adenoma that 20% of the cases had lymphatic metastasis.

In this case, local metastasis was very extensive, extending to the inferior pole of the left parotid gland. On the other hand, contralateral neck (supraclavicular) lymph node metastasis, which is very far from the original is good evidence for the hypothesis of hematogenic and lymphatic routes of metastasis.

This case is the second case with metastasis to the contralateral neck. Miladi et al reported a case of a left submandibular gland pleomorphic adenoma with multiple asymptomatic lymph nodes on both sides of the neck.[11] All reported cases had ipsilateral lymph node metastasis, metastases to the contra-lateral supraclavicular region and latency period between recurrence and metastasis gives strong evidence to consider metastasizing pleomorphic ade-

noma as a low-grade malign tumour. Although multiple metastases considered as a poor prognostic factor,[6,12] the relationship between the type of metastasis and aggressivity of the tumours is not clear, and there is no study done on this.

Histological the primary tumour and recurrent pleomorphic adenoma and metastasizing pleomorphic adenoma have no significant difference between them. All are composed of a mixture of benign-appearing epithelial and mesenchymal components of a pleomorphic adenoma. However, histology is not a predictive factor for its ability to metastasis. Also, currently, there is no way to predict which tumour have a risk of metastasis. Only Knight et al found that younger age presentation of pleomorphic adenoma could be a risk factor for developing of metastasizing pleomorphic adenoma.[6]

The exact mechanism of the metastatic behaviour of pleomorphic adenoma is still unknown. Hypercellularity, hyalinization, cellular neoplasia and mitosis are characteristic features of the malignant transformation of pleomorphic adenoma to carcinoma ex-pleomorphic adenoma, but these features are not encountered in metastasizing pleomorphic adenoma.[13]

Hoorweg et al[14] stated that the expression of apoptosis-related proteins and markers of cell proliferation activity like (p 53, Bcl-2, MIB1, CD 105, p27, p21) no significant difference was found between metastasizing pleomorphic adenoma and benign pleomorphic adenoma.

Flow cytometric analysis still is not predictive for which kind of pleomorphic adenoma having the risk of metastasis. Mariano et al found that rearrangements of 3 p and 9 p have a relationship with metastatic pleomorphic adenoma and reported that deletions of 3 p are frequently found in a large variety of malignant epithelial neoplasm.[15] Deletion of one or more tumour suppressor genes may be significant in the metastatic progression period of some pleomorphic adenomas.[16] Some authors reported that metastasizing pleomorphic adenoma is an intermediate link benign pleomorphic adenoma and malign pleomorphic adenoma.

Weissferdt et al[17] published a case of a carcinoma ex pleomorphic adenoma with lung metastases composed exclusively of benign elements, showing histological evidence for the link between metastatic pleomorphic adenoma and carcinoma ex-pleomorphic adenoma. Although there is no clear genetic evidence for metastasizing pleomorphic adenoma, the accumulation of key genetic alterations is the most rational explanation up to now.

Recently some authors suggested investigation with positron emission tomography (PET) for local recurrence to detect metastasis because most of the reported cases have more than one recurrence before metastasis detected.[6] In this case, we scanned with positron emission tomography-computed tomography (PET-CT) for metastasis, and there were no other sites of metastasis.

The most preferred treatment option is surgery, and total parotidectomy is performed with conserving the facial nerve to achieve control and tumour-free survival. Nourai et al supported parotidectomy with preservation of facial nerve rather than inoculation.[8] Witt et al reported in their study by comparing total parotidectomy, superficial parotidectomy, and extracapsular dissection techniques, that only capsular rupture is a very important factor which resulted in a significantly higher rate of recurrence and did not vary among surgical approaches.[2]

Radiotherapy not routinely indicated for all patients; still, there is no clear evidence for the role of radiation and chemotherapy in the treatment and prevention of metastasis. But in Liu et al[18] reported in a retrospective study of 128 patients, 55 patients received radiotherapy, and the primary reason for radiation was recurrence after surgery. They also presented that they achieved local control in 13 of 16 patients (82%) at ten years with a median dose of 45 Gy. While local control with surgery alone achieved in 1 out of 17 patients. Chen et al[19] and Wallace et al[20] reported local control of 94% and 75% respectively, with combined surgery and radiotherapy. In this case with a multi-disciplined approach, the patient had radiotherapy and no recurrence seen until in our regular follow-ups.

CONCLUSION

As reported in the literature, the first surgery is critical, especially in young female patients. its strongly recommended to do apparent surgery and avoid capsular rupture. So it's also essential to investigate for metastasis and treat them as a low-grade malignant tumour.

CONSENT

The authors have received written informed consent from the patient.

CONFLICTS OF INTEREST

The authors declare that they have no conflicts of interest.

REFERENCES

1. Barnes DSL, Eveson JW, Reichart P. World Health Originization (WHO) classification of Tumours. *Pathol Genet Head Neck Tumours*. 2005; 209-281. Web site. https://whobluebooks.iarc.fr/. Accessed February 16, 2019.

2. Witt RL, Eisele DW, Morton RP, Nicolai P, Poorten VV, Zbären P. Etiology and management of recurrent parotid pleomorphic adenoma. *Laryngoscope*. 2015; 125(4): 888-893. doi: 10.1002/lary.24964

3. Malard O, Wagner R, Joubert M, et al. Prognostic factors for secondary recurrence of pleomorphic adenoma: A 20-year, retrospective study. *J Laryngol Otol*. 2013; 127(9): 902-907. doi: 10.1017/S0022215113001801

4. Young VS, Viktil E, Loberg EM, Enden T. Benign metastasizing pleomorphic adenoma in liver mimicking synchronic meta-

static disease from colorectal cancer: A case report with emphasis on imaging findings. *Acta Radiol Open*. 2015; 4(8): 1-5. doi: 10.1177/2058460115594199

5. McGarry JG, Redmond M, Tuffy JB, Wilson L, Looby S. Metastatic pleomorphic adenoma to the supraspinatus muscle: A case report and review of a rare aggressive clinical entity. *J Radiol Case Rep*. 2015; 9(10): 1-8. doi: 10.3941/jrcr.v9i10.2283

6. Knight J, Ratnasingham K. Metastasising pleomorphic adenoma: Systematic review. *Int. J. Surg*. 2015; 19: 137-145. doi: 10.1016/j.ijsu.2015.04.084

7. LiVolsi VA, Perzin KH. Malignant mixed tumors arising in salivary glands. I. Carcinomas arising in benign mixed tumors: A clinicopathologic study. *Cancer*. 1977; 39(5): 2209-2230. doi: 10.1002/1097-0142(197705)39:5<2209::aid-cncr2820390540>3.0.co;2-8

8. Nouraei SA, Ferguson MS, Clarke PM, et al., Metastasizing pleomorphic salivary adenoma. *Arch Otolaryngol Head Neck Surg*. 2006; 132(7): 788-793. doi: 10.1001/archotol.132.7.788

9. Myers EN, Chen Ih, Tu Hy. Pleomorphic adenoma of the parotid gland metastasizing to the cervical lymph node. *Otolaryngol Head Neck Surg*. 2000; 122(3): 455-457. doi: 10.1067/mhn.2000.98360

10. Wenig BM, Hitchcock CL, Ellis GL, Gnepp DR. Metastasizing mixed tumor of salivary glands. A clinicopathologic and flow cytometric analysis. *Am J Surg Pathol*.1992; 16(9): 845-858.

11. Marchetti A, Padova RA, Vercelli AG, et al. Pathologica. 2010; 102(3): 119-126.

12. Steele NP, Wenig BM, Sessions RB. A case of pleomorphic adenoma of the parotid gland metastasizing to a mediastinal lymph node. *Am J Otolaryngol*. 2007; 28(2): 130-133. doi: 10.1016/j.amjoto.2006.07.002

13. El-Naggar A, Batsakis JG, Kessler S. Benign metastatic mixed tumours or unrecognized salivary carcinomas? *J Laryngol Otol*. 1988; 102(9): 810-812. doi: 10.1017/S0022215100106528

14. Hoorweg JJ, Hilgers FJ, Keus RB, Zoetmulder FA, Loftus BM. Metastasizing pleomorphic adenoma: a report of three cases. *Eur J Surg Oncol*. 1998; 24(5): 452-455. doi: 10.1016/S0748-7983(98)92651-8

15. Mariano FV, Gondak Rde O, Martins AS, et al., Genomic copy number alterations of primary and secondary metastasizing pleomorphic adenomas. *Histopathology*. 2015; 67(3): 410-415. doi: 10.1111/his.12655

16. Bradley PJ. Metastasizing pleomorphic salivary adenoma' should now be considered a low-grade malignancy with a lethal potential. *Curr Opin Otolaryngol Head Neck Surg*. 2005; 13(2): 123-126. doi: 10.1097/01.moo.0000153450.87288.2a

17. Weissferdt A, Langman G. An intracapsular carcinoma ex pleomorphic adenoma with lung metastases composed exclusively of benign elements: Histological evidence of a continuum between metastasizing pleomorphic adenoma and carcinoma ex pleomorphic adenoma. *Pathol Res Pract*. 2010; 206(7): 480-483. doi: 10.1016/j.prp.2009.07.008

18. Liu FF, Rotstein L, Davison AJ, et al. Benign parotid adenomas: A review of the princess margaret hospital experience. *Head Neck*.1995; 17(3): 177-183. doi: 10.1002/hed.2880170302

19. Chen AM, Garcia J, Bucci MK, Quivey JM, Eisele DW. Recurrent pleomorphic adenoma of the parotid gland: Long-term outcome of patients treated with radiation therapy. *Int J Radiat Oncol Biol Phys*. 2006; 66(4): 1031-1035. doi: 10.1016/j.ijrobp.2006.06.036

20. Wallace AS, Morris CG, Kirwan JM, Werning JW, Mendenhall WM. Radiotherapy for pleomorphic adenoma. *Am J Otolaryngol*. 2013; 34(1): 36-40. doi: 10.1016/j.amjoto.2012.08.002