Openventio PUBLISHERS

ISSN 2470-4059

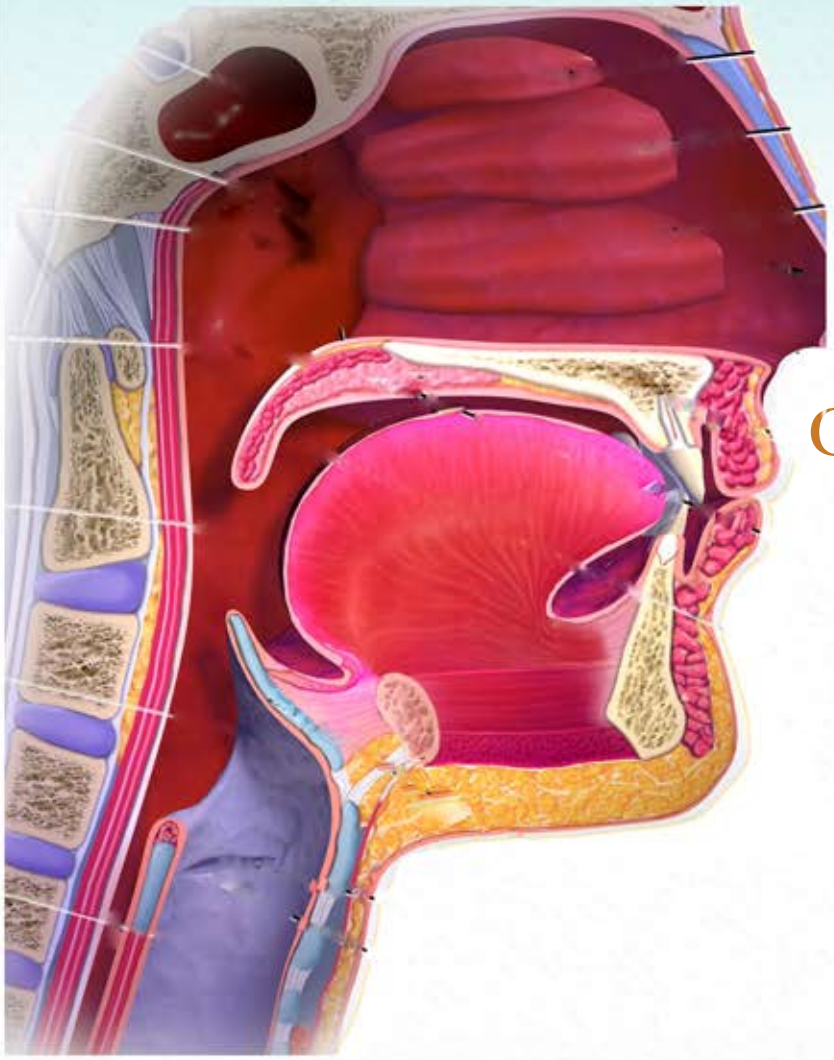

OTOLARYNGOLOGY

Open Journal

| April 2019 | Volume 5 | Issue 1 |

www.openventio.org

ISSN 2470-4059

OTOLARYNGOLOGY
Open Journal

Openventio
PUBLISHERS

CONTENTS

ISSN 2470-4059

OTOLARYNGOLOGY

Open Journal

Openventio PUBLISHERS

Mini Review

Nonmedical Treatment (Voice Therapy) for Vocal Nodules in Children

Neha Taneja, MASLP*

Ex Assistant Professor-2 (Senior Faculty), Department of Audiology and Speech-Language Pathology, Amity Medical School, Amity Univeristy, Haryana, India

***Corresponding author**
Neha Taneja, MASLP
Consultant Speech Language Pathologist and Audiologist
Kanpur, Uttar Pradesh 208012, India; Tel. 8860709530; E-mail: neha.aslp04@gmail.com

Article information

Received: November 15th, 2018; **Revised:** December 20th, 2018; **Accepted:** December 27th, 2018; **Published:** January 4th, 2019

Cite this article

Taneja N. Nonmedical treatment (voice therapy) for vocal nodules in children. *Otolaryngol Open J*. 2019; 5(1): 1-4. doi: 10.17140/OTLOJ-5-150

ABSTRACT

Introduction

Voice disorders due to vocal nodules have been a major cause of voice problems in school-aged children. Several behaviors such as excessive speaking, shouting too loudly, yelling may contribute to voice disorders due to vocal nodules, vocal polyps, vocal cysts, etc. Hoarseness due to vocal nodules may have an impact on their overall communication, social and educational development. Many treatment approaches exist which attempt to treat vocal nodules and hoarseness related to it such as surgery (medical treatment), voice therapy (nonmedical), vocal hygiene, etc. Even after the surgical treatment voice therapy plays a crucial role for further prevention and care for reoccurring of vocal nodules. Voice therapy holds a significant role in the treatment of vocal nodules.

Aim

This mini-review attempts to summarize studies on the efficacy of voice therapy for vocal nodules especially in school-aged children.

Method

A literature search was conducted using an electronic database such as PubMed, Google Scholar, and Google for the keywords "voice therapy" in "school aged children". The results from the literature studies were summarized in a narrative manner.

Results

Existing findings from the literature review and the present review support the efficacy of voice therapy as a treatment option for vocal nodules. Various databases searched for the references related to the headings such as efficacy of voice therapy for vocal nodules in school children which were included in this mini-review were published from 1976 to 2018.

Conclusion

Treatment of voice disorders in children is one of the most challenging and difficult concerns for professionals. Voice disorders affect the overall development of the child in terms of oral communication and educational participation. Though many treatment modalities have been adapted for treating adult voice disorders but their efficacy in children is still a debatable concern. No one fixed voice therapy technique that can be generalized for all children and its time period/sessions. Several key factors play an important role in case of children learning these techniques such as child learning behaviors, environment, and parental participation, etc. But among all other treatments nonmedical (voice therapy) approach has been found to be helpful for vocal nodules in school-aged children. For effective voice management in school-aged children with hoarseness due to vocal nodules, the holistic approach may be up taken involving school teachers, parents, active participation of child and clinician to prevent such voice problems.

Keywords

School age children; Vocal nodules; Voice disorders; Hoarseness; Voice therapy.

Otolaryngol Open J. 2019; 5(1): 1-4. doi: 10.17140/OTLOJ-5-150

INTRODUCTION

Children as compared to adults are difficult to examine for the varied problems. Voice problems form a challenging area of treatment for children.[1] Among the many causes of voice disorders in children vocal nodules are commonly reported in children and may result in hoarseness.[2] Children are prone to voice problems due to misuse or abuse of their voice. Several behaviors such as excessive speaking, shouting too loudly, yelling,[2] etc. may contribute to voice disorders due to vocal nodules, vocal polyps, vocal cysts etc., and may attribute to communication difficulties.

The process of normal voice production happens in larynx or voice box.[3] The voice box is situated at the level near the level of Adam's Apple in the neck. The vocal folds also commonly referred as vocal cords are located in the larynx as two small muscles. During speech production, these vocal cords together come together and use the air from the lungs for their vibration.[3] The sound is thus produced from the vibration of these vocal cords and further, the movements of lips and tongue create individual speech sounds. During normal speech production vocal folds come closer and press firmly together.[3] Due to the occurrence of nodules on these cords they cannot close completely. Hence the extra air escapes and voice becomes breathy and hoarse. Vocal nodules are defined as the bilateral (symmetry not necessary) membranous folds thickening with normal to minimal impairment of vibratory properties of the mucosa.[4] The reported prevalence ratio of vocal nodules has been found as 21.6% in males and 11.7% in females school going children.[2] Vocal nodules can be caused due to several causative sources such as its abuse, misuse of voice, etc. Some of the vocal misuse causes can be the excessive rate of speech, insufficient breath support or use of incorrect pitch, loudness, and quality. Voice abuse which is the most prominent cause of vocal nodules in children may include excessive talking, excessive coughing, screaming, cheering or crying loudly, excessive throat clearing and abrupt hard vocal attacks.[5] In addition, several other factors may contribute as factors for vocal nodules such as smoking, air pollution, infections of upper respiratory tracts. Vocal abuse and misuse results in the excessive closing of vocal cords which result in the formation of vocal nodules at the point of maximum contact. The early signs of formation of vocal nodules can be marked as slight reddening on the margin of the cord followed by thickening on the edge of cord. This may finally lead to the formation of the bump on upper one-third of the vocal cords at the place of maximum vibration.[6,7] There may be no pain during the initial development of vocal nodule process. Vocal nodules can be initially identified by their notable symptom of breathy and hoarse quality of voice. Several treatments have been advocated for vocal nodules in children. Among such are vocal hygiene, voice therapy, and surgery.[8] Voice therapy has been in use for vocal nodules in children[9] regardless of whether nodules are surgically removed. There is a lack of studies in pediatric voice therapy. At present, the debate is still ongoing among the professionals on which treatment modality should be used for treating vocal nodules in children, i.e., voice therapy alone, or combination of voice therapy or surgery or no treatment. This mini-review attempts to summarize the literature findings for the effectiveness of voice therapy for treating vocal nodules in school-aged children. Treating hoarseness due to vocal nodules in children is a very challenging and of growing interest as it may have a severe impact on the overall educational development of children including their communication skills and self-esteem.

LITERATURE REVIEW

There is a dearth of literature supporting the effectiveness of a particular type of treatment to correct hoarseness in children due to vocal fold nodules. Limited evidence exists to confirm which treatment options such as voice therapy alone or in a combination of surgery or no treatment needs to be applied for pediatrics with voice disorders. However, there are literature studies which have found voice therapy to be useful in treating vocal nodules in school children.

In a study by Deal et al[9] the effectiveness of voice therapy for treating vocal fold nodules was reported. The study comprised patients in the age range of 5 to 13 years. Voice therapy of 30 min for 2-3 times per week showed a significant improvement. Eight hundred forty five had a reduction in nodules size and 65% had normal larynges. Tezcaner et al[10] in their prospective study analyzed the efficiency of the voice therapy in patients with vocal fold nodules. The subjects 39 in total aged between 7 years to 14 years. Post voice therapy treatment showed improvements in acoustic analysis parameters such as shimmer, jitter, and noise to harmonic ratio.[10] In another study by Mori[8] on 169 patients age range between 2-18 years with vocal fold nodules. Out of total 122 who underwent voice therapy and rest for vocal hygiene program. Among them who underwent at least seven sessions of voice therapy were found to have 69% improvement. Similarly, the effectiveness of voice therapy for vocal fold nodules was reported in study by Şenkal ÖA et al[11] on 99 out patients aged 7-15 years with hoarseness as the main complaint for 2 months. The subjective assessment was carried using scales such as GRBAS (Grade, Roughness, Breathiness, Asthenicity, Strain) S/Z ratio and MPT (Maximum Phonation Time). Data was collected for three different types of voice therapy techniques such as physiological, hygienic and symptomatic. Symptomatic voice therapy was reported to be better among all through subjective assessments carried post voice therapy for vocal nodules in school children. In another retrospective study by Şenkal ÖA et al[12] on 75 children aged 7-14 years voice therapy was reported as an effective treatment method for hoarseness in school children. Niedzielskaet et al[13] in their study on children aged 4 to 14 years found improved acoustic parameters-jitter, shimmer, and NHR and flattened nodules post voice therapy. Similar findings were found by Trani et al[14] on 6 to 11 aged children in terms of improved acoustic parameters-jitter, shimmer, fundamental frequency and NHR post voice therapy for vocal nodules treatment. Ramig and Verdolini et al[15] reported the literature findings are suggestive of the efficacy of vocal hygiene and direct voice therapy in the improvement of voice quality in children. Lee and Son[16] also found voice therapy efficacy in terms of improvements in the perceptual analysis (GRBAS), and acoustic parameters such as pitch, and jitter, shimmer and noise-to-harmonic ratio in children with hyper functional voice disorders (mostly nodules).

Literature review findings have been suggestive of the efficacy of voice therapy treatment in school children with vocal nodules. But the major challenge in reviewing the above findings is that the type of voice therapy, number of sessions required has not been clearly defined. Most of the results are based on perceptual measures or retrospective cohort studies. There is a lack of a control group against which it can be the efficacy of such a treatment approach can be generalized.

RESULTS

Existing findings from the literature review and the present review support the efficacy of voice therapy as a treatment option for vocal nodules. Various databases searched for the references related to the headings such as efficacy of voice therapy for vocal nodules in school children which were included in this mini-review were published from 1976 to 2018.

DISCUSSION AND CONCLUSION

Treatment of voice disorders in children is one of the most challenging and difficult concerns for professionals. Voice disorders affect the overall development of the child in terms of oral communication and educational participation. Though many treatment modalities have been adapted for treating adult voice disorders but their efficacy in children is still a debatable concern.[17-20] No one fixed voice therapy technique that can be generalized for all children and its time period/sessions. Though few voice therapy techniques such as manual laryngeal tension reduction or accent method, yawn sigh, vocal intensity reduction, vocal function exercises, resonant voice therapy techniques have been commonly reported to be useful for treating vocal nodules in children.[20] The combination of these is considered as the best protocol for children.[8-10] Many variables play a crucial role in the effectiveness of voice therapy for school children such as parental involvement, clinicians experience and acquisition of therapy principles by the child themselves on a daily basis. The environment of the child plays a very dominant role in providing the appropriate vocal model including home environment. For effective voice management in such children with a complaint of hoarseness due to vocal nodules, the holistic approach may be uptaken involving school teachers, parents, active participation of child and clinician to prevent such voice problems. Follow-up measures is equally important after voice therapy sessions so that it does not reoccur in proper adjunct with vocal hygiene program. Furthermore, studies are warranted with the control group, larger sample size, different population and application of different types of voice therapy techniques with defined time period/sessions on these school-aged children to confirm about voice therapy efficacy in the management of hoarseness due to vocal nodules.

REFERENCES

1. Theis SM. Pediatric voice disorders: Evaluation and treatment. *ASHA Leader*. 2010; 15(14):12-15. doi: 10.1044/leader.FTR1.15142010.12

2. Mansuri B, Tohidast SA, Soltaninejad N, Kamali M, Ghelichi L, Azimi H. Nonmedical treatments of vocal fold nodules: A systematic review. *J Voice*. 2018; 32(5): 609-620. doi: 10.1016/j.jvoice.2017.08.023

3. Sataloff RT. The human voice. *Sci Am*. 1992; 267(6): 108-115.

4. Rosen CA, Gartner-Schmidt J, Hathaway B, et al. A nomenclature paradigm for benign midmembranous vocal fold lesions. *Laryngoscope*. 2012; 122(6): 1335-1341. doi: 10.1002/lary.22421

5. Baker BM, Blackwell PB. Identification and remediation of pediatric fluency and voice disorders. *J Pediatr Health Care*. 2004; 18(2): 87-94. doi: 10.1016/j.pedhc.2003.09.008

6. Titze IR. Mechanical stress in phonation. *J Voice*. 1994; 8(2): 99-105. doi: 10.1016/S0892-1997(05)80302-9

7. Johns MM. Update on the etiology, diagnosis, and treatment of vocal fold nodules, polyps, and cysts. *Curr Opin Otolaryngol Head Neck Surg*. 2003; 11(6): 456-461. doi: 10.1097/00020840-200312000-00009

8. Mori K. Vocal fold nodules in children: Preferable therapy. *Int J Pediatr Otorhinolaryngol*. 1999; 49(suppl 1): S303-306. doi: 10.1016/S0165-5876(99)00181-0

9. Deal RE, McClain B, Sudderth JF. Identification, evaluation, therapy, and follow-up for children with vocal nodules in a public school setting. *J Speech Hear Disord*. 1976; 41(3): 390-397. doi: 10.1044/jshd.4103.390

10. Tezcaner CZ, Karatayli Ozgursoy S, Sati I, Dursun G. Changes after voice therapy in objective and subjective voice measurements of pediatric patients with vocal nodules. *Eur Arch Otorhinolaryngol*. 2009; 266(12): 1923-1927. doi: 10.1007/s00405-009-1008-6

11. Şenkal ÖA, Çiyiltepe M. Effects of voice therapy in school-age children. *J Voice*. 2013; 27(6): 787.e19-25. doi: 10.1016/j.jvoice.2013.06.007

12. Şenkal ÖA, Özer C. Hoarseness in school-aged children and effectiveness of voice therapy in international classification of functioning framework. *J Voice*. 2015; 29(5): 618-623. doi: 10.1016/j.jvoice.2014.10.018

13. Niedzielska G, Glijer E, Niedzielski A. Acoustic analysis of voice in children with nodulivocales. *Int J Pediatr Otorhinolaryngol*. 2001; 60(2): 119-122. doi: 10.1016/S0165-5876(01)00506-7

14. Trani M, Ghidini A, Bergamini G, Presutti L. Voice therapy in pediatric functional dysphonia: A prospective study. *Int J Pediatr Otorhinolaryngol*. 2007; 71(3): 379-384. doi: 10.1016/j.ijporl.2006.11.002

15. Ramig LO, Verdolini K. Treatment efficacy: Voice disorders. *J Speech Lang Hear Res*. 1998; 41(1): S101-S116. doi: 10.1044/

jslhr.4101.s101

16. Lee EK, Son YI. Muscle tension dysphonia in children: Voice characteristics and outcome of voice therapy. *Int J Pediatr Otorhinolaryngol*. 2005; 69(7): 911-917. doi: 10.1016/j.ijporl.2005.01.030

17. Moran MJ, Pentz AL. Otolaryngologists' opinions of voice therapy for vocal nodules in children. *Lang Speech Hear Serv Sch*. 1987; 18(2): 172-178. doi: 10.1044/0161-1461.1802.172

18. Hooper CR. Treatment of voice disorders in children. *Lang Speech Hear Serv Sch*. 2004; 35(4): 320-326. doi: 10.1044/0161-1461(2004/031)

19. Cook JV, Palaski DJ, Hanson WR. A vocal hygiene program for school-age children. *Lang Speech Hear Serv Sch*. 1979; 10(1): 21-26. doi: 10.1044/0161-1461.1001.21

20. Ongkasuwan J, Friedman EM. Is voice therapy effective in the management of vocal fold nodules in children? *Laryngoscope*. 2013; 123(12): 2930-2931. doi: 10.1002/lary.23830

ISSN 2470-4059

OTOLARYNGOLOGY

Open Journal

Openventio PUBLISHERS

Case Series

Surgical Treatment of Laryngeal Haemangioma Laser CO_2 Excision: Our Experience in Adult Patients

Maria Cristina Cristi, MD[2]; Valeria Gambacorta, MD[1]; Arianna Di Stadio, MD, PhD[1*]; Simona Pindozzi, MD[3]; Luigi Tassi, MD[3]; Giampietro Ricci, MD[1,2]

[1]*Department of Surgery and Biomedical Science Section of Otorhinolaryngology, University of Perugia, Perugia, Italy*
[2]*Santa Maria della Misericordia Hospital, Department of Otorhinolaryngology, Head and Neck Surgery, Perugia, Italy*
[3]*Specialist in Otolaryngology, Surgical Department of Otorhinolaryngology, San Giovanni Battista Hospital, Foligno, Italy*

***Corresponding author**
Arianna Di Stadio, MD, PhD
Department of Surgery and Biomedical Science Section of Otorhinolaryngology, University of Perugia, Perugia 06132, Italy; E-mail: ariannadistadio@hotmail.com

Article information
Received: November 29th, 2018; **Revised:** December 12th, 2018; **Accepted:** December 16th, 2018; **Published:** January 7th, 2019

Cite this article
Cristi MC, Gambacorta V, Di Stadio A, Pindozzi S, Tassi L, Ricci G. Surgical treatment of laryngeal haemangioma laser co_2 excision: Our experience in adult patients. *Otolaryngol Open J*. 2019; 5(1): 5-7. doi: 10.17140/OTLOJ-5-151

ABSTRACT

Introduction
Haemangioma is a benign vascular tumor, of endothelial origin, that affects the head and neck region in 60% of cases. Laryngeal localization is rare.

Case Presentation
In the last 9-years, we observed three cases of laryngeal haemangioma, two females, and one male. All patients underwent to surgical excision. None of the three cases had intraoperative complications.

Discussion
The elective treatment of laryngeal haemangiomas remains controversial. In our cases, we opted for laser excision and we noticed that the risk of haemorrhages was particularly low, without no post-surgery complications.

Conclusion
We believe that due to the low morbidity and the fast-clinical recovery after treatment with definitive problem resolution, surgical treatment with laser CO_2 should be always considered for treatment of laryngeal haemangioma.

Keywords
Haemangioma; Laser CO_2; Laryngeal neoformation.

INTRODUCTION

Haemangioma is a benign vascular tumor, of endothelial origin, that affects the head and neck region in 60% of cases;[1] a laryngeal localization is rare.[2,3] It is more common during pediatric age;[4] in children it tends towards spontaneous regression and to subglottic localization,[5] whereas in adults it is infrequent and is normally observed in the glottic or supraglottic region,[5] mainly affecting the male sex.[4] Clinical symptoms are often absent;[1] in fact, a diagnosis of supraglottic haemangioma is generally due to an occasional endoscopic finding.[6,7] The detection of cutaneous head and neck haemangioma seems to be a risk factor because of the simultaneous presence of a laryngeal haemangioma;[8] which happens in 50% of infantile haemangiomas, but only seldom in the adult variant.[9] From a histologic viewpoint, it is mainly of cavernous type or mixed with a thin and friable mucosa covering the vascular stroma.[10] Potential complications consist of growth along with alteration of the laryngeal functionality; in the most advanced cases, it might even give rise to obstructive symptoms of the respiratory tracts and to hemorrhage.[11] We should bear in mind that it is not a progressive tumor, hence in some instances clinical observation is the preferable treatment;[12] given, however, the risk of hemorrhage, an aggressive type of treatment is instead opted for.[5] The therapeutic options envisage endoscopic removal with CO_2 laser, use of systemic steroids, interferon, and intralesional corticosteroid injections with short-term intubation.[11]

CASE SERIES

The study has been conducted by respecting the role of Helsinki declaration for human right and it was authorized by the institutional review board (IRB) committee of the Silvestrini University

Otolaryngol Open J. 2019; 5(1): 5-7. doi: 10.17140/OTLOJ-5-151

Hospital, without releasing an identification number. At Perugia's Otorhinolaryngology and Cervical-Facial Surgery Clinic, between August 2008 and February 2017, we observed 3 cases of laryngeal haemangioma, two females and one male, age ranging between 45 and 70-years. The female patient, aged forty-five, did not exhibit any symptom; as for the second case, a 56-year-old man, he had shown an episode of hemoptysis one month earlier; whereas the third patient (a woman), seventy years old, asymptomatic, underwent examination by an otolaryngologist to assess laryngeal motility in anticipation of a total thyroidectomy operation. All the patients underwent an ear nose throat (ENT) visit, magnetic resonance imaging (MRI) and fiber-optic laryngoscopy that highlighted: in the first case, as an occasional finding, a red-bluish lesion, lobate and mulberry-shaped, of approximately 11x13 mm, with an elastic texture at the level of the right aryepiglottic fold, an extremely rare localization (Figures 1 and 2); in the second case, there was a bluish sessile neoformation, localized at the level of the upper edge of the epiglottis; in the third case, there was a clear neoformation of the left vestibular fold about 0.8 mm in diameter. All the patients were surgically treated by CO_2 laser. The surgical intervention was carried out under general anesthesia. We used an operations mikroskop (OPMI) Sensera/S7-type Carl Zeiss microscope with 415 mm focal lenses, associated with a Sharplan CO_2 Laser System. The Laser was set in the pulsed emission mode (0.05 sec) and with an intensity variability between 2 and 5 watts; during the coagulation procedure, the laser intensity was reduced to 1-2 watts. The histological examination, in all the instances, attested a venous malformation with thrombosed and organized areas.

Figure 1: *Endoscopic View of a Red-Bluish Lesion on the Right Aryepiglottic Fold*

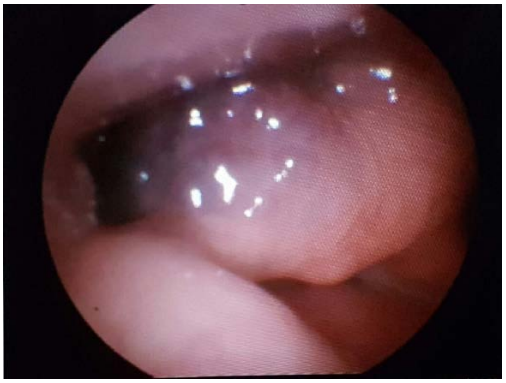

Figure 2: *Endoscopic View of a Red-Bluish Lesion on the Right Aryepiglottic Fold*

None of the three cases showed intraoperative complications. The excision has been easily finalized, thanks to excellent control of bleeding carried out by the combination of laser and bipolar tweezers. Thanks to the setting of CO_2 at the intensity of 1-2 watts during the coagulation procedure, we did not observe significative intraoperative bleeding. The patients were discharged after 48 hours following surgery. The follow-up was conducted 15 to 30-days after the intervention, and subsequently on a quarterly basis for the first year and then after 18 and 24-months from the excision. A temporary form of dysphonia was observed in patients 2 and 3, the symptom regressive spontaneously and it wasn't observed at the second follow-up in both patients. We speculate that dysphonia was secondary to the inflammation and edema of the surrounding tissue after CO_2 treatment; subcutaneous edema may be diffused until the glottic plane by inhibiting the normal vocal folds function. No functional post-surgery alterations were detected (Figure 3). In the second case, we detected the presence of a small bluish lesion at the level of the upper edge of the epiglottis after 24-months.

Figure 3: *Laser CO_2 Removal Results*

DISCUSSION

Laryngeal haemangioma in adults is an infrequent tumor, and it is rarer especially in the female population.[4,5] In our case series, we report two women affected from this pathology *versus* a single man only, and thus the strength of our paper is due to the rarity of the haemangioma in the female. There are a few clinical pieces of evidence in the literature, especially in the arytenoid localization, in support of rarity of this pathology. The election treatment of laryngeal haemangiomas remains still unclear.[5] Silent from a clinical viewpoint, it may manifest with dysphagia, dyspnea in the event of very bulky neoformations, or hemorrhage in case of breakage.[6, 7] In our case, detection of the neoformation was a occasional, and execution of the MRI has proven to be useful to confirm the nature and extent of the neoformation. Due to the high risk of hemorrhage, execution of a biopsy and cold excision is not recommended;[6,7,13,14] in agreement with other authors, we believe, although from a histopathological point view it exhibits some benign characteristics, the first choice treatment of laryngeal haemangioma is excision.

We think that our choice to not perform a tracheostomy

before CO_2 may explain the reduced time of recovery in our case series, in addition, to limit the inflammation and edema intraoperatory cortisone was administered. We did not perform a temporary tracheotomy before laser CO_2 excision and this reduced the time of recovery of our patients that was in all of the cases 2 day.

The intraoperative bleeding was not significative in any patients. The optimal surgical approach to these lesions is still controversial given the limited case studies. Leaving aside such surgical approaches as pharyngotomy and laryngofissure, suitable for very bulky and/or very extensive neoformations, we recall that some authors believe that excision by CO_2 laser is not recommended for laryngeal haemangioma in adults.[15] On the other hand, Steiner and Ambrosch take the stance that this type of haemangioma might be successfully treated by CO_2 laser if it is pedunculated or circumscribed.[16]

CONCLUSION

In our cases, we opted for laser excision and we noticed that the risk of hemorrhages was particularly low, while no post-surgery complications arose. Thanks to the CO_2 laser technique, excision of the neoformation was, for all the patients, complete and free from any relapses months later. The limited morbidity of this technique and the fast clinical recovery with a permanent solution of symptoms makes us believe that the surgical approach through CO_2 laser is an effective one in treating this type of disease.

CONFLICTS OF INTEREST

The authors declare that they have no conflicts of interest.

REFERENCES

1. Martins RHG, Neto ACL, Semenzate G, Lapate R. Laryngeal hemangioma. *Braz J Otorhinolaryngol.* 2006; 72(4): 434-575. doi: 10.1016/S1808-8694(15)31009-0

2. Kawakami M, Hayashi I, Yoshimura K, Ichihara K, Nishikawa S, Ichihara T. Adult giant hemangioma of the larynx: A case report. *Auris Nasus Larynx.* 2006; 33(4): 479-482. doi: 10.1016/j.anl.2006.05.010

3. Dogan M, Ozgursoy OB, Muz SE, Gerceker M, Dursun G. Management of laryngeal hemangioma in adults: A case report. *Kulak Burun Bogaz Ihtis Derg.* 2010; 20(6): 314-317.

4. Lucioni M, Marioni G, Della Libera D, Rizzotto G. Adult Laryngeal hemangioma CO_2 laser excision. A single institution 3-year experience (Vittorio Veneto 2001-2003). *Acta Otolaryngol.* 2006; 126(6): 621-626. doi: 10.1080/00016480500452517

5. Chun-Ming H, Ka-Woo L, Chih-Jen H. Radiation therapy for life-threatening huge laryngeal hemangioma involving pharynx and parapharyngeal space. *Head Neck.* 2013; 35(4): E98-E101. doi: 10.1002/hed.21919

6. Shpitzer T, Noyek AM, Witterick I, et al. Noncutaneous cavernous hemangiomas of the head and neck. *Am J Otolaryngol.* 1997; 18(6): 367-374. doi: 10.1016/S0196-0709(97)90055-7

7. Gutièrrez HA, Dias MAD, Nieto S, Arzadun AH. Emangioma cavernoso laringeo dell' adulto [Italian]. *ORL-DIPS.* 2003; 30: 142-144.

8. Orlow SJ, Isakoff MS, Blei F. Increased risk of symptomatic hemangiomas of the airway in association with cutaneous hemangiomas in a "beard" distribution. *J Pediatr.* 1997; 131(4): 643-646. doi: 10.1016/S0022-3476(97)70079-9

9. Bitar MA, Moukarbel RV, Zalzal GH. Management of congenital subglottic hemangioma: Trends and success over the past 17 years. *Otolaryngol Head Neck Surg.* 2005; 132(2): 226-231 doi: 10.1016/j.otohns.2004.09.136

10. Yellin SA, LaBruna A, Anand VK. Nd:YAG laser treatment for laryngeal and hypopharyngeal hemangiomas: A new technique. *Ann Otol Rhinol Laryngol.* 1996; 105(7): 510-515. doi: 10.1177/000348949610500703

11. Rosai M. *Rosai and Ackerman's Surgical Pathology.* Maryland Heights, Missouri, USA: Elsevier. 2004.

12. Jong Won Won, Hyun Woong Lee, Kyu Hyun Yoon, Suh Yoon Yang, In Seok Moon, Tae Jin Lee. Extended Hemangioma from pharynx to esophagus that could be misdiagnosed as an esophageal varix on endoscopy. *Dig Endosc.* 2013; 25(6): 626-629. doi: 10.1111/j.1443-1661.2012.01405.x

13. Van Aalst JA, Bhuller A, Sadove AM. Pediatric vascular lesions. *J Craniofac Surg.* 2003; 14: 566-583.

14. Rahbar R, Nicollas R, Roger G, et al. The biology and management of subglottic hemangioma: Past, present, future. *Laryngoscope.* 2004; 114(11): 1880-1891. doi: 10.1097/01.mlg.0000147915.58862.27

15. Mugliston TAH, Sangwan S. Persistent cavernous haemangioma of the larynx: A pregnancy problem. *J Laryngol Otol.* 1985; 99(12): 1309-1311.

16. Steiner W, Ambrosch P. *Endoscopic Laser Surgery of the Upper Aerodigestive Tract.* NY, UK: Thieme Publisher. 2000.

ISSN 2470-4059

OTOLARYNGOLOGY

Open Journal

Openventio PUBLISHERS

Original Research

Combined Epley and Semont Maneuver in Benign Paroxysmal Positional Vertigo

Nevzat Demirbilek, PhD*

Department of ENT, Medilife Beylikduzu Hospital, Yakuplu Hurriyet Caddesi No: 5 Beylikduzu, Istanbul 34524, Turkey

***Corresponding author**
Nevzat Demirbilek, PhD
Department of ENT, Medilife Beylikduzu Hospital, Yakuplu Hurriyet Caddesi No: 5 Beylikduzu, Istanbul 34524, Turkey; Tel. +90 5322354490;
Fax: +90 0212 8668081; E-mail: drnevzatdemirbilek@gmail.com

Article information
Received: November 5th, 2018; **Revised:** January 28th, 2019; **Accepted:** February 7th, 2019; **Published:** February 7th, 2019

Cite this article
Demirbilek N. Combined epley and semont maneuver in benign paroxysmal positional vertigo. *Otolaryngol Open J*. 2019; 5(1): 8-12. doi: 10.17140/OTLOJ-5-152

ABSTRACT

Introduction
Benign paroxysmal positional vertigo is defined as a short, episodic, transient vertigo caused by changes in the position of the head.

Objectives
In this study, the effects of combined Epley and Semont maneuvers were investigated in patients with vertigo who were detected with some pathology in the posterior semicircular canal.

Methods
This prospective study, which was conducted between December 2016 and January 2018 at our clinic, included 196 patients with a typical history and positive Dix-Hallpike test with Videonystagmography (VNG). The patients were randomized into three groups as those who were subjected to the Epley, Semont or combined maneuvers. The patients were reevaluated after the first day, first week and first month following the maneuver. Evaluation of treatment response was based on the VNG test.

Results
Treatment rates of the Epley Group patients were 69.35% on the first day, 75.80% after the first week and 85.48% after the first month. The treatment rates of the Semont Group patients were found to be 63.26% on the first day, 75.51% after the first week and 81.63% after the first month. On the other hand, the treatment rates of the combined group patients were 85.88% on the first day, 90.58% after one week and 95.29% after one month. The treatment rate registered with the combined maneuver was found to be significantly higher than those in the Epley Group and the Semont Group ($\chi^2 = 6.685$, $p<0.05$; $\chi^2 = 6.346$, $p<0.05$). Six months after recovery, recurrence was registered in four patients in the Epley Group (6.4%) and five patients in the Semont Group (10.2%).

Conclusion
The results show that utilization of combined maneuvers in our study increased the success rate.

Keywords
Vertigo; Maneuver; Videonystagmography (VNG).

INTRODUCTION

Benign paroxysmal positional vertigo (BPPV) is defined as a short, episodic, transient vertigo caused by changes in the position of the head.[1] The most commonly observed reason is peripheral vestibular system disease.[2-4] It is observed two-fold in women in comparison to men and most commonly in the 5th and 6th decades of life.[5]

Although benign paroxysmal positional vertigo affects all three semicircular canals, the most commonly involved one is the posterior canal.[6,7] It is very important to identify which canal is involved in determining the treatment to be administered. The Dix-Hallpike test is used to detect posterior canal involvement, while the roll or Pagnini-McClure maneuver is used to detect horizontal (lateral) canal involvement.[7,8]

Patients diagnosed with benign paroxysmal positional vertigo are frequently treated with repositioning maneuvers.[1-4] The most commonly used one, the Epley maneuver is based on the

Otolaryngol Open J. 2019; 5(1): 8-12. doi: 10.17140/OTLOJ-5-152

canalithiasis theory, whereas the other commonly used a maneuver, the Semont maneuver is based on the cupulolithiasis theory.[5,7,8]

In this study, we aimed to investigate the efficacy of treatment success of the combination of the Epley and Semont maneuvers, which are the two most commonly used maneuvers in patients who present with positional vertigo who were diagnosed with pathology in the posterior semicircular canal.

MATERIALS AND METHODS

A total of 196 patients (83 males, 113 females, mean age of 52.6±8.5-years, range of 19 to 66 years) who visited our ear-nose-throat (ENT) outpatient clinic between December 2016 and January 2018 with complaints of dizziness who were diagnosed with posterior canal benign paroxysmal positional vertigo (BPPV) were enrolled in this prospective randomized comparative study. The study protocol was approved by the Bakırköy Sadi Konuk Research and Training Hospital Ethical Committee (Protocol No. 2016-129). All patients in the study provided written informed consent to confirm their voluntary participation.

Patients with non-posterior canal or bilateral canal involvement, those using ototoxic and tranquilizing drugs, those who could not tolerate the Dix-Hallpike test, those suspected of having central nervous system (CNS) disorders, patients with vestibular system diseases other than BPPV such as Meniere's disease, postural hypotension, chronic otitis media, perilymph fistula, labyrinthitis and vestibular neuritis were excluded from the study.

Videonystagmography equipment (VNG, Micromedical Technologies INC., Chatham, USA) was used in our study. Individuals who were to be tested for VNG were asked not to use any sedative drugs or take alcohol within 48 hours prior to the test. For a healthy recording, any makeup around the eyes was cleaned before the test. A quiet, dimly lit room and a quiet environment were preferred for the test to avoid distracting the patient. Dynamic positional tests (the Dix-Hallpike maneuver and roll maneuver) were performed together with VNG. The images were recorded. Observation of torsional nystagmus that lasted for less than 30 seconds clockwise when the left ear was below, unlike anti-clockwise, after 10-15 seconds of latency when the right ear was underneath; observation of torsional nystagmus in the reverse direction when the patient was brought to a sitting position; slowing and disappearance of the nystagmus when the maneuver was repeated and observation of concomitant vertigo with nystagmus, were considered as indicators of posterior canal BPPV. The absence of horizontal canal BPPV after the roll test was also confirmed.

Treatment was performed randomly by the same specialist with the Epley maneuver in one group (Epley group) and the Semont maneuver in another group (Semont group). The combined maneuvers were applied to the last group (combination group). In other words, the Semont maneuver was performed on the pathology side of the patient immediately after the Epley maneuver (Figure 1A-1G).

Figure 1A-1G: *The Epley Maneuver was Initiated for the Left Side. E-at the End of the Epley Maneuver, the Patient was Laid on the Opposite Side, with the Face Immediately Facing Upwards While Seating. F- the Patient was Laid on the Other Side without Changing the Position of the Head. At this Moment, their Face was Facing Downwards. G- the Patient was Lifted Up and the Maneuver was Terminated*

The combined maneuver was also suspended from the examination table by turning the patient's head 45 degrees to the lesion side and providing a 30-degree extension position. The head was then rotated 90 degrees to the opposite side of the lesion, maintaining the head in the extended position. The patient was then rotated 90 degrees to the opposite side of the lesion alongside with the head and the body and positioned in a face-down position with an angle of 135 degrees from the supine position. The patient was later laid down to the opposite side without changing the position of the head. At this moment the face was looking upwards. The patient was then swiftly put in a sitting position and immediately laid onto the other side. At this moment, the face was looking downwards. Lastly, they were slowly brought to an upright position, and the head was brought to a slight flexion position. Two minutes were spent in all the positions.

No aggravation technique or sedative premedication was administered during the procedure. After the patients were subjected to the maneuvers, they were informed about avoiding excessive physical exercise and sudden head movements for a week and told not to lie on the side of canal involvement. No drug treatment was administered after the procedure.

The patients were reevaluated after the first day, first week and the first month after the maneuver. The VNG test was considered as the basis for evaluating treatment response. The patients who did not develop vertigo and nystagmus were reported to have recovered, whereas those who developed such conditions were considered to not have responded to treatment. These patients were subjected to the same maneuvers. The patients were contacted in the sixth month, and findings were obtained on whether or not they had a repeated vertigo attack during this period.

Statistical analysis was performed using the PASW 19.0 version software (SPSS Inc., Chicago, IL, USA). Standard deviation (SS) was used for variables determined by measurement, whereas percentage (%) value was used for variables determined by counting. Wilcoxon signed-rank test was used for intra-group comparison of parameters of the abnormal distribution. A value of $p < 0.05$ was considered statistically significant.

RESULTS

Clinical and demographic data of the patients are shown in Table 1. Comparison of the groups with regards to age demonstrated a similarity among all three groups (p=0.554). Comparison of the groups with regards to sex demonstrated that all three groups were similar (p=0.796).

Table 1. *Clinical and Demographic Data of the Patients*

Affected side (right/left)	1/1.5
Vertigo presentation duration (days)	6.2±10.3
Sex	
Male	83
Female	113
Etiology	Trauma 21.9%, idiopathic 78.1%
First vertigo attack	72%

The treatment rates of the 62 Epley group patients who were subjected to the Epley maneuver were found to be 43/62 (69.35%) on the first day, 47/62 (75.80%) after one week and 53/62 (85.48%) after one month. The group recovery rates of the patients are shown in Table 2.

Table 2. *Group Recovery Rates*

	1st Day	1st Week	1st Month
Epley Group (n=62)	43/62 (69.35%)	47/62 (75.80%)	53/62 (85.48%)
Semont Group (n=49)	31/49 (63.26%)	37/49 (75.51%)	42/49 (81.63%)
Combined Group (n=85)	73/85 (85.88%)	77/85 (90.58%)	81/85 (95.29%)

Treatment rates of the 49 Semont group patients subjected to the Semont maneuver were 31/49 (63.26%) on the first day, 37/49 (75.51%) after one week and 42/49 (81.63%) after one month.

The treatment rates of the 85 Combined Group patients treated with the combined maneuver were found to be 73/85 (85.88%) on the first day, 77/85 (90.58%) after one week and 81/85 (95.29%) after one month.

The treatment rate in the combined group was found to be significantly higher than that in the Epley and Semont groups (χ^2=6.685, p<0.05; χ^2=6.346, p<0.05).

Six months after recovery, recurrence was reported in four patients in the Epley Group (6.4%) and five patients in the Semont Group (10.2%). However, no recurrence was observed in the Combined Group (0%).

Subsequent evaluation showed that there was no other maneuver-related canal escape or canal obstruction in any of the patients. Lower back pain was reported in one patient in the Epley group and in three patients in the combined maneuver group. Successful treatment was achieved with oral non-steroidal anti-inflammatory drug therapy.

DISCUSSION

Symptoms of BPPV are characterized by brief and severe episodes of dizziness, which may be frightening and very disturbing for the patient, caused by movements of the head against gravity. These are explained by the most current and widely accepted "*cupulolithiasis*" and "*canalithiasis*" theories. The definition of cupulolithiasis was first introduced by Schuknecht, who demonstrated that otoconia adhering to the cupula made the cupula susceptible to gravity, with resulting development of nystagmus and vertigo.[9] The Semont maneuver, which was developed in association with the cupulolithiasis theory, is based on the theory that otoconia in the cupula break free from their adhering positions following rapid head movements.[3,8,10] On the other hand, the most widely accepted "*canalithiasis*" theory is based on the notion that otoconia do not adhere to the cupula but actually move freely in the endolymph. Together with head movements, the particles initiate movement through the endolymph by piston action. As a result of this movement, the cupula is stimulated, causing the development of vertigo attacks.[11] The Epley maneuver, which is based on the canalithiasis theory, was developed to have these otoconia to fall back into the vestibule.[8] Better results that are obtained with the Epley maneuver in the treatment of BPPV have over the time led to consideration of the cupulolithiasis theory as invalid and attempts made in the application of canalithiasis treatment in all patients. However, studies have shown that the cupulolithiasis theory is still valid, and both methods demonstrate success in BPPV.[11-13] In our study, we aimed to investigate the effects of combining both maneuvers on treatment success.

This is a test based on recording eye movements created with visual or caloric stimuli with infrared video cameras by wearing spectacles with special recording apparatus without using VNG electrodes.[14] It is helpful in identifying unilateral/bilateral vestibular function deficits, confirming the diagnosis of BPPV, and in the differential diagnosis of central pathologies which are not easily distinguished with clinical examination.[15] In our study, we performed dynamic position tests with VNG in order to maintain objective criteria. As a result, all non-posterior canal pathologies were excluded from the study.

There are many studies in the literature related to these two maneuvers. Gans et al demonstrated that there were no statistically significant differences between the results of the Epley maneuver and the Semont maneuver in their study on 376 posterior canal BPPV patients, and there was no decrease in the recurrence rate with the Semont maneuver in comparison to the Epley maneuver.[16] In their study, Toupet et al demonstrated that the success rates of the Epley and Semont maneuvers were similar.[17] Herdman et al[18] compared the Epley and Semont maneuvers which were randomly performed in 60 patients with posterior canal BPPV; however, they could not demonstrate any statistically significant differences between the two treatment modalities. In a study of 840 patients with posterior channel BPPV, Steenerson et al[19] showed that the success rates of the Semont and Epley maneuvers were close (98% and 94%, respectively). However, disease recurrence was reported in 16% of the patients after a six-month follow-up period.

Wang et al[20] applied combined treatment with the Epley and Semont maneuvers. The results showed that there was an 85% success rate at the end of three months in patients subjected to the Epley maneuver alone, 84% success rate in patients who were subjected only to the most commonly practiced Semont maneuver, and there was 98% success in administering the two maneuvers in combination, while the difference was found to be statistically significant. The authors noted that the combined use of the two maneuvers increased the success rate and reduced the likelihood of recurrence of the disease. The VNG test was not noted in their publications.

In our study, the success rate with the Epley maneuver was reported as 69.35% on the first day, 75.80% after one week and 85.48% after one month. With the Semont maneuver, the success rate was found to be 63.26% on the first day, 75.51% after one week and 81.63% after one month. The success rate of the combined maneuver was 85.88% on the first day, 90.58% after one week and 95.29% after one month. The healing rate during the combined maneuver was found to be significantly higher than those in the Epley and Semont groups. In our repeated maneuver performed based on two different theories, no other canal escape or canal obstruction was observed in any of our patients.

To prevent debris from returning to the semicircular canal after applying the maneuvers on patients, a suggestion may be made for restriction of motion, such as waiting for 10-minutes after treatment, the necessity of avoiding sudden head movements, using three pillows at bedtime and not lying on the side of the pathology.[21,22] At our clinic, we also advise restriction of movement to our patients. We do not wear any soft cervical collar.

BPPV is a recurrent disease even after appropriate maneuvers.[19] In our six-month follow-up period, recurrence was reported in four (6.4%) of the patients who were subjected to the Epley maneuver and in five (10.2%) of the patients subjected to the Semont maneuver. There was no recurrence in the patients subjected to the combined maneuver (0%). The most important limitations of our study were the absence of control groups not subjected to maneuvers and the lack of prolonged recurrence of the disease for a period longer than six months.

CONCLUSION

The combined maneuvers in our study were found to have an increased success rate. The absence of recurrence during a six-month follow-up period is encouraging. There is a need for further studies to assess long-term outcomes.

REFERENCES

1. Brandt T. Positional and positioning vertigo and nystagmus. *J Neurol Sci*. 1990; 95: 3-28.

2. von Brevern M, Radtke A, Lezius F, et al. Epidemiology of benign paroxysmal positional vertigo: A population based study. *J Neurol Neurosurg Psychiatry*. 2007; 78: 710-715. doi: 10.1136/jnnp.2006.100420

3. Parnes LS, Agrawal SK, Atlas J. Diagnosis and management of benign paroxysmal positional vertigo (BPPV). *CMAJ*. 2003; 169: 681-693.

4. Kroenke K, Hoffman RM, Einstadter D. How common are various causes of dizziness? A critical review. *South Med J*. 2000; 93: 160-167.

5. Hilton M, Pinder D. The Epley (canalith repositioning) manoeuvre for benign paroxysmal positional vertigo. *Cochrane Database Syst Rev*. 2014; (12): CD003162. doi: 10.1002/14651858.CD003162.pub3

6. Dornhoffer JL, Colvin GB. Benign paroxysmal positional vertigo (BPPV): Idiopatic versus posttraumatic. *Acta Otolaryngol*. 1999; 119: 745-749.

7. Cakir BO, Ercan I, Cakir ZA, Civelek S, Sayin I, Turgut S. What is the trueincidence of horizontal semicircular canal benign paroxysmal positional vertigo? *Otolaryngol Head Neck Surg*. 2006; 134: 451-454. doi: 10.1016/j.otohns.2005.07.045

8. Viirre E, Purcell I, Baloh RW. The Dix-Hallpike manevraand the canalith repositioning manevra. *Laryngoscope*. 2005; 115(1): 184-187. doi: 10.1097/01.mlg.0000150707.66569.d4

9. Schuknecht HF. Positional vertigo: Clinical and experimental observations. *Trans Am Acad Ophthalmol Otolaryngol*. 1962; 66: 319-332.

10. Bisdorff AR, Debatisse D. Localizing signs in positional vertigo due to lateral canal cupulolithiasis. *Neurology*. 2001; 57(6): 1085-1088.

11. Pollak L, Davies RA, Luxon LL. Effectiveness of the particle repositioning maneuver in benign paroxysmal positional vertigo with and without additional vestibular pathology. *Otol Neurotol* 2002; 23(1): 79-83.

12. Squires TM, Weidman MS, Hain TC, Stone HA. A mathematical model for top-shelf vertigo: The role of sedimenting otoconia in BPPV. *J Biomech*. 2004; 37(8): 1137-1146. doi: 10.1016/j.jbiomech.2003.12.014

13. Otsuka K, Suzuki M, Furuya M. Model experiment of benign paroxysmal positional vertigo mechanism using the whole membranous labyrinth. *Acta Otolaryngol*. 2003; 123(3): 515-518.

14. SohaMekki. The role of videonystagmography (VNG) in assessment of dizzy patient. *Egypt J Otolaryngol*. 2014; 30: 69-72. doi: 10.4103/1012-5574.133167

15. Maslovara S, Vešligaj T, Butković Soldo S, et al. Importance of accurate diagnosis in benign paroxysmal positional vertigo (BPPV) therapy. *Med Glas (Zenica)*. 2014; 11(2): 300-306.

16. Gans RE, Harrington-Gans PA. Treatment efficiacy on benign paroxysmal positional vertigo (BPPV) with canalith repositioning

maneuver and Semont liberatory maneuver in 376 patients. *Semin Hear*. 2002; 23: 129-142. doi: 10.1055/s-2002-33002

17. Toupet M, Ferrary E, Bozorg Grayeli A. Effect of repositioning maneuver type and postmaneuver restrictions on vertigo and dizziness in benign positional paroxysmal vertigo. *Scientific World Journal*. 2012; 2012: 162123. doi: 10.1100/2012/162123

18. Herdman SJ, Tusa RJ, Zee DS, Proctor LR, Mattox DE. Single treatment approaches to benign paroxysmal positional vertigo. *Arch Otolaryngol Head Neck Surg*. 1993; 119(4): 450-454.

19. Steenerson RL, Cronin GW, Marbach PM. Effectiveness of treatment techniques in 923 cases of benign paroxysmal positional vertigo. *Laryngoscope*. 2005; 115(2): 226-231. doi: 10.1097/01.mlg.0000154723.55044.b5

20. Wang T, An F, Xie C, Chen J, Zhu C, Wang Y. The treatment of benign positional paroxysmal vertigo of posterior semicircular canal by Epley maneuver combined with Semont maneuver. *Lin Chung Er Bi Yan Hou Tou Jing Wai Ke Za Zhi*. 2014; 28: 1469-1471.

21. Moon SJ, Bae SH, Kim HD, Kim JH, Cho YB. The effect of postural restrictions in the treatment of benign paroxysmal positional vertigo. *Eur Arch Otorhinolaryngol*. 2005; 262: 408-411.

22. Cakir BO, Ercan I, Cakir ZA, Turgut S. Efficacy of postural restriction in treating benign paroxysmal positional vertigo. *Arch Otolaryngol Head Neck Surg*. 2006; 132: 501-505. doi: 10.1001/archotol.132.5.501

ISSN 2470-4059

OTOLARYNGOLOGY

Open Journal

Openventio PUBLISHERS

Original Research

Evaluation of the Effects of Resonance Voice Therapy in Children with Vocal Fold Nodules

Ziya Saltürk, MD*; Erdi Özdemir, MD; Tolgar Lütfi Kumral, MD; Güler Berkiten, MD; Belgin Tutar, MD; Yavuz Atar, MD; Huseyin Sari, MD; Yavuz Uyar, MD

ENT Clinic, Okmeydanı Training and Reseacrh Hospital, Darulaceze cadde, Şişli, Istanbul, Turkey

***Corresponding author**
Ziya Saltürk, MD
ENT Specialist, Okmeydanı Training and Reseacrh Hospital, Darulaceze cadde, Şişli, Istanbul, Turkey; Tel. 090 212 314 55 55; Fax. 090 221 78 00;
E-mail: ziyasalturk@gmail.com

Article information
Received: March 13th, 2019; **Revised:** March 27th, 2019; **Accepted:** April 1st, 2019; **Published:** April 15th, 2019

Cite this article
Salturk Z, Ozdemir E, Kumral TL, et al. Evaluation of the effects of resonance voice therapy in children with vocal fold nodules. *Otolaryngol Open J*. 2019; 5(1): 13-17. doi: 10.17140/OTLOJ-5-153

ABSTRACT

Purpose
We evaluated objective, auditive perceptual and subjective changes in the voices of children who underwent resonance voice therapy to treat vocal fold nodules.

Methods
We included 30 children with vocal fold nodules. All were evaluated prior to therapy and 6 and 8 weeks after therapy commenced *via* acoustic voice analysis, the grade, roughness, breathiness, asthenia, strain (GRBAS) scale, and the Turkish version of the pediatric voice handicap index. Fundamental frequency, jitter, and shimmer were recorded. The results were compared.

Results
The overall success rate was 86%. All data acquired before therapy differed significantly from those obtained after therapy.

Conclusion
Resonance voice therapy is effective for children with vocal fold nodules.

Keywords
Children; Vocal fold nodule; Voice therapy; Resonance; Voice analysis; Larynx.

INTRODUCTION

Vocal fold nodules (VFNs) are the most common benign laryngeal pathology and the most frequent cause of chronic voice problems in children.[1-4] The most common cause of VFNs is chronic phonotrauma.[5-7] Gastroesophageal reflux is among the possible etiologies,[8-10] but physiological problems, psychological factors, and issues related to excessive use, such as a large family, crowded classrooms, a noisy environment, and personal traits, such as a talkative personality, are contributing factors.[5,6,11,12] VFNs are estimated to occur in 17%-30% of children and are more common in boys,[3,4,13] but they usually disappear in both sexes at puberty.[4,14]

Voice is affected by supraglottic structures after voice production in the larynx. The supraglottic structures are resonator organs that add various formants and the final characteristics to the voice.[15] Nasal obstruction forces the voice to use the oral route, rendering the voice hyponasal. Enlarged nasal cavities cause air leakage, triggering hypernasal voice.[11]

Voice is an important aspect of personality; voice disorders may influence personal development during childhood. Adaptation to social life and schooling can be problematic, triggering personality problems such as poor confidence and social phobia.[16]

The management options for VFNs in children include follow-up with no treatment, voice therapy, surgery, medication aimed at treating gastroesophageal reflux, and a combination of approaches.[5,17] However, VFNs in children should be managed conservatively.[18] The aim of voice therapy is to change voice production and usage habits, thus obtaining a change in vocal use in daily life. In most patients, this will resolve the voice problems and

prevent recurrences.[19,20] Resonance voice therapy (RVT) is a holistic approach first described by Lessac and Madsen and then improved and formulated by Verdolini.[21] It can be used to treat both hypofunctional and hyperfunctional problems related to VFNs,[21,22] usually combined with efforts to improve vocal hygiene.[23] Previous studies on the effectiveness of voice therapy have not recommended any specific therapeutic method.[24] Therefore, no standardized therapy and therapy duration are available. In addition, our observations showed that vocal improvement occured before the end of therapy and usually at about 5th to 6th weeks. This study evaluated the objective and subjective changes in the voices of children who received vocal hygiene training and RVT for VFNs.

MATERIALS AND METHODS

Institutional Review Board approval for this study was obtained from the Okmeydanı Training and Research Hospital Ethical Committee. Thirty children with bilateral VFN treated with RVT between January and May 2017 were included in the study. The parents of all participants gave written informed consent.

All children underwent a complete otorhinolaryngological examination. Their vocal folds were then evaluated using a rigid 70° telescope laryngostroboscopy (Karl Storz Pulsar II, Tuttingen, Germany) after their oropharynx was anesthesized by 10% lidocaine sprey. Patients with vocal fold pathologies other than nodules, previous vocal tract surgery (including adenotonsillectomy), obstructive nasal and adenotonsillary pathology, laryngopharyngeal reflux, or asthma, or patients, who had previously received voice therapy, were excluded. We included all suitable patients treated in our phoniatrics clinic whose parents agreed with inclusion. In all, 36 patients were diagnosed with VFNs, 4 of whom underwent adenotonsillectomies and were thus excluded; 30 of the remaining 32 were enrolled. The vocal symptoms were between 3 months and 1 year in duration. The nodules were located at the bilateral junctions of the anterior and middle portions of the vocal folds in all patients. Nodules were classified as minimal (irregularity at the junction of the vocal folds), immature (hyperemic and edematous lesions), and mature (fibrotic). Full nodular regression, partial regression, no change, and enlargement were scored during therapy.

RVT was performed as described by Koçak and Bengisu[22] and conducted by Dr. Z.S. Patients were taught to relax the shoulders, neck, mouth, mouth floor, lips, tongue, and pharynx, and to engage in abdominodiaphragmatic breathing. Next, they began to repeat a "mamama" sound to feel vibration in the nose, paranasal sinuses, and face. The initial exercises were monotonal, and the tone was later varied. Next, patients voiced "mamama." Finally, words and sentences commencing with "m" were voiced. Initial exercises were performed melodically. Following this step, they were instructed to read books with the taught technique to adapt speech.[25] Patients attended therapy sessions with their parents, who monitored exercise consistency. Patients' compliance to therapy was checked by parents' feedbacks. Patients were evaluated prior to therapy and 6 and 8 weeks later. Patients were seen weekly and were asked to repeat their exercises at least five times daily. All patients were assessed by acoustic voice analysis, the Turkish version of the pediatric voice handicap index (pVHI), and the grade, roughness, breathiness, asthenia, strain (GRBAS) scale.

Vocal data were recorded using an akustische und kino-geräte gesellschaft m.b.H. (AKG) D5 dynamic microphone (Vienna, Austria) positioned 15 cm from the participant's lips. Following deep inspiration, the participant was prompted to say Turkish vowel "a." Praat software (ver. 4.4.13; Boersma and Weenink, University of Amsterdam, Amsterdam, The Netherlands) was used to conduct the acoustic analysis. Standard Praat scripts were employed. To evaluate the voice objectively, the fundamental frequency (F0), jitter, and shimmer were determined during acoustic voice analysis. The grade, roughness, breathiness, asthenia, strain (GRBAS) scale was used for perceptual analyses.[25] Voice recordings were evaluated twice, in a blinded manner, by an experienced speech pathologist and an experienced singing teacher; the mean scores were calculated. The Turkish version of the pVHI, validated by Ozkan et al[26] was used for subjective analyses.

The data were statistically analyzed using SPSS 22 (IBM, Turkey). A repeated analysis of variance (ANOVA) test for the analysis of repeated measurements, and the Bonferroni test to identify differences in the repeated measurements.

RESULTS

The mean age of the children in the study group was 8.386-13 years old. There were 19 boys and 11 girls in the study group. Nodules were immature in 11 patients and mature in 19. Parents reported that 21 of the children consistently performed their exercises but 9 did not. Consistency improved over time (Table 1).

Table 1. *Nodule Size*

Nodule size	0 week	6th week	8th week
Minimal	-	15	2
Immature	11	3	9
Mature	19	8	2

Therapy for VFN failed to afford complete resolution (the ultimate aim) in four patients, but their nodules regressed partially. The overall success rate was 86% complete resolution. Table 2 provides the results of acoustic voice analyses.

Use of the GRBAS and the PVHI-10, followed by Bonferroni testing, showed that Fo, jitter, and shimmer differed significantly from prior to therapy to week 6, and also between weeks 6 and 8 ($p<0.001$ and $p<0.001$ respectively, for all three parameters). The GRBAS also revealed significant differences between pre-therapy data and those obtained at week 6 (all three parameters), but not between the week 6 and week 8 data on asthenicity and strain ($p=0.24$ and 0.482, respectively). Grade, roughness, and breathiness scores differed between weeks 6 and 8 ($p<0.001$, $p<0.001$, and $p=0.04$, respectively). The PVHI-10 results differed significantly between baseline and week 6 and between weeks 6 and 8 ($p<0.001$ and $p<0.01$, respectively).

Table 2. *A Comparison of Vocal Parameters*

N=30	Before Therapy	6th week	8th week	p
Fo	234.54±5.34	252.62±7.18	267.37±7.67	p<0.001
Jitter	2.64±0.71	0.98±0.38	0.54±0.29	p<0.001
Shirmer	7.91±1.09	4.49±0.81	4.04±0.85	p<0.001
Grade	2.33±0.71	0.97±0.49	0.20±0.41	p<0.001
Ro111mess	2.37±0.72	0.87±0.57	0.20±0.48	p<0.001
Breathiness	2.20±0.81	0.63±0.56	0.33±0.48	p<0.001
Asthenicity	0.87±0.68	0.17±0.38	0.07±0.25	p<0.001
Strain	0.53±0.51	0.13±0.35	0.07±0.25	p<0.001
PVHI-10	35.90±11.04	8.30±2.62	4.77±1.31	p<0.001

Fo: Fundamental frequency; pVHI-10: Pediatric voice handicap index-10
Repeated anova p<0.05 is significant

DISCUSSION

There is no standardized treatment of VFNs in children, although they are the most common cause of chronic voice problems. Among the available options, voice therapy is the preferred approach. Surgical treatment without voice therapy is usually not indicated because the recurrence rate is extremely high unless vocal behaviors are modified.[27] Voice therapy was shown to be effective alone, but the optimal therapy technique is not clear.[28] Studies on VFNs in children have used combinations of different voice therapy methods that were not clearly defined.[29-32] The primary aim in both non-surgical and surgical therapeutic approaches is reduction of vocal abuse.[32]

Deal et al[29] published the first study of VFNs in children, which reported regression of the nodules in 84% of the patients, 65% of whom had normal larynges after therapy. The children were evaluated with respect to loudness reduction and the easy initiation and maintenance of phonation. Mori[33] compared the results of voice therapy with other treatment options and found that 52% of patients had some degree of improvement after voice therapy, but the exact technique was not specified. That study emphasized the improvements shown by most prepubertal patients after they entered puberty, but also with surgery in those patients who sought immediate resolution. For school-aged children, waiting until puberty may cause emotional and psychological problems because the voice is an important tool for self-expression and social development.[34] We therefore recommend voice therapy for all of our patients at the time of diagnosis. Niedzielska et al[31] used a combination of pharmacological agents and psychological, physical, and voice therapy methods in a group of patients. In a comparison of the results with those of a similarly treated healthy control group, they found flattening of the vocal nodules on stroboscopy and improvement in the acoustic voice analysis. In our study, we excluded patients with gastroesophageal reflux disease and other problems to avoid bias related to medication, among other factors. Tezcaner et al[32] also used a combination of therapies and noted improvements in acoustic voice analysis and perceptual scores. Valadez et al[27] used acoustical analysis, perceptual assessment, and video nasolaryngoscopy to assess the therapeutic results. They suggested that eliminating forceful phonation through speech therapy using visual support and the Speech-Viewer software was effective for treating VFNs in their initial stages.

All of our patients underwent RVT together with vocal hygiene precautions. RVT consists of several well-formulated steps aimed at changing a patient's vocalization habits. Thus, the therapist guides the patient to feel the resonance of the voice at the palate, lips, nose, and paranasal region. This is achieved by having the patients study phonemes first individually and then by using their resonated voice in sentences. Therapy generally consists of eight episodes held once a week.[22]

We found that the fundamental frequency, jitter, and shimmer improved significantly after therapy. Perturbations in these parameters caused by nodule-induced turbulence while voicing seriously affect voice.[33] All acoustic parameters and the GRBAS scores improved significantly after therapy. Significant improvements in our patients were obtained at the end of 6 weeks. The main problem in therapy is compliance, as children often have difficulties in obeying vocal hygiene instructions and have a tendency to shout and talk in social environments. The cooperation of the family and teacher is therefore an important component of therapeutic success. Home exercises should be performed regularly and previous exercises repeated at every session to monitor the child's progress.

The main limitation of our study was the small number of patients. We do not perform surgery for vocal nodules in children and were therefore unable to compare the results of our therapeutic approach with those obtained surgically. Nonetheless, the main advantage of our study is its subjective evaluation of children with VFN and its collection of data at 6 weeks to evaluate the progress before the end of therapy.

CONCLUSION

RVT combined with vocal hygiene and respiration exercises is an effective approach in children with VFNs. Patients and parents should be informed about the course of therapy and the importance of compliance. Because VFNs regress gradually, therapy should be completed even though dramatic improvement, determined in perceptual and subjective evaluations, may occur before the conclusion of the full 8-week course.

FINANCIAL DISCLOSURE

No author has any relevant relationship to disclose

CONFLICTS OF INTEREST

The authors declare that they have no conflicts of interest.

REFERENCES

1. Gray SD, Smith ME, Schneider H. Voice disorders in children. *Pediatr Clin North Am.* 1996; 43: 1357-1384.

2. Herrington-Hall BL, Lee L, Stemple JC, Niemi KR, McHone MM. Description of laryngeal pathologies by age, sex and occupation in a treatment-seeking sample. *J Speech Hear Disord.* 1988; 53: 57-64. doi: 10.1044/jshd.5301.57

3. Dobres R, Lee L, Stemple JC, Kummer AW, Kretschmer LW. Description of laryngeal pathologies in children evaluated by otolaryngologists. *J Speech Hear Disord.* 1990; 55: 526-532. doi: 10.1044/jshd.5503.526

4. von Leden H. Vocal nodules in children. *Ear Nose Throat J.* 1985; 64: 473-480.

5. Pannbacker M. Treatment of vocal nodules: Options and outcomes. *American Journal of Speech-Language Pathology.* 1999; 8: 209-217. doi: 10.1044/1058-0360.0803.209

6. Roy N, Holt KI, Redmond S, Muntz H. Behavioural characteristics of children with vocal fold nodules. *J Voice.* 2007; 21: 157-168. doi: 10.1016/j.jvoice.2005.11.004

7. Boone DR, McFarlane SC, Von Berg SL. Voice disorders. In: *The Voice and Voice Therapy.* 7th (edn). Pearson, Boston, USA: Allyn & Bacon. 2005. 68-71.

8. Kuhn J, Toohill RJ, Ulualp SO, et al. Pharyngeal acid reflux events in patients with vocal cord nodules. *Laryngoscope.* 1998; 108:1146-1149. doi: 10.1097/00005537-199808000-00008

9. Yellon RF, Goldberg H. Update on gastroesophageal reflux disease in pediatric airway disorders. *Am J Med.* 2001; 3(111 Suppl 8A): 78S-84S. doi: 10.1016/S0002-9343(01)00861-0

10. Putnam PE, Orenstein SR. Hoarseness in a child with gastroesophageal reflux. *Acta Paediatr.* 1992; 81: 635-636. doi: 10.1111/j.1651-2227.1992.tb12319.x

11. Carding PN, Roulstone S, Northstone K, ALSPAC Study Team. The prevalence of childhood dysphonia: A cross-sectional study. *J Voice.* 2006; 20: 623-630. doi: 10.1016/j.jvoice.2005.07.004

12. Green G. Psycho-behavioral characteristics of children with vocal nodules: WPBIC ratings. *J Speech Hear Disord.* 1989; 54: 306-312. doi: 10.1044/jshd.5403.306

13. Akif Kilic M, Okur E, Yildirim I, Guzelsoy S. The prevalence of vocal fold nodules in school age children. *Int J Pediatr Otorhinolaryngol.* 2004; 68: 409-412. doi: 10.1016/j.ijporl.2003.11.005

14. Sataloff RT. Structural Abnormalities of the Larynx. In: Sataloff RT (ed). *Professional Voice, The Science and Art of Clinical Care.* 3rd (edn). Plural Publishing, San Diego, 2005. 1259.

15. Nardone HC, Recko T, Huang L, Nuss RC. A retrospective review of the progression of pediatric vocal fold nodules. *JAMA Otolaryngol Head Neck Surg.* 2014; 140: 233-236. doi: 10.1001/jamaoto.2013.6378

16. Angelillo N, Di Costanzo B, Angelillo M, et al. Epidemiological study on vocal disorders in pediatric age. *J Prev Med Hyg.* 2008; 49: 1-5. doi: 10.15167/2421-4248/jpmh2008.49.1.109

17. Wohl DL. Nonsurgical management of pediatric vocal fold nodules. *Arch Otolaryngol Head Neck Surg.* 2005; 131: 68-70. doi: 10.1001/archotol.131.1.68

18. Colton RH, Casper JK, Leonard R. Voice problems associated with the pediatric and the geriatric voice. In: *Understanding Voice Problems.* 3rd (edn). Philadelphia, USA: Lippincott Williams and Wilkins. 2006; 208-209.

19. Koçak İ, Dursun G, Demireller A. Fonksiyonel disfonilerde larengostroboskopi ile vizüel biofeedback terapisi [In: Turkish]. *Ses ve Ses Bozuklukları.* : 1996; 85-93.

20. Morrison MD, Rammage LA. Muscle misuse voice disorders: Description and classification. *Acta Otolaryngol.* 1993; 113(3): 428-434. doi: 10.3109/00016489309135839

21. Verdolini K, Druker DG, Palmer PM, Samawi H. Laryngeal adduction in resonant voice. *J Voice.* 1998; 12(3): 315-327. doi: 10.1016/S0892-1997(98)80021-0

22. Bengisu S, Koçak İ. Rezonan ses terapisi yöntemi [In: Turkish]. *Turkiye Klinikleri J E.N.T.* 2013; 6(2): 22-26.

23. Behlau M, Pontes P, Vieira VP, Yamasaki R, Madazio G. Presentation of the comprehensive vocal rehabilitation program for the treatment of behavioral dysphonia. *Codas.* 2013; 25(5): 492-496. doi: 10.1590/S2317-17822013000500015

24. Desjardins M, Halstead L, Cooke M, Bonilha HS. A systematic review of voice therapy: What "effectiveness" really implies. *J Voice.* 2017; 31(3): 392.e13-392.e32. doi: 10.1016/j.jvoice.2016.10.002

25. De Bodt MS, Wuyts FL, Van de Heyning PH, Croux C. Test–retest study of the GRBAS scale: Influence of experience and professional background on perceptual rating of voice quality. *J Voice.* 1997; 11: 74-80. doi: 10.1016/S0892-1997(97)80026-4

26. Özkan ET, Tüzüner A, Demirhan E, Topbaş S. Reliability and validity of Turkish pediatric voice handicap index. *Int J Pediatr Otorhinolaryngol.* 2015; 79: 680-684. doi: 10.1016/j.ijporl.2015.02.014

27. Valadez V, Ysunza A, Ocharan-Hernandez E, Garrida-Bustamante N, Valeria-Sanchez A. Voice parameters and videonasolaryngoscopy in children with vocal nodules: A longitudinal study, before and after voice therapy International *Journal of Pediatric Otorhinolaryngology.* 2012; 76: 1361-1365. doi: 10.1016/j.ijporl.2012.06.007

28. Sıgnorelli ME, Madıll CJ, Mccabe P. The management of vocal fold nodules in children: A national survey of speech-language pathologists. *Int J Speech Lang Pathol.* 2011; 13(3): 227-238. doi: 10.3109/17549507.2011.549570

29. Deal RE, McClain B, Sudderth JF. Identification, evaluation, therapy, and follow-up for children with vocal nodules in a public school setting. *J Speech Hear Disord*. 1976; 41: 390-397. doi: 10.1044/jshd.4103.390

30. Mori K. Vocal fold nodules in children: Preferable therapy. *Int J Pediatr Otorhinolaryngol*. 1999; 49 (suppl 1): S303-306. doi: 10.1016/S0165-5876(99)00181-0

31. Niedzielska G, Glijer E, Niedzielski A. Acoustic analysis of voice in children with noduli vocales. *Int J Pediatr Otorhinolaryngol*. 2001; 60: 119-122. doi: 10.1016/S0165-5876(01)00506-7

32. Tezcaner CZ, Karataylı Özgürsoy S, Satı I, Dursun G. Changes after voice therapy in objective and subjective voice measurements of pediatric patients with vocal nodules. *Eur Arch Otorhinolaryngol*. 2009; 266: 1923-1927. doi: 10.1007/s00405-009-1008-6

33. Deroche MLD, Limb CJ, Chatterjee M, Gracco VL. Similar abilities of musicians and nonmusicians to segregate voices by fundamental frequency. *J Acoust Soc Am*. 2017; 142(4): 1739. doi: 10.1121/1.5005496

34. Fuchs M. Landmarks of physiological development of the voice in childhood and adolescense (Part 1). *Laryngorhinootologie*. 2008; 87(1): 10-16. doi: 10.1055/s-2007-995343

ISSN 2470-4059

OTOLARYNGOLOGY

Open Journal

Openventio PUBLISHERS

Retrospective Study

Increased Epulis Gravidarum Prevalence in Women with Both Nasal and Oral Symptoms

Maria Cristina Cristi, MD[1]; Valeria Gambacorta, MD[2*]; Alfredo Di Giovanni, MD[2]; Simona Pindozzi, MD[3]; Luigi Tassi, MD[3]; Paradiso Daniele, MD[4]; Giampietro Ricci, MD[1,2]

[1]*Department of Head and Neck Surgery, Santa Maria della Misericordia Hospital, Perugia, Italy*
[2]*Department of Surgery and Biomedical Science Section of Otorhinolaryngology, University of Perugia, Perugia, Italy*
[3]*Department of Head and Neck Surgery, San Giovanni Battista Hospital, Foligno, Italy*
[4]*Department of Dentistry, Santa Maria della Misericordia Hospital, Perugia, Italy*

***Corresponding author**
Valeria Gambacorta, MD
Medical doctor, Resident, Department of Surgery and Biomedical Science Section of Otorhinolaryngology, University of Perugia, Perugia 06132, Italy;
Tel. +393204794042; E-mail: gambacortavaleria@gmail.com

Article information

Received: March 28th, 2019; **Revised:** April 11th, 2019; **Accepted:** April 15th, 2019; **Published:** April 17th, 2019

Cite this article

Cristi MC, Gambacorta V, Di Giovanni, et al. Increased epulis gravidarum prevalence in women with both nasal and oral symptoms. *Otolaryngol Open J*. 2019; 5(1): 18-21. doi: 10.17140/OTLOJ-5-154

ABSTRACT

Background

Hormonal variations during pregnancy are frequently linked with functional mucosal alterations both at oral and nasal level. Clinical manifestations of this mucosal involvement can be described generally as pregnancy rhinitis and pregnancy stomatitis and gingivitis. The sexual hormones produced during pregnancy have an important role in the development of rhinitis and gingivitis. Epulis gravidarum affects about 5-10% of pregnant, being defined as a hyperplastic and inflammatory lesion which origins from the buccal mucosa and mainly from gingival tissues.

Objective

To define whether the coexistence of nasal and oral symptoms should be considered as a major risk factor for the development of epulis gravidarum.

Materials and Methods

From November 2010 to January 2017, 228 pregnant women were examined during the weeks of gestation, two and four months after partum. They underwent a clinical examination at enrollment (t0), after 2 months (t1), at ninth month of gestation (t2), 2 months after childbirth (t3) and 4 month after childbirth (t4). Were also administered two anamnestic questionnaires concerning the risk factors and nasal and oral symptoms. Patients were divided into 4 groups according to the symptoms of questionnaires: Group A, including women with no nasal and oral risk; Group B, including women with nasal symptoms and no oral involvement; Group C, including pregnant women with oral symptoms and no nasal involvement; and Group D including women with both oral and nasal involvement.

Results and Conclusion

Our study reveals a statistic significative difference (p=0.01) between the frequency of epulis in pregnant women presenting only gingival symptoms (Group C) compared to those which manifest simultaneously nasal and gum symptoms (Group D). In fact, our results seem to suggest that pregnant women who present both nasal and gum symptoms have an increased risk of developing epulis.

Keywords

Epulis gravidarum; Pregnancy rhinitis; Stomatitis; Gingivitis; Nasal secretion; Nasal blockage; Gum lesion.

Openventio PUBLISHERS

BACKGROUND

Hormonal variations during pregnancy are frequently linked with functional mucosal alterations both at oral and nasal level.[1,2] Although a specific pathophysiological mechanism responsible of this correlation has not yet been defined, an important role is likely played by increasing plasma sex steroid hormone levels during pregnancy, whose effect on periodontium[2] and on nasal mucosa[3-5] is well demonstrated. Recent researches have shown that increasing blood levels of oestrogen and progesterone during pregnancy are responsible for the gingivitis progression.[2-4] Accordingly, rhinitis may be caused by several substances and hormones secreted during pregnancy (porcine growth hormone (PGH), vasoactive intestinal polypeptide (VIP), oestrogen, progesterone), leading to changes in the nasal mucosa.[5] However, in most cases, these alterations are reversible at the end of the pregnancy.[2-5] Clinical manifestations of this mucosal involvement can be described generally as pregnancy rhinitis and pregnancy stomatitis and gingivitis.[2,3,6] Rhinitis, which is most frequently observed, is reported in the 22% of pregnant women.[7-9] Pregnancy rhinitis is defined as a nasal mucosal congestion present for at least six consecutive weeks, without any sign of infection, even in absence of allergy predisposition or endonasal neoformations.[5-7] Symptoms may develop in every stage of pregnancy and completely regresses within two weeks after partum.[8-10] The probability to show pregnancy rhinitis is increased in smokers, with a 69% increase prevalence, in house dust mites sensitized women, and in chronic sinusitis.[7,8,10] Clinically, pregnancy rhinitis is characterized by classic symptoms: serious rhinorrhoea, nasal obstruction, headache, sleep disorders.[10,11] However, etiology is still to be clarified. Numerous substances and hormones secreted during pregnancy lead to changes in the nasal mucosa, increasing the activity of serous-mucous glands and of local vascularization.[5,11,12] Pregnancy gingivitis is defined as a form of periodontal (gum) disease due to the hormonal changes. This leads to increased blood flow to the gum tissue with secondary inflammation of this tissue in response to the presence of plaque.[4-13] During this condition, the gums will appear swollen and easily bleeding.[4-13] In a lower number of cases, gingivitis can be complicated by the development of an epulis.[14] Epulis gravidarum affects about 5-10% of pregnant, being defined as a hyperplastic and inflammatory lesion which origins from the buccal mucosa and mainly from gingival tissues.[15,16] Risk factors are inadequate oral hygiene, chronic gingivitis, use of hormonal therapies, antihypertensive, antiepileptic, immunosuppressive drugs and high gingival levels of active progesterone due to pregnancy.[14] High-levels of progesterone act on the capillary vessels causing endothelial proliferation.[13,14] It is believed that the epulis gravidarum originates from the mesenchyme of the alveolar-dental ligament. The most common histologic type is the "Lobular Capillary Hemangioma (LCH)", also called "pregnancy tumor"; usually it spontaneously regresses after delivery[14] secondary to the inhibition of vascular endothelial growth factor (VEGF) production and cell apoptosis signaling. In our study we have tried to better evaluate the correlation between oral and nasal symptoms during pregnancy, aiming at defining whether the coexistence of nasal and oral symptoms should be considered as a major risk factor for the development of epulis gravidarum.

MATERIALS AND METHODS

From November 2010 to January 2017, 228 pregnant women in different gestational ages, aged 24 to 40, were evaluated by ears, nose, and throat (ENT) visit and dental examination. Patients were administered two anamnestic questionnaires concerning the risk factors and nasal (Table 1), and oral symptoms (Table 2). Clinical examination, conducted by a specialist Otorhinolaryngologist and by a dentist, was designed to assess the integrity of the nasal and gingival mucosa, congestion of the same, the quantity and quality of nasal secretions, the presence of gum hyperemia in the absence of prosthetic bed sore, gum bleeding, pain and/or tenderness of the gums to acupressure or tenderness to percussion of teeth, development of epulis (Table 3). The clinical examination was performed at enrollment (t0), after 2 months (t1), at ninth month of gestation (t2) (when possible), and 2 and 4 months after childbirth (t3 and t4). Patients were divided into four groups, according to the symptoms questionnaires: Group A, including women with no nasal and oral risk; Group B, including women with nasal symptoms and no oral involvement; Group C, including pregnant women with oral symptoms and no nasal involvement; and Group D including women with both oral and nasal involvement. Statistical analysis was performed with SPSS 10.0 for Windows. Comparison between groups was performed with contingency tables and Fisher's Exact Test. The limit for significance was 0.05.

Table 1. *Nasal Symptoms Questionnaire*

1	Have you ever experienced any of these symptoms?
	- Nasal blockage
	- Nasal secretions
	- Oral respiration
	- Nasal itching
	- Sneezing
	- Itchy palate
2	Have you ever suffered of rhinitis before pregnancy?
3	Did you ever take nasal decongestant drugs?
4	Have you ever been admitted for nasal surgery?
5	Any of your relatives is/has been affected by rhinitis?

Table 2. *Oral Symptoms Questionnaire*

1	Have you ever experienced any of these symptoms or signs?
	- Drooling
	- Gum bleeding
	- Gum lesion
	- Tooth decay
	- Periodontitis
	- Gengival hyperemia
	- Gum tenderness
2	Any of your relatives is/has been affected by epulis?
3	Have you got a mobile o fixed dentures?
4	Have you ever done a dental evaluation?
5	Have you ever taken hormonal therapy?

Openventio PUBLISHERS

Table 3. *Symptoms and Signs During the Follow-up*

Symptoms and Signs	t0	t1	t2	t3	t4
State of nasal mucosa					
Quantity and quality of nasal secretions					
Nasal mucosa congestion					
State of gum					
Gum congestion					
Gum hyperemia					
Gum pain					
Pain to percussion of the teeth					
Gum bleeding					
Epulis					

Table 4. *Summary of the Results*

Group	N	Rhinitis	Gingivitis	Risk Factors	Epulis	Symptoms
A	92	0	0	0	0	Asyntomatic
B	42	42	0	0	0	Sereus rhinorrhea, headache, mouth breathing
C	64	0	64	26	4	Hypersalivation, gengival hypertrophy and hyperemia, bleeding gums
D	20	20	20	6	6	Gum and nasal symptoms
Total	218					

RESULTS

Group A, included 92 pregnant women, none of them, according to the questionnaire, reported any risk factors nor developed any symptoms. Group B, included 42 pregnant women without risk factors, all of them reported serious rhinorrhea, headache, nasal blockage, sleep disorders, and the ENT examination showed hyperemia of the nasal mucosa, turbinate hypertrophy with sub stenosis in one or both of the nasal cavity, presence of serious secretions; all symptoms developed around the 4th-5th month of pregnancy. Group C included 64 pregnant women, 26 of which showed positive risk factors, all of them showed hypersalivation and hypertrophy of the gingival mucosa around 4th-5th month of pregnancy and, at the follow-up visit, 4 of them had an epulis. Group D, included 20 pregnant women suffering from pregnancy rhinitis and gingival diseases, 6/20 developed an epulis occurring approximately at the same gestational age of Group C (Table 4). After two months postpartum, signs and symptoms of pregnancy rhinitis in women of Group B and D were completely regressed, in one woman of Group C and in two women of Group D, after 4 months postpartum, the surgical excision of the lesion was required. Ten pregnant women left the study. Our findings on the frequency of the nasal and gum disease during pregnancy are consistent with the scientific literature: the 42.20% of pregnant women were asymptomatic, the frequency of pregnancy rhinitis alone was of 19, 27% (22% reported from the literature).[7-9] As for the epulis, this occurred in 5.5% of our entire sample, in 6.25% of pregnant women who had only the symptoms gum (Group C) compared with 30% of Group D (positive for rhinitis and gingivitis).

DISCUSSION AND CONCLUSION

Our study reveals a statistic significative difference (p=0.01) between the frequency of epulis in pregnant women presenting only gingival symptoms (Group C) compared to those which manifest simultaneously nasal and gum symptoms (Group D). In fact, 4 of 26 pregnant women of Group C presented an epulis; in Group D, a more consistent number of women (6 of 20) developed an epulis.

Although the pathophysiological mechanism is still unclear, the literature suggests the key role of some hormones in the development of gingivitis[4-14] and rhinitis[1-7] during pregnancy. It is well known that increasing blood levels of sex steroid hormone during pregnancy are responsible for mucosal alterations both on periodontium and nasal mucosa.[2,3,5] A study conducted by Wu et al shows the effects of progesterone and estrogen on the change of subgingival microbiota and immunologic physiological mediators in periodontal tissue.[2]

Several studies have shown that the presence of gum diseases is a risk factor for the development of epulis gravidarum.[13-15] A study conducted by Di Placido et al argues that sexual hormones seem to act as growth factors for the subgingival bacterial flora it. They can cause modifications in the peripheric vascular system, and a marked increase of vascular permeability and the following edema of the gingival tissues.[17]

The aim of our study was to verify if the concomitant presence of pregnancy rhinitis and gum disorders increases the risk of epulis development during pregnancy. To our knowledge, no other studies were aimed at evaluating such correlation, as most studies are focused on epulis alone or gestational rhinitis alone. Our results seem to suggest that pregnant women who present both nasal and gum symptoms have an increased risk of developing epulis. In our opinion this could be important in order to know and observe the development of epulis in the gravid women, maybe, after further studies, we could consider rhinitis as a predictive prognostic factor for the occurrence of epulis. In fact, these data should, however, be confirmed by further studies involving a greater number of subjects, in order to avoid any possible bias due to local and regional variations.

FINANCIAL DISCLOSURE

No author has any relevant relationship to disclose

CONFLICTS OF INTEREST

The authors declare that they have no conflicts of interest.

REFERENCES

1. Ellegard EK. The etiology and management of pregnancy rhinitis. *Am J Respir Med*. 2003; 2(6): 469-475. doi: 10.1007/BF03256674

2. Wu M, Chen SW, Jiang SY. Relationship between gingival inflammation and pregnancy. *Mediators Inflamm*. 2015; 2015: 623427. doi: 10.1155/2015/623427

3. Ellegard EK. Clinical and pathogenetic characteristics of pregnancy rhinitis. *Clin Rev Allergy Immunol*. 2004; 26(3): 149-159. doi: 10.1385/CRIAI:26:3:149

4. Preethi R, Ramamurthy J. Pregnancy gingivitis. *Research Journal of Pharmaceutical Biological and Chemical Sciences*. 2015; 6(1): 7-10.

5. Dzieciolowska-Baran E, Teul-Swiniarska I, Gawlikowska-Sroka A, Poziomkowska-Gesicka I, Zietek Z. Rhinitis as a cause of respiratory disorders during pregnancy. *Adv Exp Med Bio*l. 2013; 755: 213-220. doi: 10.1007/978-94-007-4546-9_27

6. Greer IA, Walters B, Nelson-Piercy C. Pulmunary disease in pregnancy. In: *Maternal Medicine: Medical Problems in Pregnancy*. London, England: Churchill Livingstone. 2007. 125-159.

7. Ellegard E, Hellgren M, Torén K, Karlsson G. The incidence of pregnancy rhinitis. *Gynecol Obstet Invest*. 2000; 49(2): 98-101. doi: 10.1159/000010223

8. Ellegård EK. Special considerations in the treatment of pregnancy rhinitis. *Womens Health (Lond)*. 2005; 1(1): 105-114. doi: 10.2217/17455057.1.1.105

9. Ellegård EK. Pregnancy rhinitis. *Immunol Allergy Clin North Am*. 2006; 26(1): 119-135. doi: 10.1016/j.iac.2005.10.007

10. Hoffmann TK, Wagenmann M, Kojda G, Bender HG, Friebe-Hoffmann U. Symptoms and therapy for pregnancy rhinitis. *Z Geburtshilfe Neonatol*. 2004; 208(4): 126-132. doi: 10.1055/s-2004-827218

11. Schatz M, Zeiger RS. Diagnosis and management of rhinitis during pregnancy. *Allergy Proc*. 1988; 9(5): 545-554.

12. Busse WW, Holgate ST. Asthma and Rhinitis. *Blackwell Science*. 2008; 1811,1813,1824,1825.

13. Tumini V, Di Placido G, D'Archivio D, Del Giglio Matarazzo A. Hyperplastic gengival lesions in pregnancy. Epidemiology, pathology and clinical aspects. *Minerva Stomatol*. 1998; 47(4): 159-167.

14. Rabinerson D, Kaplan B, Dicker D, Dekel A. Epulis during pregnancy. *Harefuah*. 2002; 141(9): 824-826, 856-857.

15. Orosz M, Szende B, Gábris K. The clinical and pathological symptoms of pregnancy epulis. *Fogorv Sz*. 2007; 100(5): 233-241.

16. Moniaci D, Lojacono A, Anglesio G, Vercellino G, Crupi VM, Garavelli M. The clinical and therapeutic aspects of epulis gravidarum. *Minerva Stomatol*. 1990; 39(12): 1023-1026.

17. Di Placido G, Tumini V, D'Archivio D, Di Peppe G. Gingival hyperplasia in pregnancy. II. Etiopathogenetic fastors and mechanisms. *Minerva Stomatol*. 1998; 47(5): 223-229.