

Mini Review

*Corresponding author

Amégninou Mawuko Yao Adigo, MD

Department of Radiology
Campus Teaching Hospital
Lome 4308, Togo
Tel. (00228)90139800

E-mail: landry05@gmail.com

Volume 2 : Issue 3

Article Ref. #: 1000NOJ2119

Article History

Received: November 11th, 2015

Accepted: December 14th, 2015

Published: December 15th, 2015

Citation

Adigo AMY, Adambounou K, Agbotsou IK, Agoda-Koussema LK, Adjénou KV. Neurovascular conflicts of cerebellopontine angle: a review of the literature. *Neuro Open J.* 2015; 2(3): 99-105. doi: [10.17140/NOJ-2-119](https://doi.org/10.17140/NOJ-2-119)

Copyright:

©2015 Adigo AMY. This is an open access article distributed under the Creative Commons Attribution 4.0 International License (CC BY 4.0), which permits unrestricted use, distribution, and reproduction in any medium, provided the original work is properly cited.

Neurovascular Conflicts of Cerebellopontine Angle: A Review of the Literature

Amégninou Mawuko Yao Adigo^{1*}, Kokou Adambounou¹, Ignéza Komi Agbotsou², Lama Kegdigoma Agoda-Koussema³ and Komlanvi Victor Adjénou¹

¹Department of Radiology, Campus Teaching Hospital, Lome, Togo

²Department of Neurology, du Sylvanus Olympio Teaching Hospital, Lome, Togo

³Department of Radiology, Sylvanus Olympio Teaching Hospital, Lome, Togo

ABSTRACT

The pathology of the cistern of the cerebellopontine angle is primarily the disease of the nervous and vascular structures that it contains and of the meninges that line it. It appears by the Trigeminal Neuralgia (TN), Hemifacial spasm (HFS), and Glossopharyngeal Neuralgia (GN). We have reviewed the anatomy, pathogenesis, diagnostics and therapy of neurovascular conflicts of cerebellopontine angle. The clinical manifestations of the conflict vary according to the affected nerve. The diagnosis is made on the basis of symptoms but need to be confirmed by imaging. Now-a-days, high-fields Magnetic Resonance Imagings (MRIs) are the standard gold diagnostic method but stay impervious in areas or countries that are less medically equipped. The treatment of neurovascular conflicts of cerebellopontine angle is conservative or interventional. The interventional acts constitute the only curative treatments.

KEYWORDS: Neurovascular conflict; Cerebellopontine angle; Glossopharyngeal neuralgia; Trigeminal neuralgia; Hemifacial spasm.

ABBREVIATIONS: CPA: Cerebellopontine angle; TN: Trigeminal Neuralgia; GN: Glossopharyngeal Neuralgia; HFS: Hemifacial spasm; REZ: Root Exit Zone; MRI: Magnetic Resonance Imaging; PICA: Posterior Inferior Cerebellar Artery; AICA: Anterior Inferior Cerebellar Artery; VA: Vertebral Artery; APC: Anterior Piriform Cortex; MeSH: Medical Subject Headings.

INTRODUCTION

The pathology of the cistern of the Cerebellopontine angle (CPA) is primarily the disease of the nervous and vascular structures that it contains and of the meninges that line it. Knowledge of its anatomy and pathogenesis makes it possible to understand and search for a rare pathology, including Trigeminal Neuralgia (TN), Hemifacial spasm (HFS), and Glossopharyngeal Neuralgia (GN). Trigeminal neuralgia consists of brief paroxysms of pain in the facial distribution of the trigeminal nerve, precipitated by stimuli to sensory endings in the trigeminal receptive area.¹ The overall incidence is estimated to be approximately 3-5 cases per year per 100,000 people and increases with age.² HFS is a facial movement disorder characterized by involuntary, unilateral and intermittent twitching of muscles innervated by the facial nerve.³ Like in TN, in more than 95% of the cases HFS is caused by neurovascular compression affecting the Root Exit Zone (REZ) of the facial nerve. Medical imagery, based on the Magnetic Resonance Imaging (MRI), is systematic and enables us to preview the conflict. We have reviewed the anatomy, pathogenesis, diagnostics and therapy of neurovascular conflicts of cerebellopontine angle.

METHODS

The research for this review was data mining through Medline and Google scholar web

sites. The Medical Subject Headings (MeSH) terms were “neurovascular conflict”, “cerebellopontine angle”, “glossopharyngeal neuralgia”, “trigeminal neuralgia” and “hemifacial spasm”. The research included English, French and Russian studies in humans. Articles were included when dealing with anatomy, pathology, pathogenesis, diagnostics or therapy of neurovascular conflicts of CPA. Case series and single cases were included. Articles were excluded when the cause of the conflict were non-neurovascular. Bibliographies of selected articles were screened for additional relevant articles. We used HITACHI (AIRIS Vento) 0,3T. The sequences carried out were: 3DT1, 3DT2 with high resolution and angio-MR-3D TOF. Informed consent was obtained for patients to publish their pictures.

ANATOMICAL RECALL

The CPA is located between the superior and inferior limbs of the cerebellopontine fissure, a V-shaped angular cleft, formed by the cerebellum folding around the pons and middle cerebellar peduncle.^{4,6} The CPA faces the posterior surface of the temporal bone. The middle cerebellar peduncle fills the interval between the superior and inferior limbs of the angle (fissure). The apex of the angle is located laterally where the superior and inferior limbs meet. The fourth through the eleventh cranial nerves are located near or within the angular space between the two limbs.⁷

The surgical cerebello pontine angle (CPA) can then be divided into three spaces comprising each one a nerve, vessels and its distinct pathologies:

- Space of the mixed nerves, inferior external occupied by the mixed nerves IX, X and XI after passing through the jugular foramen. Apart from these, the sigmoid sinus will become gulf of the chin-strap. The artery belonging to this territory is the Posterior Inferior Cerebellar Artery (PICA) born from the ipsilateral vertebral artery;^{7,9}
- Space located coarsely at the medium of the CPA, more internal than the previous, consists of the acousticofacial package (VII and VIII), emanating from the bulbo-protuberantial furrow and engulfing themselves in the porus. It crosses this space in straight line. It is the zone of the Anterior Inferior Cerebellar Artery (AICA) which may form several loops there engaging itself or engaging one of its branches towards the porus and more or less deeply in the meatus. In this space, the presence of a vein is very variable from one subject to another, but one can find with the former face of the cerebellum and sometimes joining directly the petrous sinus, a vein of rather large gauge;^{7,9}
- Third space is located at the anterior tip of the Cerebello-pontine space, well inside of the precedent. It contains the motor and sensitive roots of the Trigeminal nerve or the fifth cranial nerve (CN V) which, being born from the former face of the protuberance, will join the trigeminal cavum.

The other occupying permanent structure of this space is the vein of Dandy, very bulky vein joining the higher petrous sinus. The artery of this territory is the superior cerebellar artery which may often form a loop by contacting the trigeminal nerve.^{7,9}

PATHOLOGY AND PATHOGENESIS

The vertebro-basilar arterial system is never perfectly symmetrical: the unilateral Vertebral Artery (VA) is all the more bulky as its counterpart contralateral hypoplastic. The basilar artery can be also very tortuous. Thus, these large arterial trunks or their branches can come in contact with the various nervous structures of the CPA and produce there a mechanical aggression on both peripheral and central nervous tissues¹⁰ leading to various signs and symptoms of neuralgias. The “ephaptic” theory refers to the development of a true short-circuit electric activity that may occur by time between fibers constituting the nerve.¹⁰ Similarly, a hyper reactivity at the core of the cranial nerves in the brainstem known as the “nuclear” theory¹⁰ may cause the sign and symptoms of these disorders. Nevertheless, there is another unifying theory, the Kindling effect, which says that a central hyper excitability of the cranial nerves does not exclude an associated peripheral origin.¹⁰ In the three cases, the “electric discharges” thus produced are responsible for various pathologies which are, by order of frequency: neuralgia of the trigeminal nerve and the spasm of the hemi face. In 95% of the cases, there is an arterial loop. The seat of the conflict is the REZ (zone of central transition myelin – myelin peripheral) of variable situation from one nerve to another. It seems that smallness of the cisterns of the Anterior Piriform Cortex (APC) and short trigeminal nerve have an impact on the pathogenesis of the essential neuralgia by facilitating the neuro-vascular conflict, particularly among younger patients.¹¹

The major etiology of cerebellopontine neurovascular conflict is the pulsatile compression of a vascular structure within a few millimeters from the origin of the nerve (REZ). Persistence of the phenomenon leads to demyelination of the nerve.¹² Baliagina, has shown that the contact between the superior cerebellar artery and trigeminal nerve trunk cannot lead to the development of trigeminal neuralgia since traumatizing action on the nerve results not from the pulsation of the wall of artery which touches the nerve, but from the strokes of the distal arm of superior cerebellar artery loop, that unbends during each systole and is located at an angle to trigeminal nerve trunk.¹³

The vessels responsible for the conflict vary according to the reached nerve. The most common offending vessel in the Hemifacial spasm (HFS), is the AICA accounting for more than 50% of the cases, while the rest may be caused by the PICA, the basilar artery or veins.¹⁴ HFS caused by developmental venous anomaly is a very rare occurrence. Developmental venous anomaly is the most frequently found cerebral vascular malformation constituting approximately 60% of all vascular lesions.^{15,16} The

role of hypertension in the late onset of HFS have been shown in a family, spanning four generations, using MRI and magnetic resonance angiography.¹⁷ Figures 1 and 2 show respective normal MRI of the cranial nerves VII and V.

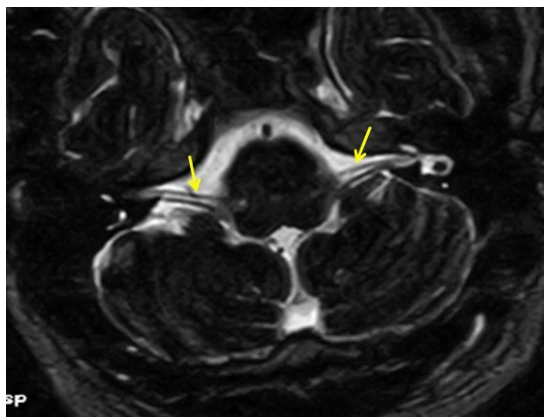


Figure 1: MRI aspect, axial sequence 3DT2 showing a normal nerve VII (yellow arrow).

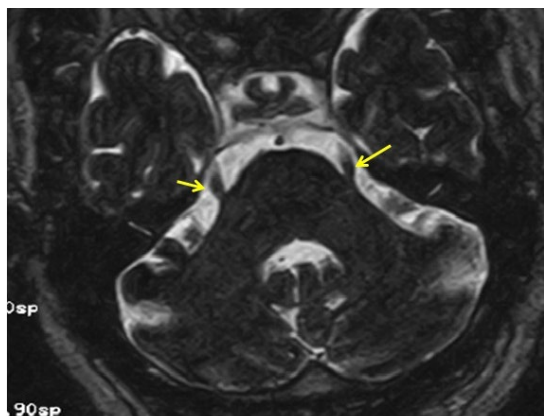


Figure 2: MRI aspect, axial sequence 3DT2 showing a normal nerve V (yellow arrow).

The vessels which most frequently make contact with a trigeminal nerve are the superior cerebellar artery (55-88%), then the AICA, and, in various order, depending on the author, the basilar artery, PICA or a vein embedded in the nerve.^{18,19} Sometimes more than one vessel contacts with the nerve. Some authors think that the offending vessel should dislocate the nerve, while according to others it is enough to find a contact between them.^{18,20} Furthermore, the vessel should touch the nerve at a right or acute angle at the level of the REZ, which means up to 6 mm from the point of sensory root exit from the pons.²¹

CLINICAL MANIFESTATION OF TN, HFS AND GN

TN is recognized by unilateral short-lived, strong, sharp, shooting pains in one or more branches of the fifth cranial nerve. The description of the pain is very important; it must be sharp, shooting, lancinating, and “electric shock”. The pain can be brought on by ordinary stimuli, such as eating, washing, shaving, cold, warmth, and draught.²²

HFS is a facial movement disorder characterized by involuntary, unilateral and intermittent twitching of muscles innervated by the facial nerve.³ The literature describes the frequency of site of onset: the orbicularis oculi muscle in 90%, the cheek in 11% and the perioral region in 10% of cases. Over months to years, the spasms spread gradually to other muscles innervated by the ipsilateral facial nerve. Tonic spasm is generally accompanied by twitching and synkinesis.²³

GN is characterized by paroxysms of repetitive lancinating pain localized unilaterally in the tongue, soft palate, and throat in the lateral and posterior parts of the pharynx, and radiating to the ipsilateral ear. Neuralgia can be triggered by swallowing, coughing, yawning or chewing, and usually lasts seconds or minutes. Vaguglossopharyngeal neuralgia is a very rare type of GN associated with cardiac syncope, arrest and bradycardia caused by vasodepressor reaction of the vagus nerve. Vaguglossopharyngeal neuralgia occurred in only 4 of 217 patients with GN.^{24,25}

IMAGING STUDIES IN TN, HFS AND GN

When the diagnosis of neurovascular conflicts of CPA is made, the patient needs to undergo a MRI scan to exclude specific pathologies such as a tumor or multiple sclerosis, which could cause a secondary TN, HFS or GN. The MRI scan can also be used if there is a suspected compression of the nerve in the posterior cranial fossa. Sometimes the MRI scan is sensitive enough to detect blood vessels that have come in contact with the nerve. Now-a-days, the high MRI fields became inescapable in the diagnosis of neurovascular conflicts of the CPA.²⁶⁻²⁹ However, in areas or countries that are less medically equipped, certain authors think that the low-fields MRI can constitute an alternative to do the proof of the conflict.³⁰ Indeed, in these countries, the access to the care is difficult because of the weak economic capacity of the population and the absence of the most stripped system of insurance. Moreover, the MRI is inalienable and inaccessible. In our low outcome country, we have two low-fields MRI for 6 million inhabitants. It means that efforts remain to be made.

The positive diagnosis of neurovascular conflicts is based on major criteria (neurovascular contact on the level of the REZ, the way how the nerve is deviated in the cistern) and on a minor criterion (remote contact of the REZ). The imagery 3DT2 with high resolution in combination with the angio-MR-3D TOF is a reliable technique to detect the conflict and to predict the grade of compression.^{28,31} Figure 3 shows a crossing with right angle between the right AICA and the ipsilateral facial nerve translating a HFS. Figure 4 shows a crossing enters V and the basilar artery with cisternal way deviation of the nerve.

The classification of Sindou et al (made on a series of trigeminal neuralgia) distinguishes three grades of neurovascular conflicts.³² Grade I corresponds to a simple contact on the

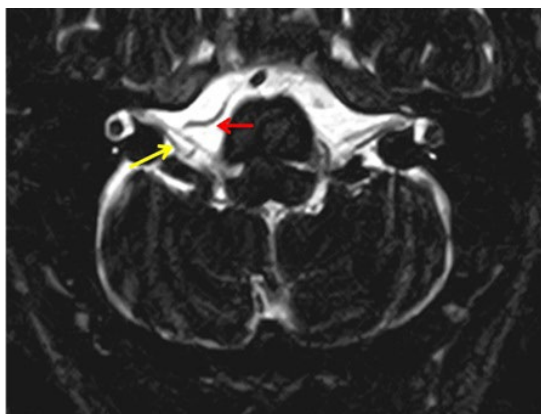


Figure 3: Axial sequences 3DT2 showing a crossing with right angle between the right AICA (red arrow) and the facial nerve ipsilateral (yellow arrow) translating a neurovascular conflict.

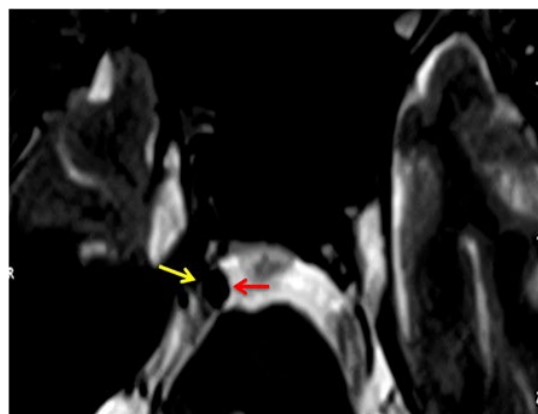


Figure 4: MRI aspect showing a crossing enters V and the basilar artery (red arrow) with cisternal way deviation of the nerve (yellow arrow).

nerve, whereas grade II corresponds to a contact with nerve distortion or displacement. Grade III is associated with indentation on the nerve.

The classification of Adameczyk et al³³ shows the evaluation criteria and the relation between arteries and trigeminal nerve. They distinguish 5 grades:

- 0: Absence of neurovascular contact;
- 1: Artery and nerve come into contact and their axes are parallel;
- 2: Artery and nerve come into contact and they cross each other by a straight or acute angle;
- 3: Contacting artery dislocates the nerve;
- 4: Artery and nerve come into contact, nerve atrophy is visible.

The degree of anatomical relationship between vessel and the cranial nerve VII was graded by Lagalla et al¹⁷ as follows: 0=adjacent; 1=closeness; 2=contact; 3=distortion; 4=indentation.

DIFFERENTIAL DIAGNOSIS

The same symptoms of HFS, TN and GN are common to many disorders such as tumors, arachnoid cysts, epidermoid cysts, neuroglial cysts, facial myokymia, blepharospasm and facial tic.³⁴⁻⁴² Generally, this is not an issue since differential diagnosis is possible by studying the MRI findings and the clinical manifestation of the disease.

TREATMENT OF TN, HFS AND GN

The treatment of neurovascular conflicts of CPA is conservative or interventional. The medication of choice is carbamazepine in trigeminal/glossopharyngeal neuralgia whereas botulinum toxin injection is used in the treatment of hemifacial spasm.

Microvascular decompression is an important procedure for the management of microvascular compression syndromes in the CPA like TN or HFS. The ability to identify the offending vessel is the key to success.^{19,32} The endoscope helps surgeons to identify and understand the responsible conflict in order to treat them. Endoscopy improves visualization of the cranial nerves and allows seeing and understanding the neurovascular conflicts, which are not able to be observed using the microscope alone for certain patients.⁴³ The endoscope is a useful adjunct to microscopic exploration of the cranial nerves in the CPA avoiding significant cerebellar or brainstem retraction. The most important thing for a successful microvascular decompression operation is to remove the offending artery off the nerve. However, if the conflict site failed to be approached after endeavors, a successful microvascular decompression can still be achieved by relocating the offending artery with the guidance of real-time electromyography even without visualization of the confliction.⁴⁴

The efficacy of endovascular treatment for neurovascular conflicts in the CPA caused by intracranial aneurysms and intracranial arteriovenous malformations, including TN, HFS, and GN, have been investigated.⁴⁵ The authors have concluded that endovascular treatment is a feasible and less invasive approach for relief of neurovascular conflicts in the CPA caused by intracranial aneurysms or intracranial arteriovenous malformations and could be considered as a therapeutic option in these situations.⁴⁵

Other techniques for the treatment of TN and GN that were reported in the literature include:

- Treatment achieved with thermocoagulation or in exceptional cases by anesthetic block for diagnostic purposes⁴⁶;
- The optimal radiation dose and target of Gamma-knife radiosurgery for medically refractory idiopathic trigeminal neuralgia⁴⁷;
- Use of Gamma Knife radiosurgery for recurrent glossopharyngeal neuralgia.

ryngeal neuralgia after microvascular decompression⁴⁸;

- Use of endotracheal tube surface electrodes to help delineate the sensory and motor vagal rootlets which may be sacrificed during the surgical treatment of glossopharyngeal neuralgia⁴⁹;
- Use of electrophysiological monitoring on selective rhizotomy of the glossopharyngeal nerve.⁵⁰ Electrophysiological monitoring in selective rhizotomy treating glossopharyngeal neuralgia can improve the efficiency of pain relief and reduce the incidence of complications.

MRI permits to identify the segment of the nerve which is atrophied. Indeed, TN is associated with atrophy of the REZ of the affected nerve compared with the asymptomatic side, but volume loss in different segments of the nerve has very different prognostic implications. Proximal atrophy is associated with vascular compression and correlates with improved outcome following microvascular decompression. However, distal atrophy is associated with a significantly worse outcome after microvascular decompression.⁵¹

CONCLUSION

The clinical manifestations of the neurovascular conflict of the CPA vary according to the affected nerve. High-field MRI remains the gold standard method in their diagnosis; but alternatively, the low-field MRI might be similarly useful. Treatment of TN, HFS and GN is initially by medicine but the intractable conditions may need interventional acts which constitute the only curative treatment.

AUTHORS CONTRIBUTIONS

All authors have contributed to the conception and design of the manuscript. They have been involved in drafting and revising the manuscript. All authors read and approved the final manuscript.

COMPETING INTEREST

The authors declare that they have no competing interests.

REFERENCES

1. Joffroy A, Levivier M, Massager N. Trigeminal neuralgia: pathophysiology and treatment. *Acta Neurol Belg.* 2001; 101: 20-25.
2. Kitt CA, Gruber K, Davis M, Woolf CJ, Levine JD. Trigeminal neuralgia: opportunities for research and treatment. *Pain.* 2000; 85: 3-7. doi: [10.1016/S0304-3959\(99\)00310-3](https://doi.org/10.1016/S0304-3959(99)00310-3)
3. Ruiz DS, Yilmaz H, Gailloud P. Cerebral developmental venous anomalies: current concepts. *Ann Neurol.* 2009; 66: 271-283. doi: [10.1002/ana.21754](https://doi.org/10.1002/ana.21754)
4. Rhoton AL Jr. Cerebellopontine angle and the retrosigmoid approach. *Neurosurgery.* 2007; 61(Suppl 4): 175-192.
5. Rhoton AL Jr. Cerebellum and fourth ventricle. *Neurosurgery.* 2000; 47(Suppl 3): S7-S27.
6. Rhoton AL Jr. The cerebellopontine angle and posterior fossa cranial nerves by the retrosigmoid approach. *Neurosurgery.* 2000; 47(Suppl 3): S93-S129.
7. Samii M, Gerganov V. Microsurgical anatomy of the cerebellopontine angle by the retrosigmoid approach. Surgery of cerebellopontine lesions. *Springer Berlin Heidelberg.* 2013; 9-72. doi: [10.1007/978-3-642-35422-9_2](https://doi.org/10.1007/978-3-642-35422-9_2)
8. Cross J, Coles A. The cerebellopontine angle. *ACNR.* 2002; 2(3): 16-17.
9. Sarrazin J-L, Marsot-Dupuch K, Chañas A. Angle ponto cerebellar pathology. (French) *J Radiol.* 2006; 87: 1765-1782.
10. Bonafé A. Neurovascular conflicts APC. (French) *J Radiol.* 2000; 81; 694-701.
11. Parise M, Acioly MA, Ribeiro CT, Vincent M, Gasparetto EL. The role of the cerebellopontine angle cistern area and trigeminal nerve length in the pathogenesis of trigeminal neuralgia: a prospective case-control study. *Acta Neurochir (Wien).* 2013; 155(5): 863-868. doi: [10.1007/s00701-012-1573-0](https://doi.org/10.1007/s00701-012-1573-0)
12. Campos-Benitez M, Kaufmann AM. Neurovascular compression findings in hemifacial spasm. *J Neurosurg.* 2008; 109: 416-420. doi: [10.3171/JNS/2008/109/9/0416](https://doi.org/10.3171/JNS/2008/109/9/0416)
13. Baliazina EV. Topographic anatomical relationship between the trigeminal nerve trunk and superior cerebellar artery in patients with trigeminal neuralgia. *Morfologiya.* 2009;136(5): 27-31.
14. Samii M, Gunther T, Iaconetta G, Muehling M, Vorkapic P, Samii A. Microvascular decompression to treat hemifacial spasm: long-term results for a consecutive series of 143 patients. *Neurosurgery.* 2002; 50: 712-718.
15. Amin-Hankani S. Venous Angiomas. *Curr Treat Options Cardiovasc Med.* 2011; 13(3): 240-246. doi: [10.1007/s11936-011-0118-9](https://doi.org/10.1007/s11936-011-0118-9)
16. Chiamonte R, Bonfiglio M, D'Amore A, Chiamonte I. Developmental venous anomaly responsible for hemifacial spasm. *Neuroradiol J.* 2013; 26(2): 201-207. doi: [10.1177/197140091302600210](https://doi.org/10.1177/197140091302600210)

17. Lagalla G, Logullo F, Di Bella P, Haghighipour R, Provinciali L. Familial hemifacial spasm and determinants of late onset. *Neurol Sci.* 2010; 31(1): 17-22. doi: [10.1007/s10072-009-0153-4](https://doi.org/10.1007/s10072-009-0153-4)
18. Yoshino N, Akimoto H, Yamada I, et al. Trigeminal neuralgia: evaluation of neuralgic manifestation and site of neurovascular compression with 3D CISS MR imaging and MR angiography. *Radiology.* 2003; 228(2): 539-545.
19. Sindou M, Howedy T, Acevedo G. Anatomical observations during microvascular decompression for idiopathic trigeminal neuralgia (with correlations between topography of pain and site of the neurovascular conflict): prospective study in a series of 579 patients. *Acta Neurochir (Wien).* 2002; 144(1): 1-12.
20. Yamakami I, Kobayashi E, Hirai S, Yamaura A. Preoperative assessment of trigeminal neuralgia and hemifacial spasm using constructive interference in steady state-three-dimensional Fourier transformation magnetic resonance imaging. *Neurol Med Chir (Tokyo).* 2000; 40(11): 545-555. doi: [10.2176/nmc.40.545](https://doi.org/10.2176/nmc.40.545)
21. Borges A. Trigeminal neuralgia and facial nerve paralysis. *Eur Radiol.* 2005; 15: 511-533. doi: [10.1007/s00330-004-2613-9](https://doi.org/10.1007/s00330-004-2613-9)
22. van Kleef M, van Genderen WE, Narouze S, et al. Trigeminal neuralgia. *Pain Practice.* 2009; 9(4): 252-259.
23. Lee SH, Rhee BR, Choi SK. Cerebellopontine angle tumours causing hemifacial spasm: types, incidence, and mechanism in nine reported cases and literature review. *Acta Neurochir.* 2010; 152: 1901-1908.
24. Esaki T, Osada H, Nakao Y, et al. Surgical management for glossopharyngeal neuralgia associated with cardiac syncope: two case reports. *British Journal of Neurosurgery.* 2007; 21(6): 599-602. doi: [10.1080/02688690701627138](https://doi.org/10.1080/02688690701627138)
25. Rushton JG, Stevens JC, Miller RH. Glossopharyngeal (vagoglossopharyngeal) neuralgia: a study of 217 cases. *Arch Neurol.* 1981; 38(4): 201-205. doi: [10.1001/archneur.1981.00510040027002](https://doi.org/10.1001/archneur.1981.00510040027002)
26. Anderson VC, Berryhill PC, Sandquist MA, Ciaverella DP, Nesbit GM, Burchiel KJ. High-resolution three-dimensional magnetic resonance angiography and three-dimensional spoiled gradient-recalled imaging in the evaluation of neurovascular compression in patients with trigeminal neuralgia: a double blind pilot study. *Neurosurg.* 2006; 58 (4): 666-673.
27. Benes L, Shiratori K, Gurschi M, et al. Is preoperative high-resolution magnetic resonance imaging accurate in predicting neurovascular compression in patients with trigeminal neuralgia: a single-blind study. *Neurosurg Rev.* 2005; 28: 131-136. doi: [10.1007/s10143-004-0372-3](https://doi.org/10.1007/s10143-004-0372-3)
28. Leal PRL, Froment J-C, Sindou M. MRI sequences for the detection of neurovascular origin conflicts trigeminal neuralgia and predictive value for characterizing the conflict (in particular the degree of vascular compression). (French) *Neurosurgery.* 2010; 56(1): 43-49.
29. Elaini S, Miyazaki H, Rameh C, Deveze A, Magnan J. Correlation between magnetic resonance imaging and surgical findings in vasculo-neural compression syndrome. *Int Adv Otol.* 2009; 5(Suppl 3): 1-23.
30. Adigo AMY, Adjénou KV, Agoda-Koussema LK, et al. Neurovascular conflicts of cerebellar pontine angle: about three cases in Lome. (French) *J Afr Imag Méd.* 2015; 7(1): 79-85.
31. Chays A, Labrousse M, Bazin A, Pierot L, Rousseaux P. Neurovascular conflicts in cerebellopontine angle. Pathogenesis and surgical treatment. (French) *e-memories of the National Academy of Surgery.* 2010; 9(2): 95-99.
32. Sindou M, Leston J, Decullier E, Chapuis F. Microvascular decompression for trigeminal neuralgia: long-term effectiveness and prognostic factors in a series of 362 consecutive patients with clear-cut neurovascular conflicts who underwent pure decompression. *J Neurosurg.* 2007; 107 (6): 1144-1153.
33. Adamczyk M, Bulski T, Sowińska J, Furmanek MI, Bekieśńska-Figatowska M. Trigeminal nerve-artery contact in people without trigeminal neuralgia: MR study. *Med Sci Monit.* 2007; 13(Suppl 1): 38-43.
34. Ruiz-Juretschke F, Vargas A, González-Rodríguez R, Garcia-Leal R. Hemifacial spasm caused by a cerebellopontine angle arachnoid cyst: case report and literature review. *Neurocirugia (Astur).* 2015; 307-301. doi: [10.1016/j.neucir.2015.05.001](https://doi.org/10.1016/j.neucir.2015.05.001)
35. Misawa S, Kuwabara S, Ogawara K, et al. Abnormal muscle responses in hemifacial spasm: F waves or trigeminal reflexes? *J Neurol Neurosurg Psychiatry.* 2006; 77: 216-218. doi: [10.1136/jnnp.2005.073833](https://doi.org/10.1136/jnnp.2005.073833)
36. Prasanna K, Manoj B, Hajime Y, et al. Cerebellopontine angle endodermal cyst presenting with hemifacial spasm. *Brain Tumor Pathol.* 2011; 28: 371-374. doi: [10.1007/s10014-011-0042-4](https://doi.org/10.1007/s10014-011-0042-4)
37. Mastronardi L, Taniguchi R, Caroli M, Crispo F, Ferrante L, Fukushima T. Cerebellopontine angle arachnoid cyst: a case of hemifacial spasm caused by an organic lesion other than neurovascular compression: case report. *Neurosurgery.* 2009; 65: E1205. doi: [10.1227/01.NEU.0000360155.18123.D1](https://doi.org/10.1227/01.NEU.0000360155.18123.D1)
38. Alemdar M. Epidermoid cyst causing hemifacial spasm epidermoid cyst in cerebellopontine angle presenting with hemifa-

- cial spasm. *J Neurosci Rural Pract.* 2012; 3(3): 344-346. doi: [10.4103/0976-3147.102618](https://doi.org/10.4103/0976-3147.102618)
39. Khan Afridi EA, Khan SA, et al. Frequency of cerebellopontine angle tumours in patients with trigeminal neuralgia. *J Ayub Med Coll Abbottabad.* 2014; 26(3): 331-333.
40. Shenouda EF, Moss TH, Coakham HB. Cryptic cerebellopontine angle neuroglial cyst presenting with hemifacial spasm. *Acta Neurochir (Wien).* 2005; 147: 787-789. doi: [10.1007/s00701-005-0514-6](https://doi.org/10.1007/s00701-005-0514-6)
41. Cenzato M, Stefini R, Ambrosi C, Latronico N, Milani D. Surgical resolution of trigeminal neuralgia due to intra-axial compression by pontine cavernous angioma. *World Neurosurg.* 2010; 74(4-5): 544-546. doi: [10.1016/j.wneu.2010.03.035](https://doi.org/10.1016/j.wneu.2010.03.035)
42. Han IB, Chang JH, Chang JW, Huh R, Chung SS. Unusual causes and presentations of hemifacial spasm. *Neurosurgery.* 2009; 65(1): 130-137. doi: [10.1227/01.NEU.0000348548.62440.42](https://doi.org/10.1227/01.NEU.0000348548.62440.42)
43. Duntze J, Litré CF, Eap C, et al. Endoscopy input for microvascular decompression in the cerebellopontine angle: about 27 cases. (French) *Neurosurgery.* 2011; 57(2): 68-72.
44. Zhu J, Li ST, Zhong J, et al. Microvascular decompression for hemifacial spasm. *J Craniofac Surg.* 2012; 23(5): 1385-1387.
45. Li C, Li Y, Jiang C, Wu Z, Wang Y, Yang X. Remission of neurovascular conflicts in the cerebellopontine angle in interventional neuroradiology. *J Neurointerv Surg.* 2014. doi: [10.1136/neurintsurg-2014-011500](https://doi.org/10.1136/neurintsurg-2014-011500)
46. Dinichert A, Serrie A, Thurel C. Treatment of essential glossopharyngeal neuralgia by thermocoagulation or anesthetic blocking ganglion Andersch. (French) *Pain: Evaluation-Diagnostic-Treatment.* 2005; 6(1): 35-41.
47. Li P, Wang W, Liu Y, Zhong Q, Mao B. Clinical outcomes of 114 patients who underwent Gamma-knife radiosurgery for medically refractory idiopathic trigeminal neuralgia. *Journal of Clinical Neuroscience.* 2012; 19(1): 71-74. doi: [10.1016/j.jocn.2011.03.020](https://doi.org/10.1016/j.jocn.2011.03.020)
48. Stanic S, Franklin SD, Pappas CT, Stern RL. Gamma knife radiosurgery for recurrent glossopharyngeal neuralgia after microvascular decompression. *Stereotact Funct Neurosurg.* 2012; 90: 188-191. doi: [10.1159/000338089](https://doi.org/10.1159/000338089)
49. Harries AM, Dong CCJ, Honey CR. Use of endotracheal tube electrodes in treating glossopharyngeal neuralgia: technical note. *Stereotact Funct Neurosurg.* 2012; 90: 141-144. doi: [10.1159/000335714](https://doi.org/10.1159/000335714)
50. Zhang W, Chen M, Zhang W, Chai Y. Use of electrophysiological monitoring in selective rhizotomy treating glossopharyngeal neuralgia. *Journal of Cranio-Maxillofacial Surgery.* 2014; 42(5): e182-e185. doi: [10.1016/j.jcms.2013.08.004](https://doi.org/10.1016/j.jcms.2013.08.004)
51. Duan Y, Sweet J, Munyon C, Miller J. Degree of distal trigeminal nerve atrophy predicts outcome after microvascular decompression for type 1a trigeminal neuralgia. *J Neurosurg.* 2015; 123(6): 1512-1518. doi: [10.3171/2014.12.JNS142086](https://doi.org/10.3171/2014.12.JNS142086)