

Case Report

*Corresponding author Khadija Warfa, MD

Gynecologic Oncology Fellow
University of Calgary &
Tom Baker Cancer Centre
1331 29 Street NW
Calgary, Alberta, T2N 4N2
Canada
Tel. +254 722 143679
E-mail: jwarfa@yahoo.com

Volume 2 : Issue 1

Article Ref. #: 1000GOROJ2108

Article History

Received: April 16th, 2015

Accepted: May 8th, 2015

Published: May 11th, 2015

Citation

Warfa K, Köbel M, Ghatage P, Nelson G. Low-grade serous carcinoma – the clinical challenge. *Gynecol Obstet Res Open J.* 2015; 2(1): 35-40. doi: [10.17140/GOROJ-2-108](https://doi.org/10.17140/GOROJ-2-108)

Copyright

©2015 Warfa K. This is an open access article distributed under the Creative Commons Attribution 4.0 International License (CC BY 4.0), which permits unrestricted use, distribution, and reproduction in any medium, provided the original work is properly cited.

Low-Grade Serous Carcinoma – The Clinical Challenge

Khadija Warfa^{1*}, Martin Köbel², Prafull Ghatage³ and Gregg Nelson³

¹Gynecologic Oncology Fellow, University of Calgary & Tom Baker Cancer Centre, 1331 29 Street NW, Calgary Alberta, T2N 4N2, Canada

²Gynecologic Pathologist, Calgary laboratory services, University of Calgary, Calgary, Alberta, Canada

³Gynecologic Oncologist, Division of Gynecologic Oncology, Tom Baker Cancer Centre, Calgary, Alberta, Canada

ABSTRACT

Low-grade serous carcinoma is one of the five major histological types of ovarian carcinoma associated with a specific biology. We reviewed three cases from our institution to demonstrate the variable clinical course and provide a brief review on this disease entity.

KEYWORDS: Low-grade serous carcinoma; High-grade serous carcinoma; Ovarian cancer.

INTRODUCTION

In 1996, Burks et al. described a peculiar micropapillary serous tumor.¹ Eighteen years later, the 2014 WHO separated low-grade serous carcinomas (LGSC) from high-grade serous carcinoma (HGSC) as individual histological type rather than a being just another level in the grading system. While both serous carcinomas share the same cell lineage (indicated by ubiquitous PAX8 and WT1 expression), this separation was based on distinct oncogenic pathways, histopathology and clinical behavior.^{2,3} The mean age of women diagnosed with LGSC is 55 years, which is six years younger than HGSC.⁴ LGSC account for only 4% of ovarian carcinomas, but LGSC represents the second most common histotype presenting with advanced disease after HGSC. Still even in the high stage setting, the ratio of LGSC to HGSC is 1:16.⁵ In 2004, Shih and Kurman proposed the dualistic model of serous carcinogenesis.⁶ The majority of LGSC show mutations in *KRAS* or *BRAF* mutations and a lower proliferation compared to HGSC.⁷ TP53 mutations are almost a defining feature for HGSC and should not be seen in LGSC. Hence, *KRAS/BRAF/TP53* mutations are so specific that they can be used diagnostically.^{8,9} Yet a diagnosis can often be made with high reproducibility based on simple morphology using the degree of nuclear atypia in conjunction with architectural patterns and ancillary immunohistochemistry.¹⁰ While HGSC are a focus of research,¹¹ there are relatively few studies of LGSC and no recurrent alterations beyond *KRAS* and *BRAF* have been identified.¹²⁻¹⁴

LGSC are commonly associated with metachronous or synchronous serous borderline tumors/Atypical Proliferative Serous Tumors (APST). APST display two distinct morphological phenotypes: a hierarchical branching pattern seen in the conventional type (not further specified) or a micropapillary pattern seen in the micropapillary variant. Seven percent of patients diagnosed with APST may subsequently develop LGSC. A recent study investigating five paired metachronous APST and LGSC showed that the same *KRAS* mutation was already present in three preceding APST, although only in minor subclones by the use of deep/sensitive sequencing, providing evidence that some metachronous APST and LGSC are clonally related.¹³ Risk factors for progression to LGSC include APST presenting at higher stage, showing microinvasion or micropapillary variant.¹⁵ The micropapillary variant shows an expression pro-

file more closely related to LGSC compared to the conventional variant and could be therefore considered as the noninvasive precursor of LGSC.¹⁶ LGSC are commonly associated with synchronous APST. A diagnosis of LGSC is made if frank invasion is present. Frank invasion is to be distinguished from microinvasion by a quantitative threshold of an invasive area greater than 5 mm in extent. The classic histological pattern of invasion displays micropapillae in non-epithelial lined cleft-like spaces but alternative patterns, such as macropapillary, solid, glandular with or without extensive psammomatous calcifications (“psammocarcinoma”), can occur.¹⁷ The location of frank invasion can be variable including sites such as ovary, peritoneum or lymph nodes.¹⁸ Noteworthy, assessment of invasion in the peritoneum (“invasive implants”) *versus* noninvasive implants of APST quality is one of the most challenging decisions to be made in gynecological pathology.

Chemotherapy administration is constantly refined resulting in increased efficacy for HGSC.¹⁹ A series of studies from MDACC reported that LGSC are only occasionally responding to chemotherapy and highlight the importance of surgery.²⁰⁻²² A recent study from a population-based series challenged the assumption that LGSC usually have a more favorable outcome than HGSC.^{23,24} We recently observed a variable clinical course of women diagnosed with LGSC. To illustrate, we present three recent cases from our institution. Institution review from Ethics Committee was obtained for a larger review on outcomes of low-grade serous carcinoma of the ovary.

Case A

A 63-year old woman was followed up since 1995. She underwent primary optimal debulking surgery; she was staged as a stage IIIC, well differentiated papillary serous adenocarcinoma of the ovary. On contemporary pathology review the tumor showed 7 mm frank invasion in form of macropapillae in a background of serous borderline tumor, micropapillary variant with multiple other foci of microinvasion. Postoperatively she received adjuvant chemotherapy with six cycles of single agent cisplatin at 60 mg/m², she tolerated treatment well and remained in remission. She recurred nine years later and we managed her with neoadjuvant chemotherapy, three cycles of Q21 carboplatin at AUC of 5 and Paclitaxel 175 mg/m² and secondary debulking procedure. Optimal debulking was achieved, which was followed with adjuvant chemotherapy with three cycles of Q 21 carboplatin at AUC of 5 and paclitaxel 175 mg/m² that was tolerated well. She remained in remission for two years. A second recurrence in 2006 was managed with two lines of chemotherapy, initially offered liposomal doxorubicin at 40 mg/m² every 4 weeks, after 2 cycles this was discontinued due to intolerable side effects. We subsequently switched her to single agent topotecan at 1.25mg/m² for 5 days Q 21 for four cycles. The patient opted out of follow up and self medicated with dichloroacetic acid and thalidomide, she remained stable for two years. A third recurrence presented as bowel obstruction. Following failure of initial conservative management, surgical management with a right hemi-

colectomy followed with three lines of adjuvant chemotherapy with single agent gemcitabine at 1 g/m² every three weeks for 6 cycles, tolerated treatment well but due to progressive disease she was enrolled in a clinical trial unfortunately she progressed on the trial she was offered single agent weekly paclitaxel at 80 mg /m² for 6 cycles. Following another two years in remission, she presented with a forth recurrence that was managed by excision of a left rectus muscle tumor, retroperitoneal tumor and partial cystectomy and adjuvant chemotherapy with six cycles of carboplatin at AUC of 5 and paclitaxel 175 mg/m², she tolerated treatment well. Unfortunately she developed progressive disease that caused her to succumb 18 years after the initial diagnosis. On pathology review, all her recurrences were classic LGSC retaining minor areas of a macropapillary pattern seen in the initial case (Figure 1A).

Case B

A 55-year old, initially presented with advanced ovarian cancer and she underwent a total abdominal hysterectomy; bilateral salpingo oophorectomy and omentectomy for a stage IIC papillary serous ovarian cancer, optimally debulked, she received six cycles of adjuvant treatment with chemotherapy with six cycles of Q 21 carboplatin at AUC of 5 and paclitaxel 175 mg/m², she tolerated treatment well. After five years of remaining in remission she was discharged from the cancer center and followed up by her family physician. Seven years after the initial treatment she developed a 2 cm swelling in her abdominal wall, which was followed radiologically. Five years later it was noted to double in size. A biopsy from this revealed serous carcinoma. She had surgical debulking to microscopic disease and is currently receiving adjuvant chemotherapy with carboplatin at AUC of 5 and paclitaxel 175mg/m² (Figure 1B).

Case C

A 33-year old woman presented with abdominal pain, weight loss and menstrual irregularities. Medical report from her home country indicated that she underwent a left salpingo-oophorectomy and omentectomy and postoperatively adjuvant chemotherapy for an ovarian tumor. On review at our institution, she presented with increasing abdominal girth, pain and shortness of breath. A Computerized Topographical (CT) scan revealed a left sided pleural effusion, free intraperitoneal fluid and an ill defined right adnexal mass. Cytology from ascitic fluid revealed metastatic adenocarcinoma of ovarian origin. She received three cycles of neoadjuvant chemotherapy with three cycles of carboplatin at AUC of 5 and paclitaxel 175 mg/m² followed by an interval debulking procedure where microscopic debulking was achieved. Pathology from the surgical specimen was reported as LGCS of the ovary (Figure 1C, and 1D). Subsequently, she received six cycles of adjuvant chemotherapy with six cycles of carboplatin AUC of 5 and paclitaxel 175 mg/m². Soon after completion of adjuvant treatment she developed progressive disease and was started on second-line chemotherapy, liposomal doxorubicin 40 mg/m² Q28, unfortunately she died

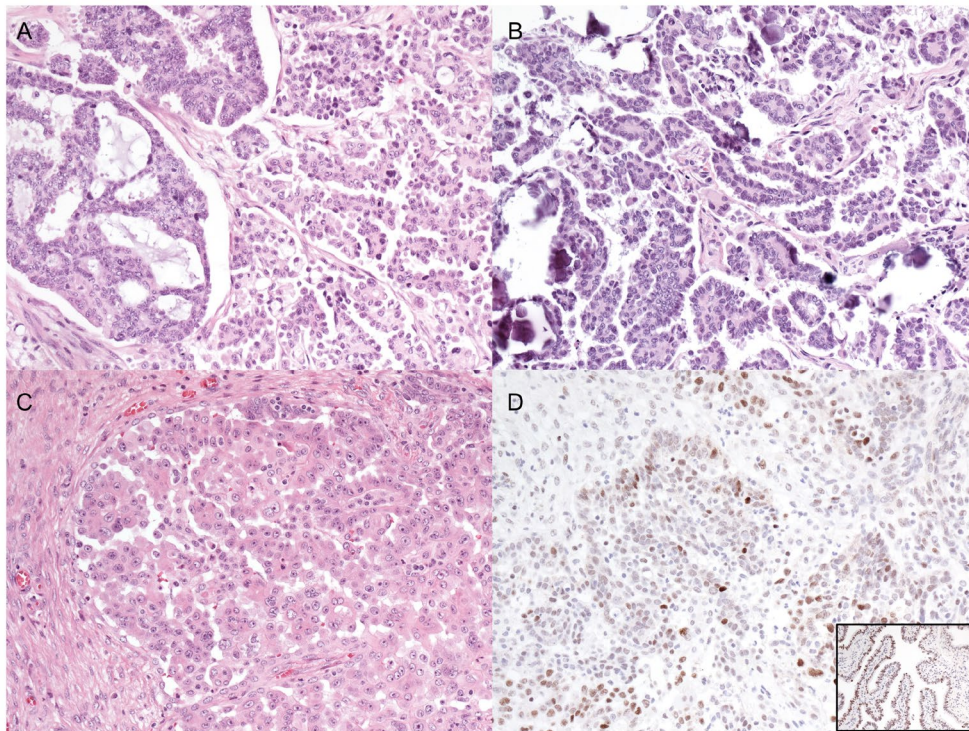


Figure 1: (A) Low-grade serous carcinoma with typical micropapillary low power architecture on the right and variant pattern on the left: so called micropapillary inside out pattern. In both pattern papillae are surrounded by non-epithelial lined cleft-like spaces. The nuclei are monomorphic lacking significant nuclear atypia (case A). (B) Low-grade serous carcinoma with typical micropapillary low power architecture and abundant psammoma bodies, which are often seen in low-grade serous carcinoma (so called psammocarcinoma being the extreme variant). The nuclei are monomorphic lacking significant nuclear atypia (case B). (C) Low-grade serous carcinoma with typical micropapillary low power architecture and monomorphic nuclei (case C). (D) TP53 immunohistochemistry on specimen from case C displaying TP53 wild type pattern. This pattern is characterized by a heterogeneous expression of TP53 with variable intensity in 1-70% of tumor nuclei similar to normal fallopian tube (inset). This pattern is distinct from aberrant TP53 expression seen in high-grade serous carcinomas indicative of underlying TP53 mutation, which is characterized by either diffuse overexpression (>70% of nuclei displaying strong expression) or complete absence (lack of any expression with positive internal control from lymphocytes and fibroblasts, not shown).

within eleven months of initial diagnosis and treatment (Table 1).

	Case A	Case B	Case C
Age at diagnosis	48	55	33
Stage at diagnosis	IIIC	IIC	IIIC
Time to first recurrence (months)	113	175	Progression under adjuvant therapy
Time to from diagnosis to death (months)	227	Alive with disease	11
Time to from first recurrence to death (months)	114	Alive with disease	NA
WT1	Diffuse	Diffuse	Diffuse
TP53	Wild type	Wild type	Wild type
P16	Patchy	Patchy	Patchy
ER	Diffuse	Diffuse	Diffuse
PR	Negative	Diffuse	Negative

Table 1: Case characteristics.

DISCUSSION

LGSC has been traditionally viewed as indolent disease compared to HGSC. In a recent population based series, however, the long-term outcome of patients diagnosed with LGSC was similar to HGSC.²⁵ What could be the reason for those dif-

ferences? We illustrated a variable clinical course. Two of our cases showed a long term survival despite recurrent disease but the third case showed an aggressive course. Hence, could above cited studies could have had a selection bias towards indolent or aggressive cases? Currently, there are no reliable criteria to assess prognosis of LGSC. Strong/diffuse progesterone receptor expression has been suggested as favorable prognostic marker (RR=0.39, 95% confidence interval 0.018-0.86).⁴ The G12V KRAS mutation was associated with unfavorable outcome in a small series.¹³ Whether these biomarker play out in clinical practice requires further validation.

LGSC is uncommon and only recently established. In a interobserver reproducibility study of eight pathologists from European Nordic countries, consistent diagnosis of LGSC was a major issue.²⁶ The main differential diagnoses are against APST, endometrioid carcinoma and HGSC. In a large population based series from Denmark, only 30% of LGSC were confirmed on review but 12% of LGSC were reclassified to HGSC and 50% to APST.²⁴ A favorable outcome of LGSC can be seen in cohorts that are contaminated by misclassified APST. This challenge is illustrated by our first case. The initial tumor consisted predominantly of APST with foci of frank invasion just exceeding the 5 mm threshold representing an example for a diagnosis of an LGSC at the lower end of the spectrum. All recurrences of this

case, however, were bona fida LGSC (Figure 1A). Even if the initial diagnosis is disputed, the survival from the first recurrence was still greater than nine years. Another diagnostic issue is illustrated with the third case that showed solid pattern in addition to the typical micropapillary features (Figure 1C). This solid pattern raised the differential diagnosis of HGSC. HGSC ubiquitously harbor *TP53* mutations and contemporary *TP53* immuno-histochemistry serves as a good surrogate for the *TP53* mutational statuses. There was no evidence for *TP53* mutation by immune-histochemistry (Figure 1D).

Clinical management greatly influences the course of the disease. The MDACC group has long been advocating for an aggressive surgical approach, which yields a relative good outcome in their patient series.²³ Treatment alternatives are limited. Chemotherapy can induce stable disease and achieve disease control, but responses are rare. Similarly, hormonal therapy may contribute to disease control but response rates are low (9%) and may depend on the PR receptor status.²⁷ In contrast to breast cancer, the optimal cut-off for PR expression as prognostic or predictive marker for LGSC is not established.²⁸ PR expression is present in most LGSC but only a quarter expresses high levels of PR and only high level expression is associated with unfavorable outcome.^{4,29}

Inhibitors targeting the key aberrant pathway in LGSC have entered early clinical trials (e.g. EUDRACT Number: 2013-000277-72). Selumetinib, a MEK 1/2 inhibitor, was studied in a phase 2 trial of 52 women with recurrent LGSC achieving a complete or partial response rate of 15% and 65% of patients had stable disease.³⁰ The responses were not related to the mutational status of *KRAS* or *BRAF* raising the question whether other functionally redundant aberrations in the MAPK pathway were present in cases wild type for *KRAS* or *BRAF* that responded. It also suggests that some LGSC with *KRAS* or *BRAF* mutation that did not respond may have additional alterations inducing primary resistance to MEK inhibitors. Further comprehensive molecular assessment combining different platform (whole genome sequencing, copy number analysis, methylome, micro RNAs) on contemporarily classified cases with detailed clinical follow up is required to increase our understanding of this uncommon disease.

We started to manage LGSC differently from HGSC. In the initial diagnostic setting, we prefer upfront surgery for LGSC while neoadjuvant chemotherapy is an option for HGSC. Although there are clinical hints for LGSC (younger age, lower CA125),³¹ we push for a tissue based diagnosis preferentially an omental core biopsy. These biopsies have the advantage that immune-histochemical markers (panel of PAX8, WT1, *TP53*, p16) can be more reliably compared to cell blocks obtained from ascites.⁶ Because LGSC has only recently been recognized, we will see recurrences of what was diagnosed well-differentiated serous carcinoma in the past for the upcoming years. Alert should be raised if the patients are younger, presents with multiple or late recurrences that do not respond to chemotherapy.

However, this can overlap with patients with HGSC carrying a *BRCA* germline mutation that that acquired resistance to chemotherapy. The decision between recurrence surgery for LGSC and additional lines of chemotherapy for HGSC may require a contemporary tissue based diagnosis.

In summary, LGSC is a separate disease entity with variable clinical outcome. The variable outcome depends on the biology of individual cases (improved understanding requires comprehensive molecular characterization beyond MAPK pathway), the clinical management (the relative resistance to chemotherapy leaves aggressive surgery as the primary treatment), and diagnostic accuracy (to improve diagnostic accuracy, ancillary tests should be judiciously applied).

CONFLICTS OF INTEREST

All authors have no conflict of interest to declare.

REFERENCES

- Burks RT, Sherman ME, Kurman RJ. Micropapillary serous carcinoma of the ovary. A distinctive low-grade carcinoma related to serous borderline tumors. *Am J Surg Pathol.* 1996; 20(11): 1319-1330.
- Kurman RJ, Carcangiu ML, Herrington CS, Young RH. WHO Classification of Tumours of Female Reproductive Organs. 4th ed; MD, USA: WHO, IARC; 2014: 6.
- Köbel M, Kalloger SE, Lee S, et al. Biomarker-based ovarian carcinoma typing: a histologic investigation in the ovarian tumor tissue analysis consortium. *Cancer Epidemiol Biomarkers Prev.* 2013; 22(10): 1677-1686. doi: [10.1158/1055-9965.EPI-13-0391](https://doi.org/10.1158/1055-9965.EPI-13-0391)
- Sieh W, Köbel M, Longacre TA, et al. Hormone-receptor expression and ovarian cancer survival: an Ovarian Tumor Tissue Analysis consortium study. *Lancet Oncol.* 2013; 14(9): 853-862. doi: [10.1016/S1470-2045\(13\)70253-5](https://doi.org/10.1016/S1470-2045(13)70253-5)
- Köbel M, Kalloger SE, Huntsman DG, et al. Differences in tumor type in low-stage versus high-stage ovarian carcinomas. *Int J Gynecol Pathol.* 2010; 29(3): 203-211. doi: [10.1097/PGP.0b013e3181c042b6](https://doi.org/10.1097/PGP.0b013e3181c042b6)
- Shih IeM, Kurman RJ. Ovarian tumorigenesis: a proposed model based on morphological and molecular genetic analysis. *Am J Pathol.* 2004; 164(5): 1511-1518. doi: [10.1016/S0002-9440\(10\)63708-X](https://doi.org/10.1016/S0002-9440(10)63708-X)
- Singer G, Oldt R 3rd, Cohen Y, et al. Mutations in *BRAF* and *KRAS* characterize the development of low-grade ovarian serous carcinoma. *J Natl Cancer Inst.* 2003; 95(6): 484-486. doi: [10.1093/jnci/95.6.484](https://doi.org/10.1093/jnci/95.6.484)

8. Ahmed AA, Etemadmoghadam D, Temple J, et al. Driver mutations in TP53 are ubiquitous in high grade serous carcinoma of the ovary. *J Pathol.* 2010; 221(1): 49-56. doi: [10.1002/path.2696](https://doi.org/10.1002/path.2696)
9. Altman AD, Nelson GS, Ghatage P, et al. The diagnostic utility of TP53 and CDKN2A to distinguish ovarian high-grade serous carcinoma from low-grade serous ovarian tumors. *Mod Pathol.* 2013; 26(9): 1255-1263. doi: [10.1038/modpathol.2013.55](https://doi.org/10.1038/modpathol.2013.55)
10. Malpica A, Deavers MT, Lu K, et al. Grading ovarian serous carcinoma using a two-tier system. *Am J Surg Pathol.* 2004; 28(4): 496-504.
11. Helland A, Anglesio MS, George J, et al. Deregulation of MYCN, LIN28B and LET7 in a molecular subtype of aggressive high-grade serous ovarian cancers. *PLoS One.* 2011; 6(4): e18064. doi: [10.1371/journal.pone.0018064](https://doi.org/10.1371/journal.pone.0018064)
12. Jones S, Wang TL, Kurman RJ, et al. Low-grade serous carcinomas of the ovary contain very few point mutations. *J Pathol.* 2012; 226(3): 413-420. doi: [10.1002/path.3967](https://doi.org/10.1002/path.3967)
13. Tsang YT, Deavers MT, Sun CC, et al. KRAS (but not BRAF) mutations in ovarian serous borderline tumor are associated with recurrent low-grade serous carcinoma. *J Pathol.* 2013; 231(4): 449-456. doi: [10.1002/path.4252](https://doi.org/10.1002/path.4252)
14. Diaz-Padilla I, Malpica AL, Minig L, Chiva LM, Gershenson DM, Gonzalez-Martin A. Ovarian low-grade serous carcinoma: a comprehensive update. *Gynecol Oncol.* 2012; 126(2): 279-285. doi: [10.1016/j.ygyno.2012.04.029](https://doi.org/10.1016/j.ygyno.2012.04.029)
15. Longacre TA, McKenney JK, Tazelaar HD, Kempson RL, Hendrickson MR. Ovarian serous tumors of low malignant potential (borderline tumors): outcome-based study of 276 patients with long-term (> or =5-year) follow-up. *Am J Surg Pathol.* 2005; 29(6): 707-723.
16. May T, Virtanen C, Sharma M, et al. Low malignant potential tumors with micropapillary features are molecularly similar to low-grade serous carcinoma of the ovary. *Gynecol Oncol.* 2010; 117(1): 9-17. doi: [10.1016/j.ygyno.2010.01.006](https://doi.org/10.1016/j.ygyno.2010.01.006)
17. Silva EG, Deavers MT, Malpica A. Patterns of low-grade serous carcinoma with emphasis on the nonepithelial-lined spaces pattern of invasion and the disorganized orphan papillae. *Int J Gynecol Pathol.* 2010; 29(6): 507-512. doi: [10.1097/PGP.0b013e3181e31f74](https://doi.org/10.1097/PGP.0b013e3181e31f74)
18. Djordjevic B, Malpica A. Ovarian serous tumors of low malignant potential with nodal low-grade serous carcinoma. *Am J Surg Pathol.* 2012; 36(7): 955-963. doi: [10.1097/PAS.0b013e31825793e1](https://doi.org/10.1097/PAS.0b013e31825793e1)
19. Katsumata N, Yasuda M, Isonishi S, et al. Long-term results of dose-dense paclitaxel and carboplatin versus conventional paclitaxel and carboplatin for treatment of advanced epithelial ovarian, fallopian tube, or primary peritoneal cancer (JGOG 3016): a randomised, controlled, open-label trial. *Lancet Oncol.* 2013; 14(10): 1020-1026. doi: [10.1016/S1470-2045\(13\)70363-2](https://doi.org/10.1016/S1470-2045(13)70363-2)
20. Schmeler KM, Sun CC, Bodurka DC, et al. Neoadjuvant chemotherapy for low-grade serous carcinoma of the ovary or peritoneum. *Gynecol Oncol.* 2008; 108(3): 510-514. doi: [10.1016/j.ygyno.2007.11.013](https://doi.org/10.1016/j.ygyno.2007.11.013)
21. Gershenson DM, Sun CC, Bodurka D, et al. Recurrent low-grade serous ovarian carcinoma is relatively chemoresistant. *Gynecol Oncol.* 2009; 114(1): 48-52. doi: [10.1016/j.ygyno.2009.03.001](https://doi.org/10.1016/j.ygyno.2009.03.001)
22. Gershenson DM, The life and times of low-grade serous carcinoma of the ovary. *Am Soc Clin Oncol Educ Book.* 2013; 195-199. doi: [10.1200/EdBook_AM.2013.33.e195](https://doi.org/10.1200/EdBook_AM.2013.33.e195)
23. Gershenson DM, Sun CC, Lu KH, et al. Clinical behavior of stage II-IV low-grade serous carcinoma of the ovary. *Obstet Gynecol.* 2006; 108(2): 361-368. doi: [10.1097/01.AOG.0000227787.24587.d1](https://doi.org/10.1097/01.AOG.0000227787.24587.d1)
24. Hannibal CG, Vang R, Junge J, Kjaerby-Thygesen A, Kurman RJ, Kjaer SK. A binary histologic grading system for ovarian serous carcinoma is an independent prognostic factor: a population-based study of 4317 women diagnosed in Denmark 1978-2006. *Gynecol Oncol.* 2012; 125(3): 655-660. doi: [10.1016/j.ygyno.2012.02.028](https://doi.org/10.1016/j.ygyno.2012.02.028)
25. Ali RH, Kalloger SE, Santos JL, Swenerton KD, Gilks CB. Stage II to IV low-grade serous carcinoma of the ovary is associated with a poor prognosis: a clinicopathologic study of 32 patients from a population-based tumor registry. *Int J Gynecol Pathol.* 2013; 32(6): 529-535. doi: [10.1097/PGP.0b013e31827630eb](https://doi.org/10.1097/PGP.0b013e31827630eb)
26. Köbel M, Bak J, Bertelsen BI, et al. Ovarian carcinoma histotype determination is highly reproducible, and is improved through the use of immunohistochemistry. *Histopathology.* 2014; 64: 1004-1013. doi: [10.1111/his.12349](https://doi.org/10.1111/his.12349)
27. Gershenson DM, Sun CC, Iyer RB, et al. Hormonal therapy for recurrent low-grade serous carcinoma of the ovary or peritoneum. *Gynecol Oncol.* 2012; 125(3): 661-666. doi: [10.1016/j.ygyno.2012.02.037](https://doi.org/10.1016/j.ygyno.2012.02.037)
28. Escobar J, Klimowicz AC, Dean M, et al. Quantification of ER/PR expression in ovarian low-grade serous carcinoma. *Gynecol Oncol.* 2013; 128(2): 371-376. doi: [10.1016/j.ygyno.2012.10.013](https://doi.org/10.1016/j.ygyno.2012.10.013)
29. Wong KK, Lu KH, Malpica A, et al. Significantly greater expression of ER, PR, and ECAD in advanced-stage low-grade ovarian serous carcinoma as revealed by immunohistochemical

analysis. *Int J Gynecol Pathol.* 2007; 26(4): 404-409.

30. Farley J, Brady WE, Vathipadiekal V, et al. Selumetinib in women with recurrent low-grade serous carcinoma of the ovary or peritoneum: an open-label, single-arm, phase 2 study. *Lancet Oncol.* 2013; 14(2): 134-140. doi: [10.1016/S1470-2045-\(12\)70572-7](https://doi.org/10.1016/S1470-2045(12)70572-7)

31. Fader AN, Java J, Krivak TC, et al. The prognostic significance of pre- and post-treatment CA-125 in grade 1 serous ovarian carcinoma: A Gynecologic Oncology Group study. *Gynecol Oncol.* 2013; 132(3): 560-565. doi: [10.1016/j.ygyno.2013.11.016](https://doi.org/10.1016/j.ygyno.2013.11.016)