

Case Report

***Corresponding author**
Hassan Ahmad, FRCA, FFICM
Consultant Anaesthetist
Tameside Hospital NHSFT
Ashton-under-Lyne OL6 9RW, UK
E-mail: drhassaan@gmail.com

Volume 2 : Issue 1

Article Ref. #: 1000AOJ2111

Article History

Received: May 17th, 2017

Accepted: June 5th, 2017

Published: June 5th, 2017

Citation

Ahmad H, Yadagiri M, Munikuntla V, Jahan S. Laryngeal transection in a patient after hanging. *Res Pract Anesthesiol Open J*. 2017; 2(1): 20-23. doi: [10.17140/RPAOJ-2-111](https://doi.org/10.17140/RPAOJ-2-111)

Copyright

©2017 Ahmad H. This is an open access article distributed under the Creative Commons Attribution 4.0 International License (CC BY 4.0), which permits unrestricted use, distribution, and reproduction in any medium, provided the original work is properly cited.

Laryngeal Transection in a Patient after Hanging

Hassan Ahmad, FRCA, FFICM¹; Manjula Yadagiri, FRCA²; Venkat Munikuntla, FRCA³; Sarwat Jahan, MBBS⁴

¹Consultant Anaesthetist, Tameside Hospital NHSFT, UK

²Anaesthetic Registrar, Pennine Acute Hospitals NHS Trust, UK

³Consultant Anaesthetist, Lancashire Teaching Hospitals NHS Trust, UK

⁴Geriatric Clinical Fellow, East Lancashire Hospitals NHS Trust, UK

ABSTRACT

Introduction: Hanging has become the second most common method of attempted suicide among adolescents and hanging injuries are associated with a high overall mortality rate.¹ Laryngeal injuries were observed in 35% to 45% of victims of hanging at autopsy.²

Case presentation: We present a 40-year-old male patient presenting after hanging. On presentation, he was alert with glasgow coma scale (GCS) 15/15 and self-ventilating, but was aphonic with quadriplegia. He suffered from complete upper laryngeal transection. He was successfully intubated in accident & emergency department (A&E), but eventually had tracheostomy with subsequent laryngeal repair. He was immediately transferred to neuro rehabilitation centre.

Conclusion: Airway injuries after hanging can be quite difficult to manage. Tracheostomy is recommended as the method of choice to secure the airway by many authors, because endotracheal intubation may pass into a false track at the site of tracheal separation and obstruct the airway completely.³⁻⁵

INTRODUCTION

Airway trauma may be life threatening, immediately or within several hours after acute injury. Although, laryngotracheal injuries represent less than 1% of all traumatic injuries, they account for more than 75% of immediate mortality.⁶ Motor vehicle accidents are the most common cause of blunt trauma to the airway, with hanging as a method of attempting suicide increasing in incidence.^{4,6} Because laryngotracheal separation caused by hanging usually results in early death at the scene, the true incidence is unknown.^{2,3,6}

CASE PRESENTATION

We would like to present the case of a 40-year-old male patient who presented to the university hospital after attempted hanging. He was reasonably fit and healthy with a background history of depression. He was witnessed to hang from a tree at a height of about 12 feet. He was brought to the hospital in the ambulance by the paramedics.

On presentation in accident & emergency department (A&E), he was fully alert with glasgow coma scale (GCS) of 15/15. His cervical spine was already stabilized in hard collar with triple in line immobilization. He was maintaining his airway but was dyspneac and tachypneac. His breathing was paradoxical with oxygen saturation of 89-92% on room air. The most important examination findings were that he was aphonic most probably due to laryngeal injury and quadriplegic most probably due to cervical spine injury. He was gradually getting tired because of dyspnea and tachypnea.

Computed tomography (CT) scan of the neck and airway was not considered at this

point, as the patient was desaturating already and it was decided to intubate him as he was getting tired. Prior to intubation, ear, nose, and throat (ENT) team did a quick nasendoscopy but could not visualize anything properly as it was a bloody field. It was fully recognized that it will be most probably difficult intubation due to altered anatomy secondary to most probable laryngeal injury as the patient was aphonic, so a proper plan was made for intubation with ENT team on stand by. Plan A was to do routine intravenous induction with modified laryngoscopy, using glidescope with manual in line neck stabilisation. Plan B was to perform quick tracheostomy, if plan A fails and for this, ENT team was ready scrubbed up on stand by to perform surgical tracheostomy straight away if needed.

Plan A was initialized and patient was induced intravenously. The patient was very easy to ventilate with bag and mask. When GlideScope was used, the view obtained was very difficult due to bloody field and altered anatomy as shown in Figure 1.

The view was 2A (as per Cormack & Lehane), so the bougie was passed through the laryngeal inlet but the bougie was seen to be subcutaneous just under the skin after going through the laryngeal inlet, so it was taken out. The patient was bag and mask ventilated for few seconds and then a second attempt was made to insert the bougie using glidescope, but same thing happened again and the bougie went through the laryngeal inlet but was again seen as subcutaneous just under the skin. This confirmed the laryngeal injury (possibly transection), which was suspected initially as well due to aphonia. The patient was ventilated again with bag and mask for few seconds and this time, laryngoscopy with glidescope was attempted by a senior anaesthetist, bougie was again inserted and this time, it went in to the trachea and the endotracheal tube was inserted over the bougie successfully. The patient was kept anaesthetized using propofol infusion and was taken to the CT scanner for having CT scan of the brain and neck. The CT scan showed no brain injury, fracture of the C2 vertebral pars inter-articularis along with facet joint dislocation between C2 and C3 vertebrae. It also showed antero-

listhesis of C2 vertebra over C3 vertebra along with respective spinal canal stenosis. In addition, there was surgical emphysema with locules of free gas in the retropharyngeal and right carotid spaces.

The patient then went straight to theatre and underwent panendoscopy. Operative findings included complete transection of epiglottis and aryepiglottic folds along with full thickness tears to lateral pharyngeal wall but with intact posterior pharyngeal wall. Esophagus was intact also. The patient then underwent laryngopharyngeal repair and tracheostomy.

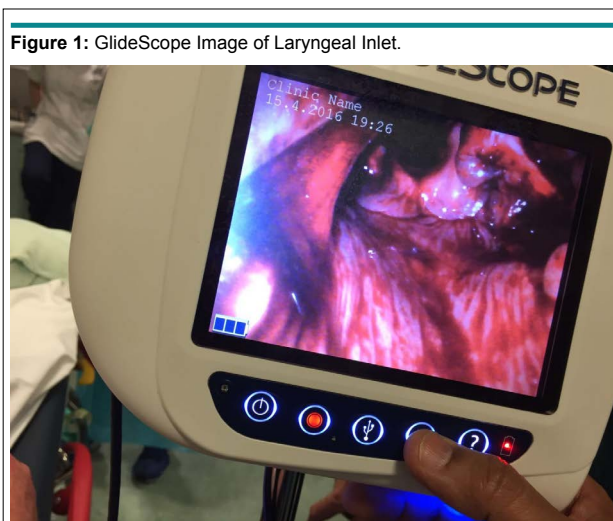
The patient was eventually sent to the neuro-rehabilitation centre for having neuro-rehabilitation with tracheostomy *in situ*.

DISCUSSION

Laryngotracheal injury is a rare injury being responsible for less than 1% of the trauma cases seen in most major centers.^{7,8} This is due to many factors, including rapid death at scene due to asphyxia, anatomical protection provided by sternum and mandible⁸ and lack of diagnosis of minor airway injuries in victims of major trauma by hospital staff.⁹

The mechanism for laryngotracheal injury after hanging may be multifold. Sudden neck extension, fixation of the larynx and anteroposterior compression of the tracheal rings result in shearing forces tearing the cricotracheal membrane.¹⁰ Direct upward pressure from hanging elevates the larynx superiorly resulting in separation of larynx and trachea.¹¹

Similarly, the extent and location of blunt laryngotracheal trauma is determined by several factors.¹² In one review, majority of the injuries occurred above the fourth tracheal ring (88%).¹³ However, penetrating and bullet wounds can occur in any part of the cervical trachea.¹⁴ Cricoid fracture can occur which can further cause recurrent laryngeal nerve injury compromising the airway lumen even further. In our case, the patient



did not suffer laryngotracheal injury. Infact, he had a total laryngeal injury including complete transection of epiglottis and aryepiglottic folds.

Admitted patient with laryngotracheal injury present with specific signs including skin abrasions over anterior neck, dyspnea, hoarseness, subcutaneous crepitus, haemoptysis and dysphagia,¹⁵ but their presence is variable^{12,13,16,17} according to the extent of injury. Surgical emphysema may develop hours after the initial injury.^{18,19} Hanging can also result in cervical spine injuries resulting in hemiplegia, quadriplegia, cranial nerve deficits, horner's syndrome and neurogenic shock. Our patient was dyspnoec and tachypnoec at presentation with minimal desaturation. However, he was aphonic and quadriplegic due to laryngeal and cervical spine injury respectively.

Investigation and management of a patient with laryngotracheal injury is dependent on the airway status of the patient at arrival in the hospital and the presence of other associated injuries.¹³ Airway control with cervical spine protection is always the priority. Chest and neck X-rays may demonstrate subcutaneous emphysema or distortion of the laryngotracheal air column.¹⁴ A CT scan has proved beneficial in differentiating between the patients with blunt laryngotracheal trauma requiring conservative management or surgical exploration.^{20,21}

Fibreoptic endoscopic examination of the upper airway may be useful to evaluate the site and extent of airway injury and also enables tracheal intubation while minimizing the risk to the potentially damaged cervical spine.²² However, it may be technically difficult to perform fibreoptic endoscopy due to bleeding, debris and anatomical disruption. It can also result in airway obstruction.¹²

Tracheostomy is the method of choice for airway management in an acutely injured patient with neck trauma, as attempts at tracheal intubation may result in creation of a false passage, compromising the airway further. Rapid deterioration of the patient, if occurs, may also necessitate tracheostomy.²³ Alternatively, femoral-femoral cardiopulmonary bypass can be considered in case of any emergency.¹⁴ After airway is established, surgical repair should be undertaken as soon as possible. Early repair within 48 hours shows improved outcomes with respect to airway and voice and also lower incidence of subglottic stenosis.^{24,25}

CONFLICTS OF INTEREST

The authors declare that they have no conflicts of interest.

CONSENT

Consent has been taken from the patient for purpose of using patient photographs for publication in print or on the internet.

REFERENCES

1. Martin ML, Weng J, Demetriades D, Salim A. Patterns of

injury and functional outcome after hanging: Analysis of the National Trauma Data Bank. *Am J Surg.* 2005; 190(6): 836-840. doi: [10.1016/j.amjsurg.2005.05.051](https://doi.org/10.1016/j.amjsurg.2005.05.051)

2. Borowski DW, Mehrotra P, Tennant D, El Badawey MR, Cameron DS. Unusual presentation of blunt laryngeal injury with cricotracheal disruption by attempted hanging: A case report. *Am J Otolaryngol.* 2004; 25(3): 195-198. doi: [10.1016/j.amjoto.2003.11.001](https://doi.org/10.1016/j.amjoto.2003.11.001)

3. McCrystal DJ, Bond C. Cricotracheal separation: A review and a case with bilateral recovery of recurrent laryngeal nerve function. *J Laryngol Otol.* 2006; 120(6): 497-501. doi: [10.1017/S0022215106000909](https://doi.org/10.1017/S0022215106000909)

4. Costache VS, Renaud C, Brouchet L, et al. Complete tracheal rupture after a failed suicide attempt. *Ann Thorac Surg.* 2004;77(4): 1422-1423. doi: [10.1016/S0003-4975\(03\)01273-6](https://doi.org/10.1016/S0003-4975(03)01273-6)

5. Baumgartner FJ, Ayres B, Theuer C. Danger of false intubation after traumatic tracheal transection. *Ann Thorac Surg.* 1997; 63(1): 227-228. doi: [10.1016/S0003-4975\(96\)00691-1](https://doi.org/10.1016/S0003-4975(96)00691-1)

6. Aouad R, Moutran H, Rassi S. Laryngotracheal disruption after blunt neck trauma. *Am J Emerg Med.* 2007; 25(9): 1084.e1-1084.e2. doi: [10.1016/j.ajem.2007.02.048](https://doi.org/10.1016/j.ajem.2007.02.048)

7. Gussack GS, Jurkovich GJ, Luterman A. Laryngotracheal trauma: A protocol approach to a rare injury. *Laryngoscope.* 1986; 96: 660-665.

8. Nahum AM. Immediate care of acute blunt laryngeal trauma. *J Trauma.* 1969; 9:112-25.

9. Bryce DP. The surgical management of laryngotracheal injury. *J Laryngol Otol.* 1972; 86: 547-587.

10. Choi JW, Koo BS, Rha KS, Yoon YH. Complete laryngotracheal separation following attempted hanging. *Clin Exp Otorhinolaryngol.* 2012 Sep;5(3):177-180. doi: [10.3342/ceo.2012.5.3.177](https://doi.org/10.3342/ceo.2012.5.3.177)

11. LeJeune FE Jr. Laryngotracheal separation. *Laryngoscope.* 1978; 88(12): 1956-1962.

12. Sofferman RA. Management of laryngotracheal trauma. *Am J Surg.* 1981; 141: 412-417. doi: [10.1016/0002-9610\(81\)90132-X](https://doi.org/10.1016/0002-9610(81)90132-X)

13. Sheely CH 2nd, Mattox KL, Beall AC Jr. Management of acute cervical tracheal trauma. *Am J Surg.* 1974; 128: 805-808. doi: [10.1016/0002-9610\(74\)90075-0](https://doi.org/10.1016/0002-9610(74)90075-0)

14. Deshpande S. Laryngotracheal separation after attempted hanging. *Br J Anaesth.* 1998; 81: 612-614. doi: [10.1093/bja/81.4.612](https://doi.org/10.1093/bja/81.4.612)

15. Alonso WA, Caruso VJ, Roncore EA. Minibikes, a new factor in laryngotracheal trauma. *Ann Otol Rhinol Laryngol Suppl.* 1973; 82: 800-804. doi: [10.1177/000348947308200608](https://doi.org/10.1177/000348947308200608)
16. Coetzee T, Van Niekerk JP. Complete subcutaneous rupture-separation of cervical trachea. *J Trauma.* 1965; 5: 458-463.
17. Urschel HC, Razzuk MA. Management of acute traumatic injuries of tracheobronchial tree. *Surgery, Gynaecology and Obstetrics.* 1973; 136: 113-117.
18. Lusk RP. The evaluation of minor cervical blunt trauma in the pediatric patient. *Clinical Pediatrics.* 1986; 25: 445-447. doi: [10.1177/000992288602500906](https://doi.org/10.1177/000992288602500906)
19. Soothill EF. Closed traumatic rupture of the cervical trachea. *Thorax.* 1960; 15: 89-92. doi: [10.1186/1757-7241-21-60](https://doi.org/10.1186/1757-7241-21-60)
20. Mancuso AA, Hanafee WN. Computed tomography of the injured larynx. *Radiology.* 1979; 133: 139-144. doi: [10.1148/133.1.139](https://doi.org/10.1148/133.1.139)
21. Maceri DR, Mancuso AA, Canalis RF. Value of computed axial tomography in severe laryngeal injury. *Archives of Otolaryngology.* 1982; 108: 449-451. doi: [10.1001/archotol.1982.00790550053014](https://doi.org/10.1001/archotol.1982.00790550053014)
22. Roberge RJ, Squyres NS, Demetropoulos S, McAuliffe M, Vukich D. Tracheal transection following trauma. *Ann Emerg Med.* 1988; 17: 95-100. doi: [10.1016/S0196-0644\(88\)80503-1](https://doi.org/10.1016/S0196-0644(88)80503-1)
23. Ayabe H, Tsuji A, Akamine S, Tagawa Y, Kawahara K, Tomita M. Combined transection of the trachea and esophagus following cervical blunt trauma. *J Thorac Cardiovasc Surg.* 1993; 41: 193-195. doi: [10.1055/s-2007-1013853](https://doi.org/10.1055/s-2007-1013853)
24. Leopold DA. Laryngeal trauma: A historical comparison of treatment methods. *Arch Otolaryngol.* 1983; 109(2): 106-112. doi: [10.1001/archotol.1983.00800160040010](https://doi.org/10.1001/archotol.1983.00800160040010)
25. Schaefer SD. Primary management of laryngeal trauma. *Ann Otol Rhinol Laryngol.* 1982; 91(4 Pt 1): 399-402. doi: [10.1177/000348948209100416](https://doi.org/10.1177/000348948209100416)