

Case Report

*Corresponding author

Alcir Escocia Dorigatti, MD

Department of Surgery
School of Medical Sciences
University of Campinas
Rua Alexander Fleming
181 - Cidade Universitária Prof. Zeferino
Vaz - Campinas, SP 13.083-970, Brazil
Tel. +55 19 3521 9450
E-mail: alcir.dorigatti@gmail.com

Volume 3 : Issue 2

Article Ref. #: 1000EMOJ3138

Article History

Received: October 18th, 2016

Accepted: January 2nd, 2017

Published: January 3rd, 2017

Citation

Dorigatti AE, Zaponi-Melek M, Schmid BP, Pereira BM, Fraga GP. Is bedside ultrasound useful for chest tube removal? Description of an initial experience. *Emerg Med Open J.* 2017; 3(2): 38-41. doi: [10.17140/EMOJ-3-138](https://doi.org/10.17140/EMOJ-3-138)

Copyright

©2017 Dorigatti AE. This is an open access article distributed under the Creative Commons Attribution 4.0 International License (CC BY 4.0), which permits unrestricted use, distribution, and reproduction in any medium, provided the original work is properly cited.

Is Bedside Ultrasound Useful for Chest Tube Removal? Description of an Initial Experience

Alcir Escocia Dorigatti, MD^{1*}; Marina Zaponi Melek, MD²; Bruno P. Schmid, MD¹; Bruno M. Peireira, MD, PhD, FACS, FCCM³; Gustavo Pereira Fraga, MD, PhD, FACS³

¹General Surgery Resident, University of Campinas (Unicamp), Campinas, SP, Brazil

²Emergency Medicine Resident, University of Campinas (Unicamp), Campinas, SP, Brazil

³Division of Trauma Surgery, Department of Surgery, University of Campinas (Unicamp), Campinas, SP, Brazil

ABSTRACT

Introduction: Point-of-care ultrasound is a propaedeutic modality more often used in a daily basis practice. Since the establishment of sonography bases for lung ultrasound, it has become a valuable extension of physical examination, providing new information about lungs, pleural structures and volume status. Currently, the removal of chest tubes is based on clinical data, associated with chest X-ray control. The objective of this manuscript is to describe two cases that ultrasound was used in order to test whether it could be an alternative control tool on these specific scenarios.

Methods: Bedside ultrasound was daily performed on two patients with iatrogenic pneumothorax until they met clinical criteria for chest tube removal. Ultrasound exam was performed before and after chest tube removal.

Results: In both cases patients were submitted to chest tube placement due to iatrogenic pneumothorax. One of the patients had a pneumothorax during diagnostic thoracocentesis for pleural effusion and the other patient during the placement of a central venous line. In both the cases, bedside ultrasound presented similar results to the chest X-ray. Bedside ultrasound was able to adequately identify chest tube placement and lung expansion. In none of the present cases was possible to see residual pneumothorax also unidentified by the chest X-ray.

Conclusion: Even though there is extensive data showing ultrasound superiority when compared to chest X-ray in the diagnosis of pneumothorax, there is little or no data using this method as image criteria for chest tube removal. This article shows two suggestive cases that lung ultrasound could be a simple, bedside manner, to show adequate lung expansion and serve as useful tool for chest tube removal. A prospective study is necessary to provide evidence-based data on the subject.

KEYWORDS: Point-of-care ultrasound; Lung ultrasound; Chest tube.

INTRODUCTION

A small amount of fluid in the space between the lungs and the chest helps the lungs move without friction during respiration. But a build-up of air (pneumothorax), blood (hemothorax), or pus (pyothorax) from injury, disease, or surgery can prevent the lungs from fully expanding. Partial or total collapse of the lungs compromises breathing and can lead to respiratory arrest. Insertion of a chest tube, also known as a thoracostomy tube or thoracic catheter, can bring rapid relief.

Most problems resolve within a few days, as the closed water-seal drainage device that's attached to the tube suctions off the abnormal accumulation of fluid or air and helps restore the negative pressure in the affected lung. No matter what the reason for the insertion,

a chest tube must be removed within one week. Leaving it in place longer than 7 days raise the risks for infection along the chest tube tract.¹ A number of clinical indicators will determine when a patient is ready for his chest tube to be removed. If the chest tube was inserted because of excess fluid, it can be safely removed when the drainage is less than 200 ml in 24 hours. If blood precipitated tube insertion, minimal output and a change in drainage from bloody to serous or serosanguinous is also a key indicator. In the case of pneumothorax, the tube can be safely removed when bubbling or fluctuation in the water-seal chamber ceases during expiration or during a cough.²

Current recommendations for chest tube removal include a chest X-ray before and after the procedure. However, as bedside ultrasound is getting routinely used on daily practice couldn't it be used as a safe tool for checking pulmonary expansion after thoracostomy tube removal?

Since the establishment of sonographic bases for lung ultrasound,³ it has become an extension of bedside physical assessment and provides valuable information about lung, pleural structures and volume status.⁴ Also, point-of-care ultrasound provides rapid and accurate assessment of pneumothorax. The presence of lung sliding or lung pulse excludes pneumothorax at the point of the probe, with a negative predictive value of 100%.^{5,6} The most specific sign of pneumothorax is the presence of a lung point, with 100% specificity for pneumothorax.⁷ Ultrasound guided chest tube insertion is a procedure already used and described in the literature, but ultrasound for chest-tube removal confirming evidence of no reminiscent pneumothorax is not described yet.

This article objective is to test the hypothesis that ultrasound point-of-care is a useful and safe tool for chest tube removal.

METHODS

Lung ultrasound was daily performed at bedside on 2 patients who had chest tubes inserted due to iatrogenic pneumothorax-one during a diagnostic thoracocentesis for pleural effusion while the other during the placement of a central venous catheter.

Initial point-of-care ultrasound was performed while they were still in the emergency room. By the other days lung ultrasound was performed once a day, by the same experienced

examiner, until patient met the clinical and radiological criteria necessary to chest tube removal (Table 1). When patients met such criteria, lung point-of-care ultrasound was obtained before and after the removal of the chest tube. The images of lung ultrasound were obtained with a 3.5 MHz convex probe. Images from the apex, middle zone, and pulmonary base were obtained through longitudinal windows.

The following criteria were evaluated: 1) the presence of lung sliding, 2) presence of lung point, 3) lung pulse, 4) presence of A lines and 5) pleural effusion on ultrasound. Clinical data were also collected, such as chest tube debt, macroscopic aspect of chest tube debt, chest tube oscillation and X-ray.

All patients signed a term when admitted to our institution authorizing the use of data from medical records for scientific research with guaranteed anonymity. If the patients are not in health status that allows sign the authorization form, a responsible family does in its place. In addition, they were informed and agreed that their hospitalization data would be used for this specific article.

RESULTS

Patient 1: Sixty-eight-years-old, male, admitted to the emergency room due to severe worsening dyspnea in the last few days. Point-of-care ultrasound was immediately performed revealing an extensive pleural effusion on the right lung. Patient was submitted to diagnostic thoracocentesis with also the purpose of symptoms relief. During the procedure clinical status and ventilation deteriorated, and patient was submitted to rapid sequence orotracheal intubation and mechanical ventilation. Clinical diagnosis of hypertensive pneumothorax was made and chest tube inserted right away. Control X-ray demonstrated a well-placed chest tube, with expanded lung and moderate pleural effusion. Lung ultrasound displayed A lines predominance, with the presence of lung sliding on the pulmonary apex. The remaining chest cavity on the right was still filled with pleural effusion, with no visible septations, chest tube was also observed and appeared well placed. Daily ultrasound evaluation demonstrated reduction of pleural effusion concomitant to chest tube debit decrease.

On the 8th admitting day, chest tube output was of 100 ml and clear. Both bedside ultrasound and X-ray confirmed full lung expansion. Ultrasound though, revealed additional information such as visualization of no pleural effusion, adequate

Table 1: Chest Tube Removal Criteria.

Chest tube removal criteria
Chest X-Ray with no residual pneumothorax/Expanded lungs
Drainage less than 200 ml in 24 hours
No oscillation on water-seal
Change in drainage from bloody to serous or serosanguinous

lung sliding and predominance of lines on the right lung. Chest tube was then removed with no complications.

US performed after chest tube removal revealed adequate lung sliding (Figure 1 and Table 2).

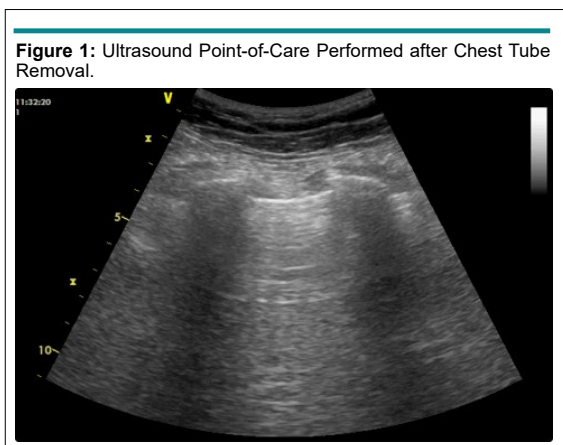


Figure 1: Ultrasound Point-of-Care Performed after Chest Tube Removal.

Patient 2: Eighty-four-years-old, female, admitted to the emergency room in cardiac arrest, suffered iatrogenic pneumothorax during the attempt of placing a central venous catheter. US performed after the insertion of the chest tube showed adequate lung sliding, no lung point, adequate chest tube placement, no pleural effusion, and predominance of lines. Daily evaluation of ultrasound demonstrated a well-expanded lung, with no lung point and no pleural effusion visible to the ultrasound. After 5 days of chest tube, output was of 50 ml with no oscillation in the water seal. US and chest X-ray demonstrated lung expansion. Point-of-care ultrasound prior to chest tube removal revealed

adequate lung sliding, no lung point, no pleural effusion and a predominance of lines. US performed after chest tube withdraw expressed the same pattern. Table 3 shows Chest X-ray *versus* US findings.

DISCUSSION

Even though the ultrasound can be used for countless procedures, including the allocation of chest tube in non-emergency situations,⁸ no reports about its use as a tool to evaluate chest tube removal can be found.

A prospective study has compared the sensitivity and specificity of bedside ultrasound in the emergency department with supine portable AP chest radiography for the detection of pneumothorax in trauma patients; standard criterion used was computed tomography.⁹ The sensitivity for chest radiography was 75.5% (95% CI=61.7% to 86.2%) and the specificity was 100% (95% CI=97.1% to 100%). The sensitivity for US was 98.1% (95% CI=89.9% to 99.9%) and the specificity was 99.2% (95% CI=95.6% to 99.9%).⁹ Another manuscript has shown that sensitivity and specificity of US use on detection of pneumothorax ranges from 86% to 98% and 97% to 100%, respectively while sensitivity of supine AP chest radiographs ranges from 28% to 75% in all included studies. Standard method for pneumothorax diagnosis were computer tomography or air gush during thoracostomy on unstable patients.¹⁰

The mentioned evidence led these authors to the following question: could ultrasound safely replace X-ray as a chest tube removal image tool? Literature shows that small pneumothoraxes could be missed on chest X-ray in 30% to 50%

Table 2: Data before Chest Tube Removal.

US exam immediately performed before chest tube removal		
	Patient 1	Patient 2
Chest tube debit	100 ml	50 ml
Chest tube oscillation	Present	Present
Pneumothorax on X-Ray	No	No
A lines in US	Predominant	Predominant
Presence of lung sliding	Yes	Yes
Presence of lung point	No	No
Presence of lung pulse	No	No
Macroscopic aspect	Clear	Clear
Chest tube placement	Adequate	Adequate

Table 3: Chest X-ray *versus* US Findings.

	Chest X-Ray (plain)	US Point-of-Care (Lung)
Lung expansion	Yes	Yes
Pleural effusion	No	No
Lung sliding	Unable to method	Yes
A lines	Unable to method	Yes

of trauma patients.¹¹ Ultrasound has higher sensitivity than X-ray with almost equal specificity, it seems to be even more accurate to search and confirm residual pneumothorax, which would infer on the maintenance of the chest-tube. It must be considered that the ultrasound is an operator-dependent method, but also is the interpretation of chest X-ray.

On the two exposed cases, ultrasound demonstrated results that lead to the same critical-decision taken with the X-ray evaluation, ultrasound though, was able to demonstrate more information than the X-ray such as A lines, absence of lung point and adequate lung sliding, data that is impossible to be seen on X-ray due to method restrictions but could bring valuable clinical decision on different scenarios.

There is a lot of disaccord regarding ultrasound use over traditional diagnostic techniques,¹² however in this initial experience description, the authors could find an unexplored use for it, which could take away hospital spending and reduce patients radiation exposure. Authors are now working on a prospective study in order to give an evidence-based answer to this question.

CONCLUSION

Even though there is extensive data showing ultrasound superiority when compared to chest X-ray in the diagnosis of pneumothorax, there is little or no data using this method as image criteria for chest tube removal. In both presented cases, lung ultrasound was able to adequately identify lung expansion and chest tube placement at bedside. This article shows two suggestive cases that lung ultrasound could be a simple, bedside manner, to show adequate lung expansion and serve as useful tool for chest tube removal. A prospective study is necessary to provide evidence-based data on the subject.

CONFLICTS OF INTEREST

The authors declare that they have no conflicts of interest.

REFERENCES

- Kao JH, Kao HK, Chen YW, et al. Chest tube duration in mechanically ventilated patients with acquired pneumothorax. *Respir care*. 2013; 58(12): 2093-2100. doi: [10.4187/respcare.02273](https://doi.org/10.4187/respcare.02273)
- Kesieme EB, Olusoji O, Inuwa IM, Ngene CI, Aigbe E. Management of chest drains: A national survey on surgeons-in-training experience and practice. *Niger J Surg*. 2015; 21(2): 91-95. doi: [10.4103/1117-6806.162569](https://doi.org/10.4103/1117-6806.162569)
- Lichtenstein DA. *Whole Body Ultrasonography in the Critically Ill*. Berlin, Germany: Springer Science & Business Media; 2010.
- Lichtenstein D. Lung ultrasound in acute respiratory failure an introduction to the BLUE-protocol. *Minerva Anesthesiol*. 2009; 75(5): 313-317. Web site. http://prismic-io.s3.amazonaws.com/hemodynamik%2F0c4934d9-d8d1-4460-9a50-b0071c0cf2e0_intro+till+blue+protocol.pdf. Accessed October 17, 2016.
- Lichtenstein DA, Menu Y. A bedside ultrasound sign ruling out pneumothorax in the critically III: Lung sliding. *Chest*. 1995; 108(5): 1345-1348. doi: [10.1378/chest.108.5.1345](https://doi.org/10.1378/chest.108.5.1345)
- Lichtenstein DA, Mezière G, Lascols N, et al. Ultrasound diagnosis of occult pneumothorax. *Crit Care Med*. 2005; 33(6): 1231-1238. doi: [10.1097/01.CCM.0000164542.86954.B4](https://doi.org/10.1097/01.CCM.0000164542.86954.B4)
- Lichtenstein D, Mezière G, Biderman P, Gepner A. The "lung point": An ultrasound sign specific to pneumothorax. *Intensive Care Med*. 2000; 26(10): 1434-1440. doi: [10.1007/s001340000627](https://doi.org/10.1007/s001340000627)
- Chichra A, Makaryus M, Chaudhri P, Narasimhan M. Ultrasound for the Pulmonary Consultant. *Clin Med Insights Circ Respir Pulm Med*. 2016; 10: 1-9. doi: [10.4137/CCRPM.S33382](https://doi.org/10.4137/CCRPM.S33382)
- Blaivas M, Lyon M, Duggal S. A prospective comparison of supine chest radiography and bedside ultrasound for the diagnosis of traumatic pneumothorax. *Acad Emerg Med*. 2005; 12(9): 844-849. doi: [10.1197/j.aem.2005.05.005](https://doi.org/10.1197/j.aem.2005.05.005)
- Wilkerson RG, Stone MB. Sensitivity of bedside ultrasound and supine anteroposterior chest radiographs for the identification of pneumothorax after blunt trauma. *Acad Emerg Med*. 2010; 17(1): 11-17. doi: [10.1111/j.1553-2712.2009.00628.x](https://doi.org/10.1111/j.1553-2712.2009.00628.x)
- Rowan K, Kirkpatrick A, Liu D, Forkheim K, Mayo J, Nicolaou S. Traumatic pneumothorax detection with thoracic US: Correlation with chest radiography and CT-initial experience. *Radiology*. 2002; 225(1): 210-214. doi: [10.1148/radiol.2251011102](https://doi.org/10.1148/radiol.2251011102)
- Pereira BM, Dorigatti AE. Current specialist awareness on ultrasound use for central venous catheterization. *Emerg Med Open J*. 2016; 2(1): 1-4. doi: [10.17140/EMOJ-2-119](https://doi.org/10.17140/EMOJ-2-119)