

Case Report

Corresponding author

Ryan Mason, MD

PGY-2

Division of Emergency Medicine

University of Washington

Seattle, WA, USA

Tel. 518-332-2306

E-mail: masonry@uw.edu

Volume 2 : Issue 2

Article Ref. #: 1000EMOJ2124

Article History

Received: April 13th, 2016

Accepted: May 17th, 2016

Published: May 17th, 2016

Citation

Mason R, Hurley W, Utarnachitt RB. Intravenous fat emulsion (IFE) improvement of qt-interval in tricyclic antidepressant overdose. *Emerg Med Open J.* 2016; 2(2): 23-26. doi: [10.17140/EMOJ-2-124](https://doi.org/10.17140/EMOJ-2-124)

Copyright

©2016 Mason R. This is an open access article distributed under the Creative Commons Attribution 4.0 International License (CC BY 4.0), which permits unrestricted use, distribution, and reproduction in any medium, provided the original work is properly cited.

Intravenous Fat Emulsion (IFE) Improvement of Qt-Interval in Tricyclic Antidepressant Overdose

Ryan Mason, MD^{*}; William Hurley, MD, FACEP; Richard B. Utarnachitt, MD, MS, FAAEM

Division of Emergency Medicine, University of Washington, Seattle, WA, USA

ABSTRACT

Here we report a case of a 62-year-old female with a potentially lethal ingestion of a tricyclic antidepressant (nortriptyline) refractory to conventional therapy. In the emergency department, she was profoundly hypotensive and significantly acidotic. She received several sodium bicarbonate boluses followed by continuous sodium bicarbonate infusion in addition to multiple vasopressors. Despite these measures, the patient remained dangerously hypotensive with a prolonged QT interval. Lipid emulsion was started with a bolus and infusion. Subsequently, the patient successfully weaned off pressor support and her QT interval normalized. After a short hospital course, patient was discharged with only moderate cognitive impairment.

KEYWORDS: Tricyclic Acid Overdose; Intravenous Fat Emulsion Therapy.

INTRODUCTION

Intentional overdose of tricyclic antidepressants (TCAs) remains a potentially lethal ingestion commonly seen in emergency departments.^{1,2} Among the many toxicities related to TCA overdose, cardiac suppression along with prolongation of QT interval is most concerning manifestation as it can lead to lethal dysrhythmias.^{2,3}

Rescue therapy using intravenous fat emulsion (IFE) therapy has been demonstrated to be a beneficial antidote for many acute poisonings. IFE for the use of bupivacaine toxicity was first described in animal models in 1998. Clinically, the therapy was first used successfully for an intra-operative bupivacaine toxicity in 2006.⁴⁻⁶ Animals were pretreated with saline or 10%, 20%, or 30% Intralipid (n=6 for all groups. Since then, the use of IFE indications have expanded to include many lipophilic medication overdoses including TCAs. A recent survey of poison control centers noted 69% now recommend IFE for TCA overdose.⁷ We now present a case of TCA overdose refractory to traditional therapies, improved with IFE.

CASE REPORT

A 62-year-old female was found by her husband at 12:30 pm at home unresponsive next to a suicide note stating a mixed ingestion including nortriptyline, gabapentin and pregabalin at 10:30 am. Unfortunately, the exact dosages remain unknown. Eventually, EMS was called who arrived at 2:55 pm to find the patient to be unresponsive, reporting a Glasgow Coma Scale score of 3. She was noted to have had multiple seizure episodes. In addition, she was also found to be profoundly hypotensive with a blood pressure of 68/palpation and a heart rate of 84 beats per minute (bpm). After establishing IV access, the patient was intubated and started to receive fluid resuscitation on route to the emergency department (ED).

Upon arrival in the ED at 3:40 pm, the patient was still hypotensive with a blood pressure of 87/67 and a heart rate of 82 bpm. The initial 12 lead ECG tracing was concerning for a prolonged QRS interval of 192 milliseconds (ms) and QTc of 550 ms. (Figure 1) The patient's

arterial blood gas was significant for a respiratory acidosis pH of 7.28 and a lactate of 3.5 mm/L. Her respiratory rate on the ventilator was increased from 12 breaths per minute to 24 breaths per minute to account for her respiratory acidosis. The patient received a total of three boluses of sodium bicarbonate in addition to the continuous infusion of sodium bicarbonate. The patient was noted to have two seizure episodes each lasting less than 15 seconds, both of which were treated with 5 milligrams (mg) of intravenous (IV) diazepam. Concurrently with on-going fluid resuscitation, the patient was started on dopamine, norepinephrine and epinephrine infusions. Bedside ultrasound of the patient's heart demonstrated poor cardiac contractility despite adequate fluid resuscitation and escalating doses of multiple vasopressors. Norepinephrine was infusing at 30 micrograms per minute (mcg/min), epinephrine at 40 mcg/min and dopamine at 15 mcg/min. Her blood pressure remained labile with mean arterial pressures ranging from 52 to 64 mm Hg. Twelve lead ECG also demonstrated persistently prolonged QRS and QTc intervals. The range

of QRS intervals was between 128 and 192 and the range of QTc intervals was 586-706 ms. (Figure 2) The decision was made to initiate lipid emulsion rescue therapy given the refractory nature of this ingestion. Poison control was contacted and agreed with our plan to initiate lipid emulsion therapy in the ED with the initial bolus 100 milliliter (ml) bolus of 20% lipid emulsion then 0.25 milliliters per kilogram per minute (ml/kg/min) over 10 minutes for a total volume of 250 ml at 9:30 pm. Repeat 12 lead ECG approximately 2 hours after lipid administration showed resolution of prolonged QRS and QTc. (Figure 3). The patient required decreasing amounts of vasopressor support throughout the night. She was successfully weaned off of vasopressors between 6 and 9 hours after lipid administration. The remainder of her hospital stay was uneventful. She was noted to have some moderate cognitive deficit but able to perform activities of daily living. She was discharged to an inpatient psychiatric facility after hospital day eight.

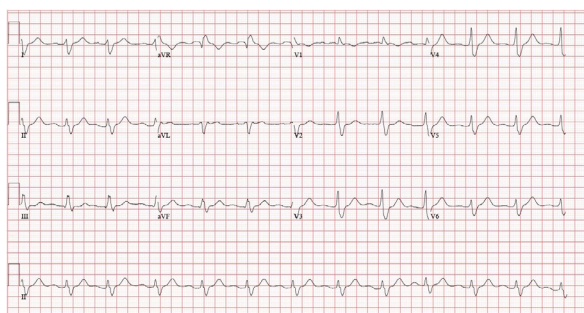


Figure 1.Initial 12-lead ECG demonstrating prolonged QRS and QTc.

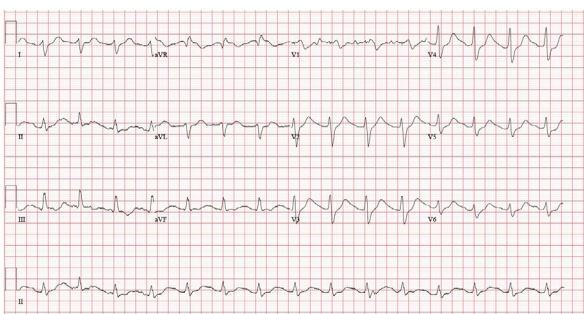


Figure 2. Subsequent 12-Lead ECG with continued QTc prolongation despite sodium bicarbonate therapy.

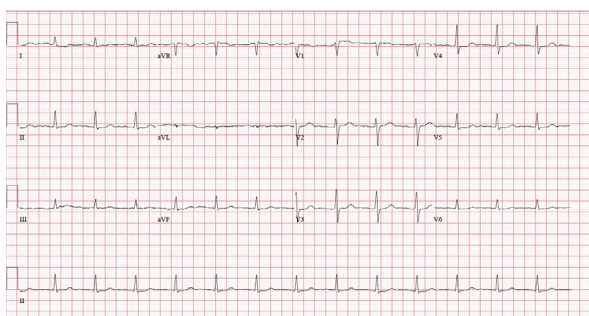


Figure 3. 12-lead ECG after lipid emulsion infusion with normalization of QRS and QTc intervals.

DISCUSSION

In recent years, there have multiple well document case reports of IFE therapy used to successfully treat TCA overdose.⁸⁻¹¹ We believe our study adds to this growing body of information. To our knowledge, this study is the first description of IFE therapy specifically in an overdose of nortriptyline, a metabolite of amitriptyline. Initially, the mechanism of IFE was unknown, theoretic mechanisms such as “lipid sink” were proposed, but lacked much evidence.¹² As interest in IFE grows, more research has been undertaken to elucidate its action. This case report provides an opportunity to review current research in this area.

Current research into the action of IFE therapy indicates it is likely multimodal, simultaneously affecting multiple physiologic processes. The 2015 Fettiplace et al¹³ study proposes three related mechanisms based on bench research. First, the lipid acts a shuttle, drawing the lipophilic toxin out of the cardiac tissue and transporting it to tissues where it can be safely metabolized. As the intra-tissue toxicity decreases, the lipid is then able to directly support cardiac inotropic function. Finally, free fatty acids from the lipids provide a supportive energy source throughout detoxification.¹³ These mechanisms of action help us understand how IFE supports cardiac function. However, this proposal of mechanism has a few caveats when discussing its use specifically in TCA overdose.

The research undertaken and reviewed by Fettiplace et al¹³ looked primary at bupivacaine, a long-acting anesthetic. Bupivacaine acts primary on voltage-gated sodium channels while TCAs have multiple cellular targets, thus their mechanism of toxicity is primarily different. Secondly, bupivacaine is administered as a solution, as opposed to TCAs, which are absorbed through the gastric mucosa complicating the bioavailability and duration of action. Therefore, we should carefully interpret IFE in the setting of TCA overdose.

Beyond the inherent drawbacks to the case report format, our case study has a number of other limitations. Foremost, the patient suffered a multi-substance intoxication, as documented by her suicide note. Gabapentin and pregabalin present possible confounders as to which drug IFE was actually treating. However, the patient did present with hypotension and ECG changes consistent with TCA overdose, and these clinical manifestations have not been described with gabapentin or pregabalin.¹⁴

Also unfortunately, there was no documentation of the suspected amount of ingestion. The listed half-life of nortriptyline is 16-90 hours. Gastric absorption always makes this a moving target, but it is possible that the resolution of the patient’s hypotension was the natural course of her disease and that the IFE was merely a correlation.

CONFLICTS OF INTEREST: None.

REFERENCES

1. McKenzie MS, McFarland BH. Trends in antidepressant overdoses. *Pharmacoepidemiol Drug Saf.* 2007; 16(5): 513-523. doi: [10.1002/pds.1355](https://doi.org/10.1002/pds.1355)
2. Kerr GW, McGuffie a C, Wilkie S. Tricyclic antidepressant overdose: a review. *Emerg Med J.* 2001; 18(4): 236-241. doi: [10.1136/emj.18.4.236](https://doi.org/10.1136/emj.18.4.236)
3. Niemann JT, Bessen HA, Rothstein RJ, Laks MM. Electrocardiographic criteria for tricyclic antidepressant cardiotoxicity. *Am J Cardiol.* 1986; 57(13): 1154-1159. doi: [10.1016/0002-9149\(86\)90691-0](https://doi.org/10.1016/0002-9149(86)90691-0)
4. Weinberg GL, VadeBoncouer T, Ramaraju GA, Garcia-Amaro MF, Cwik MJ. Pretreatment or resuscitation with a lipid infusion shifts the dose-response to bupivacaine-induced asystole in rats. *Anesthesiology.* 1998; 88(4): 1071-1075. Web site. <http://anesthesiology.pubs.asahq.org/article.aspx?articleid=1947600>. Accessed April 12, 2016
5. Rosenblatt M, Abel M, Fischer GW, Itzkovich CJ, Eisenkraft JB. Successful use of a 20% lipid emulsion to resuscitate a patient after a presumed bupivacaine-related cardiac arrest. *Anesthesiology.* 2006; 105(1): 217-218. Web site. <http://anesthesiology.pubs.asahq.org/article.aspx?articleid=1923252>. Accessed April 12, 2016
6. Woolf AD, Erdman AR, Nelson LS, et al. Tricyclic antidepressant poisoning: An evidence-based consensus guideline for out-of-hospital management. *Clin Toxicol.* 2007; 45(5): 203-233. doi: [10.1080/15563650701226192](https://doi.org/10.1080/15563650701226192)
7. Christian MR, Pallasch EM, Wahl M, Mycyk MB. Lipid Rescue 911: Are Poison Centers Recommending Intravenous Fat Emulsion Therapy for Severe Poisoning? *J Med Toxicol.* 2013; 9(3): 231-234. doi: [10.1007/s13181-013-0302-2](https://doi.org/10.1007/s13181-013-0302-2)
8. Agarwala R, Ahmed SZ, Wiegand TJ. Prolonged use of intravenous lipid emulsion in a severe tricyclic antidepressant overdose. *J Med Toxicol.* 2014; 10(2): 210-214. doi: [10.1007/s13181-013-0353-4](https://doi.org/10.1007/s13181-013-0353-4)
9. Blaber MS, Khan JN, Brebner JA, McColm R. “lipid Rescue” for tricyclic antidepressant cardiotoxicity. *J Emerg Med.* 2012; 43(3): 465-467. doi: [10.1016/j.jemermed.2011.09.010](https://doi.org/10.1016/j.jemermed.2011.09.010)
10. Harvey M, Cave G. Case report: successful lipid resuscitation in multi-drug overdose with predominant tricyclic antidepressant toxidrome. *Int J Emerg Med.* 2012; 5(1): 8. doi: [10.1186/1865-1380-5-8](https://doi.org/10.1186/1865-1380-5-8)
11. Hendron D, Menagh G, Sandilands E, Scullion D. Tricyclic Antidepressant Overdose in a Toddler Treated With Intravenous

Lipid Emulsion. *Pediatrics*. 2011; 128(6): e1628-e1632. doi: [10.1542/peds.2011-0867](https://doi.org/10.1542/peds.2011-0867)

12. Kuo I, Akpa BS. Validity of the lipid sink as a mechanism for the reversal of local anesthetic systemic toxicity: a physiologically based pharmacokinetic model study. *Anesthesiology*. 2013; 118(6): 1350-1361. doi: [10.1097/ALN.0b013e31828ce74d](https://doi.org/10.1097/ALN.0b013e31828ce74d)

13. Fettiplace MR, Lis K, Ripper R, et al. Multi-modal contributions to detoxification of acute pharmacotoxicity by a triglyceride micro-emulsion. *J Control Release*. 2015; 198: 62-70. doi: [10.1016/j.jconrel.2014.11.018](https://doi.org/10.1016/j.jconrel.2014.11.018)

14. Klein-Schwartz W, Shepherd JG, Gorman S, Dahl B. Characterization of gabapentin overdose using a poison center case series. *J Toxicol Clin Toxicol*. 2003; 41(1): 11-15. doi: [10.1081/CLT-120018265](https://doi.org/10.1081/CLT-120018265)