

## Case Report

### \*Corresponding author

Edward A. Monaco 3<sup>rd</sup>, MD, PhD

Assistant Professor

Department of Neurological Surgery

University of Pittsburgh Medical

Center, Suite F158, 200 Lothrop

Street, Pittsburgh, PA 15213, USA

Tel. 412-647-6777

Fax: 412-647-6483

E-mail: [monacoea2@upmc.edu](mailto:monacoea2@upmc.edu)

Volume 1 : Issue 1

Article Ref. #: 1000NOJ1107

### Article History

Received: November 13<sup>th</sup>, 2014

Accepted: December 15<sup>th</sup>, 2014

Published: December 16<sup>th</sup>, 2014

### Citation

Chen SH, Monaco EA 3<sup>rd</sup>. Intra-abdominal ventriculoperitoneal shunt abscess from *Streptococcus pyogenes* after pharyngitis with scarlet fever: Case report and review of the literature. *Neuro Open J*. 2014; 1(1): 27-30. doi: [10.17140/NOJ-1-107](https://doi.org/10.17140/NOJ-1-107)

### Copyright

©2014 Monaco EA 3<sup>rd</sup>. This is an open access article distributed under the Creative Commons Attribution 4.0 International License (CC BY 4.0), which permits unrestricted use, distribution, and reproduction in any medium, provided the original work is properly cited.

# Intra-Abdominal Ventriculoperitoneal Shunt Abscess from *Streptococcus Pyogenes* after Pharyngitis with Scarlet Fever: Case Report and Review of the Literature

Stephanie H. Chen and Edward A. Monaco 3<sup>rd</sup>\*

Department of Neurological Surgery, University of Pittsburgh Medical Center, Suite F158, 200 Lothrop Street, Pittsburgh, PA 15213, USA

### ABSTRACT

**Objective:** Infection is one of the most frequent complications of ventriculoperitoneal shunts. However, *Streptococcus pyogenes* (Group A *Streptococcus*, GAS) as a causative agent appears to be extremely rare. We present an unusual case of a peritoneal shunt infection due to GAS that occurred after pharyngitis with scarlet fever.

**Case Description:** A 31 year-old woman with congenital shunt-dependent hydrocephalus presented with fever, vomiting, and acute abdominal symptoms several weeks after being treated for pharyngitis and scarlet fever. She was found to have a large intra-abdominal peritoneal catheter-associated abscess that grew out GAS.

**Results:** The patient's shunt was externalized at the clavicle and the cerebrospinal fluid (CSF) was sterile. Her peritoneal abscess was treated by percutaneous drainage, laparotomy, and intravenous antibiotics. More permanent CSF diversion was accomplished *via* ventriculoatrial shunt creation after treatment. She made a full recovery.

**Conclusion:** While shunt infection is an all too common clinical problem, this is the first report of a peritoneal shunt infection caused by GAS after pharyngitis and scarlet fever. Presumably, this infection occurred as a result of haematogenous spread to the shunt site in the abdomen.

**KEYWORDS:** Abdominal abscess; Group A streptococcus; Shunt infection; *Streptococcus pyogenes*; Ventriculoperitoneal shunt.

### INTRODUCTION

Ventriculoperitoneal shunt (VPS) infections are frequent complications that result in shunt failure in 5-15% of patients.<sup>1</sup> Common causative agents include *Staphylococcus aureus*, Coagulase-negative staphylococcus species, a variety of gram-negative rods, *Propionibacterium* species, and *Enterococcus faecalis*. Other less common isolates include *Haemophilus influenzae* type B, *Klebsiella pneumoniae*, *Serratia marcescens*, Group B *Streptococcus*, *Streptococcus pneumoniae*, *Proteus mirabilis*, *Pseudomonas aeruginosa* and *Morganella morganii*.<sup>2</sup> The mechanism of shunt infection most frequently involves colonization of the shunt by skin flora at the time of surgery or postoperatively *via* breakdown of the wound. Alternatively, shunt infection can occur due to direct contamination of the peritoneal end of the shunt by gut flora in the setting of bowel perforation or peritonitis.<sup>3</sup>

We present a rare case of a hydrocephalic patient with a ventriculoperitoneal shunt who developed a *Streptococcus pyogenes* (Group A *Streptococcus*, GAS) peritoneal catheter-associated intra-abdominal abscess that occurred several weeks after pharyngitis and scarlet fever. GAS colonizes epithelial surfaces, primarily the throat and skin, but also the vagina and rectum, from where it can cause a wide array of superficial, invasive, and immune-mediated diseases. GAS most commonly causes mild infections such as pharyngitis and impetigo, but

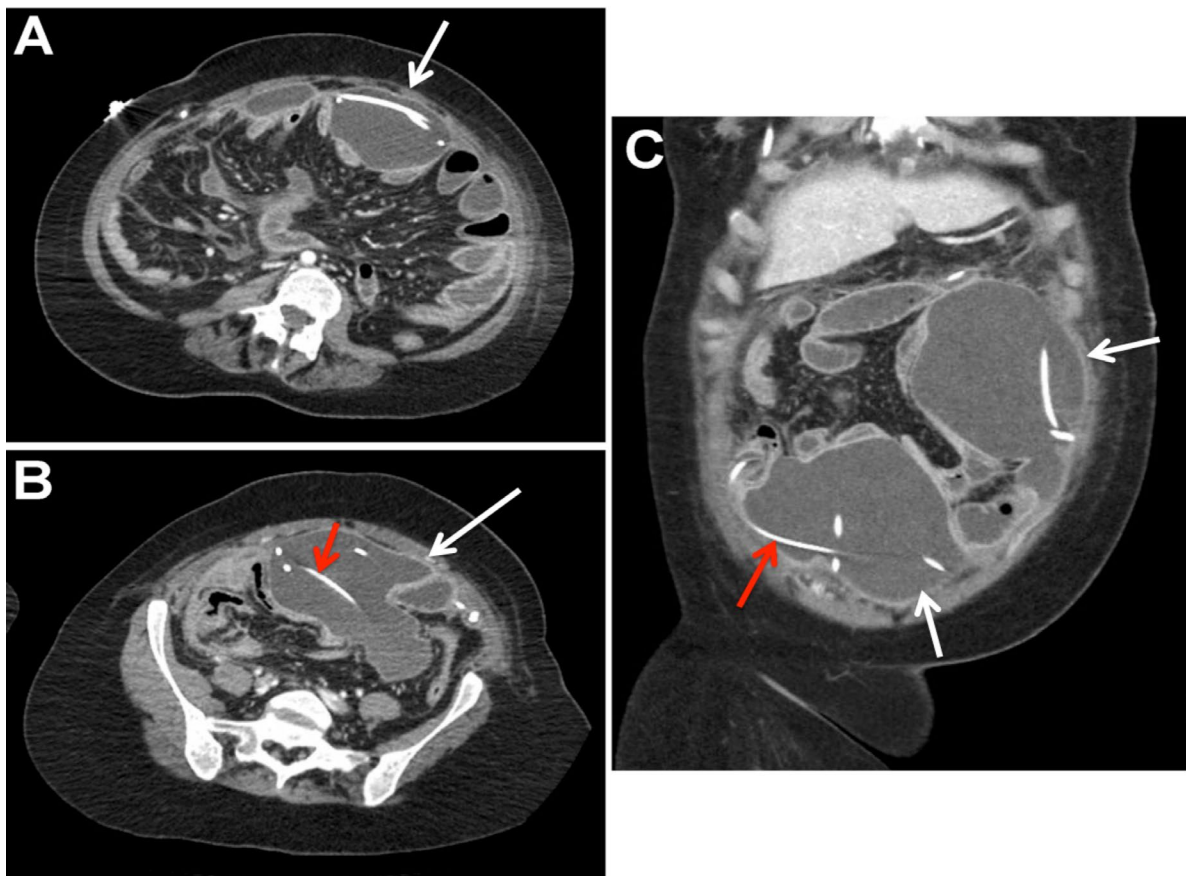
is also associated with serious non-suppurative complications such as acute rheumatic fever, acute glomerulonephritis, and toxic shock syndrome.<sup>4</sup> Suppurative complications include peritonsillar/retropharyngeal abscess, sinusitis, meningitis, brain abscess, or thrombosis of intracranial venous sinuses.<sup>4</sup> However, to our knowledge this is the first case of a peritoneal shunt abscess due to GAS following pharyngitis and scarlet fever reported in the literature. Only one other case of GAS shunt infection has been reported, however that case involved direct contamination of the cranial shunt site.<sup>5</sup>

### CASE REPORT

Our patient was a 31 year-old woman with a history of holoprosencephaly and VPS dependent congenital hydrocephalus requiring a total of nine previous shunt revisions. Her most recent revision was four years prior to presentation due to fractured shunt tubing in the neck. At that time, she underwent a complete shunt revision. The old distal catheter could not be completely removed due to calcification and scarring and was left in place from the upper chest down to the peritoneal cavity. Her immediate post-operative course from that surgery was uneventful with confirmation of correct shunt placement on x-ray and no evidence of CSF leak.

In late December 2013, she developed a systemic illness characterized by cough, fever, and scarlatiniform rash. A throat culture was unable to be obtained due to limited patient cooperation. She was clinically diagnosed with GAS pharyngitis and scarlet fever and treated with a seven-day course of amoxicillin. The patient's symptoms did not completely resolve and she was treated with a second 7-day course of amoxicillin for presumed streptococcal pharyngitis in February 2014.

Approximately three weeks later, the patient developed fevers, diaphoresis, diarrhea, and bilious vomiting. She presented to the emergency department at our institution. On physical examination she was febrile to 38.7, tachycardic to the 130s, and with a normal blood pressure. She was at her neurological baseline. Her abdomen was soft, distended, and tender to palpation. Her white blood cell count was elevated, measuring  $15.4 \times 10^9/L$  with 61% neutrophils and 20% bands. Elevated inflammatory markers were also identified including an erythrocyte sedimentation rate of 103 mm/hr and platelet count of  $635 \times 10^9/L$ . A Computed Tomography (CT) scan of the abdomen was obtained and revealed a large anterior intra-abdominal loculated fluid collection involving the two VPS peritoneal catheters (Figure 1). CT imaging of her head was unchanged from her previous studies.



**Figure 1:** Contrast-enhanced computed tomography scan of the abdomen with L5 axial (A), S1 axial (B), and coronal (C) images demonstrating the peritoneal catheters (red arrow) within the large, loculated abdominal abscess (white arrows).

The shunt was immediately externalized at the clavicle and cerebrospinal fluid was evaluated showing: one erythrocyte and no leukocytes per mm<sup>3</sup>, glucose of 104 mg/dL, and protein of 10 mg/dL. The patient immediately underwent ultrasound guided percutaneous drainage of the abdominal collection that revealed pus. The resulting cultures of the peritoneal abscess grew numerous colonies of GAS sensitive to penicillin. Blood and CSF cultures showed no growth. Given extensive adhesions and loculations, a laparotomy was required to remove the distal shunt catheters and complete the abscess evacuation.

The patient was treated with a 14-day course of vancomycin given the patient's known allergy to cephalosporins. After a transthoracic echocardiogram revealed no vegetations, a ventriculoatrial shunt was created to definitively manage her hydrocephalus. This was performed without complications and patient had no subsequent sequelae of her infection.

## CONCLUSIONS

Peritoneal GAS shunt-related abscess could be a potential complication of GAS pharyngitis with scarlet fever in a patient with a VPS. Clinicians should be aware of the possibility of hematogenous spread of GAS and VPS infection. A combination of abscess drainage, surgical removal of shunt tubing, and antibiotic therapy was successful in this case. Ventriculoatrial shunting is a reasonable option for CSF diversion when the peritoneum is prohibited due to infection or adhesions.

## DISCUSSION

*Streptococcus pyogenes* is the most common bacterial cause of pharyngitis with over 600 million cases per year.<sup>6</sup> Occasionally, GAS pharyngitis is accompanied by scarlet fever, which manifests as a diffuse erythematous and finely papular rash, "strawberry tongue", and exudative pharyngitis. Development of the scarlet fever rash is thought to be the result of delayed-type skin reactivity to streptococcal pyrogenic exotoxins produced by the organism.<sup>4</sup>

Less commonly, GAS has the capacity to breach epithelial barriers and cause a variety of invasive diseases. The incidence of severe invasive GAS infections in North America has been estimated to be 1.5 -7.0 cases per 100,000 persons annually.<sup>7</sup> Invasive GAS infection is defined as an infection associated with isolation of GAS from a normally sterile body site. Acute peritonitis caused by GAS is a form of invasive infection that is rarely diagnosed in a person without underlying disease such as hepatic cirrhosis, immunosuppression, or nephrotic syndrome.<sup>8</sup> In the few cases reported describing GAS peritonitis in healthy women, the entry sites of GAS were not well understood. Ascending genital infections are thought to be the major primary source,<sup>8</sup> however other possible primary locations of infection are respiratory tract and cutaneous sites with hematogenous spread of bacteria.<sup>9</sup> Direct transluminal spread from the bowel has also been suggested in the pathogenesis of primary

GAS peritonitis.<sup>10</sup> However, given the preceding pharyngitis in our case, hematogenous spread of GAS to the peritoneum is the most plausible mechanism of infection.

Hematogenous spread as a mode of VPS associated abscess is not well described in the literature. The occurrence of an abdominal abscess following VPS placement is rare, accounting for only 5% of intra-abdominal shunt related complications in one retrospective study.<sup>11</sup> The organisms isolated from VPS related abdominal abscesses include *pseudomonas*,<sup>2</sup> *staphylococci* and *enterococcus*,<sup>12</sup> consistent with the most common organisms associated with VPS infections. Hepatic abscesses are the most commonly reported intra-abdominal location in the literature. The pathogenic mechanisms postulated are penetration of the shunt tube into the liver and subsequent abscess formation from bacterial translocation from skin flora versus seeding into the liver via portal veins due to intraabdominal sepsis.<sup>13</sup> In our patient, the VPS may have served as a nidus for the infection given the large collections surrounding the near entirety of the tubing in the peritoneal cavity.

There has only been one other case of a GAS shunt infection reported in the literature. Patel et al. describe a 7-year-old male who presented with purulent drainage from a cranial shunt site, with GAS isolated from the wound and CSF cultures.<sup>5</sup> The mechanism of infection was hypothesized to be autoinoculation from a pharyngeal source as the patient frequently placed his fingers in his mouth and scratched his shunt site. Alternatively, GAS meningitis is a known but rare manifestation of invasive GAS infections, and may have resulted in a secondary shunt infection.<sup>14</sup> However, these mechanisms are not likely to be responsible for the shunt infection in our case as the intra-abdominal GAS abscess did not track to the skin and there was no evidence of a CSF infection. Additionally, our patient's shunt revision surgery was distant enough in the past (4 years prior) that infection from bacterial translocation from skin was unlikely.

The occurrence of a peritoneal shunt infection necessitates shunt externalization and drainage of the infected collection.<sup>15</sup> The options for hydrocephalus management thereafter include: replacement of shunt into peritoneum, ventriculoatrial shunt, or placement of shunt tube into pleural cavity. In our case, the recent infection and extensive adhesions within the abdomen excluded the peritoneum as a viable shunt site. A ventriculoatrial shunt was placed for long-term management of hydrocephalus given the patient's high output of CSF.

## ACKNOWLEDGEMENTS

There is no funding source for the work contained in this manuscript.

## CONFLICTS OF INTEREST

The authors have no conflicts of interest to report.

**CONSENT**

Consent for treatment and publication of this report was obtained.

**REFERENCES**

1. McGirt MJ, Zaas A, Fuchs HE, George TM, Kaye K, Sexton DJ. Risk factors for pediatric ventriculoperitoneal shunt infection and predictors of infectious pathogens. *Clin Infect Dis*. 2003; 36: 858-862. doi: [10.1086/368191](https://doi.org/10.1086/368191)
2. Stamos JK, Kaufman BA, Yogev R. Ventriculoperitoneal shunt infections with gram- negative bacteria. *Neurosurgery*. 1993; 33: 858-862.
3. Rubin RC, GhatakNR, Visudhipan P. Asymptomatic perforated viscus and gram- negative ventriculitis as a complication of valve-regulated ventriculoperitoneal shunts. Report of two cases. *J Neurosurg*. 1972; 37: 616-618. doi: [10.3171/jns.1972.37.5.0616](https://doi.org/10.3171/jns.1972.37.5.0616)
4. Walker MJ, Barnett TC, McArthur JD, et al. Disease manifestations and pathogenic mechanisms of group a Streptococcus. *Clin Microbiol Rev*. 2014; 27: 264-301. doi: [10.1128/CMR.00101-13](https://doi.org/10.1128/CMR.00101-13)
5. Patel C, Chaudhuri NR, Gaur S. Group A streptococcus ventriculoperitoneal shunt infection in a child. *Pediatr Infect Dis J*. 2012; 31: 660. doi: [10.1097/INF.0b013e31824c04a5](https://doi.org/10.1097/INF.0b013e31824c04a5)
6. O'Brien KL, Beall B, Barrett NL, et al. Epidemiology of invasive group a streptococcus disease in the United States, 1995-1999. *Clin Infect Dis*. 2002; 35: 268-276. doi: [10.1086/341409](https://doi.org/10.1086/341409)
7. American Academy of Pediatrics. Committee on Infectious Diseases. Severe invasive group A streptococcal infections: a subject review. *Pediatrics*. 1998; 101: 136-140.
8. Moskovitz M, Ehrenberg E, Grieco R, et al. Primary peritonitis due to group A streptococcus. *J Clin Gastroenterol*. 2000; 30: 332-335.
9. Martin PR, Hoiby EA. Streptococcal serogroup A epidemic in Norway 1987-1988. *Scand J Infect Dis*. 1990; 22: 421-429.
10. Schweinburg FB, Seligman AM, Fine J. Transmural migration of intestinal bacteria; a study based on the use of radioactive Escherichia coli. *N Engl J Med*. 1950; 242: 747-751. doi: [10.1056/NEJM195005112421903](https://doi.org/10.1056/NEJM195005112421903)
11. Chung JJ, Yu JS, Kim JH, Nam SJ, Kim MJ. Intraabdominal complications secondary to ventriculoperitoneal shunts: CT findings and review of the literature. *AJR Am J Roentgenol*. 2009; 193: 1311-1317. doi: [10.2214/AJR.09.2463](https://doi.org/10.2214/AJR.09.2463)
12. Popa F, Grigorean VT, Onose G, Popescu M, Strambu V, Sandu AM. Laparoscopic treatment of abdominal complications following ventriculoperitoneal shunt. *J Med Life*. 2009; 2: 426-436.
13. Yang TK, Sim KB. Multiple liver abscesses associated with ventriculoperitoneal shunt infection: case report and review of the literature. *J Korean Neurosurg Soc*. 2013; 54: 441-443. doi: [10.3340/jkns.2013.54.5.441](https://doi.org/10.3340/jkns.2013.54.5.441)
- 14 de Almeida Torres RS, Fedalto LE, de Almeida Torres RF, Steer AC, Smeesters PR. Group A streptococcus meningitis in children. *Pediatr Infect Dis J*. 2013; 32: 110-114. doi: [10.1097/INF.0b013e31826fd4af](https://doi.org/10.1097/INF.0b013e31826fd4af)
15. James HE, Walsh JW, Wilson HD, Connor JD. The management of cerebrospinal fluid shunt infections: a clinical experience. *Acta Neurochir (Wien)*. 1981; 59: 157-166.