

## Case Report

### \*Corresponding author

**Jorge de Tomás, PhD**

Associate Professor of Surgery  
Department of General Surgery  
University General Hospital Gregorio  
Marañón, Calle del Doctor Esquerdo  
46, 28007 Madrid, Spain

E-mail: [jdetomaspal@hotmail.com](mailto:jdetomaspal@hotmail.com)

Volume 1 : Issue 1

Article Ref. #: 1000OROJ1101

### Article History

Received: November 6<sup>th</sup>, 2014

Accepted: December 15<sup>th</sup>, 2014

Published: December 18<sup>th</sup>, 2014

### Citation

de Tomás J, Lusilla A, Burneo M, Franco R, Maria-Monturiol J. Improvement of ventricular ejection fraction after bariatric surgery in obese patients with dilated cardiomyopathy. *Obes Res Open J*. 2014; 1(1): 1-3. doi: [10.17140/OROJ-1-101](https://doi.org/10.17140/OROJ-1-101)

### Copyright

©2014 de Tomás J. This is an open access article distributed under the Creative Commons Attribution 4.0 International License (CC BY 4.0), which permits unrestricted use, distribution, and reproduction in any medium, provided the original work is properly cited.

# Improvement of Ventricular Ejection Fraction after Bariatric Surgery in Obese Patients with Dilated Cardiomyopathy

**Jorge de Tomás\*, Alejandro Lusilla, Mauricio Burneo, Rocio Franco and Jose Maria-Monturiol**

*Department of General Surgery, University General Hospital Gregorio Marañón, Calle del Doctor Esquerdo, 46, 28007 Madrid, Spain*

### ABSTRACT

Morbid obesity has been considered a contraindication for cardiac transplantation in some patients with Dilated cardiomyopathy (DCM). However, the positive effect of bariatric surgery on this population, with improvement in Ventricular Ejection Fraction (VEF), could even avoid the necessity of a cardiac transplant. Obesity produces cardiac dysfunction and weight loss operations can partially revert it.

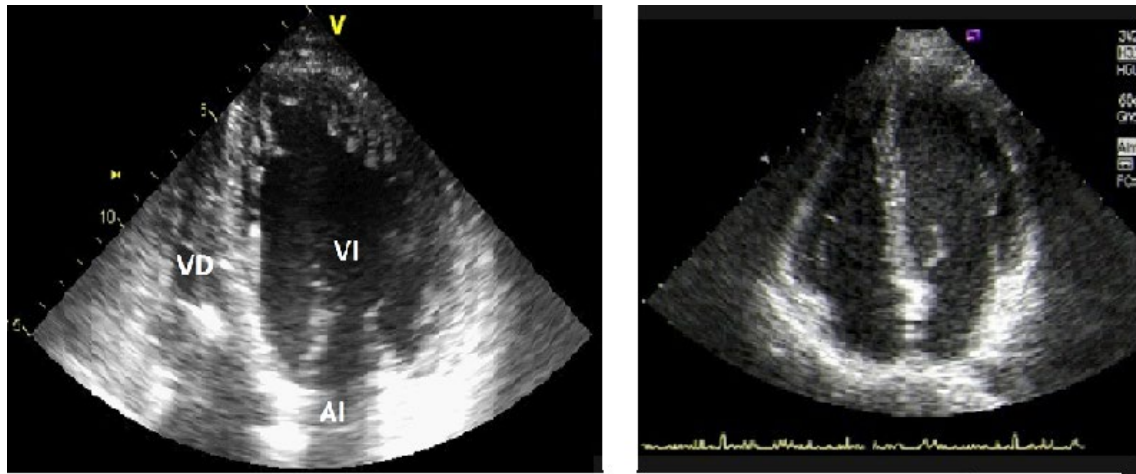
The impact of bariatric surgery among people with DCM has been studied in two patients with morbid obesity. Both male patients suffered from DCM with a VEF less than 27%, and other co-morbidities. Their Body Mass Index (BMI) was 44 kg/m<sup>2</sup> and 37 kg/m<sup>2</sup>, respectively. They underwent a sleeve gastrectomy and reached a BMI of 28 kg/m<sup>2</sup>, 18 months after the operation, with more than 10% improvement in their VEF. The second patient had a gastric leak, due a stapler failure, and finally underwent an uneventful total gastrectomy after unsuccessful endoscopic procedures.

In conclusion, bariatric surgery offers a significant benefit for obese patients with DCM and should be considered by cardiologists as other therapeutic approach when other weight loss strategies had failed.

**KEYWORDS:** Dilated cardiomyopathy (DCM); Ventricular Ejection Fraction (VEF); Bariatric surgery; Morbid Obesity (MO).

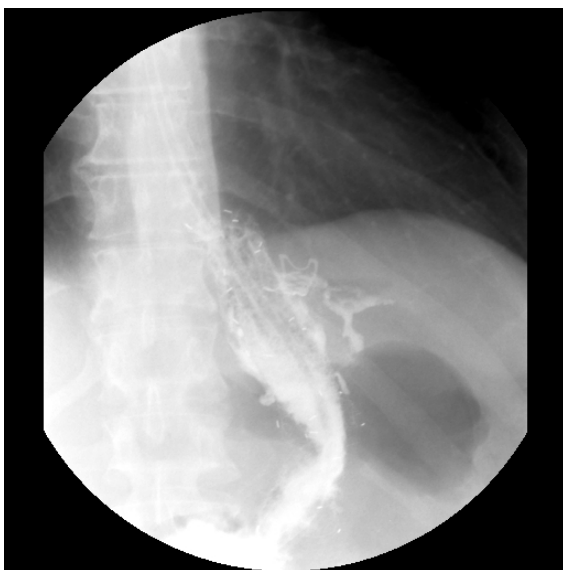### CASE REPORTS

**Case 1:** A 54-year-old male with Sleep Apnea Syndrome (SAS), Diabetes Mellitus (DM) type 2, hypertension, Morbid Obesity (MO) and Dilated cardiomyopathy (DCM) was referred to our hospital for bariatric surgery. In addition, the preoperative cardiac ultrasound showed a Ventricular Ejection Fraction (VEF) of 24%. He had a Body Mass Index (BMI) of 41 kg/m<sup>2</sup> and underwent an uneventful Sleeve Gastrectomy (SG). Three years after the surgical procedure, the patient co-morbidities and quality of life have improved, and the cardiac ultrasound confirmed an increase of his VEF from 24% to 36% (Figure 1A-1B).



**Figure 1A:** Preoperative cardiac ultrasound in case 1 showing a dilated left ventricle. **1B:** The cardiac ultrasound, 12 months later, revealed a decreased in left ventricular dilation and a ventricular ejection fraction improvement.

**Case 2:** A 46-year-old male with DM type 2, hepatitis B, hypertension, MO and DCM, was operated on with a VEF of 27%. On physical examination, a BMI of 37 kg/m<sup>2</sup> was the most relevant finding. During the SG, the last cartridge of the stapler failed and the patient developed a leak near the esophagogastric junction, albeit a prompt reoperation was done during the first 48 hours. All the subsequent therapeutic approaches with stents, glues or metallic clips were unsuccessful (Figure 2) and finally, a total gastrectomy was performed, with an excellent recovery. 18 months after the first bariatric procedure, the patient showed an improvement of 10% in his VEF as well as in his co-morbidities.



**Figure 2:** Barium swallow of case 2 patient after failure to control the gastric leak (V) by a metallic clip (arrow).

In both cases, the BMI was under 28 kg/m<sup>2</sup> after the first year of the bariatric operation.

**DISCUSSION**

Obesity causes anatomical and functional heart impairment, which can be ameliorated with weight loss surgery, as an increase in cardiac output, preload and post-load.<sup>1-3</sup> In patients with DCM, these hemodynamic changes produce impairment in the systolic left ventricular function and a larger heart dilatation. In the recent literature there is some evidence about the positive impact of BS on specific cases of heart disease as DCM.<sup>3-6</sup> Furthermore, some patients with DCM who are in an end-stage heart failure have been denied cardiac transplantation due to MO. Nevertheless, it has been shown that the cardiac function improvement after different bariatric procedures can avoid the necessity of an ulterior cardiac transplantation.<sup>4-6</sup>

On the other hand, those patients usually have other co-morbidities linked to the metabolic syndrome (SAS, DM, hypertension) that improve after weight loss.

Which bariatric technique is the best for such patients?

This is a difficult question but the simplest is the best in this scenario. For this reason, we preferred sleeve gastrectomy instead of gastric bypass. However, we had a dreadful complication in our second case due to a technical problem but, at the end, the gastric leak was solved and the patient was able to experiment the benefits of a significant loss of his weight.

If we focus on functional heart changes, VEF increase is perhaps one of the most relevant indicators, and it has been highlighted in other cases.<sup>4,6</sup> Nowadays, is appropriate to confirm the durability of this benefit and how is the long-term heart

behaviour of these patients with larger prospective studies.

In summary, BS offers an important improvement in obese patients with DCM. Thus, it should be considered when other weight loss approaches were unsuccessful because bariatric operations are quite safe and effective at the present time.

#### REFERENCES

1. Luaces M, Cachofeiro V, García-Muñoz-Najar A, et al. Anatomical and functional alterations of the heart in morbid obesity. Changes after bariatric surgery. *Rev Esp Cardiol.* 2012; 65(1): 14-21. doi: [10.1016/j.recesp.2011.06.018](https://doi.org/10.1016/j.recesp.2011.06.018)
2. Garza CA, Pellikka PA, Somers VK, et al. Structural and functional changes in left and right ventricles after major weight loss following bariatric surgery for morbid obesity. *Am J Cardiol.* 2010; 105(4): 550-556. doi: [10.1016/j.amjcard.2009.09.057](https://doi.org/10.1016/j.amjcard.2009.09.057)
3. González-Mansilla A, de Tomás J, Yotti R, Álvarez-Llano L. Cardiac functional and structural improvement after vertical gastrectomy in an obese patient with noncompactation cardiomyopathy. *Med Clin (Barc).* 2014; 143(8): 377-378. doi: [10.1016/j.medcli.2014.01.005](https://doi.org/10.1016/j.medcli.2014.01.005)
4. Ristow B, Rabkin J, Haeusslein E. Improvement in dilated cardiomyopathy after bariatric surgery. *J Card Fail.* 2008; 14(3): 198-202. doi: [10.1016/j.cardfail.2007.12.006](https://doi.org/10.1016/j.cardfail.2007.12.006)
5. Samaras K, Connolly SM, Lord RV, Macdonald P, Hayward CS. Take heart: bariatric surgery in obese patients with severe heart failure. Two cases reports. *Heart Lung Circ.* 2012; 21(12): 847-849. doi: [10.1016/j.hlc.2012.05.783](https://doi.org/10.1016/j.hlc.2012.05.783)
6. McCloskey CA, Ramani GV, Mathier MA, et al. Bariatric surgery improves cardiac function in morbidly obese patients with severe cardiomyopathy. *Surg Obes Relat Dis.* 2007; 3(5): 503-507. doi: <http://dx.doi.org/10.1016/j.soard.2007.05.006>