Openventio PUBLISHERS

ISSN 2377-1542

GYNECOLOGY AND OBSTETRICS RESEARCH

Open Journal

| December 2017 | Volume 4 | Issue 2 |

www.openventio.org

GYNECOLOGY AND OBSTETRICS RESEARCH

Openventio PUBLISHERS

ISSN 2377-1542

Open Journal

CONTENTS

GYNECOLOGY AND OBSTETRICS RESEARCH

Openventio PUBLISHERS

ISSN 2377-1542 Open Journal http://dx.doi.org/10.17140/GOROJ-4-140

Review

*Corresponding author
Ayman S. Dawood, MD
Department of Obstetrics and Gynecology, Faculty of Medicine
Tanta University, Tanta, Egypt
Tel. +201020972067
E-mail: ayman.dawood@med.tanta.edu.eg

Volume 4 : Issue 2
Article Ref. #: 1000GOROJ4140

Article History
Received: May 21st, 2017
Accepted: June 21st, 2017
Published: June 22nd, 2017

Citation
Dawood AS, Omar MK. Competing endoscopic surgeries in the era of assisted reproductive technologies: Evidence and practice. *Gynecol Obstet Res Open J*. 2017; 4(2): 20-29. doi: 10.17140/GOROJ-4-140

Competing Endoscopic Surgeries in the Era of Assisted Reproductive Technologies: Evidence and Practice

Ayman S. Dawood, MD*; Mona K. Omar, MD

Department of Obstetrics and Gynecology, Tanta University, Tanta, Egypt

ABSTRACT

Now-a-days the assisted reproductive technologies (ART) are progressing and advancing rapidly. Many reproductive medicine specialists do believe in ART to be the first choice for infertile women regardless of age related issues while gynecologists do believe in reproductive surgery as basic treatment option for these patients. Debate is still unsolved between reproductive surgery or ART which is the first choice for management of infertility. Many issues increase the complexity of the debate as age of infertile patient, ovarian reserve and previous management whether surgery or ART. In this review, both aspects were discussed to clear some aspects of this debate. The objective of this review is to highlight this debate and mention the aspects which help gynecologists and reproductive surgeons to choose the best for infertile patients.

KEY WORDS: Endoscopic reproductive surgeries; Assisted reproductive technologies; *In Vitro* fertilisation/Intracytoplasmic sperm injection (IVF/ICSI).

ABBREVIATIONS: ART: Assisted Reproductive Technologies; IVF: *In Vitro* Fertilisation; ICSI: Intracytoplasmic sperm injection; LOD: Laparoscopic Ovarian Drilling; CPR: Cumulative Pregnancy Rates; PCOS: Polycystic Ovary Syndrome.

INTRODUCTION

The role of endoscopic surgeries prior to assisted reproductive technologies (ART) is a matter of debate where some studies stress on its importance, other studies confirm its importance only in selected cases, and other studies minimize its role before *in vitro* fertilisation/intracytoplasmic sperm injection (IVF/ICSI) procedures.[1,2]

Now-a-days IVF/ICSI procedures are widely spread worldwide and are replacing reproductive surgical procedures limiting its role as first-line treatment. This change in clinical practice may be due to the higher cost-effectiveness of IVF/ICSI compared to reproductive surgery or may be preferred due to other factors such as a lack of surgical expertise, patient's desires to achieve rapid results or the fear of procedure-related complications.[3]

ENDOSCOPIC TUBAL SURGERY

Tubal surgery is the first-line management option for young women less than 35-years-old with minor tubal pathology. The second option should be IVF if there are other factors affecting fertility, if the patient is >38-years-old, if patient had moderate to severe tubal disease, and if one year or more had passed post-surgery for tubal pathology.[4]

Salpingectomy and ART

Hydrosalpix is a common tubal pathology that affects IVF/ICSI results by many mechanisms. Surgical treatment should be considered for all women with hydrosalpinges prior to IVF/ICSI procedures. Previous evidence supported only unilateral salpingectomy for a unilateral hydro-

ISSN 2377-1542
http://dx.doi.org/10.17140/GOROJ-4-140

salpinx (bilateral salpingectomy for bilateral hydrosalpinges). Now evidence supports laparoscopic tubal occlusion as an alternative to laparoscopic salpingectomy in improving IVF pregnancy rates in women with hydrosalpinges.[5]

Further studies are required to assess the value of aspiration of hydrosalpinges prior to or during IVF/ICSI procedures and also the value of tubal plastic surgery as an alternative (or as a preliminary) to IVF.[5]

Other studies were not advocating salpingectomy prior IVF/ICSI due to its deleterious effects on ovarian reserve. Available data suggested an absence of variation in ovarian reserve markers after unilateral salpingectomy while contradictory results were reported for bilateral surgery. Evidence supports unilateral salpingectomy and considers it a safe procedure, without negative effects on ovarian reserve and ovarian response to gonadotropins stimulation; moreover, it has a positive effect on pregnancy rate. Benefits of bilateral salpingectomy before IVF/ICSI and its safety on ovarian reserve, needed to be confirmed by further trials as the available studies regarding this issue are conflicting.[6]

Tubal Cannulation and ART

Tubal block is another tubal pathology where some studies advocate laparoscopic salpingectomy prior IVF/ICSI procedures as it has a significant improvement in ongoing pregnancy/live-birth rate without significant reduction in ovarian response to gonadotropin stimulation.[7]

Honoré et al[8] in a meta-analysis examined the value of tubal microsurgery and macrosurgery, and hysteroscopic management of proximal tubal occlusion. They found that the average pregnancy rate was higher in women managed by hysteroscopic tubal recanalization compared with those managed with tubal microsurgery and open surgery or selective salpingography (48.9% *vs*. 38% *vs*. 28.8%, respectively).

A more recent review evaluated success and pregnancy rates of tubal recanalization with hysteroscopy where the success rates ranged from 57% to 88% with partially occluded tubes or with complete occlusion in the cornual, proximal, and intramural/interstitial portions of the fallopian tube. One study that was reviewed reported a success rate of 13.3% for distal tubal occlusion after hysteroscopic tubal cannulation.[9]

Tubal Sterilization Reversal and ART

Laparoscopic tubal reversal is a difficult operation, time consuming and success rates are comparable to IVF/ICSI procedures allowing many gynecologists to choose ART over laparoscopic reversal of tubal sterilization.[10,11]

Considering number of desired children, cost/benefit ratioand age of patient may change the choice between the 2 treatment options for laparoscopic tubal reversal over ART especially if patient is young and wishing more children. If only one more child is desired and the woman is older than 35 years of age, perhaps IVF is the best choice.[10,11]

Beyond age 40, the success with either tubal reversal or IVF is extremely low less than 1-3% in most reports. In this situation cost/benefit ratio should be considered and tubal reversal becomes the more cost-effective option.[12]

In a Belgian retrospective study published in 2007, the difference in pregnancy rates between IVF and tubal reversal were statistically insignificant until they were examined by age of the woman. It became clear that cumulative pregnancy rates for women under 37 were significantly better for tubal reversal; for women over age 37 the rates were better for IVF. However, for all age groups in all published reports the success-per-cycle rates in IVF are better than those for tubal reversal.[13]

The decision between IVF and tubal reversal is highly complex and profoundly affected by the factors of age, cost and time as well as the presence of other potential infertility problems. Each couple facing this decision must be assessed and counseled individually to ensure selection of the treatment option best suited to them.[10-13]

ENDOSCOPIC UTERINE SURGERY

Although, a great progress in ART occurs every day, there are still unknown factors limiting successful implantation and decreasing percentage of both clinical and ongoing pregnancy rates. These facts suggest an underestimated role for the uterus in the success rates of ART.[14]

Some studies advocated and recommended the use of office hysteroscopy as a routine procedure in the infertility work-up.[15-19] It has become easy to perform in an outpatient setting without anesthesia. Moreover, it offers direct visualization and enables clinicians to diagnose and treat intrauterine pathology during the same session.[20,21]

One study found a significant concordance between 3D transvaginal ultrasound and hysteroscopy (*RR* 0·77, 95% CI 0·6-0·84). The authors advocated 3D ultrasound imaging of uterine cavity prior to IVF/ICSI even in women recurrent implantation failure and considered 3D a sufficient tool for evaluation of the endometrial cavity before IVF. That study stated that any problems missed by conventional transvaginal ultrasound are not relevant to the outcomes of IVF.[22]

Recent studies, address the importance of the morphological evaluation of the uterus through assessment of the effect of office hysteroscopy on IVF outcomes in women undergoing IVF for the first time and in women with recurrent implantation failure.[23-25]

The results of these studies suggest that there is no reason to perform hysteroscopy before IVF, irrespective of whether

ISSN 2377-1542
http://dx.doi.org/10.17140/GOROJ-4-140

the woman is about to undergo the first cycle of IVF or if she has undergone several failed IVF attempts, as long as conventional transvaginal ultrasound shows no uterine pathology. These studies did not find an answer on the significance of hysterescopic correction of the common intrauterine lesions as polyps, submucous myomata or partial septae prior to IVF/ICSI and their relation to pregnancy rates.[23-25]

ENDOMETRIAL TRAUMA PRIOR INTRACYTOPLASMIC *IN VITRO* FERTILISATION/SPERM INJECTION (IVF/ICSI)

From practical point of view, many gynecologists and reproductive medicine specialists trust in diagnostic plus traumatic effects of hysteroscopy prior IVF/ICSI cycles. On the other hand evidence proved that hysteroscopy does not seem to improve implantation through a hypothetical pro-inflammatory effect.[25]

Hystereoscopy after Repeated IVF Failures

Hysteroscopy increases pregnancy rates even in the absence of intrauterine pathology in women with recurrent IVF failure. This could be explained by the cervical dilatation and/or direct hysteroscopic visualisation of the uterine cavity facilitating embryo transfer or alternatively by an immunological mechanism triggered by the hysteroscopic manipulation or by the effect of the distension medium on the endometrium.[26]

Uterine Fibroids and ART

Submucosal fibroids negatively affect fertility, especially fibroids larger than 4 cm, even without cavity distortion. Fibroids impair fertility by many mechanisms involving alteration of local anatomical location, inducing functional changes of the myometrium and endometrium, and finally endocrine and paracrine molecular mechanisms which could alone or in combination cause reduced reproductive potential, impaired gamete transport, diminished implantation, and creation of a hostile environment.[27]

Hysteroscopic excision of submucosal myomas seems to restore fertility with pregnancy rates after surgery similar to normal controls. Even open excision of intramural myomas seems to be associated with higher pregnancy rates when compared to non-operated controls, although evidence is still not sufficient. The results of endoscopic and open myomectomy are similar; thus, endoscopic treatment is the recommended approach due to its advantages in patient's post-operative course.[28]

Casini et al[29] analyzed whether the removal of fibroids before conception improves pregnancy rates and outcomes compared with no surgery. In that study 92 patients underwent myomectomy, *via* either hysteroscopy or laparotomy, and 89 patients did not undergo surgery. All patients were followed-up for 12 months to determine the rate of clinical pregnancy. Higher pregnancy rates were observed in the patients who underwent myomectomy with submucous fibroids (43.35% *vs*. 27.2% in the non-surgical group) or submucous and intramural fibroids (36.4% *vs*. 15% in the non-surgical group) ($p<0.05$). There was no statistically significant increase in pregnancy rate in the patients with only intramural or intramural and subserosal fibroids ($p>0.05$).

Pritts et al[30] in a meta-analysis of 23 studies evaluating women with fibroids and infertility. The authors found that a large difference between infertile women with submucous fibroids and those without submucous fibroids as regard pregnancy rate, implantation, and ongoing pregnancy/live birth rates, as well as the spontaneous abortion rate. They found also that women who underwent a hysteroscopic myomectomy had greater clinical pregnancy rate compared with those with fibroids left *in situ*.[30]

Cochrane database found that in a subset of women with a submucous fibroid (n=94), there was a statistically insignificant increased odds of clinical pregnancy (odds ratio, 2.4; 95% confidence interval, 0.97-6.2; $p=0.06$).[31] Shokeir et al[32] found similar results in their randomized controlled study.

Uterine Septum Surgery and ART

The debate for infertile women with uterine disease, such as myoma and adenomyosis, is whether infertility treatment including ART should be the first choice considering the aging of eggs, or whether surgery for uterine disease (as the cause of infertility) should precede ART.[33]

Abnormal uterine anatomy and function are major factors affecting success of fertility treatments. Uterine pathologies, including congenital or acquired lesions, have been reported in 21-47% of patients undergoing *in vitro* fertilization cycles. In another study these abnormalities were found to be lower than reported representing only 11%.[34,35]

Some studies answered the question that hysteroscopy could enhance fertility in cavitary uterine lesions or not where they found that hysteroscopic surgery enhanced fertility in most of the congenital and acquired problems affecting women and concluded that both diagnostic and operative hysteroscopy are rapid and safe procedures to improve fertility.[34,36]

Uterine septum is not only associated with infertility but also is associated with increase rates of pregnancy loss as high as 90%. The American Fertility Association (AFA), now known as the American Society of Reproductive Medicine (ASRM), explained these septum related pregnancy wastages by structural alterations in the endometrium of the septum, which affects implantation.[37]

Mollo et al[38] studied 2 groups with unexplained fertility, a group of women with septate uteri who underwent hysteroscopic metroplasty and a control group without septate uteri. The 2 groups were similar in terms of age, duration of infertility, and body mass index (BMI). The pregnancy rate and live birth rate were significantly higher in the hysteroscopic metroplasty group

ISSN 2377-1542 http://dx.doi.org/10.17140/GOROJ-4-140

compared with the control group (38.6% *vs*. 20.4%; p=0.016 and 34.1% *vs*. 18.9%; p<0.05, respectively).

Pabuçcu and Gomel[39] evaluated women aged 21-35 years with unexplained primary fertility and septate uteri who underwent hysteroscopic metroplasty. Five women (8.2%) underwent repeat surgery for a residual septum >1 cm. The outcome of that study was a 41% pregnancy rate, with a 29.5% live birth rate. In 13 of the 18 pregnancies that carried to term, 2 patients had a total septum and 11 had a subtotal septum resected.

Although, hysteroscopic metroplasty appears to improve fertility, the role of surgical correction in patients with primary infertility remains under debate. An older prospective study identified a reduction in pregnancy wastage from 87.5-44.4% and recommended hysteroscopic metroplasty as the treatment of choice in patients experiencing recurrent abortions.[39,40]

Looking further at septum length, Shokeir et al[41] studied women with septum length of ≥2.5 cm and compared them with women with a septum length of <2.5 cm. All of the 42 women (47.7%) who achieved pregnancy were age <40 years with <3 years of infertility; 8% of these pregnancies were spontaneous. The pregnancy rate was 66.7% in those with a septum length of ≥2.5 cm and 42.8% in those with a septum length of <2.5 cm. The overall live birth rate was 40.1%.[41]

Grimbizis et al[42] reviewed 6 studies published before 2001 that reported a live birth rate of 6.1% in women with intact septums compared with 82% in those women who underwent hysteroscopic metroplasty. Nouri et al[43] performed a more recent literature search that revealed live birth rates ranging from 26% to 73%, with a cumulative rate of 45%, after hysteroscopic metroplasty. Both of these reviews evaluated studies in women with a septate uterus, and both unexplained primary infertility and recurrent abortions.

More recently Abuzeid et al[44], conducted a historical cohort study, to determine reproductive outcome after (IVF/ICSI) in women with primary infertility following hysteroscopic septoplasty of incomplete uterine septum or arcuate uterine anomaly. They found that there was no significant difference between the hysteroscopic septoplasty and control groups in the clinical pregnancy (74.4% *vs*. 67.3%) or in the delivery (65.4% *vs*. 60.2%) rates per patient, respectively. They concluded that reproductive outcome of *in vitro* fertilization pre-embryo transfer (IVF-ET) after hysteroscopic correction of incomplete uterine septum/arcuate uterine anomaly in women with primary infertility is no different from women with normal uterine cavity.

Uterine Polyp Excision and ART

Uterine polyps can cause infertility by many mechanisms which include irregular endometrial bleeding, inflammatory endometrial response, obstructive inhibition of sperm transport, physical obstruction of exposure of the embryo to the endometrium, interference with normal patterns of endocrine function, and inhibition of sperm binding to the zona pellucida.[45]

In 2005, Pérez-Medina et al[46] evaluated 204 women with infertility for 2 years or more. The study group (n=101) underwent hysteroscopic polypectomy, whereas the control group (n=103) underwent hysteroscopic polyp biopsy only. After either procedure, participants were to receive up to 4 intrauterine insemination cycles. They concluded that, there were no significant differences between groups in polyp size and pregnancy conception rates (p=0.32).[46]

Stamatellos et al[47] in a retrospective study evaluated the impact of the size and number of uterine polyps on fertility in women with primary or secondary infertility for more than one year. The participants were divided into 2 groups, those with a polyp ≤1 cm and those with a polyp >1 cm or multiple polyps. The pregnancy rate was 61.4% for the entire study population undergoing hysteroscopic polypectomy, irrespective of whether the patient had primary or secondary infertility. The findings of that study correlated with those of Pérez-Medina et al[46], with polyp size and number of polyps having no significant association with pregnancy rate.

Another retrospective study conducted by Yahaihara et al[48] on 230 women to determine the significance of the location of endometrial polyps. The locations were defined as anterior wall, posterior wall, lateral wall, utero-tubal junction, and multiple polyps. Similar to previously reported findings, polyp size in any area of the uterus did not significantly impact pregnancy rate; however, the highest pregnancy rate, 50-60%, was achieved in those who had polyps removed from the utero-tubal junction. Similar results were obtained by Ghaffari et al[49] who reported no significant difference in pregnancy rates by polyp location.

Asherman's Syndrome and ART

Intrauterine adhesions are not life threatening, and may be asymptomatic in many patients. The main symptoms of Asherman's syndrome include pain, infertility, and abnormal menstrual patterns especially amenorrhea and scanty menstruation.[50]

Hysteroscopy has been the method of choice in the investigation and treatment of the condition. Management of moderate to severe disease may be a challenge, and repeated surgery may be necessary in some cases and may not always produce the desired outcome.[51,52]

A prospective study evaluated 24 women with infertility (12 of whom had previously delivered) and 12 women with a history of recurrent abortions. Of these 24 women, 48% conceived after hysteroscopic adhesiolysis. Among the 12 women with recurrent abortions, pregnancy wastage was reduced from 86.5-42.8% post-operatively.[53]

Another study, conducted by Tsui et al[54] conducted a study on 4 cases of severe asherman's syndrome where hysterescopic adhesiolysis was done for all cases. They found that all

ISSN 2377-1542 http://dx.doi.org/10.17140/GOROJ-4-140

the women (100%, 4/4) conceived successfully (three undergoing IVF & ET, and one had a spontaneous pregnancy). They concluded that hysteroscopic adhesiolysis has promising reproductive outcomes for infertile women with severe Asherman syndrome.

A more recent study enrolled 357 patients with mild, moderate, and severe Asherman's syndrome who underwent hysteroscopic adhesiolysis between January 2012 and December 2015. They found that the reproductive outcomes of 332 women (93%) were followed for an average duration of 27±9 months, and the overall conception rate after hysteroscopic adhesiolysis was 48.2%, which decreased with increased intrauterine adhesions (IUA) severity (mild, 60.7%; moderate, 53.4%; severe, 25%). The mean time to conception following hysteroscopic adhesiolysis was 9.7±3.7 months. The miscarriage rate was 9.4%, and the live birth rate was no lower than 85.6%. Eleven patients (7.9%) had postpartum hemorrhage, including 6 (4.3%) due to adherent placenta and 3 (2.1%) due to placenta accreta.[55]

ENDOSCOPIC OVARIAN SURGERY AND ART

Benign Ovarian Cysts and Endometriomas

The debate here remain unsolved as many gynecologic surgeons believe in the role of laparoscopic cystectomy for treatment of benign ovarian cysts, other reproductive medicine specialists antagonize this treatment option as it may influence women's fertility. There are no randomized trials comparing laparoscopic excision to expectant management before IVF–ICSI cycles. The idea that surgery increases IVF pregnancy rates is not supported by the available evidence.[56]

A review study was conducted by Legendre et al[57] to explore the potential relationship between ovarian cysts, their treatment, and infertility. They concluded that surgery does not seem to improve pregnancy rates. The best surgical approach is the laparoscopic approach. The surgical options studied were excision, sclerotherapy and plasma vaporization which were found to be promising, offering a greater preservation of the ovarian parenchyma, especially in endometriomas.

Kostrzewa et al[58] conducted a study to compare women's fertility after laparoscopic cystectomy of endometrioma *versus* other benign ovarian tumors. They found that there is a low pregnancy rate after laparoscopic cystectomy of benign ovarian tumors. Moreover, pregnancy rate after cystectomy of endometrioma is significantly lower and the percentage of reccurence of endometrioma is significantly higher. They concluded that the decision about surgical treatment among childbearing women must be well-considered because of the risk of subsequent surgery in the future.

Shervin et al[59] conducted a similar study to evaluate the result of laparoscopic endometrioma excision in fertility outcome of advanced endometriosis patients. They found that cumulative pregnancy rates (CPR) did not show any statistical significance between cases (35.6%) and controls (39.5%) (p value=0.959). The regression analysis of covariates showed there is no significant relationship between cystectomy and fertility outcome. They concluded that fine excision and stripping of the endometrioma along with radical resection of deep lesions improves fertility without any significant adverse effect in comparison with patients with intact ovaries.

Studies recruiting women with unilateral endometrioma and comparing ovarian responsiveness in the affected and contralateral intact ovary indicate that excision of endometriomas is associated with a quantitative damage to ovarian reserve. Other issues linked to laparoscopic surgery for endometriomas include costs and hazard of surgical complications. All above mentioned risks support expectant management. On the other hand, oocyte retrieval associated risks, the possibility of missing occult malignancy and endometriosis progression due to ovarian stimulation remain unsolved obstacles in front of conservative management advisors. The alternative options for endometriomas away from surgery and conservation include medical treatment and ultrasound-guided aspiration. Whereas prolonged gonadotropin-releasing hormone (GnRH) agonist down-regulation may be beneficial, data on ultrasound aspiration are more controversial.[60-63]

In fact, this surgery can actually reduce IVF pregnancy rates, because every time endometriotic tissue is removed from ovaries, normal ovarian tissues are also sacrificed at the same time. This reduces ovarian reserve, and can end up in growing few oocytes and getting only a few embryos to transfer.[64,65]

Ovarian Drilling Prior ART

Recently, laparoscopic ovarian drilling (LOD) has been used widely by gynecologists as an alternative surgical method for ovulation induction using gonadotropins for polycystic ovary syndrome (PCOS) patients unresponsive to clomiphene, but there is a lack of consensus on effectiveness of this method.[66,67]

Dale et al[68] conducted a study on the effectiveness of LOD on insulin resistance and pregnancy rate in patients with PCO. They followed patient for 12-18 months where they found that following ovarian drilling the non-insulin-resistant women more frequently achieved a regular menstrual cycle and ovulation than the insulin-resistant PCOS women. Consequently 18 (50%) of the non-insulin-resistant PCOS women achieved a pregnancy *versus* only five (18%) of women in the insulin-resistant PCOS group. Following treatment with both ovarian drilling and IVF, 27 cases (75%) of the non-insulin resistant PCOS women achieved a successful pregnancy, while 13 (46%) of the insulin-resistant PCOS group achieved pregnancy. They concluded that further studies are needed to evaluate the effectivness of LOD in PCO patients resistant to ovulation induction.

ISSN 2377-1542 http://dx.doi.org/10.17140/GOROJ-4-140

Eftekhar et al[69] conducted a retrospective study to evaluate the IVF/ICSI outcomes in clomiphene-resistant women with PCOS who were treated with LOD. They found that ovarian cauterization before IVF/ICSI in patients with PCOS reduced the risk of OHSS (p=0.025). Despite the same pregnancy rate in both groups (p=0.604), more obtained oocytes and embryos were seen on women without ovarian drilling than women with LOD (p<0.001 and p=0.033, respectively).

Another retrospective study was conducted by Cai et al[70] to determine if history of undergoing LOD affects cumulative ongoing pregnancy rates following IVF in patients with PCOS. The study included 110 patients in the LOD group, 127 patients in the no-LOD group, and 990 patients in the age-matched group. A lower number of retrieved oocytes, fewer available embryos, and a lower number of cryopreserved embryos were observed in among patients in the LOD-group compared with the other groups (p≤0.001). They concluded that LOD could compromise cumulative ongoing pregnancy rates during subsequent IVF.

Bosteels et al[26] conducted a review study on the role of reproductive surgery prior to ART. They found that LOD results at least in equal pregnancy rates as gonadotropin treatment (RR 1.0, 95% CI 0.83-1.2) but decreases the multiple pregnancy rate (RR 0.16, 95% CI 0.04-0.58).

Laparoscopic Ovarian Transposition Prior ART

Women who have received systemic therapy for malignancy should be considered to be low-responders and counseled that their per-cycle live birth rate is lower than that of their peers. These data strongly support offering fertility preservation before cancer therapy when possible. A final option for fertility preservation is unique to women undergoing radiation to the pelvis. Ovarian transposition is a surgical technique where the ovaries are moved to distance them from the radiation field. Correct ovarian placement can reduce radiation exposure to the ovaries down to 5-10% of non-transposed ovaries.[71,72]

Laparoscopic ovarian transposition to the lateral abdominal wall is a procedure that involves ligation of the utero-ovarian ligament and fallopian tube, mobilization of the vascular pedicle, and fixation of the ovary lateral to the psoas muscle. As tubal transection prohibits natural conception from the transposed ovary, facilitating oocyte retrieval from the transposed ovary by abdominal oocyte retrieval. In all ovarian transposition cases, marking the boundaries of the ovary with surgical clips will help to identify the ovaries during radiotherapy mapping.[73,74]

An alternative site for ovarian transposition is medial with ligation to the uterosacral ligament. This location is ideal in the case of abdominal external radiation as the uterus can shield and protect the transposed ovary. Ovarian transpositionmay be done in round ligament if abdominal external radiation is designed.[75,76]

Ovarian Tissue Transplantation

Ovarian cryopreservation is one of fertility preservation methods in women who wish to conceive, the current and proven method is to graft the frozen-thawed ovarian tissue into the ovarian fossa or into the remaining and irradiated ovary. Harvesting ovarian tissue could be done laparoscopically.[77]

The implanted ovarian tissue becomes functional 3-4 months after transplantation and may last up to 3 years, depending on the amount of ovarian tissue transplanted. Accordingly, ovarian transplantation should be carried out only when the patient is ready to conceive.[78,79]

Endoscopic Peritoneal Surgery (Laparoscopic Adhesiolysis)

Laparoscopic adhesiolysis is necessary to improve the outcome of the IVF cycle as ovaries may be adherent due to adhesions resulting from conditions such as endometrioisis, pelvic infections and previous surgeries. In these situations, a laparoscopic adhesiolysis can help in the breakdown of these adhesions and free the ovaries.[80]

Laparoscopy and IVF/ICSI are Complementary Since a Long Time

The first IVF child ensued following laparoscopic ovum retreival. In modern practice, laparoscopic egg retrieval is still required whenever inaccessible ovaries are encountered.[81]

Laparoscopic GIFT: A blastocyst intra-fallopian transfer was associated with an intrauterine pregnancy; however, when the indication for blastocyst tubal transfer of an obstructed cervix is associated with a foreshortened cervix requiring cervical cerclage, there can be major health risks for infant and mother.[82]

CONCLUSION

Endoscopic reproductive surgeries should replace open surgeries and should be the first choice in women with lesions in the tubes, uterus, ovary or peritoneum affecting fertility. With expert hands, endoscopic reproductive surgeries remain superior to ART being less costly and with minimal complications.

CONFLICTS OF INTEREST

The authors declare that they have no conflicts of interest.

REFERENCES

1. Tulandi T, Akkour K. Role of reproductive surgery in the era of assisted reproductive technology. *Best Pract Res Clin Obstet Gynaecol*. 2012; 26(6): 747-755. doi: 10.1016/j.bpobgyn.2012.04.003

2. Cholkeri-Singh A, Sasaki KJ. Hysteroscopy for infertile

ISSN 2377-1542
http://dx.doi.org/10.17140/GOROJ-4-140

women: A review. *J Minim Invasive Gynecol*. 2015; 22(3): 353-362. doi: 10.1016/j.jmig.2014.12.163

3. Dechanet C, Rihaoui S, Reyftmann L, Hedon B, Hamamah S, Dechaud H. Endometriosis and fertility: Results after surgery and assisted reproductive technology. *Gynecol Obstet Fertil*. 2011; 39(1): 3-7. doi: 10.1016/j.gyobfe.2010.08.018

4. Daniilidis A, Balaouras D, Chitzios D, Theodoridis T, Assimakopoulos E. Hydrosalpinx: Tubal surgery or in vitro fertilisation? An everlasting dilemma nowadays; a narrative review. *J Obstet Gynaecol*. 2017; 37(5): 550-556. doi: 10.1080/01443615.2017.1287685

5. Johnson N, van Voorst S, Sowter MC, Strandell A, Mol BW. Surgical treatment for tubal disease in women due to undergo in vitro fertilisation. *Cochrane Database Syst Rev*. 2010; 1: CD002125. doi: 10.1002/14651858.CD002125

6. Noventa M, Gizzo S, Saccardi C, et al. Salpingectomy before assisted reproductive technologies: A systematic literature review. *J Ovarian Res*. 2016, 3; 9(1): 74. doi: 10.1186/s13048-016-0284-1

7. Gomel V. The place of reconstructive tubal surgery in the era of assisted reproductive techniques. *Reprod Biomed Online*. 2015; 31(6): 722-731. doi: 10. 1016/ j.rbmo .2015.09.010

8. Honoré G, Holden A, Schenken R. Pathophysiology and management of proximal tubal blockage. *Fertil Steril.* 1999; 71: 785-795. doi: 10.1016/S0015-0282(99)00014-X

9. Allahbadia G, Merchant R. Fallopian tube recanalization: Lessons learnt and future challenges. *Womens Health*. 2010; 6: 531-548. doi: 10.2217/whe.10.34

10. Schepens JJ, Mol BW, Wiegerinck MA, Houterman S, Koks CA. Pregnancy outcomes and prognostic factors from tubal sterilization reversal by sutureless laparoscopical re-anastomosis: A retrospective cohort study. *Hum Reprod*. 2011; 26: 354-359. doi: 10.1093/humrep/deq326

11. Hirshfeld-Cytron J, Winter J. Laparoscopic tubal reanastomosis versus in vitro fertilization: Cost-based decision analysis. *Am J Obstet Gynecol*. 2013; 209(1): 56.e1-56.e6. doi: 10.1016/j.ajog.2013.04.018

12. van Seeters JA, Chua SJ, Mol BW, Koks CA. Tubal anastomosis after previous sterilization: A systematic review. *Hum Reprod Update*. 2017: 1-13. doi: 10.1093/humupd/dmx003

13. Boeckxstaens A, Devroey P, Collins J, Tournaye H. Getting pregnant after tubal sterilization: Surgical reversal or IVF? *Hum Reprod*. 2007; 22(10): 2660-2664.

14. Bosteels J, Kasius J, Weyers S, Broekmans FJ, Mol BW, D'Hooghe TM. Hysteroscopy for treating subfertility associated with suspected major uterine cavity abnormalities. *Cochrane Database Syst Rev*. 2015; (2): CD009461. doi: 10.1002/14651858.CD009461

15. Oliveira FG, Abdelmassih VG, Diamond MP, Dozortsev D, Nagy ZP, Abdelmassih R. Uterine cavity findings and hysteroscopic interventions in patients undergoing in vitro fertilization–embryo transfer who repeatedly cannot conceive. *Fertil Steril*. 2003; 80(6): 1371-1375. doi: 10.1016/j.fertnstert.2003.05.003

16. Hinckley MD, Milki AA. 1000 office-based hysteroscopies prior to in vitro fertilization: Feasibility and findings. *JSLS*. 2004; 8(2): 103-107.

17. Doldi N, Persico P, Di SF, et al. Pathologic findings in hysteroscopy before in vitro fertilization-embryo transfer (IVF-ET). *Gynecol Endocrinol*. 2005; 21: 235-237. doi: 10.1080/09513590500366696

18. Rama Raju GA, Shashi KG, Krishna KM, Prakash GJ, Madan K. Assessment of uterine cavity by hysteroscopy in assisted reproduction programme and its influence on pregnancy outcome. *Arch Gynecol Obstet*. 2006; 274: 160-164. doi: 10.1007/s00404-006-0174-7

19. Lorusso F, Ceci O, Bettocchi S, et al. Office hysteroscopy in an in vitro fertilization program. *Gynecol Endocrinol*. 2008; 24: 465-469. doi: 10.1080/09513590802246232

20. Bozdag G, Aksan G, Esinler I, Yarali H. What is the role of office hysteroscopy in women with failed IVF cycles? *Reprod Biomed Online*. 2008; 17: 410-415. doi: 10.1016/S1472-6483(10)60226-X

21. Cholkeri-Singh A, Sasaki KJ. Hysteroscopy for infertile women: A review. *J Minim Invasive Gynecol*. 2015; 22(3): 353-362. doi: 10.1016/j.jmig.2014.12.163

22. Negm SM, Kamel RA, Abuhamila FA. Three-dimensional sonohysterography compared with vaginoscopic hysteroscopy for evaluation of the uterine cavity in patients with recurrent implantation failure in in vitro fertilization cycles. *J Minim Invasive Gynecol*. 2012; 19: 503-508. doi: 10.1016/j.jmig.2012.03.021

23 Pellicer A, Galliano D. Hysteroscopy before IVF: Can it improve outcomes? *Lancet*. 2016; 387(10038): 2578-2579. doi: 10.1016/S0140-6736(16)00549-3

24. El-Toukhy T, Campo R, Khalaf Y, et al. Hysteroscopy in recurrent in-vitro fertilisation failure (TROPHY): A multicentre, randomised controlled trial. *Lancet*. 2016; 387(10038): 2614-2621. doi: 10.1016/S0140-6736(16)00258-0

25. Smit JG, Kasius JC, Eijkemans MJC, et al. Hysteroscopy before in-vitro fertilisation (inSIGHT): A multicentre, randomised

ISSN 2377-1542
http://dx.doi.org/10.17140/GOROJ-4-140

controlled trial. *Lancet*. 2016; 387(10038): 2622-2629. doi: 10.1016/S0140-6736(16)00231-2

26. Bosteels J, Weyers S, Mathieu C, Mol BW, D'Hooghe T. The effectiveness of reproductive surgery in the treatment of female infertility: Facts, views and vision. *Facts Views Vis Obgyn*. 2010; 2(4): 232-252.

27. Somigliana E, Vercellini P, Daguati R, Pasin R, De Giorgi O, Crosignani PG. Fibroids and female reproduction: A critical analysis of the evidence. *Hum Reprod Update*. 2007; 13(5): 465-476. doi: 10.1093/humupd/dmm013

28. Zepiridis LI, Grimbizis GF, Tarlatzis BC. Infertility and uterine fibroids. *Best Pract Res Clin Obstet Gynaecol*. 2016; 34: 66-73. doi: 10.1016/j.bpobgyn.2015.12.001

29. Casini ML, Rossi F, Agostini R, et al. Effects of the position of fibroids on fertility. *Gynecol Endocrinol*. 2006; 22: 106-109. doi: 10.1080/09513590600604673

30. Pritts EA., Parker WH, Olive DL. Fibroids and infertility: An updated systematic review of the evidence. *Fertil Steril*. 2009; 9: 1215-1223. doi: 10.1016/j.fertnstert.2008.01.051

31. Bosteels J, Kasius J, Weyers S, Broekmans FJ, Mol BWJ, D'Hooghe TM. Hysteroscopy for treating subfertility associated with suspected major uterine cavity abnormalities. *Cochrane Database Syst Rev*. 2013; (1): CD009461. doi: 10.1002/14651858.CD009461.pub2

32. Shokeir T, El-Shafei M, Yousef H, et al. Submucous myomas and their implications in the pregnancy rate of patients with otherwise unexplained primary infertility undergoing hysteroscopic myomectomy: A randomized matched control study. *Fertil Steril*. 2010; 94: 724-729. doi: 10.1016/j.fertnstert.2009.03.075

33. Pundir J, El Toukhy T. Uterine cavity assessment prior to IVF. *Womens Health (Lond)*. 2010; 6(6): 841-847; quiz 847-8.

34. Cela V, Litta P, Franchini M, et al. Fertility-enhancing hysteroscopic surgery. *Minerva Ginecol.* 2016; 68(2): 167-174.

35. Fatemi H, Kasius J, Timmermans A, et al. Prevalence of unsuspected uterine cavity abnormalities diagnosed by office hysteroscopy prior to in vitro fertilization. *Hum Reprod*. 2010; 25: 1959-1965. doi: 10.1093/humrep/deq150

36. Cholkeri-Singh A, Sasaki KJ. Hysteroscopy for infertile women: A review. *J Minim Invasive Gynecol*. 2015; 22(3): 353-362. doi: 10.1016/j.jmig.2014.12.163

37. Gubbini G, Sardo ADS, Nascetti D, et al. New outpatient subclassification system for American Fertility Society classes V and VI uterine anomalies. *J Minim Invasive Gynecol*. 2009; 16: 554-561. doi: 10.1016/j.jmig.2009.06.002

38. Mollo A, De Franciscis P, Colacuci N, et al. Hysteroscopic resection of the septum improves the pregnancy rate of women with unexplained infertility: A prospective controlled trial. *Fertil Steril*. 2009; 91: 2628-2631. doi: 10.1016/j.fertnstert.2008.04.011

39. Pabuçcu R, Gomel V. Reproductive outcome after hysteroscopic metroplasty in women with septate uterus and otherwise unexplained infertility. *Fertil Steril*. 2004; 81: 1675-1678. doi: 10.1016/j.fertnstert.2003.10.035

40. Goldenberg M, Sivan E, Sharabi Z, et al. Reproductive outcome following hysteroscopic management of intrauterine septum and adhesions. *Hum Reprod*. 1995; 10: 2663-2665. doi: 10.1093/oxfordjournals.humrep.a135763

41. Shokeir T, Abdelshaheed M, El-Shafie M, et al. Determinants of fertility and reproductive success after hysteroscopicseptoplasty for women with unexplained primary infertility: Aprospective analysis of 88 cases. *Eur J Obstet Gynecol Reprod Biol*. 2011; 155: 54-57. doi: 10.1016/j.ejogrb.2010.11.015

42. Grimbizis GF, Camus M, Tarlatzis BC, Bontis JN, Devroey P. Clinical implications of uterine malformations and hysteroscopic treatment results. *Hum Reprod Update*. 2001; 7: 161-174

43. Nouri K, Ott J, Huber JC, et al. Reproductive outcome after hysteroscopic septoplasty in patients with septate uterus: A retrospective cohort study and systematic review of the literature. *Reprod Biol Endocrinol*. 2010; 8: 52. doi: 10.1186/1477-7827-8-52

44. Abuzeid M, Ghourab G, Abuzeid O, Mitwally M, Ashraf M, Diamond M. Reproductive outcome after IVF following hysteroscopic division of incomplete uterine septum/arcuate uterine anomaly in women with primary infertility. *Facts Views Vis Obgyn*. 2014; 6(4): 194.

45. Mouhayar Y, Yin O, Mumford SL, Segars JH. Hysteroscopicpolypectomy prior to infertility treatment: A cost analysis and systematic review. *Eur J Obstet Gynecol Reprod Biol*. 2017; 213: 107-115. doi: 10.1016/j.ejogrb.2017.04.025

46. Pérez-Medina T, Bajo-Arenas J, Salazar F, et al. Endometrial polyps and their implication in the pregnancy rates of patients undergoing intrauterine insemination: A prospective, randomized study. *Hum Reprod*. 2005; 20: 163-165. doi: 10.1093/humrep/deh822

47. Stamatellos I, Apostolides A, Stamatopoulos P, et al. Pregnancy rates after hysteroscopicpolypectomy depending on the size or number of the polyps. *Arch Gynecol Obstet*. 2008; 277: 395-399. doi: 10.1007/s00404-007-0460-z

48. Yahaihara A, Yorimitsu T, Motoyama H, Iwasaki S, Kawamura T. Location of endometrial polyp and pregnancy rate in infer-

tility patients. *Fertil Steril*. 2008; 90: 180-182. doi: 10.1016/j.fertnstert.2007.05.072

49. Ghaffari F, Arabipoor A, Bagheri Lankarani N, Hosseini F, Bahmanabadi A. Hysteroscopic polypectomy without cycle cancellation in IVF/ICSI cycles: A cross-sectional study. *Eur J Obstet Gynecol Reprod Biol*. 2016; 205: 37-42. doi: 10.1016/j.ejogrb.2016.08.019

50. Hanstede MM, van der Meij E, Goedemans L, Emanuel MH. Results of centralized Asherman surgery, 2003-2013. *Fertil Steril*. 2015; 104: 1561-1568. doi: 10.1016/j.fertnstert.2015.08.039

51. Zupi E, Centini G, Lazzeri L. Asherman syndrome: An unsolved clinical definition and management. *Fertil Steril*. 2015; 104(6): 1380-1381. doi: 10.1016/j.fertnstert.2015.09.036

52. Pabuccu R, Onalan G, Kaya C, et al. Efficiency and pregnancy outcome of serial intrauterine device-guided hysteroscopicadhesiolysis of intrauterine synechiae. *Fertil Steril*. 2008; 90: 1973-1977. doi: 10.1016/j.fertnstert.2007.06.074

53. Fernandez H, Al-Najjar F, Chauveaud-Lambling A, et al. Fertility after treatment of Asherman's syndrome stage 3 and 4. *J Minim Invasive Gynecol*. 2006; 13: 398-402. doi: 10.1016/j.jmig.2006.04.013

54. Tsui KH, Lin LT, Cheng JT, Teng SW, Wang PH. Comprehensive treatment for infertile women with severe Asherman syndrome. *Taiwan J Obstet Gynecol*. 2014; 53(3): 372-375. doi: 10.1016/j.tjog.2014.04.022

55. Chen L, Zhang H, Wang Q, et al. Reproductive Outcomes in Patients With Intrauterine Adhesions Following Hysteroscopic-Adhesiolysis: Experience From the Largest Women's Hospital in China. *J Minim Invasive Gynecol*. 2017; 24(2): 299-304. doi: 10.1016/j.jmig.2016.10.018

56. Somigliana E, Benaglia L, Paffoni A, Busnelli A, Vigano P, Vercellini P. Risks of conservative management in women with ovarian endometriomas undergoing IVF. *Hum Reprod Update*. 2015; 21(4): 486-499. doi: 10.1093/humupd/dmv012

57. Legendre G, Catala L, Morinière C, et al. Relationship between ovarian cysts and infertility: What surgery and when? *Fertil Steril*. 2014; 101(3): 608-614. doi: 10.1016/j.fertnstert.2014.01.021

58. Kostrzewa M, Stachowiak G, Zyła M, et al. Women's fertility after laparoscopic cystectomy of endometrioma and other benign ovarian tumors - a 24-month follow-up retrospective study. *Neuro Endocrinol Lett*. 2016; 37(4): 295-300.

59. Shervin A, Mohazzab A, Aminlou M, et al. Fertility outcome after laparoscopic treatment of advanced endometriosis in two groups of infertile patients with and without ovarian endometrioma. *Eur J Obstet Gynecol Reprod Biol*. 2016; 201: 46-50. doi: 10.1016/j.ejogrb.2016.03.009

60. Somigliana E, Vercellini P, Viganó P, Ragni G, Crosignani PG. Should endometriomas be treated before IVF–ICSI cycles? *Hum Reprod Update*. 2006; 12(1): 57-64. doi: 10.1093/humupd/dmi035

61. Muzii L, Di Tucci C, Di Feliciantonio M, Marchetti C, Perniola G, Panici PB. The effect of surgery for endometrioma on ovarian reserve evaluated by antral follicle count: A systematic review and meta-analysis. *Hum Reprod*. 2014; 29(10): 2190-2198. doi: 10.1093/humrep/deu199

62. Roustan A, Perrin J, Debals-Gonthier M, Paulmyer-Lacroix O, Agostini A, Courbiere B. Surgical diminished ovarian reserve after endometrioma cystectomy versus idiopathic DOR: Comparison of in vitro fertilization outcome. *Hum Reprod*. 2015; 30(4): 840-847. doi: 10.1093/humrep/dev029

63. Zhang XR, Ding LL, Tang R, Sheng Y, Qin YY, Chen ZJ. Effects of cystectomy for ovary benign cyst on ovarian reserve and pregnancy outcome of in vitro fertilization-embryo transfer cycle [In Chinese]. *Zhonghua Fu Chan Ke Za Zhi*. 2016; 51(3): 180-185. doi: 10.3760/cma.j.issn.0529-567X.2016.03.004

64. Young K, Fisher J, Kirkman M. Endometriosis and fertility: Women's accounts of healthcare. *Hum Reprod*. 2016; 31(3): 554-562. doi: 10.1093/humrep/dev337

65. Hamdan M, Dunselman G, Li TC, Cheong Y. The impact of endometrioma on IVF/ICSI outcomes: A systematic review and meta-analysis. *Hum Reprod Update*. 2015; 21(6): 809-825. doi: 10.1093/humupd/dmv035

66. Amer SA, Li TC, Cooke ID. Laparoscopic ovarian diathermy in women with polycystic ovarian syndrome: A retrospective study on the influence of the amount of energy used on the outcome. *Hum Reprod*. 2002; 17(4): 1046-1051. doi: 10.1093/humrep/17.4.1046

67. Escrivá AM, García CD, Gómez-Marco BV, Sarrió AR. IVF outcomes after ovarian drilling in women with polycystic ovary syndrome. *Revista Iberoamericana de Fertilidad y Reproduccion Humana*. 2010; 27(3): 187-193.

68. Dale PO, Tanbo T, Ertzeid G, et al. The impact of insulin resistance on the outcome of laparoscopic ovarian electrocautery in infertile women with the polycystic ovary syndrome. *Gynecol Endocrinol*. 2004; 19 (4); 182-189. doi: 10.1080/09513590400012093

69. Eftekhar M, Firoozabadi RD, Khani P, Bideh EZ, Forghani H. Effect of laparoscopic ovarian drilling on outcomes of in vitro fertilization in clomiphene-resistant women with polycystic ovary syndrome. *Int J Fertil Steril*. 2016; 10(1): 42-47. doi:

ISSN 2377-1542
http://dx.doi.org/10.17140/GOROJ-4-140

10.22074/ijfs.2016.4767

70. Cai J, Liu L, Sun L, Sha A, Jiang X, Ren J. Effects of previous ovarian drilling on cumulative ongoing pregnancy rates among patients with polycystic ovarian syndrome undergoing in vitro fertilization. *Int J Gynaecol Obstet*. 2016; 134(3): 272-277. doi: 10.1016/j.ijgo.2016.03.008

71. Barton SE, Missmer SA, Berry KF, Ginsburg ES. Female cancer survivors are low responders and have reduced success compared with other patients undergoing assisted reproductive technologies. *Fertil Steril*. 2012; 97(2): 381-386. doi: 10.1016/j.fertnstert.2011.11.028

72. Noyes N, Knopman JM, Long K, Coletta JM, Abu-Rustum NR. Fertility considerations in the management of gynecologic malignancies. *Gynecol Oncol*. 2011; 120(3): 326-333. doi: 10.1016/j.ygyno.2010.09.012

73. McLaren JF, Bates GW. Fertility preservation in women of reproductive age with cancer. *Am J Obstet Gynecol*. 2012; 207(6): 455-462. doi: 10.1016/j.ajog.2012.08.013

74. Morice P, Castaigne D, Haie-Meder C, et al. Laparoscopic ovarian transposition for pelvic malignancies: Indications and functional outcomes. *Fertil Steril*. 1998; 70: 956-960. doi: 10.1016/S0015-0282(98)00284-2

75. Bisharah M, Tulandi T. Laparoscopic preservation of ovarian function: An underused procedure. *Am J Obstet Gynecol*. 2003; 188: 367-370. doi: 10.1067/mob.2003.38

76. Visvanathan DK, Cutner AS, Cassoni AM, et al. A new technique of laparoscopic ovariopexy before irradiation. *Fertil Steril*. 2003; 79: 1204-1206. doi: 10.1016/S0015-0282(03)00157-2

77. Mayerhofer K, Ott J, Nouri K, et al. Laparoscopic ovarian tissue harvesting for cryopreservation: An effective and safe procedure for fertility preservation. *Eur J Obstet Gynecol Reprod Biol.* 2010; 152: 68-72. doi: 10.1016/j.ejogrb.2010.05.034

78. Huang JYJ, Tulandi T, Holzer H, et al. Combining ovarian tissue cryobanking with retrieval of immature oocytes followed by in vitro maturation and vitrification: An additional strategy of fertility preservation. *Fertil Steril*. 2008; 89: 567-572. doi: 10.1016/j.fertnstert.2007.03.090

79. Bedaiwy MA, El-Nashar SA, El Saman AM, et al. Reproductive outcome after transplantation of ovarian tissue: A systematic review. *Hum Reprod*. 2008; 23: 2709-2717. doi: 10.1093/humrep/den301

80. Daniell JF, Pittaway DE, Maxson WS. The role of laparoscopic adhesiolysis in an in vitro fertilization program. *Fertil-Steril*. 1983; 40(1): 49-52.

81. Hirata T, Fujimoto A, Koga K, Wada-Hiraike O, Fujii T, Osuga Y. Concomitant ovarian drilling and oocyte retrieval by laparoendoscopic single-site surgery led to live birth using in vitro maturation of oocyte and transfer of frozen-thawed blastocyst in woman with polycystic ovary syndrome. *J Obstet Gynaecol Res*. 2014; 40(5): 1431-1435. doi: 10.1111/jog.12365

82. Darwish A. *Endoscopy Versus IVF: The Way to Go*. Rijeka, Croati: INTECH Open Access Publisher; 2012.

GYNECOLOGY AND OBSTETRICS RESEARCH

Openventio PUBLISHERS

ISSN 2377-1542 Open Journal http://dx.doi.org/10.17140/GOROJ-4-141

Mini Review

***Corresponding author**
Hongjie Fan, PhD
Department of Obstetrics and Gynaecology, Li Ka Shing Faculty of Medicine, The University of Hong Kong Hong Kong SAR, China
Tel. +85239179378
Fax: +85228161947
E-mail: u30030120@connect.hku.hk

Volume 4 : Issue 2
Article Ref. #: 1000GOROJ4141

Article History
Received: November 22nd, 2017
Accepted: December 8th, 2017
Published: December 8th, 2017

Citation
Fan H, Lee K-F. Bisphenol compounds on human reproduction health. *Gynecol Obstet Res Open J.* 2017; 4(2): 30-35. doi: 10.17140/GOROJ-4-141

Bisphenol Compounds on Human Reproduction Health

Hongjie Fan, PhD[1*]; Kai-Fai Lee, PhD[1,2]

[1]*Department of Obstetrics and Gynaecology, Li Ka Shing Faculty of Medicine, The University of Hong Kong, Hong Kong SAR, China*

[2]*Shen Zhen Key Laboratory of Fertility Regulation, The University of Hong Kong-Shenzhen Hospital, Haiyuan 1st Road, Futian District, Shenzhen, 518053, China*

ABSTRACT

Bisphenol-A (BPA) is widely used in the plastic industry, and it is one of the well-studied endocrine disrupting chemicals (EDCs). Growing evidence raised the concern of BPA having weak estrogenic activity on human health including female reproductive functions and diseases. Serum BPA level is also associated with pregnancy loss, reproductive tract diseases and infertility. In fact, several countries restricted the use of BPA, and therefore substitutes which share similar chemical and physical properties with BPA were used. However, the effects of these bisphenols (e.g. bisphenol-F (BPF) and bisphenol-S (BPS)) on human reproductive health have not been fully investigated, and this mini-review summarized the recent data of these bisphenols on human reproductive health, and raise the concern on the safety and transgenerational effect of these bisphenols in humans.

KEY WORDS: Bisphenol-A; Bisphenol-F; Bisphenol-S; Pregnancy; Reproduction.

ABBREVIATIONS: BPA: Bisphenol-A; EDCs: Endocrine Disrupting Chemicals; PCOS: Poly-Cystic Ovary Syndrome; RSA: Recurrent Spontaneous Abortion; AFC: Antral Follicle Count; ERα: Estrogen receptor α; ERβ: Estrogen Receptor β.

INTRODUCTION

Endocrine disrupting chemicals (EDCs) are various chemicals mimicking hormones present in the body, and they bind and act through hormone receptors to modulate the functions of endocrine systems. In human, the target of EDCs in endocrine system include thyroid, pituitary, adrenal, mammary glands, ovaries, uterus in female, and prostate and testes in male.[1] EDCs with different hormone-like activities have diverse effect on endocrine systems,[2-4] which could be classified into persistent and non-persistent groups depending on their biodegradation and bioaccumulation properties (Table 1).

In various EDCs, bisphenol-A (BPA) is one of the well-studied chemical that might affect human health. Bisphenol compounds are a group of chemicals with two hydroxyphenyl groups, and most of which contains diphenylmethane structure. The naming of each bisphenol chemical is based on the reactant linking two hydroxyphenyls. For example, bisphenol-A has acetone as a bridge linking two phenols. As a result, bisphenol compounds share very simi-

Figure 1: Chemical Structures of Bisphenol Compounds.

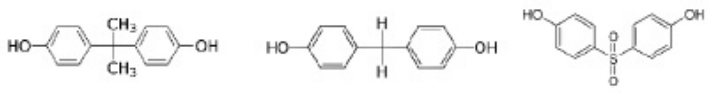

ISSN 2377-1542
http://dx.doi.org/10.17140/GOROJ-4-141

Table 1: Main EDCs and their Effects in Endocrine Systems.

EDCs	Major hormonal effect	Endocrine effect
Persistent organic pollutants		
Polychlorobiphenyls (PCBs)	Thyroid	Alter ovarian steroidogenesis, oocyte development, reduce semen quality, learning disability, thyroid cancer, hypertension, diabetes
dichlorodiphenyltrichloroethane (DDT)	Estrogen	Reduced fertility, spontaneous abortion, type 2 diabetes, breast cancer, reduced bone mineral density
Dioxins	Anti-androgen	Alter steroid hormone metabolism, reduce semen quality, auto-immune disease, diabetes, breast/liver/ lung cancer, cancer mortality
Non-persistent organic pollutants		
Bisphenol A (BPA)	Estrogen	Alter steroidogenesis, reduced female and male fertility, reduced birth weight, asthma, increased children anxiety/depression, type 2 diabetes, breast/prostate cancer, obesity, hypertension
Phthalates	Estrogen	Reduced sperm quality and female fertility, endometriosis, preterm birth, pubertal delay, autoimmune disease, children abnormal behaviors
Isoflavones	Estrogen	Alter steroid hormone metabolism, autoimmune disease, increase bone mineral density, reduce prostate/breast cancer, anti-diabetes effect

lar chemical structure, and the difference is the reactant in the middle (Figure 1).

Among these bisphenols, BPA is the most commonly used chemical nowadays. BPA is heat resistant and has good elasticity. It has been widely used as plastic monomer in the manufacture of polycarbonate plastics and epoxy resins since 1950. Over 6 billion pounds of BPA are produced every year for manufacturing of plastic products, such as plastic bags, paper bags, bottles, microwave box, dental sealants, coated tins, paintings. BPA was firstly found to have the estrogenic effect in 1936.[5] Humans are exposed to BPA through dietary intake, dermal contact, and inhalation.[6] Since 1999, BPA were detected in human blood, urine, serum and placental tissue.[7] In last two decades, serval lines of evidence suggest adverse effect of BPA on human health including obesity, diabetes, abnormal behavior, and female and male reproductive functions.[2,8,9]

BPA Levels During Pregnancy

BPA could be detected in the serum of non-pregnant women, and pregnant women at early and late gestational stage, as well as in the fetal cord serum and amniotic fluid (1-2 ng/mL). For amniotic fluid at 15-18 weeks gestation, there was a 5-fold increase in BPA level (8.3 ng/mL).[10] After delivery, the placental BPA level was higher (11.2 ng/g tissue) when compared to the maternal serum and umbilical cord blood collected from the same subjects,[11] suggesting that BPA could be accumulated at the maternal-fetal interface that might affect fetal development during the whole gestational period.

The association of BPA and pregnancy-associated diseases was reported in several studies. Serum BPA level was much higher in patients with polycystic ovary syndrome (PCOS) than normal female.[12] Higher BPA level in follicular fluid (440 pg/ml) was also observed in PCOS patients compared with non-PCOS patients (338 pg/mL).[13] Similarly, patients with history of unexplained recurrent spontaneous abortion (RSA) have a significantly higher serum BPA level than normal women.[14,15] In women undergoing *in vitro* fertilization (IVF), BPA could be detected in most of the cases, and the higher urinary BPA concentrations were found in patients with lower antral follicle count (AFC) and number of oocytes retrieved.[16,17] A positive association was also found between BPA urinary concentrations and implantation failure.[18] However, it was also reported that IVF outcomes and endometrial wall thickness were not associated with urinary BPA concentrations,[19] but the spontaneous preterm birth rate[20] and the risk of low birth weight[21] were associated with higher urine BPA levels. In patients with uterine leiomyoma, their urine and plasma BPA levels were not different from the control group,[22] and endometriosis was not associated with urinary BPA level in infertile Japanese population.[23]

Mechanism of BPA in Female Reproduction

As an estrogen-like EDC, the activity of BPA was found to be 100 to 10,000-fold lower than that of 17β-estradiol (E2).[24-26] Estrogen receptor α (ERα) and estrogen receptor β (ERβ), and a transmembrane ER called G protein-coupled receptor 30 (GPR30) are the main targets of BPA when it carries out its effect.[27,28] Most of mechanism studies of BPA was performed in *in vitro* and *in vivo* animal models. In human, endometrial adenocarcinoma cell line Ishikawa is response to BPA with many genes modulated.[29] Human primary endometrial cell proliferation was inhibited by BPA,[30,31] BPA also induced the expression of decidualization makers and several hormone related mol-

ISSN 2377-1542 http://dx.doi.org/10.17140/GOROJ-4-141

ecules in endometrial stromal cells.[32-34] BPA induces apoptosis, necrosis and the tumor necrosis factor-alpha (TNF-α) expressions in the human primary placental cells and the first trimester human chorionic villous explant.[35,36] Cell migration and invasion of trophoblast cell line HTR-8/SVneo and BeWo was reduced by BPA.[37,38] More detailed mechanism of BPA in animal study was reviewed elsewhere.[9,39,40]

Very few evidence support the detrimental effect of BPA on ovarian function. As mentioned previously, it was found that follicular fluid has a very low BPA level (1-2 ng/ml).[10] BPA at supra-physiological level altered the progesterone and estradiol synthesis in luteinized granulosa cells and reduced the expression of steroidogenesis enzymes, such as 3 beta-hydroxysteroid dehydrogenase (3 beta-HSD), CYP11A1 and CYP19A1 *in vitro*.[41] Human oocytes cultured in medium containing BPA (20 ng/mL to 20 μg/mL) exhibited abnormal meiotic maturation, changed spindle morphology and delayed chromosome alignment.[42] In sum, the synthesis of hormones and development of oocyte *in vitro* were significantly affected by BPA.

Other Bisphenols and Female Reproductive Functions

Due to the public concern about the risk of BPA in endocrine related diseases and infertility problems, the usage of BPA has been restricted in some products especially baby bottles in some countries, including Norway, Denmark, Germany, France and USA.[43] Several chemicals with similar structures with BPA were used as substitutes, such as bisphenol-F (BPF) and bisphenol-S (BPS), which lack thorough safety investigations.[44] Similar to BPA, these bisphenols could bind to the C-terminal ligand-binding domain of estrogen receptor and exhibit similar or weaker estrogenic activity as BPA.[45,46]

BPA, BPF and BPS are detected in our environment including water from rivers, sewage sludge and indoor air.[47-49] Receipts, paper products, and many canned food and soft drinks were found to have BPS and BPF.[50-57] In USA, BPF and BPS were detected in most of the human urine samples, albeit less frequent and lower concentrations than BPA in the same sample.[58,59] Low concentration of BPS was detected in some serum samples of pregnant women and the cord blood of the sibling,[60] suggesting BPS could also cross the placenta. Importantly, BPA, BPF and BPS could also be detected in breast milk.[61]

There is no published report regarding the association of BPF or BPS level and diseases related to pregnancy in humans. The potential effect of these bisphenols in reproduction was based on *in vitro* and *in vivo* animal studies. In porcine, BPS affected meiotic division of the oocytes and the expression and distribution of ERβ, ERα and aromatase.[62] BPS reduced egg production and the gonadosomatic index (gonad weight/body weight) in zebrafish.[63] BPS and BPF increased the uterine weight in rats,[64] but another study did not find the same effect.[65] In fact, the estrogenic and androgenic activities of BPF and BPS were found to have similar order of magnitude and mechanic action as BPA.[66,67] BPF and BPS also have genotoxicity and mutagenicity as BPA.[44] Although, the evidence of BPF and BPS on female reproduction is limited, the activity and mechanism of these two bisphenols is quite similar to BPA, leading to the adverse effect of bisphenols on female reproductive health could not be ignored.

CONCLUSION

It is widely recognized that BPA is harmful to human health and female reproduction. Whether BPA at current low environmental level poses chronic and transgenerational effect remains unknown.[68] Several countries have issued regulations to ban on the usage of BPA in specific products, such as baby bottles. Other bisphenols with similar structure to BPA are used to replace BPA in manufacturing process. Although compiling evidence of these bisphenols on female reproductive functions are lacking, concern about the safety of these bisphenols in public should be raised.

ACKNOWLEDGEMENT

Part of the work is supported by Sanming Project of Medicine in Shenzhen (SZSM201612083) and GRF Grant (17120415) to KFL.

CONFLICTS OF INTEREST

The authors declare that they have no conflicts of interest.

REFERENCES

1. Gore AC, Crews D, Doan LL, et al. *Introduction To Endocrine Disrupting Chemicals (EDCs). A Guide for Public Interest Organizations and Policy-Makers*. Washington, DC, USA: Endocrine Society; 2014: 7-13.

2. Rochester JR. Bisphenol A and human health: A review of the literature. *Reprod Toxicol*. 2013; 42: 132-1055. doi: 10.1016/j.reprotox.2013.08.008

3. Wuttke W, Jarry H, Seidlova-Wuttke D. Definition, classification and mechanism of action of endocrine disrupting chemicals. *Hormones (Athens)*. 2010; 9(1): 9-15.

4. Schug TT, Janesick A, Blumberg B, Heindel JJ. Endocrine disrupting chemicals and disease susceptibility. *J Steroid Biochem Mol Biol*. 2011; 127(3-5): 204-215. doi: 10.1016/j.jsbmb.2011.08.007

5. Dodds EC, Lawson W. Synthetic strogenic agents without the phenanthrene nucleus. *Nature*. 1936; 137(996). doi: 10.1038/137996a0

6. Vandenberg LN, Hauser R, Marcus M, Olea N, Welshons WV. Human exposure to bisphenol A (BPA). *Reprod Toxicol*. 2007;

ISSN 2377-1542 http://dx.doi.org/10.17140/GOROJ-4-141

24(2): 139-177. doi: 10.1016/j.reprotox.2007.07.010

7. Sajiki J, Takahashi K, Yonekubo J. Sensitive method for the determination of bisphenol-A in serum using two systems of high-performance liquid chromatography. *J Chromatogr B Biomed Sci Appl*. 1999; 736(1-2): 255-261. doi: 10.1016/S0378-4347(99)00471-5

8. Vom Saal FS, Nagel SC, Coe BL, Angle BM, Taylor JA. The estrogenic endocrine disrupting chemical bisphenol A (BPA) and obesity. *Mol Cell Endocrinol*. 2012; 354(1-2): 74-84. doi: 10.1016/j.mce.2012.01.001

9. Peretz J, Vrooman L, Ricke WA, et al. Bisphenol a and reproductive health: Update of experimental and human evidence, 2007-2013. *Environ Health Perspect*. 2014; 122(8): 775-786. doi: 10.1289/ehp.1307728

10. Ikezuki Y, Tsutsumi O, Takai Y, Kamei Y, Taketani Y. Determination of bisphenol A concentrations in human biological fluids reveals significant early prenatal exposure. *Hum Reprod*. 2002; 17(11): 2839-2841.

11. Schonfelder G, Wittfoht W, Hopp H, et al. Parent bisphenol A accumulation in the human maternal-fetal-placental unit. *Environ Health Perspec*t. 2002; 110(11): A703-A707.

12. Takeuchi T, Tsutsumi O, Ikezuki Y, Takai Y, Taketani Y. Positive relationship between androgen and the endocrine disruptor, bisphenol A, in normal women and women with ovarian dysfunction. *Endocr J*. 2004; 51(2): 165-169. doi: 10.1507/endocrj.51.165

13. Wang Y, Zhu Q, Dang X, et al. Local effect of bisphenol A on the estradiol synthesis of ovarian granulosa cells from PCOS. *Gynecol Endocrinol*. 2017; 33(1): 21-25. doi: 10.1080/09513590.2016.1184641

14. Zheng YM, Wang Y, Zhao J, et al. Association between serum bisphenol-A and recurrent spontaneous abortion: A 1:2 case-control study, China. *Zhonghua Liu Xing Bing Xue Za Zhi*. 2012; 33(8): 841-845.

15. Sugiura-Ogasawara M, Ozaki Y, Sonta S, Makino T, Suzumori K. Exposure to bisphenol A is associated with recurrent miscarriage. *Hum Reprod*. 2005; 20(8): 2325-2329. doi: 10.1093/humrep/deh888

16. Mok-Lin E, Ehrlich S, Williams PL, et al. Urinary bisphenol A concentrations and ovarian response among women undergoing IVF. *Int J Androl*. 2010; 33(2): 385-393. doi: 10.1111/j.1365-2605.2009.01014.x

17. Souter I, Smith KW, Dimitriadis I, et al. The association of bisphenol-A urinary concentrations with antral follicle counts and other measures of ovarian reserve in women undergoing infertility treatments. *Reprod Toxicol*. 2013; 42: 224-231. doi: 10.1016/j.reprotox.2013.09.008

18. Ehrlich S, Williams PL, Missmer SA, et al. Urinary bisphenol A concentrations and implantation failure among women undergoing in vitro fertilization. *Environ Health Perspect*. 2012; 120(7): 978-983. doi: 10.1289/ehp.1104307

19. Minguez-Alarcon L, Gaskins AJ, Chiu YH, et al. Urinary bisphenol A concentrations and association with in vitro fertilization outcomes among women from a fertility clinic. *Hum Reprod*. 2015; 30(9): 2120-2128. doi: 10.1093/humrep/dev183

20. Cantonwine DE, Ferguson KK, Mukherjee B, McElrath TF, Meeker JD. Urinary bisphenol A levels during pregnancy and risk of preterm birth. *Environ Health Perspect*. 2015; 123(9): 895-901. doi: 10.1289/ehp.1408126

21. Huo W, Xia W, Wan Y, et al. Maternal urinary bisphenol A levels and infant low birth weight: A nested case-control study of the Health Baby Cohort in China. *Environ Int.* 2015; 85: 96-103. doi: 10.1016/j.envint.2015.09.005

22. Shen Y, Xu Q, Ren M, et al. Measurement of phenolic environmental estrogens in women with uterine leiomyoma. *PLoS One*. 2013; 8(11): e79838. doi: 10.1371/journal.pone.0079838

23. Itoh H, Iwasaki M, Hanaoka T, et al. Urinary bisphenol-A concentration in infertile Japanese women and its association with endometriosis: A cross-sectional study. *Environ Health Prev Med*. 2007; 12(6): 258-264. doi: 10.1007/BF02898033

24. Kuiper GG, Lemmen JG, Carlsson B, et al. Interaction of estrogenic chemicals and phytoestrogens with estrogen receptor beta. *Endocrinology*. 1998; 139(10): 4252-4263. doi: 10.1210/endo.139.10.6216

25. Hiroi H, Tsutsumi O, Momoeda M, et al. Differential interactions of bisphenol A and 17beta-estradiol with estrogen receptor alpha (ERalpha) and ERbeta. *Endocr J*. 1999; 46(6): 773-778. doi: 10.1507/endocrj.46.773

26. Fang H, Tong W, Perkins R, et al. Quantitative comparisons of in vitro assays for estrogenic activities. *Environ Health Perspect*. 2000; 108(8): 723-729.

27. Eyster KM. The Estrogen receptors: An overview from different perspectives. *Methods Mol Biol*. 2016; 1366: 1-10. doi: 10.1007/978-1-4939-3127-9_1

28. Wetherill YB, Akingbemi BT, Kanno J, et al. In vitro molecular mechanisms of bisphenol A action. *Reprod Toxicol*. 2007; 24(2): 178-198. doi: 10.1016/j.reprotox.2007.05.010

29. Naciff JM, Khambatta ZS, Reichling TD, et al. The genomic response of Ishikawa cells to bisphenol A exposure is dose- and time-dependent. *Toxicology*. 2010; 270(2-3): 137-149. doi:

ISSN 2377-1542
http://dx.doi.org/10.17140/GOROJ-4-141

10.1016/j.tox.2010.02.008

30. Lee MS, Hyun SH, Lee CK, et al. Impact of xenoestrogens on the growth of human endometrial epithelial cells in a primary culture system. *Fertil Steril*. 2003; 79(6): 1464-1465. doi: 10.1016/S0015-0282(03)00360-1

31. Bredhult C, Sahlin L, Olovsson M. Gene expression analysis of human endometrial endothelial cells exposed to Bisphenol A. *Reprod Toxicol*. 2009; 28(1): 18-25. doi: 10.1016/j.reprotox.2009.03.006

32. Aghajanova L, Giudice LC. Effect of bisphenol A on human endometrial stromal fibroblasts in vitro. *Reprod Biomed Online*. 2011. 22(3): 249-256. doi: 10.1016/j.rbmo.2010.12.007

33. Forte M, Mita L, Cobellis L, et al. Triclosan and bisphenol a affect decidualization of human endometrial stromal cells. *Mol Cell Endocrinol*. 2015; 18(15): 30142-30148. doi: 10.1016/j.mce.2015.11.017

34. Mannelli C, Szostek AZ, Lukasik K, et al. Bisphenol A modulates receptivity and secretory function of human decidual cells: An in vitro study. *Reproduction*. 2015; 150(2): 115-125. doi: 10.1530/REP-14-0601

35. Benachour N, Aris A. Toxic effects of low doses of Bisphenol-A on human placental cells. *Toxicol Appl Pharmacol*. 2009; 241(3): 322-328. doi: 10.1016/j.taap.2009.09.005

36. Morck TJ, Sorda G, Bechi N, et al. Placental transport and in vitro effects of Bisphenol A. *Reprod Toxicol*. 2010; 30(1): 131-137. doi: 10.1016/j.reprotox.2010.02.007

37. Spagnoletti A, Paulesu L, Mannelli C, et al. Low concentrations of Bisphenol A and para-Nonylphenol affect extravillous pathway of human trophoblast cells. *Mol Cell Endocrinol*. 2015; 412: 56-64. doi: 10.1016/j.mce.2015.05.023

38. Wang ZY, Lu J, Zhang YZ, et al. Effect of Bisphenol A on invasion ability of human trophoblastic cell line BeWo. *Int J Clin Exp Pathol*. 2015; 8(11): 14355-14364.

39. Caserta D, Di Segni N, Mallozzi M, et al. Bisphenol A and the female reproductive tract: An overview of recent laboratory evidence and epidemiological studies. *Reprod Biol Endocrinol*. 2014; 12: 37. doi: 10.1186/1477-7827-12-37

40. Ziv-Gal A, Flaws JA. Evidence for bisphenol A-induced female infertility: Review (2007-2016). *Fertil Steril*. 2016; 106(4): 827-856. doi: 10.1016/j.fertnstert.2016.06.027

41. Mansur A, Adir M, Yerushalmi G, et al. Does BPA alter steroid hormone synthesis in human granulosa cells in vitro? *Hum Reprod*. 2016; 31(7): 1562-1569. doi: 10.1093/humrep/dew088

42. Machtinger R, Combelles CM, Missmer SA, et al. Bisphenol-A and human oocyte maturation in vitro. *Hum Reprod*. 2013 28(10): 2735-2745. doi: 10.1093/humrep/det312

43. Metz CM. Bisphenol A: Understanding the controversy. *Workplace Health Saf*. 2016; 64(1): 28-36; quiz 37. doi: 10.1177/2165079915623790

44. Usman A, Ahmad M. From BPA to its analogues: Is it a safe journey? *Chemosphere*. 2016; 158: 131-142. doi: 10.1016/j.chemosphere.2016.05.070

45. Chen D, Kannan K, Tan H, et al. Bisphenol analogues other than BPA: Environmental occurrence, human exposure, and toxicity-A review. *Environ Sci Technol*. 2016; 50(11): 5438-5453. doi: 10.1021/acs.est.5b05387

46. Delfosse V, Grimaldi M, Pons JL, et al. Structural and mechanistic insights into bisphenols action provide guidelines for risk assessment and discovery of bisphenol A substitutes. *Proc Natl Acad Sci U S A*. 2012; 109(37): 14930-14935. doi: 10.1073/pnas.1203574109

47. Yamazaki E, Yamashita N, Taniyasu S, et al. Bisphenol A and other bisphenol analogues including BPS and BPF in surface water samples from Japan, China, Korea and India. *Ecotoxicol Environ Saf*. 2015; 122: 565-572. doi: 10.1016/j.ecoenv.2015.09.029

48. Ruan T, Liang D, Song S, et al. Evaluation of the in vitro estrogenicity of emerging bisphenol analogs and their respective estrogenic contributions in municipal sewage sludge in China. *Chemosphere*. 2015; 124: 150-155. doi: 10.1016/j.chemosphere.2014.12.017

49. Xue J, Wan Y, Kannan K. Occurrence of bisphenols, bisphenol A diglycidyl ethers (BADGEs), and novolac glycidyl ethers (NOGEs) in indoor air from Albany, New York, USA, and its implications for inhalation exposure. *Chemosphere*. 2016; 151: 1-8. doi: 10.1016/j.chemosphere.2016.02.038

50. Vinas P, Campillo N, Martinez-Castillo N, Hernandez-Cordoba M. Comparison of two derivatization-based methods for solid-phase microextraction-gas chromatography-mass spectrometric determination of bisphenol A, bisphenol S and biphenol migrated from food cans. *Anal Bioanal Chem*. 2010; 397(1): 115-125. doi: 10.1007/s00216-010-3464-7

51. Gallart-Ayala H, Moyano E, Galceran MT. Analysis of bisphenols in soft drinks by on-line solid phase extraction fast liquid chromatography-tandem mass spectrometry. *Anal Chim Acta*. 2011; 683(2): 227-233. doi: 10.1016/j.aca.2010.10.034

52. Liao C, Kannan K. Concentrations and profiles of bisphenol A and other bisphenol analogues in foodstuffs from the United States and their implications for human exposure. *J Agric Food*

ISSN 2377-1542
http://dx.doi.org/10.17140/GOROJ-4-141

Chem. 2013; . 61(19): 4655-4662. doi: 10.1021/jf400445n

53. Liao C, Kannan K. A survey of bisphenol A and other bisphenol analogues in foodstuffs from nine cities in China. *Food Addit Contam Part A Chem Anal Control Expo Risk Assess*. 2014; 31(2): 319-329. doi: 10.1080/19440049.2013.868611

54. Russo G, Barbato F, Grumetto L. Monitoring of bisphenol A and bisphenol S in thermal paper receipts from the Italian market and estimated transdermal human intake: A pilot study. *Sci Total Environ*. 2017; 599-600: 68-75. doi: 10.1016/j.scitotenv.2017.04.192

55. Liao C, Liu F, Kannan K. Bisphenol S, a new bisphenol analogue, in paper products and currency bills and its association with bisphenol a residues. *Environ Sci Technol*. 2012; 46(12): 6515-6522. doi: 10.1021/es300876n

56. Glausiusz J. Toxicology: The plastics puzzle. *Nature*. 2014; 508(7496): 306-308.

57. Jurek A. Leitner E. Analytical determination of bisphenol A (BPA) and bisphenol analogues in paper products by GC-MS/MS. *Food Addit Contam Part A Chem Anal Control Expo Risk Assess*. 2017; 34(7):1225-1238. doi: 10.1080/19440049.2017.1319076

58. Zhou X, Kramer JP, Calafat AM, Ye X. Automated on-line column-switching high performance liquid chromatography isotope dilution tandem mass spectrometry method for the quantification of bisphenol A, bisphenol F, bisphenol S, and 11 other phenols in urine. *J Chromatogr B Analyt Technol Biomed Life Sci*. 2014; 944: 152-156. doi: 10.1016/j.jchromb.2013.11.009

59. Ye X, Wong LY, Kramer J, et al. Urinary concentrations of bisphenol A and three other bisphenols in convenience samples of U.S. Adults during 2000-2014. *Environ Sci Technol*. 2015; 49(19): 11834-11839. doi: 10.1021/acs.est.5b02135

60. Liu J, Li J, Wu Y, et al. Bisphenol A Metabolites and Bisphenol S in Paired Maternal and Cord Serum. *Environ Sci Technol*. 2017. doi: 10.1021/acs.est.6b05718

61. Niu Y, Wang B, Zhao Y, Zhang J, Shao B. A highly sensitive and high-throughput method for the analysis of bisphenol analogues and their halogenated derivatives in breast milk. *J Agric Food Chem*. 2017. doi: 10.1021/acs.jafc.7b04394

62. Zalmanova T, Hoskova K, Nevoral J, et al. Bisphenol S negatively affects the meotic maturation of pig oocytes. *Sci Rep*. 2017; 7(1): 485. doi: 10.1038/s41598-017-00570-5

63. Ji K, Hong S, Kho Y, Choi K. Effects of bisphenol S exposure on endocrine functions and reproduction of zebrafish. *Environ Sci Technol*. 2013; 47(15): 8793-800. doi: 10.1021/es400329t

64. Yamasaki K, Noda S, Imatanaka N, Yakabe Y. Comparative study of the uterotrophic potency of 14 chemicals in a uterotrophic assay and their receptor-binding affinity. *Toxicol Lett.* 2004; 146(2): 111-120. doi: 10.1016/j.toxlet.2003.07.003

65. Stroheker T, Chagnon MC, Pinnert MF, Berges R, Canivenc-Lavier MC. Estrogenic effects of food wrap packaging xenoestrogens and flavonoids in female Wistar rats: A comparative study. *Reprod Toxicol*. 2003; 17(4): 421-432. doi: 10.1016/S0890-6238(03)00044-3

66. Rochester JR and Bolden AL. Bisphenol S and F: A systematic review and comparison of the hormonal activity of bisphenol A substitutes. *Environ Health Perspect*. 2015; 123(7): 643-650. doi: 10.1289/ehp.1408989

67. Rosenmai AK, Dybdahl M, Pedersen M, et al. Are structural analogues to bisphenol a safe alternatives? *Toxicol Sci*. 2014; 139(1): 35-47. doi: 10.1093/toxsci/kfu030

68. Hengstler JG, Foth H, Gebel T, et al. Critical evaluation of key evidence on the human health hazards of exposure to bisphenol A. *Crit Rev Toxicol*. 2011; 41(4): 263-291. doi: 10.3109/10408444.2011.558487

GYNECOLOGY AND OBSTETRICS RESEARCH

Openventio PUBLISHERS

ISSN 2377-1542 Open Journal http://dx.doi.org/10.17140/GOROJ-4-142

Research

*Corresponding author
Doaa Abdelnaby Marey, MBBCH
Department of Obstetrics and Gynecology, Tanta University
Tanta, 31111, Egypt
Tel. +201010304729
E-mail: doaamarey2012@gmail.com

Volume 4 : Issue 2
Article Ref. #: 1000GOROJ4142

Article History
Received: November 20th, 2017
Accepted: December 12th, 2017
Published: December 13th, 2017

Citation
Marey DA, Dawood AS, Mostafa MZ, Salem HA. Outcome of stepwise uterine sparing approach as a conservative surgical management of placenta accreta. *Gynecol Obstet Res Open J.* 2017; 4(2): 36-40. doi: 10.17140/GOROJ-4-142

Outcome of Stepwise Uterine Sparing Approach as a Conservative Surgical Management of Placenta Accreta

Doaa Abdelnaby Marey, MBBCH[1]; Ayman Shehata Dawood, MD[2]; Mostafa Zeinelabedeen Mostafa, MD[3]; Hesham Abdelaziz Salem, MD[3]

[1]*Resident of Obstetrics and Gynecology, Tanta University, Tanta, Egypt*
[2]*Lecturer of Obstetrics and Gynecology, Tanta University, Tanta, Egypt*
[3]*Professor of Obstetrics and Gynecology, Tanta University, Tanta, Egypt*

ABSTRACT

Introduction: The incidence of placenta accreta is rising as a consequence of increased rate of cesarean sections and placenta previa which is the strongest risk factor. Intractable postpartum hemorrhage associated with placenta accrete is a leading direct cause of maternal morbidity and mortality. Major surgical modalities were described for management of placenta accreta like hysterectomy, systemic pelvic devascularization, stepwise surgical measures, intervention radiology methods and massive blood transfusions, all were recommended to be used for successful management and saving the maternal life.
Patients and Methods: Fifty cases of placenta accrete were included in our study. They were selected from Obstetrics and Gynecology Department at Tanta University Hospital diagnosed by ultrasound (US) and magnetic resonance imaging (MRI). Pre-operative evaluation, laboratory investigations, and cross matched blood were done. Stepwise uterine sparing technique included simply: double ligation of uterine artery at two different levels on both sides before and after placental removal, lower at level of uterine isthmus and higher for utero-ovarian vessels ligation. Hemostatic quadruple sutures with sewing the placental bed were applied for control bleeding at the placental site attachment. Finally insertion of triple way Foley's catheter through the cervix and inflation to 50 cc saline to compress lower uterine segment and drain bleeding.
Results: The stepwise uterine sparing procedure achieved a high success rate 96%. From a total 50 cases with placenta accrete, 41 cases (82%) passed their major surgery and recovery period without any reported complications. There were some common complications between the same cases. There was 14% (7 cases) complicated with bladder injury, 8% (4 cases) with fever, also 8% (4 cases) with UTI, 12% (6 cases) wound infection and 10% (5 cases) needed post-operative maternal ICU admission. Neither maternal death, DIC, readmission for any cause nor relaparotomy was reported for any case.
Conclusion: The stepwise uterine sparing procedure was successful as a conservative form of surgical management of placenta accrete with preserving the uterus and fertility, saving patient's life and minimizing major surgical interventions in all patients.

KEY WORDS: Placenta accrete; Uterine sparing technique.

ABBREVIATIONS: MRI: Magnetic Resonance Imaging; UTI: Urinary Tract Infection; DUAL: Double Uterine Artery Ligation on both sides; RBCs: Red Blood Cells.

INTRODUCTION

Placenta accrete is a life-threatening obstetric condition which requires multidisciplinary team for management. It is an abnormal firm attachment of placenta into the uterine wall. It is a high risk pregnancy condition, in which blood vessels and other parts of the placenta grow too deep into the uterine wall. It occurs when a defect in the decidua basils allows chorionic villi to invade the myometrium and the normal decidua fails to develop. It is associated with the highly invasive and penetrating power of the developing trophoblast.[1]

ISSN 2377-1542
http://dx.doi.org/10.17140/GOROJ-4-142

Placenta accreta may lead to massive obstetric hemorrhage with attempt to remove the placenta leading to several complications such as disseminated intravascular coagulopathy, cesarean hysterectomy, multiple surgical injuries to the ureters, bladder, and other viscera, adult respiratory distress syndrome, renal failure, hypovolemic shock, circulatory collapse and need for post-operative intensive care unit (ICU) or death. The average amount of blood loss at delivery in a case of placenta accreta is 3,000-5,000 ml.[2]

Diagnosis of placenta accreta can be done by different modalities such as Ultrasound Grey scale, color Doppler (CD) and Magnetic Resonance Imaging (MRI). Ultrasonography is usually employed as the primary modality for antenatal diagnosis of invasive placentation. MRI is reported to be complementary to the ultrasound, as it may help in diagnosing of invasive placentation, especially in those cases in which ultrasound (US) is not conclusive as posterior placenta previa.[3]

Prenatal diagnosis of invasive placentation is associated with a reduced risk of maternal complications by enabling the surgeon to plan for the type of resources needed at the time of delivery as management is a team work. These resources include two seniors obstetrician staff, anesthesia team, neonatologists, available blood products, possible intervention radiology for uterine artery embolization or internal iliac artery occlusion, urologists if surgery associated with bladder or ureteric injury, vascular surgery for internal iliac artery ligation and need for maternal post-operative ICU admission.[4]

Till now, it has been found that there is no definite planned management of placenta accreta as it depends upon personal expertise and hemodynamics of patient. In the past, it was generally accepted that placenta accreta was well and ideally treated by total abdominal hysterectomy. Hysterectomy is a lifesaving measure to manage uncontrolled uterine hemorrhage.[5]

Recently, obstetricians searched for new different modalities for removal of the placenta with less blood loss and fewer complications with repair of the uterus at the time of the delivery to preserve the female fertility. This study was conducted to evaluate the stepwise uterine sparing technique as a conservative management of placenta accrete for preserving the uterus and fertility of the female with minimizing surgical complications.

PATIENTS AND METHODS

Study Setting and Design

Prospective, single armed clinical trial study conducted at Obstetrics and Gynecology Department of Tanta University, Tanta, Egypt in the period from April 2016 till September 2016.

Patient Selection

A total of fifty pregnant women with placenta accreta after 32 weeks of gestation diagnosed by Doppler Ultrasonography and MRI or discovered intra-operatively on surgical table in emergent cases. False diagnosed placenta accreta or managed cases with severe destruction of lower uterine segment and non-separable placenta which needed hysterectomy were excluded from the study.

Elective termination of pregnancy was conducted at completed 36 weeks of gestation. While in emergent cases, termination mediated regardless of the gestational age. Preparation of cross matched packed red blood cells (RBCs) and four units of fresh frozen plasma was a routine practice before the beginning of surgery.

Surgical Technique

- Under general anesthesia all patients were operated. The following steps were done in all cases by the same surgeon:
- Dissection of the urinary bladder from anterior wall of lower uterine segment as much as possible for good exposure, with cauterization or ligation of the newly formed utero-vesical anastomotic branches.
- High transverse incision of the uterus at upper border of placenta to avoid trans-placental incision which provoked severe bleeding then extraction of the baby with ecbolics administration.
- *Double uterine artery ligation on both sides (DUAL)*. First ligature was done before separation of the placenta lower at the level of the uterine isthmus. Second ligature was done after separation of the placenta higher at the level of utero-ovarian anastomosis.
- *Removal of placenta*. Either the total placenta or piece meal was removed according to the degree of placental invasion.
- Hemostatic "square" quadruple sutures at lower uterine segment at the bleeding points or even sewing the placental bed. If there were destructive edges of lower uterine segment, local resection of the invaded part of the uterus with the placenta and trimming the edges was done to provide healthy edges for sutures and repair.
- Insertion of triple way Foley catheter size 24 F inflated by 50 cc saline to compress the bleeding points on the lower uterine segment. It was inserted by assistant or straight artery forceps from the uterine cavity descending to the cervix and caught by another assistant from the vagina. It was preferred to be done from above to avoid upward ascending vaginal infection and keep the intra cervical portion aseptic. This triple way catheter aided additional benefits in irrigation and drainage the uterine cavity from any retained blood.
- Closure of uterine incision wall in continuous double layers, the first layer was associated with significant reductions of blood loss, second layer for tightness of the sutures.
- If the procedure associated with bladder injury (from placental invasion to the serosal covering of the bladder as in the case of placenta percreta), urologists were asked to repair. Also if there was invasion or penetration of the urinary bladder, partial cystectomy and repair were done.
- Insertion of wide pore pelvic intra-peritoneal drains to drain any blood or retained fluid also for early and meticulous follow-up for any complications.

ISSN 2377-1542
http://dx.doi.org/10.17140/GOROJ-4-142

Methods

All demographic data, pre-operative findings, operative data, complications, and post-operative recording of vital signs, drains, urinary output, bleeding, fever and number of transfused blood units if needed also hemoglobin level checked 6 hours post-operatively.

Ethical Approval

This study was approved by local ethical committee of Tanta University before start of this study. All patients were informed about procedure, its risks/benefits and all signed a written consent.

Statistical Methods

The results were analyzed by SPSS, version 18, USA. The tests used were mean, standard deviation, and percentage.

RESULTS

In this study, the enrolled patients (n=50) with placenta accrete were diagnosed prenatally with Ultrasound and MRI. The demographic data of the patients were presented in Tables 1 and 2.

The surprising finding in this study was that patients were so younger due to increasing rate of cesarean sections and encouraging preservation of uterus.

Hemoglobin level was significantly dropped after the procedure which was corrected later by cross-matched blood transfusion.

This study showed a high success rate of the stepwise uterine sparing technique in preserving the uterus. The success rate was 96%, included 48 cases from total 50 ones successfully preserved the uterus and only 2 cases who required hysterectomy representing 4%. But there were some related complications in the form of 14% (7 cases) complicated with bladder injury, 8% (4 cases) with post-operative fever, also 8% (4 cases) with urinary tract infection (UTI), 12% (6 cases) wound infection and 10% (5 cases) needed post-operative maternal ICU admission. Postpartum hemorrhage was detected in 6% (3 cases) which was controlled by uterine massage and strong ecbolic. There was no need for vascular surgery during operation, also no need for re-operation or readmission for any case. No visceral or ureteric injuries were reported. Complications are illustrated in Figure 1.

Table 1: Demographic Data of the Patients.

		Range	Mean±SD
Age		24-39	31.78±3.89
Number of previous CS		0-4	3.12±1.68
Parity		0-6	3.38±1.64
Gestational age at delivery (weeks)	**Preterm**	34-35.6	35.3±0.8
	Full-term	36-39	37.10±1.40
Duration since last CS		1-6 years	3.24±1.74

Table 2: Operative Findings of This Study.

		Range	Mean±SD
Type of morbidly adherent placenta (n, %)			
Placenta accreta		30 (60.00%)	
Placenta increta		15 (30.00%)	
Placenta percreta		5 (10.00%)	
Operative time (minutes)		75-140	105.65±27.93
Intraoperative blood transfusion units)		2-5	3.80±1.64
Hospital stay (days)	**Non complicated**	2-3	2.6±0.46
	Complicated cases	7-11	9.27±2.34
Intraoperative blood loss (mL)		1000-2500	1750±1060.66
Postoperative blood transfusion (units)		2-5	3.24±1.05
Postoperative blood loss (mL)		400-1100	745.65±238.96
Hemoglobin level (gm/dl)	**Pre-operative**	8-11.4	9.62±1.21
	Post-operative	6.7-10.6	8.22±1.08

ISSN 2377-1542
http://dx.doi.org/10.17140/GOROJ-4-142

Figure 1: Procedure Related Complications.

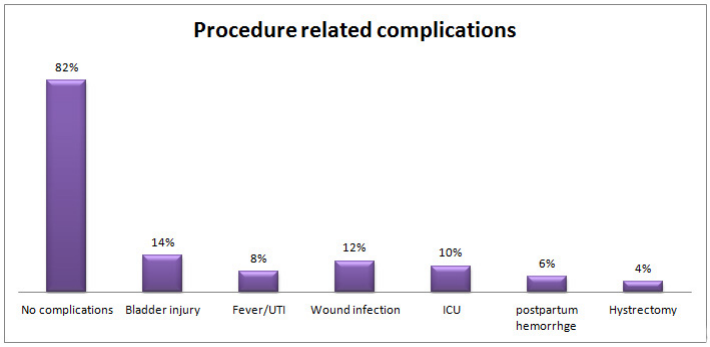

DISCUSSION

The results of this study were encouraging to use the stepwise uterine sparing technique in preservation of uterus in morbidly adherent placenta cases. Previous studied conducted to assess the outcome of uterine sparing techniques, were found to be different in the techniques used and results obtained. The results of this study are in agreement with Walker et al in the pre-operative preparations for management of cases with placenta accreta. The main difference was that Walker et al used prophylactic occlusion of the anterior division of the internal iliac artery which is an invasive procedure. Our study achieved a high success rate with uterine artery ligation alone. Comparing the results of both studies, operative time (107 minutes) similar to our study (105 minutes), also the hospital stay was (5 days), our only (3-11 days) but it had more bladder injury (30%) than our study (14%).[6]

Shahin et al conducted a similar study depending on bilateral uterine artery ligation for control bleeding. Also the idea of using B-Lynch suturing as compression sutures is similar to the quadruple local hemostatic ones used to control bleeding. The differences were that in Shahin et al, two cases needed internal iliac artery ligation, needed post-operative ICU admission and complicated with disseminated intravascular coagulation (DIC) and maternal death. Shahin et al was associated with the need for (2-5 units) units of fresh blood transfused intra-operatively which were less than our study where (1-4) units of blood transfusion were needed. The total hospital stay in Shahin et al was (17 days) which was longer than hospital stay in our study (11 days).[7]

El Shazly et al used bilateral uterine artery ligation as primary step with 8-suture compression procedure as a second step for control bleeding associated with placenta accreta when uterine artery ligation failed to stop bleeding. The difference was that the average time of this procedure which was relatively short (142 seconds). The total intra-operative time of our surgical procedure was (75-140 minutes). The mean estimated amount of intra-operative blood loss was (2830 mL) during this procedure and (2375 mL) in women managed with bilateral uterine artery ligation alone in Elshazly et al study while in our study, the total amount of intraoperative blood loss was (1750 mL).[8]

Shabana et al reported a modified approach of some surgical steps similar to our study but the only difference was that Shabana et al depended on bilateral ligation of the anterior division of internal iliac artery to control bleeding. The operative time in Shabana et al study was (70-140 minutes), similar to our study (75-140 minutes) and number of blood transfusion units was (2-6 units), similar to our study (2-5 units). The associated complications were (8.5%) rate of cesarean hysterectomy, comparing to our study which was (4%) only. As regard complications 10 patients (14.1%) had urinary tract complications similar to our study, nine (90%) were managed during cesarean section and one case presented later in the form of vesico-uterine fistula. No evidence of later complications as vesico-uterine fistula or later repair in our procedure.[9]

Kelekci et al achieved a successful technique in management of placenta accrete using the same our surgical steps including suturing the placental bed with squarely shaped sutures for hemostasis, ligation of utero-ovarian anastomosis branches and finally insertion of a balloon of 3-ways 20 F Foley catheter which was inflated by 80 cc saline and placed into the intrauterine cavity. The study of Kelekci et al differed mainly in internal iliac artery ligation for control bleeding and leaving placenta in situ in some cases. Also there were some different results, such as the units of blood transfusion (2-7) units while in our study (2-5) units. The operative time was (110±20) minutes, while in our study was (75-140) minutes and the mean hospital stay was (4.2±0.4) days, while in our study was (3-11) days. Comparing rates of associated complications, one patient had post-operative wound infection while in our study, 6 cases (12%). The post-operative febrile reactions developed in 2 patients in Kelekci et al study while in our study 4 cases (8%) developed post-operative febrile reaction.[10]

Shehata et al reported a study with 100% success rate. It completely agreed with our surgical technique. Both depended on bilateral ligation of uterine artery, higher incision of uterus and insertion of Foley catheter for compressing lower uterine segment. There were some different results. The operative time was (60-100 minutes), while our study (75-140 minutes) and

ISSN 2377-1542
http://dx.doi.org/10.17140/GOROJ-4-142

blood transfusion (2-4 units) and our study (2-5 units). The complications were presented in 6 cases from the all 15 cases represents (40%), while (82%) of cases in our study passed their surgery without any complications. Two cases (13.3%) had bladder injury, our study (14%), 2 cases (13.3%) had pyrexia, compared to our study (8%), 1 case (6.66%) had pyometria and 1 case (6.66%) of wound disruption. There was readmission for two cases but no need for ICU admission for any case. While in our study, 5 cases needed post-operative ICU admission represented (10%) but there was no need for readmission for any case.[11]

Palacios-Jaraquemada et al conducted a study with nearly similar surgical procedure which included removal of destructed part of lower uterine segment invaded by the placenta and trimming the uterine edges with repair the defect then insertion of a Foley's balloon catheter, three-way 22 F, in the lower uterine segment as in our study. The differences were that higher success rates were observed without the need for uterine artery ligation rather than in our study which depended mainly on uterine artery ligation. Also repair of the uterine edges in our study was mediated by healthy uterine tissue with usual sutures without need for using any mesh or other foreign bodies. Comparing rate of CS hysterectomy, 18 of total 68 cases needed cesarean hysterectomy while in our study included 2 from total 50 cases. There were some different surgical complications, 1 case had pelvic hemorrhage, 2 cases had coagulopathies, 3 cases with uterine infection, 2 ureteral ligations, 2 iatrogenic foreign bodies reaction, 3 post-operative collections, rupture of an epigastric artery in 1 case and vesical fistula in another case. In our study, these complications never had been reported in any case.[12]

CONCLUSIONS

Successful management of the potentially catastrophic conditions associated with abnormal placental adhesion requires early antenatal diagnosis with well preparation of the selected cases. Early and proper management of cases of placenta accreta can preserve life of both mother and her fetus with preserving her uterus well-functioning for further pregnancy. In this study, we have presented a simple approach as a conservative treatment for placenta accreta cases. Our surgical procedure was effective and safe in the conservative management of patients with placenta accreta.

ACKNOWLEDGEMENT

We are very much thankful to our professors, assistants and residents who helped us to complete this work. We also thankful to statistics analyzers.

CONFLICTS OF INTEREST

The authors declare that they have no conflicts of interest.

REFERENCES

1. Jauniaux E, Jurkovic D. Placenta accreta: Pathogenesis of placenta, iatrogenic uterine disease. *Placenta*. 2012; 33(4): 244-251. doi: 10.1016/j.placenta.2011.11.010

2. Kastner ES, Figueroa R, Garry D, Maulik D. Emergency peripartum hysterectomy: Experience at a community teaching hospital. *Obstet Gynecol.* 2002; 99(6): 971-975. doi: 10.1016/S0029-7844(02)01999-3

3. Tonni G, Araujo Junior E. Three-dimensional ultrasound in obstetrics practice: Myth or reality. *Rev Bras Ginecol Obstet*. 2014; 36(4): 143-145. doi: 10.1590/S0100-7203201400040001

4. Warshak CR, Ramos GA, Eskander R, et al. Effect of predelivery diagnosis in 99 consecutive cases of placenta accreta. *Obstet Gynecol*. 2012; 115(1): 65-69. doi: 10.1097/AOG.0b013e3181c4f12a

5. Tebeu PM, Ndive PE, Ako WT, Biyaga PT, Fomulu JN, Doh AS. Emergency obstetric hysterectomy at University Hospital, Yaoundé, Cameroon. *Int J Gynaecol Obstet*. 2013; 120(1): 91-92. doi: 10.1016/j.ijgo.2012.07.013

6. Walker MG, Allent L, Windrim RC, et al. Multidiscipli-nary management of invasive placenta previa. *J Obstet Gynaecol Can*. 2013; 35(5): 417. doi: 10.1016/S1701-2163(15)30932-4

7. Shahin AY, Farghaly TA, Mohamed SA, Youssef AM. Bilateral uterine artery ligation plus B-Lynch procedure for atonic postpartum hemorrhage with placenta accreta. *Int J Gynaecol Obstet*. 2009; 108(3): 187-190. doi: 10.1016/j.ijgo.2009.08.035

8. El Shazly S, Badee A, Ali M. The use of multiple 8 compression suturing as a novel procedure to preserve fertility in patients with placenta accreta: Case series. *Aust N Z J Obstet Gynaecol*. 2012; 52(4): 395-399. doi: 10.1111/j.1479-828X.2012.01449.x

9. Shabana A, Fawzy M, Refaie W. Conservative management of placenta percreta: a stepwise approach. *Arch Gynecol Obstet*. 2015; 291(5): 993-998. doi: 10.1007/s00404-014-3496-x

10. Kelekci S, Ekmekci E, Aydogmus S, Gencdal S. A comprehensive surgical procedure in conservative management of placenta accreta: A case series. *Medicine (Baltimore)*. 2015; 94(7): e529. doi: 10.1097/MD.0000000000000529

11. Shehata A, Hussein N, El-Halwagy A, El Gergawy A. Could simple procedures minimize hysterectomy in management of placenta accreta? *J Obstet Gynaecol Res*. 2015; 2(4): 213-217.

12. Palacios Jaraquemada JM, Pesaresi M, Nassif JC, Hermosid S. Anterior placenta percreta: Surgical approach, hemostasis and uterine repair. *Acta Obstet Gynecol Scand*. 2004; 83(8): 738-744. doi: 10.1111/j.0001-6349.2004.00517.x

GYNECOLOGY AND OBSTETRICS RESEARCH

Openventio PUBLISHERS

ISSN 2377-1542 Open Journal http://dx.doi.org/10.17140/GOROJ-4-143

Commentary

*Corresponding authors
Erin Bishop, MD
Assistant Professor
Department of Obstetrics and Gynecology
Division of Gynecology Oncology
Medical College of Wisconsin
8701 Watertown Plank Road
Milwaukee, WI 53226, USA
Tel. 414-805-6623
Fax: 414-805-6805
E-mail: erbishop@mcw.edu

Ramani Ramchandran, PhD
Professor
Department of Obstetrics and Gynecology
Division of Gynecology Oncology
Medical College of Wisconsin
8701 Watertown Plank Road
Milwaukee, WI 53226, USA
Tel. 414-955-2387
Fax: 414-955-6325
E-mail: rramchan@mcw.edu

Volume 4 : Issue 2
Article Ref. #: 1000GOROJ4143

Article History
Received: December 6th, 2017
Accepted: December 20th, 2017
Published: December 20th, 2017

Citation
Bishop E, Ramchandran R. Tumor conditioning regimens: An evolution in cancer treatment that relies on short-term sacrifice for long-term gain. *Gynecol Obstet Res Open J.* 2017; 4(2): 41-43. doi: 10.17140/GOROJ-4-143

Tumor Conditioning Regimens: An Evolution in Cancer Treatment that Relies on Short-Term Sacrifice for Long-Term Gain

Erin Bishop, MD[1*]; Ramani Ramchandran, PhD[1,2*]

[1]Department of Obstetrics and Gynecology, Division of Gynecology Oncology, Medical College of Wisconsin, 8701 Watertown Plank Road, Milwaukee, WI 53226, USA

[2]Department of Pediatrics, Division of Neonatology, Developmental Vascular Biology Program, Children's Research Institute, Medical College of Wisconsin, 8701 Watertown Plank Road, Milwaukee, WI 53226, USA

In this commentary, the authors discuss a new concept for tumor treatment, which is based on observations from published studies and clinical practice protocols. This new treatment regimen, which we coin "Tumor Conditioning Regimens," abbreviated as TCRs is based on the idea that by conditioning tumors with oxygenation, increasing mutation loads or normalizing vessels, we create a permissive environment for tumor growth in the short-term, which will eventually in the long run benefit tumor regression. In our view, such a strategy of making things worse before they get better for tumor treatment has not been articulated in the literature although anecdotal examples exist, which we have highlighted in the commentary. This commentary serves as a discussion starter for the scientific and clinical community as to the pros and cons of such an approach.

Traditional concepts in cancer treatment, including gynecologic cancers, involve using chemotherapeutic agents to target malignant cell populations, while sparing off-target effects on surrounding normal cells. This approach is based on decades of research focused on alterations within cells that allow them to become malignant and metastasize.[1] Over the last several years an increased understanding of the role of the tumor microenvironment and the host immune system in the development of cancer cell resistance to treatment has led to revisiting traditional approaches to treatment.[2] Treatment now often involves *recruiting* the host (patient) immune system and surrounding microenvironment to support and enhance the anticancer effects of treatment. With this shift in understanding of tumor biology a new concept has evolved where tumor conditioning regimens (TCR) are used that often improve conditions for tumor growth, before responses are ultimately observed. TCR is defined as, "*regimens that will influence tumor microenvironment, which may seem advantageous to tumor growth in the short run but in the long run will enable subsequent secondary treatment strategies to be more efficacious.*" The TCR concept espouses the theory that "*making things worse in the short-term will actually provide benefits in the long-term*." In this commentary, we provide three treatment examples which are current practices based on ideas of increased tumor perfusion and increased mutation burden. These practices broadly span the fields of radiation oncology, vascular biology and immune biology, and apply to gynecological cancer treatments.

The TCR concept, in our opinion, is not entirely new but clearly counterintuitive. For example, in the field of radiation oncology solid tumors, including cervical cancer, with poor oxygenation do not respond as well to radiation as tumors with adequate oxygenation.[3] Improving oxygenation to a tumor seems counterintuitive, with the concern that this could potentially allow for tumor growth. In fact, oxygen chemically modifies radiation-induced DNA damage, making it irreparable, a process known as the oxygen fixation hypothesis.[4] Therefore, methods are employed to *improve* oxygenation such as surgically decreasing tumor size prior to radiation, and administering concurrent medications that improve oxygenation during radiation.[5]

Increased oxygenation is a hallmark of angiogenesis, the growth of new blood ves-

ISSN 2377-1542 http://dx.doi.org/10.17140/GOROJ-4-143

sels from existing vessels. The anti-vascular endothelial growth factor agent bevacizumab is used in many tumor types including ovarian and cervical cancers. In glioblastomas (GB), a malignant brain tumor known to be highly vascularized, patients treated with bevacizumab only show modest improvement in response and no improvement in overall survival.[6,7] In general, the tumor-associated vasculature is disorganized, has poor structural integrity,[8] and perfusion is poor. Vessel normalization, a concept proposed by Rakesh Jain and others, suggests that if we could convert the tumor vascular bed briefly from a pathological to a physiological angiogenesis state, subsequent therapy regimens will be effective.[9-11] This is an intriguing idea, which has concerns in that during this window of normalization, tumor cells will benefit from conditions for improved growth and metastasis. While this is possible, improved perfusion would also increase ability for treatments to penetrate tumor, and thus combining anti-angiogenics with novel therapeutics has the potential to provide a solution to this problem. We do caution the reader that additional pre-clinical research using appropriate model systems that can mimic perfusion will help gain evidence for the feasibility of this strategy.

A second example of the TCR concept involves the host immune system. Molecules on immune cells, or "checkpoints," are used to initiate or stop immune responses to foreign cells or self. T-cells express a checkpoint protein called programmed cell death protein-1 (PD-1) and when PD-1 binds to the protein programmed death ligand-1 (PD-L1) on normal cells, this signals the T-cell to not attack the normal cell.[12] Some cancer cells utilize this host defense mechanism to their advantage by carrying large amounts of PD-L1 protein that keep the immune system from attacking them.[13] Checkpoint inhibitors are used in many types of cancer and are being actively investigated for use in ovarian cancer. In melanoma, it has been shown that patients with a high mutation burden have increased neo-antigen formation and subsequent increase in response to checkpoint inhibitors.[14] Similar findings have been observed in GB patients and patients with metastatic tumors with a high frequency of somatic mutations.[15] Due to these findings, DNA *damaging* agents, such as radiation and chemotherapy, along with checkpoint inhibitors are proposed as one way to overcome resistance to immune therapy.[16] The idea of using TCR to create more DNA damage, or make the tumor "worse" (increase mutation burden for revelation of novel epitopes) to improve responses to immune therapy is a shift from traditional treatment where the goal is to target and decrease the population of cells with DNA damage.

Finally, from a clinical standpoint, as immune therapy has become more common in clinical trials, including gynecologic cancer trials, the criteria for assessing response to therapy has changed. When patients initiate immune therapy, it is common to see an initial *increase* in tumor size (pseudo-progression) before an eventual shrinkage of lesions due to activation and recruitment of the host immune system in and around the tumor. When patients are on clinical trials, a common criterion used by clinicians to determine radiological response to trial therapy is the Response Evaluation Criteria in Solid Tumors (RECIST).[17] With the initiation of immune therapy in clinical trials, a new response criteria have been developed, immune-related Response Evaluation Criteria in Solid Tumors (irRECIST)[18,19] that accounts for the initial increase in tumor size. Again, this is an example where a clinician must accommodate for an initial impression of worsening disease before an eventual improvement, which can be difficult for both the clinician and the patient.

As new treatments emerge for gynecological cancer, understanding how to make a tumor respond to therapy will need to be adjusted to incorporate not just the tumor, but the numerous surrounding host factors involved as well. Some of these modalities will involve using TCR to create initial improvement in conditions for tumor growth, which is acceptable in the short-term if the long-term outcome is regression.

ACKNOWLEDGMENTS

We thank scientists who work with us and patients who have been treated under our care for inspiring the ideas that are discussed in this document. We also thank Dr. Denise Uyar, Division Chief of Gynecology Oncology in Department of OBGYN at MCW for providing critical feedback on this document. Dr. Bishop is supported by Laura's Smile Foundation and the Wisconsin Ovarian Cancer Alliance. Dr. Ramchandran is partly supported by NIH grants (HL123338, HL136423, HL033833, HL120585), and institutional support from Medical College of Wisconsin (MCW), Children's Research Institute and Departments of Pediatrics and Obstetrics and Gynecology (OBGYN). Both investigators are supported by Women's Health Research Fund in the Department of OBGYN at MCW.

CONFLICTS OF INTEREST

The authors declare no conflicts of interest, and opinions expressed here are based on facts from scientific papers.

REFERENCES

1. Hanahan D, Weinberg RA. The hallmarks of cancer. *Cell*, 2000; 100(1): 57-70. doi: 10.1016/S0092-8674(00)81683-9

2. Musrap N, Diamandis EP. Revisiting the complexity of the ovarian cancer microenvironment—clinical implications for treatment strategies. *Mol Cancer Res*. 2012; 10(10): 1254-1264. doi: 10.1158/1541-7786.MCR-12-0353

3. Wilson WR, Hay MP. Targeting hypoxia in cancer therapy. *Nat Rev Cancer*. 2011; 11(6): 393-410. doi: 10.1038/nrc3064

4. Howard-Flanders P, Alper T. The sensitivity of microorganisms to irradiation under controlled gas conditions. *Radiat Res*. 1957; 7(5): 518-540.

5. Overgaard J. Hypoxic modification of radiotherapy in squa-

ISSN 2377-1542
http://dx.doi.org/10.17140/GOROJ-4-143

mous cell carcinoma of the head and neck--a systematic review and meta-analysis. *Radiother Oncol*. 2011; 100(1): 22-32. doi: 10.1016/j.radonc.2011.03.004

6. Gilbert MR, Dignam JJ, Armstrong TS, et al. A randomized trial of bevacizumab for newly diagnosed glioblastoma. *N Engl J Med*. 2014; 370(8): 699-708. doi: 10.1056/NEJMoa1308573

7. Chinot OL, Wick W, Mason W, et al. Bevacizumab plus radiotherapy-temozolomide for newly diagnosed glioblastoma. *N Engl J Med*. 2014; 370(8): 709-722. doi: 10.1056/NEJMoa1308345

8. Jain RK, di Tomaso E, Duda DG, Loeffler JS, Sorensen AG, Batchelor TT. Angiogenesis in brain tumours. *Nat Rev Neurosci*. 2007; 8(8): 610-622. doi: 10.1038/nrn2175

9. Jain RK. Normalization of tumor vasculature: An emerging concept in antiangiogenic therapy. *Science*. 2005; 307(5706): 58-62.

10. Tong RT, Boucher Y, Kozin SV, Winkler F, Hicklin DJ, Jain RK.Vascular normalization by vascular endothelial growth factor receptor 2 blockade induces a pressure gradient across the vasculature and improves drug penetration in tumors. *Cancer Res*. 2004; 64(11): 3731-3736. doi: 10.1158/0008-5472.CAN-04-0074

11. Winkler F, Kozin SV, Tong Rt, et al. Kinetics of vascular normalization by VEGFR2 blockade governs brain tumor response to radiation: Role of oxygenation, angiopoietin-1, and matrix metalloproteinases. *Cancer Cell*. 2004. 6(6): 553-563. doi: 10.1016/j.ccr.2004.10.011

12. Francisco LM, Salinas VH, Brown KE, et al. PD-L1 regulates the development, maintenance, and function of induced regulatory T cells. *J Exp Med*. 2009; 206(13): 3015-3129. doi: 10.1084/jem.20090847

13. Tumeh PC, Harview CL, Yearley JH, et al. PD-1 blockade induces responses by inhibiting adaptive immune resistance. *Nature*. 2014; 515(7528): 568-571. doi: 10.1038/nature13954

14. Restifo NP, Smyth MJ, Snyder A. Acquired resistance to immunotherapy and future challenges. *Nat Rev Cancer*. 2016. 16(2): 121-126. doi: 10.1038/nrc.2016.2

15. Bouffet E, Larouche V, Campbell BB, et al, Immune checkpoint inhibition for hypermutant glioblastoma multiforme resulting from germline biallelic mismatch repair deficiency. *J Clin Oncol*. 2016; 34(19): 2206-2211. doi: 10.1200/JCO.2016.66.6552

16. Twyman-Saint Victor C, Rech AJ, Maity A, et al. Radiation and dual checkpoint blockade activate non-redundant immune mechanisms in cancer. *Nature*. 2015; 520(7547): 373-377. doi: 10.1038/nature14292

17. Eisenhauer EA, Therasse P, Bogaerts J, et al. New response evaluation criteria in solid tumours: revised RECIST guideline (version 1.1). European Journal of Cancer. 2009; 45(2): 228-247. doi: 10.1016/j.ejca.2008.10.026

18. Wolchok JD, Hoos A, O'Day S, et al. Guidelines for the evaluation of immune therapy activity in solid tumors: Immune-related response criteria. *Clin Cancer Res*. 2009; 15(23): 7412-7420. doi: 10.1158/1078-0432.CCR-09-1624

19. Chiou VL, Burotto M. Pseudoprogression and immune-related response in solid tumors. *J Clin Oncol*. 2015; 33(31): 3541-3543. doi: 10.1200/JCO.2015.61.6870

GYNECOLOGY AND OBSTETRICS RESEARCH

Openventio PUBLISHERS

ISSN 2377-1542 Open Journal http://dx.doi.org/10.17140/GOROJ-4-144

Research

*Corresponding author
Salma Samy Abdellateef, MBBCH
Assistant Professor
Department of Obstetrics and Gynecology
Tanta University, Tanta
Gharbia Governorate Egypt
E-mail: salma_samy877@yahoo.com

Volume 4 : Issue 2
Article Ref. #: 1000GOROJ4144

Article History
Received: December 13th, 2017
Accepted: January 11th, 2018
Published: January 11th, 2018

Citation
Abdellateef SS, El Shorbagy SH, Hagras AM, Ghareeb AE. Assessment of maternal nifedipine as a tocolytic agent on the Doppler indices of uterine and fetal umbilical and middle cerebral arteries. *Gynecol Obstet Res Open J*. 2018; 4(2): 44-49. doi: 10.17140/GOROJ-4-144

Assessment of Maternal Nifedipine as a Tocolytic Agent on the Doppler Indices of Uterine and Fetal Umbilical and Middle Cerebral Arteries

Salma Samy Abdellateef, MBBCH*; Shahinaz Hamdy El Shorbagy, PhD; Ahmed Mahmoud Hagras, PhD; Ashraf ELmohamady Ghareeb, PhD

Department of Obstetrics and Gynecology, Tanta University, Tanta, Gharbia Governorate, Egypt

ABSTRACT

Objective: This study was designed to assess the effects of maternal nifedipine administration on blood flow resistance in uterine, umbilical and fetal middle cerebral arteries by evaluating resistance index (RI) and pulsatility index (PI).

Patients and Methods: This was a prospective, observational, analytic cohort study performed in 50 pregnant women undergoing nifedipine tocolysis, all women with a singleton pregnancy between 24 and 34 weeks of gestation, each subject acting as her own control. Doppler assessment of uterine, umbilical and fetal middle cerebral (MCA) arteries was performed before and 24 h and 72 h after an initial 20 mg oral dose, which was repeated at 20 min intervals if contractions failed to diminish up to a total maximum dose of 60 mg. The maintenance dose consisted of 20 mg orally every 6 h. We analyzed whether there was a time effect and compared values at the different time-points.

Results: The research showed that the UtA-RI has increased significantly after 24 h and after 72 h of nifedipine administration (0 h=0.53; 24 h=0.56; 72 h=0.55; p=0.002, p=0.015 respectively). The MCA-RI had decreased significantly after 24 h (p=0.003) of tocolysis returning to baseline after 72 h (0 h=0.75; 24 h=0.73; 72 h=0.74; p=0.150). The MCA-PI had decreased significantly after 24 h (P=0.024) of tocolysis returning to baseline between 24 h and 72 h (0 h=1.85; 24 h=1.75; 72 h=1.79; p=0.204), with no differences in UtA-PI or in the umbilical arteries Doppler (RI & PI) or in the MCA to umbilical artery ratio.

Conclusions: Nifedipine tocolysis is associated with a reduction in RI and PI in the MCA, and an increase in RI in uterine arteries after 24 h but returning to baseline within 72 h, with no long-term effect on fetomaternal circulation in pregnant women at risk of preterm delivery.

KEY WORDS: Preterm; Nifedipine; Doppler.

ABBREVIATIONS: MCA: Middle Cerebral Artery; PI: Pulsatility Index; RI: Resistance Index; UtA: Uterine Artery.

INTRODUCTION

Preterm labor is one of the biggest challenges for obstetricians and so are the preterm babies for the neonatologists. Preterm delivery is defined as labor beginning before completed 37 weeks of gestation. The incidence of preterm labor is reported by the WHO to be 5-11%.[1] Preterm delivery is an international health problem and is responsible for approximately two-thirds of early neonatal morbidity and mortality.[2,3]

Yet, current evidence shows that it is possible to reduce the complications caused by prematurity.[4,5] Consequently, tocolytic therapy has a well-defined role in the management of preterm labor, accomplishing the following objectives: permitting transfer of the pregnant woman to a tertiary care center; prolonging pregnancy for at least 48 h to optimize the ben-

ISSN 2377-1542
http://dx.doi.org/10.17140/GOROJ-4-144

eficial effect of steroids on fetal lung maturity; and prolonging pregnancy in an attempt to improve perinatal outcome.[6,7]

Many pharmacological agents that inhibit uterine contractions are used in clinical practice in an attempt to prevent preterm delivery such as β2 agonists, calcium channel blockers (as nifedipine), progesterone, magnesium sulfate, oxytocin antagonists and anti-prostaglandins (as indomethacin). The maternal and fetal side-effect profiles of tocolytic agents are important considerations in the choice of these agents. According to the most recent Cochrane database review, the use of calcium channel blockers over other tocolytic agents is likely to increase.[8,9]

Nifedipine, a dihydropyridine calcium channel blocker, has emerged as an effective alternative tocolytic agent for management of preterm labor. Although, nifedipine is an effective tocolytic agent with low toxicity and teratogenicity but it has cardiovascular side effects that may affect the mother as well as the fetus.[10,11]

Animal studies suggest that use of calcium channel blockers may result in impaired uterine blood flow, potentially resulting in fetal hypoxemia and academia.[12] This may result in differential changes in the placental and cerebral blood flow resistances which may affect the cerebroplacental Doppler ratio and the overall distribution of cardiac output. However, studies in human pregnancies did not confirm significant alterations in uterine blood flow.[13,14]

PATIENTS AND METHODS

This prospective, observational, analytic cohort study was conducted on 50 pregnant women presented with preterm labor admitted in Department of Obstetrics & Gynecology in University Hospitals of Tanta, Egypt between December 2015 to June 2016 after approval of the ethical committee.

All women with a singleton pregnancy between 24 and 34 weeks of gestation with intact amniotic membranes and showing evidence of premature labor. This was defined as painful and persistent uterine contractions (at least two contractions in 10 min or four in 1 h), resulting in changes in the cervix (at least 2 cm cervical dilatation and 80% ripening). All patients had accurate dating with a gestational age based on the last menstrual period that had been validated with a ultrasound (US) examination, during which crown-rimp length was measured between 11 and 14 weeks; if that wasn't possible, bi-parietal diameter measurement was used between 14 and 22 weeks.

Pregnant women with concomitant morbidities, such as heart or lung disease, high blood pressure, diabetes or infectious disease or an obstetric morbidity (e.g., pre-eclampsia, premature rupture of membranes, gestational diabetes, intrauterine growth restriction or acute fetal distress), were excluded from the study. Patients with maternal hypotension, amnionitis, fever of unknown origin, genital or fetal malformations or uterine fibroids, women already using another tocolytic agent and those in false premature labor were also excluded.

A written consent was taken from all studied women in this research. Full history was taken from all patients. General examination with special attention to blood pressure. For all patients, blood pressure was above 80/50 mmHg before the commencement of treatment.

Abdominal examination to measure the fundal level, palpate the uterine contractions and monitoring of the fetal heart rate. Pelvic examination: to assess the state of membranes and exclude their rupture, to exclude vaginal bleeding and assess the state of the cervix and measure the Bishop score. Sonographic assessment to estimate the gestational age, amount of liquor and to exclude placenta previa, placental abruption and major fetal congenital anomalies.

After Selection of the Cases

All patients received 12 mg intramuscular dexamethasone with another dose 12 hours later to promote fetal lung maturation. Administration of tocolytic agent in the form of oral nifedipine as an initial oral dose of 20 mg, repeated at 20 min intervals if contractions failed to diminish up to a total maximum dose of 60 mg. The maintenance regimen consisted of 20 mg taken orally every 6 h.

Doppler velocimetry on uterine, umbilical and fetal middle cerebral arteries were performed immediately prior to initial nifedipine administration, after 24 hours and 72 hours after therapy. Examinations were carried out with the patients in the semi-Fowler position to avoid orthostatic hypotension. Scans of the vessels were obtained during fetal inactivity, during periods of apnea and in the absence of uterine contractions. The examinations were performed by a specialist, using a Samsung ultrasound machine, model H60, USS- H60NF4K/WR (Samsung, Korea) with 3.5-MHz and 5-MHz convex probes were used. The high-pass filter was set at 100 Hz.

The sequence in which the vessels were examined were uterine arteries followed by the umbilical artery and then fetal MCA. Doppler flow velocimetry of the uterine arteries was performed according to the usual technique. After the ultrasound image of the intersection between the uterine artery and the iliac vessel was obtained, at the 'crossing' with the external iliac artery. The same technique was used for both left and right sides. For the umbilical artery, velocimetry was carried out at free-floating loop of the umbilical cord, and for the MCA it was performed in its peripheral portion. In addition, the cerebroplacental Doppler ratio was calculated.

Finally, all data were entered into and stored in a database. The sonographically measured Doppler indices obtained were correlated with each other and statistically analyzed.

ISSN 2377-1542
http://dx.doi.org/10.17140/GOROJ-4-144

RESULTS

Maternal age ranged between 18-40 with the mean 25.70±4.94. Gravidity ranged between 1-5 with the mean 2.44±1.20. Parity ranged between 0-4 with the mean 1.33±1.15. Gestational age on admission ranged between 25-34 with the mean 30.33±2.54. Fetal weight ranged between 780-2432 with the mean 1611.56±459.73.

The results of the Doppler measurements are shown in Table 1 and Figures 1-4. Blood flow resistance in the placental circulation did not change in the maternal or fetal compartment.

We found that the UtA-RI has increased significantly after 24 h and 72 h of nifedipine administration. Also, the MCA-RI and PI had decreased significantly after 24 h of tocolysis returning to baseline after 72 h, with no differences in UtA-PI or in

Table 1: Doppler Indices before and after Nifedipine Tocolysis.

	Before Mean±SD	24 h Mean±SD	72 h Mean±SD	*p* value Before & 24 h	*p* value Before & 72 h	*p* value 24 h & 72 h
RI Uterine	0.53±0.05	0.56±0.05	0.55±0.05	0.002*	0.015*	0.462
PI Uterine	0.73±0.095	0.77±0.092	0.75±0.087	0.068	0.335	0.385
RI Umbilical	0.57±0.05	0.56±0.04	0.57±0.05	0.422	0.965	0.397
PI Umbilical	1.0±0.21	1.05±0.19	1.02±0.16	0.579	0.211	0.473
RI MCA	0.75±0.03	0.73±0.03	0.74±0.04	0.003*	0.150	0.118
PI MCA	1.85±0.19	1.75±0.21	1.79±0.18	0.024*	0.204	0.313
RI Umbilical/ MCA ratio	0.76± 0.05	0.78±0.05	0.78±0.04	0.268	0.339	0.879

MCA: Middle Cerebral Artery; PI: Pulsatility Index; RI: Resistance Index.

Figure 1: (a) Comparison between Resistive Index of Uterine Artery. (b)Comparison between Pulstility Index of Uterine Artery.

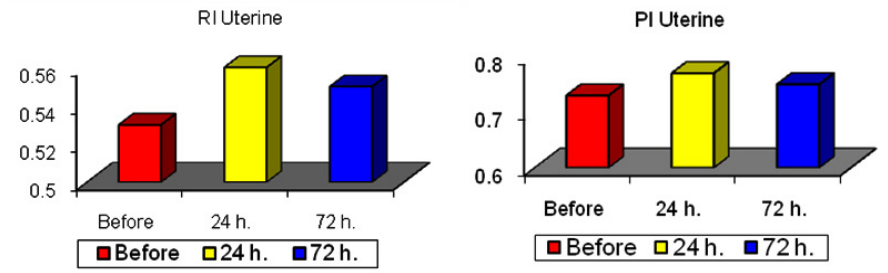

Figure 2: (a) Comparison between Resistive Index of Umbilical Artery. (b) Comparison between Pulsatility Index of Umbilical Artery.

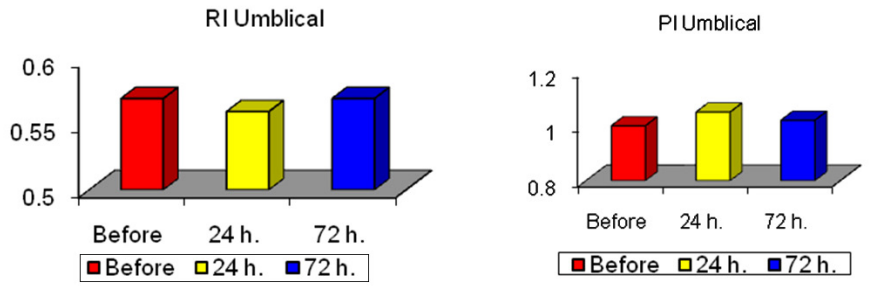

Figure 3: (a) Comparison between Resistive Index of MCA Artery. (b) Comparison between Pulstility Index of MCA Artery.

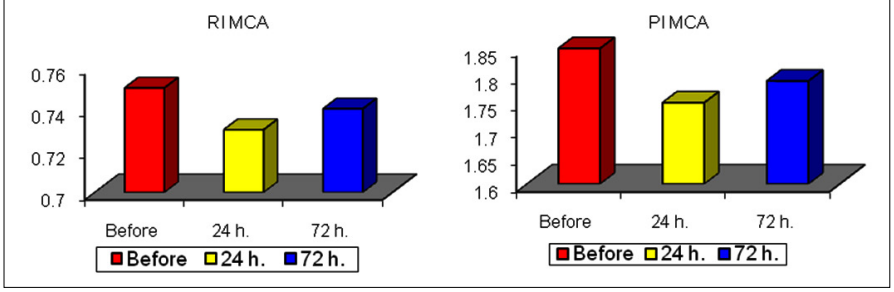

ISSN 2377-1542
http://dx.doi.org/10.17140/GOROJ-4-144

Figure 4: Comparison between RI Umbilical/MCA Ratio.

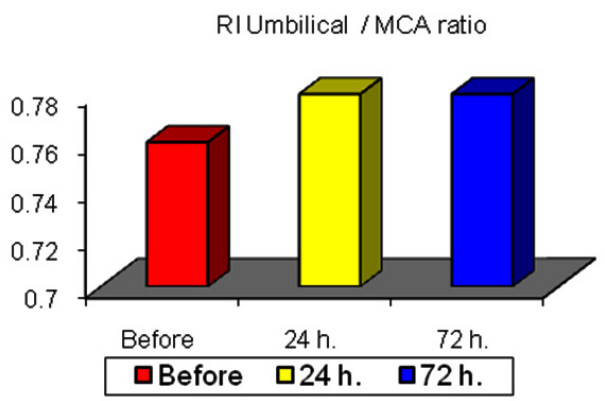

the umbilical arteries Doppler (RI and PI). The cerebroplacental ratio was equally unaffected.

DISCUSSION

Several classes of tocolytic agents are used in the management of threatened preterm delivery. Of these, sympathomimetics and agents such as magnesium and calcium channel blockers are among the most widely studied. In the choice of the appropriate agent, the side effect profile is an important consideration. Nifedipine, as one of the major classes of tocolytic agents by virtue of its effects on calcium channels, has the potential for cardiovascular side effects. We performed this study to concurrently evaluate the effects of oral nifedipine loading for tocolysis on the fetoplacental circulation. Potential effects on placental blood flow dynamics were evaluated by examination of the maternal (UtA) and fetal (UA) compartments. Effects on cerebral blood flow and downstream distribution of cardiac output were evaluated by measurement of the MCA and the cerebroplacental ratio.

Our data showed that nifedipine tocolysis is associated with an increase in the UtA-RI after 24 h of nifedipine administration, with a reduction in RI and PI in the MCA, returning to baseline after 72 h, with no differences in UtA-PI or in the umbilical arteries Doppler (RI and PI) or in the MCA to umbilical artery ratio. Thus, MCA blood flow dynamics and distribution of cardiac output was unaltered. These data suggest that sequential nifedipine is not associated with any maternal and fetal side effects. Although more clinicians are currently considering the use of nifedipine as the first line tocolytic agent, they are often concerned over the theoretical risk of maternal hypotension and placental hypoperfusion.

Grzesiak showed that uterine blood flow patterns were not altered significantly during administration of nifedipine tocolysis.[15]

Studies on similar subjects presented different observations. In contrast to our findings, Guclu et al detected significant fall in uterine artery pulsatility index at 24 and 48 h of tocolysis.[16] Similar to our findings they showed no changes in the blood flow in umbilical artery (RI and PI) at the same point of time.

The present study showed no significant difference in the mean UtA-RI measured after 72 h of using oral nifedipine compared with measurements at 24 h (p=0.462). This is consistent with the study done by Baykal and Avcıoğlu where they did not find any significant difference in Doppler ultrasonography measurements of UtA or between Doppler indices for MCA at 2 h (early phase) and 48 h (late phase) after nifedipine treatment (p>0.05).[17]

Our data showed that nifedipine tocolysis produced no differences in the umbilical arteries Doppler (RI and PI) or in the MCA to umbilical artery ratio, similar to the findings of Karahanoglu et al who found that RI, the PI and the S/D ratio of UA did not change after treatment with nifedipine.[18] Also, de Heus et al showed that over the 5-day study period. The use of tocolytics did not significantly alter the time courses of PI-values for UA (p=0.37).[19]

Whereas, Ulubaşoğlu et al found in cohort study of 65 pregnant women undergoing nifedipine tocolysis, that there was a decrease in the 24 h values of the UA pulsatility index with nifedipine therapy in comparison with the values recorded prior to nifedipine therapy. However, these differences were not statistically significant. There were no statistically significant differences between the data recorded prior to nifedipine administration and those obtained at 48 h and 1 week after treatment.[20]

When comparing the MCA Doppler, it was found that After 24 h of tocolysis with oral nifedipine compared with prior to administration of the drug, there was a significant decrease in the mean RI of the MCA artery (p=0.003). However, there was no significant difference in the mean RI measured after 72 h of using oral nifedipine compared with measurements at 24 (p=0.118). These results agreed with a study done by Lima et al to evaluate Doppler velocimetry who showed alteration of MCA blood flow between 5 and 24 hours from the time of administered medication. Authors suggested that decreased resistance ratio could be related to decrease peak systolic velocity in

ISSN 2377-1542 http://dx.doi.org/10.17140/GOROJ-4-144

MCA.[21] The significant decrease in MCA PI after 24 hours of tocolysis in our study was previously reported by Guclu et al. In such short-term observation no changes in maternal and fetal compartment was observed. We found no statistically significant differences in the MCA to umbilical artery RI ratio (p=0.485), similar to that reported by Guclu et al.[22]

On the other side, While MCA Doppler indices (RI and PI) were unchanged in the study of Grzesiak et al. The evaluation of MCA PSV revealed a transient significant decrease after 24 h. A resolution of this distraction was observed within the following 24 h.[15]

Another study performed by Cornette et al in which 15 healthy normotensive pregnant women with an uncomplicated singleton pregnancy between 35 and 37 weeks was studied. Then, one 10 mg capsule of nifedipine was administered twice with a 20 min interval to assess maternal and fetal hemodynamic effects of nifedipine in normotensive pregnant women. They found that nifedipine had no influence on the uteroplacental and fetal circulations.[23]

Thus oral nifedipine is a safe tocolytic agent with no long-term effect on fetomaternal circulation in pregnant women at risk of preterm delivery as fetal and maternal blood flow dynamics and distribution of cardiac output were unaltered.

CONCLUSION

Nifedipine tocolysis is associated with a reduction in RI and PI in the MCA, and an increase in RI in uterine arteries after 24 h but returning to baseline within 72 h, with no differences in UA-PI or in the umbilical arteries Doppler (RI and PI) or in the MCA to umbilical artery ratio.

ACKNOWLEDGMENT

Authors are grateful to all women agreed to participate in this study.

CONFLICTS OF INTEREST

No conflicts of interest exists in relation to this manuscript.

DISCLOSURE

All authors were contributed significantly and are responsible for the content of this manuscript.

REFERENCES

1. Dodd JM, Crowther CA. The role of progesterone in prevention of preterm birth. *Int J Womens Health*. 2010; 1: 73.

2. Beck S, Wojdyla D, Say L, et al. The worldwide incidence of preterm birth: A systematic review of maternal mortality and morbidity. *Bull World Health Organ*. 2010; 88(1): 31-38.

3. Serenius F, Ewald U, Farooqi A, et al. Neurodevelopmental outcomes among extremely preterm infants 6.5 years after active perinatal care in Sweden. *JAMA Pediatr*. 2016; 170(10): 954-996. doi: 10.1001/jamapediatrics.2016.1210

4. Monaghan C, Binder J, Thilaganathan B, Morales-Roselló J, Khalil A. Perinatal loss at term: The role of uteroplacental and fetal doppler assessment. *Ultrasound Obstet Gynecol*. 2017. doi: 10.1002/uog.17500

5. Spong CY. Prediction and prevention of recurrent spontaneous preterm birth. *Obstet Gynecol.* 2007; 110: 405-415. doi: 10.1097/01.AOG.0000275287.08520.4a

6. Romero R. Prevention of spontaneous preterm birth: The role of sonographic cervical length in identifying patients who may benefit from progesterone treatment. *Ultrasound Obstet Gynecol.* 2007; 30: 675-686. doi: 10.1002/uog.5174

7. King JF, Flenady VJ, Papatsonis DN, Dekker GA, Carbonne B. Calcium channel blockers for inhibiting preterm labour. *Cochrane Database Syst Rev.* 2003; 1: CD002255. doi: 10.1002/14651858.CD002255

8. American College of Obstetricians and Gynecologists; Committee on Practice Bulletins—Obstetrics. ACOG practice bulletin no. 127: Management of preterm labor. *Obstet Gynecolgy*. 2012; 119: 1308-1317. doi: 10.1097/AOG.0b013e31825af2f0

9. King JF, Flenady VJ, Papatsonis DN, Dekker GA, Carbonne B. Calcium channel blockers for inhibiting preterm labour. *Cochrane Database Syst Rev*. 2003. doi: 10.1002/14651858.CD002255

10. Kamat S, Veena P, Rani R. Comparison of nifedipine and progesterone for maintenance Tocolysis after arrested preterm labour. *J Obstet Gynaecol*. 2014; 34(4): 322-325. doi: 10.3109/01443615.2013.874407

11. Alfirevic Z, Stampalija T, Gyte GML. Fetal and umbilical Doppler ultrasound in normal pregnancy. *Cochrane Database Syst Rev*. 2015; 15(4): CD001450. doi: 10.1002/14651858.CD001450.pub3

12. Oloyede OA, Iketubosin F. Uterine artery Doppler study in second trimester of pregnancy. *Pan Afr Med J*. 2013; 15: 87. doi: 10.11604/pamj.2013.15.87.2321

13. Patel RM, Rysavy MA, Bell EF, Tyson JE. Survival of infants born at periviable gestational ages. *Clin Perinatol*. 2017; 44(2): 287-303. doi: 10.1016/j.clp.2017.01.009

14. Simhan HN, Caritis SN. Prevention of preterm delivery. *N Engl J Med*. 2007; 357(5): 477-487. doi: 10.1056/nejmra050435

15. Grzesiak M, Ahmed RB, Wilczynski J. 48-hours administra-

ISSN 2377-1542
http://dx.doi.org/10.17140/GOROJ-4-144

tion of nifedipine in spontaneous preterm labor - Doppler blood flow assessment of placental and fetal circulation. *Neuro Endocrinol Lett*. 2013; 34(7): 687-692.

16. Guclu S, Gol M, Saygili U, Demir N, Sezer O, Baschat AA. Nifedipine therapy for preterm labor: Effects on placental, fetal cerebral and atrioventricular Doppler parameters in the first 48 hours. *Ultrasound Obstet Gynecol*. 2006; 27(4): 403-408. doi: 10.1002/uog.2728

17. Baykal BÖ, Avcıoğlu SN. Comparison of effects of nifedipine and ritodrine on maternal and fetal blood flow patterns in preterm labor. *J Turk Ger Gynecol Assoc*. 2015; 16(2): 80-85. doi: 10.5152/jtgga.2015.15156

18. Karahanoglu E, Altinboga O, Akpinar F, et al. Nifedipine increases fetoplacental perfusion. *J Perinat Med*. 2016. doi: 10.1515/jpm-2016-0072

19. de Heus R, Mulder EJ, Derks JB, Visser GH. The effects of the tocolytics atosiban and nifedipine on fetal movements, heart rate and blood flow. *J Matern Fetal Neonatal Med*. 2009; 22(6): 485-490. doi: 10.1080/14767050802702349

20. Lima MM, Souza AS, Diniz C, Porto AM, Amorim MM, Moron AF. Doppler velocimetry of the uterine, umbilical and fetal middle cerebral arteries in pregnant women undergoing tocolysis with oral nifedipine. *Ultrasound Obstet Gynecol*. 2009; 34(3): 311-315. doi: 10.1002/uog.6445

21. Guclu S, Saygili U, Dogan E, Demir N, Baschat AA. The short term effect of nifedipine tocolysis on placental, fetal cerebral and atrioventricular Doppler wave forms. *Ultrasound Obstet Gynecol*. 2004; 24(7): 761-765. doi: 10.1002/uog.1770

22. Ulubaşoğlu H, Özmen Bayar Ü, Kaya C, Ungan B. The effect of nifedipine tocolysis on Doppler indices of the uterine and umbilical arteries. *J Clin Ultrasound*. 2015; 43(5): 322-326. doi: 10.1002/jcu.22252

23. Cornette J, Duvekot JJ, Roos-Hesselink JW, Hop WC, Steegers EA. Maternal and fetal haemodynamic effects of nifedipine in normotensive pregnant women. *Br J Obstet Gynaecol*. 2011; 118(4): 510-540. doi: 10.1111/j.1471-0528.2010.02794.x