

## Research

### \*Corresponding author

**Mithra N. Hegde, BDS, MDS, PhD**  
 Head of the Department  
 Department of Conservative Dentistry  
 and Endodontics  
 A.B. Shetty memorial institute of  
 dental sciences  
 Nitte University, Deralakatte - 575018  
 Mangalore, India  
 Tel. +919845284411  
 E-mail: [mithra\\_hegde@yahoo.co.in](mailto:mithra_hegde@yahoo.co.in)

Volume 2 : Issue 5

Article Ref. #: 1000DOJ2125

### Article History

Received: April 2<sup>nd</sup>, 2016

Accepted: May 11<sup>th</sup>, 2016

Published: May 18<sup>th</sup>, 2016

### Citation

Hegde MN, Malhotra S. Evaluation of golden proportion between maxillary anterior teeth of south indian population. *Dent Open J.* 2016; 2(5): 137-141. doi: [10.17140/DOJ-2-125](https://doi.org/10.17140/DOJ-2-125)

### Copyright

©2016 Hegde MN. This is an open access article distributed under the Creative Commons Attribution 4.0 International License (CC BY 4.0), which permits unrestricted use, distribution, and reproduction in any medium, provided the original work is properly cited.

# Evaluation of Golden Proportion Between Maxillary Anterior Teeth of South Indian Population

**Mithra N. Hegde, BDS, MDS, PhD<sup>\*</sup>; Sakshi Malhotra, BDS**

*A. B. Shetty Memorial Institute of Dental Sciences, Nitte University, Deralakatte, Mangalore, India*

### ABSTRACT

Golden proportion is a proportion frequently present in nature and is considered as a means of achieving harmony in the teeth. It forms an important aspect of aesthetic dentistry as it deals with the restoration of the maxillary anterior teeth in relation to their widths.

**Aim:** The study was conducted to evaluate the presence of golden proportion between the maxillary anterior teeth in south Indian population by examining their widths. The study also aimed to evaluate the existing ratio present in the population

**Materials and Methods:** The study was conducted over a period of two months, March and April, 2014. 200 individuals including 100 male and 100 female patients were selected for the study based on the inclusion and exclusion criteria. The measurements were made using Vernier calliper.

**Result:** Golden proportion was not prevalent in the south Indian population and did not serve as an adequate guideline to be applied to all maxillary anterior teeth.

**Conclusion:** Golden proportion is not a suitable method to correlate the maxillary anterior teeth widths in the south Indian population and cannot be applied as an absolute rule.

**KEYWORDS:** Golden proportion; South Indian; Anterior teeth; Esthetics.

### INTRODUCTION

Anterior aesthetics is of prime importance for all individuals. It is of importance in aesthetic dentistry to replace or restore the anterior teeth in harmony as during a smile it is the facial aspect of these teeth that is visible. Authors have given the ratio of 1:1.618 as a means of achieving aesthetic dental relationships<sup>1-7</sup> This is known as the golden proportion or the divine proportion. It is considered as a cornerstone in the smile designing theory.<sup>3</sup>

Levin had proposed the use of golden proportion to relate the widths of anterior teeth, when seen from the labial aspect. In this, from the frontal aspect the width of the central incisor should be in golden proportion to the width of the lateral incisor and the lateral incisor should be in golden proportion with the canine.<sup>3</sup> He invented a grid to evaluate golden proportion and to apply it in the dentition to achieve appropriate proportions of the teeth.

Golden proportion is a relation which is ideal, perfect, desirable and helps in the evaluation of dominance, symmetry and proportion in the dentition.<sup>1,3,8</sup> Although in every individual having an aesthetic smile this proportion does not exist.<sup>9</sup> Studies have determined its use to be more theoretical and its application is difficult in the dentition.<sup>10-13</sup>

### AIM

The study was aimed at evaluating the proportion between maxillary anterior teeth width in south Indian population.

**MATERIALS AND METHODS**

The study was conducted in the department of Conservative dentistry and endodontics in A.B. Shetty Memorial Institute of Dental Sciences. The study included 200 patients which included 100 male and 100 female patients. The patients for the study were selected based on the inclusion and exclusion criteria.

**Inclusion criteria**

- Patients in the age group of 21-30 were selected
- Patients were to have all their natural teeth
- No History of dental anomalies associated with tooth size and morphology alteration.
- No history of orthodontic treatment

**Exclusion Criteria**

- Teeth having maxillary anterior restorations or history of trauma or maxillofacial surgery.
- Presence of rotation, spacing or crowding.
- Presence of severe dentofacial deformities or obvious asymmetries.

Patients were evaluated under normal clinical set up. Vernier calliper was used to measure the widths of the maxillary anterior teeth: central incisor, lateral incisor and canine. Each measurement was repeated to reduce the error involved and the repetitive value was used for accurate readings.

The width of the central incisor and lateral incisor was measured at the mesio-distal contact point of the teeth. The width of the canine was measure from the mesial contact point to the distal most visible area from the frontal view.

The golden proportion was evaluated by measuring the anterior teeth from the frontal aspect and dividing the measured mesiodistal width of the central incisor, lateral incisor and canine by the measured width of the lateral incisor. The ratio of the central incisor and the lateral incisor is greater than 1 as the central incisor usually appears wider than the lateral incisor. The measurements were made and recorded. The data was statistically analysed using paired t test.

**RESULTS**

Data obtained was statistically analysed using the paired t-test and the data is depicted in Tables 1 and 2, Figures 1 and 2.

Ratio	Ratio of Right Central Incisor to Lateral Incisor	Ratio of Left Central Incisor to Lateral Incisor
1.0	12(6.0%)	11(5.5%)
1.1	47(23.5%)	27(13.5%)
1.2	79(39.5%)	82(41%)
1.3	41(20.5%)	56(28%)
1.4	12(6.0%)	24(12%)
1.5	9(4.5%)	0
1.6	0	0
1.7	0	0
1.8	0	0
1.9	0	0
2.0	0	0
Total	200(100%)	200(100%)
Median Ratio	1.18(1.12-1.26)	1.23(1.15-1.29)

**Table 1:** Median Ratio of the right and left central incisors.

		Mean (SD)	t(df) <sup>#</sup>	p value
With of central incisor	Right	8.91(0.31)	3.84(199)	<0.05*
	Left	9.01(0.44)		
Width of lateral incisor	Right	7.45(0.61)	2.07(199)	0.03*
	Left	7.36(0.51)		
Width of canine	Right	4.73(0.61)	3.24(199)	0.001*
	Left	4.87(0.66)		

<sup>#</sup>paired t test  
\*p<0.05 statistically significant

**Table 2:** The width of central incisor, lateral incisor and canine with standard deviation.

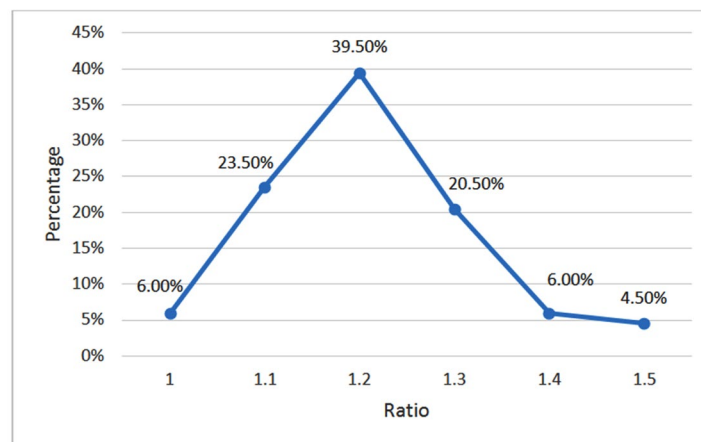


Figure 1: Depicting the Ratio of Right Central Incisor to lateral Incisor: 1.18.

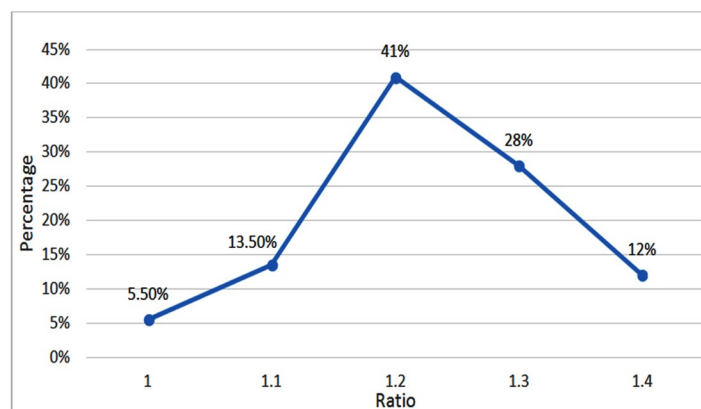


Figure 2: Depicting the Ratio of Left Central Incisor to Lateral Incisor: 1.2.

The study showed that golden proportion was not prevalent in the south Indian population. The ratio present in relation to central incisor and lateral incisor on left and right side was 1.23 and 1.18 respectively.

## DISCUSSION

Golden proportion in dentistry mathematically determines the ratio between a larger and shorter length with the larger length equivalent to phi.<sup>14</sup> It is present in nature and has been commonly associated with fields such as art, architecture, science and philosophy. Golden proportion was based on the concept that it is essential to obtain a mathematical or geometrical relationship in the teeth to deliver an aesthetic restorative result.

Although, each individual is unique and the application of a generalised relationship is not accurate. In the present study golden proportion was not seen to be present in the south Indian population. This was in accordance with the studies conducted by George and Bhat, Minoomashid et al and Fayyad MA et al.<sup>13-15</sup> They concluded that golden proportion was not present in the natural dentition. Snow had recommended the application of golden proportion in diagnosis and development of various aesthetic factors such as dominance, proportion and symmetry.

This is contradictory to the present study.

Ward had determined that the ratio central and lateral incisors and that between lateral incisor and canine is not a constant which is similar to the present study.<sup>16</sup> A study was done to evaluate the presence of golden proportion in the Kashmiri population. This study also concluded that golden proportion was not an appropriate method to relate the successive widths of the maxillary anterior teeth in the Kashmiri population.<sup>17</sup>

Lombardi had recommended the use of repeated ratio instead of golden proportion.<sup>18</sup> Preston had determined that only 17% of the population in his study showed the presence of golden proportion in the widths of maxillary central and lateral incisors.<sup>9</sup> He determined that golden proportion did not exist between maxillary lateral incisors and canines. Gillen and colleagues had found low relation between the tooth widths and the golden proportion.<sup>19</sup>

Levin<sup>3</sup> was the first researcher to emphasize the application and advantages of the golden proportion. This provided an ideal template for the widths of the maxillary anterior teeth. However, the grid used by him was not accurate enough to permit proportions such as those in Preston's study.<sup>9</sup>

Levin's concept is not in use in present day dentistry.

A median ration of 1.18 and 1.23 was observed in the widths of the right and left central incisors to lateral incisors respectively in the present study. Several researchers have concluded that golden proportion is more theoretical, artistic and difficult in application in their study on the maxillary anterior widths<sup>20-28</sup> Further in aesthetic dentistry, macroesthetic factors play a predominant role rather than factors such as golden proportion which is a microesthetic factor.<sup>29</sup>

## CONCLUSION

The golden proportion was not prevalent in the south Indian population and is not an accurate means of obtaining aesthetic outcomes in all individuals. A median ration of 1.18 and 1.23 was observed in the widths of the right and left central incisors to lateral incisors respectively in the present study.

## CONFLICTS OF INTEREST

Dr. Hegde has nothing to disclose.

## REFERENCES

- Ricketts RE. The biologic significance of the divine proportion. *Am J Orthod.* 1982; 81: 351-370. doi: [10.1016/0002-9416\(82\)90073-2](https://doi.org/10.1016/0002-9416(82)90073-2)
- Ricketts RM. The divine proportion in facial esthetics. *Clin Plast Surg.* 1982; 9: 401-422. Web site. <http://europepmc.org/abstract/med/7172592>. Accessed April 1, 2016
- Levin EL. Dental esthetics and the golden proportion. *J Prosthet Dent.* 1978; 40: 244-252. doi: [10.1016/0022-3913\(78\)90028-8](https://doi.org/10.1016/0022-3913(78)90028-8)
- Rufenacht CR. *Fundamentals of esthetics.* Berlin, Germany: Quintessence; 1990.
- Shoemaker WA Jr, Nestor J. A time to recognize the science in the art of healing. *Florida Dent J.* 1981; 52: 22-23.
- Shoemaker WA Jr. How to take the guesswork out of dental esthetics and function. *Florida Dent J.* 1987; 58(4): 25-26.
- Huntley HE. *The divine proportion.* New York, USA: Dover Publications; 1970.
- Snow SR. Esthetic smile analysis of maxillary anterior tooth width: the golden percentage. *J Esthet Dent.* 1999; 11(4): 177-184. doi: [10.1111/j.1708-8240.1999.tb00397.x](https://doi.org/10.1111/j.1708-8240.1999.tb00397.x)
- Preston JD. The golden proportion revisited. *J Esthet Den.* 1993; 5(6): 247-251. doi: [10.1111/j.1708-8240.1993.tb00788.x](https://doi.org/10.1111/j.1708-8240.1993.tb00788.x)
- Mizumoto Y, Deguchi T Sr, Fong KW. Assessment of facial golden proportions among young Japanese women. *Am J Orthod Dento facial Orthop.* 2009; 136(2): 168-174. doi: [10.1016/j.ajodo.2007.07.029](https://doi.org/10.1016/j.ajodo.2007.07.029)
- Murthy BV, Ramani N. Evaluation of natural smile: Golden proportion, RED or Golden percentage. *J Conserv Dent.* 2008; 11(1): 16-21. doi: [10.4103/0972-0707.43413](https://doi.org/10.4103/0972-0707.43413)
- Bukhary SM, Gill DS, Tredwin CJ, Moles DR. The influence of varying maxillary lateral incisor dimensions on perceived smile aesthetics. *Br Dent J.* 2007; 203(12): 687-693. doi: [10.1038/bdj.2007.1110](https://doi.org/10.1038/bdj.2007.1110)
- Fayyad MA, Jamani KD, Agrabawi J. Geometric and mathematical proportions and their relations to maxillary anterior teeth. *J Contemp Dent Pract.* 2006; 7(5): 62-70. Web site. <http://www.4everlearning.com/pdfs/geometricproportions.pdf>. Accessed April 1, 2016
- George S, Bhat V. Inner canthal distance and golden proportion as predictors of maxillary central incisor width in south Indian population. *Indian J Dent Res.* 2010; 21(4): 491-495. doi: [10.4103/0970-9290.74214](https://doi.org/10.4103/0970-9290.74214)
- Mashid M, Khoshvaghti A, Varshosaz M, Vallei N. Evaluation of "golden proportion" in individuals with an esthetic smile. *J EsthetRestor Dent.* 2004; 16(3): 185-192. doi: [10.1111/j.1708-8240.2004.tb00032.x](https://doi.org/10.1111/j.1708-8240.2004.tb00032.x)
- Ward DH. Proportional smile design using the recurring dental (RED) proportion. *Dent Clin North AM.* 2001; 45(1): 143-154. Web site. <http://europepmc.org/abstract/med/11210692>. Accessed April 1, 2016
- Naqash TA, Bali SK. Evaluation of golden proportion between maxillary anterior teeth in Kashmiri population. *Int j clin cases investig.* 2013; 3(2): 3-7. Web site. <http://www.ijcci.info/issue-index/volume-5-issue-2/206-original-research/287-evaluation-of-golden-proportion-between-maxillary-anterior-teeth-in-kashmiri-population-?showall=1>. Accessed April 1, 2016
- Lombardi RE. The principles of visual perception and their clinical application to denture esthetics. *J Prosthet Dent.* 1973; 29(4): 358-382. doi: [10.1016/S0022-3913\(73\)80013-7](https://doi.org/10.1016/S0022-3913(73)80013-7)
- Gillen RJ, Schwartz RS, Hilton TJ, et al. An analysis of selected normative tooth proportion. *Int J Prosthodont.* 1994; 7(5): 410-417.
- Rosenstiel SF, Ward DH, Rashid RG. Dentists' preferences of anterior tooth proportion-a web-based study. *J Prosthodont.* 2000; 9(3): 123-136. doi: [10.1053/jopr.2000.19987](https://doi.org/10.1053/jopr.2000.19987)
- Javaheri DS, Shahnavaz S. Utilizing the concept of the

golden proportion. *Dent Today*. 2002; 21(6): 96-101.

22. Jahanbin A, Basafa M, Alizadeh Y. Evaluation of the Divine Proportion in the facial profile of young females. *Indian J Dent Res*. 2008; 19(4): 292-296. Web site. <http://www.ijdr.in/article.asp?issn=0970-9290;year=2008;volume=19;issue=4;spage=292;epage=296;aulast=Jahanbin>. Accessed April 1, 2016

23. Decker JD. The divine proportion. *Am J Orthod Dento facial Orthop*. 2004; 126: 19A-20A.

24. Sarver DM, Ackerman MB. Dynamic smile visualization and quantification: Part 2. Smile analysis and treatment strategies. *Am J Orthod Dento facial Orthop*. 2003; 124(2): 116-127. doi: [10.1016/S0889-5406\(03\)00307-X](https://doi.org/10.1016/S0889-5406(03)00307-X)

25. Marquardt SR. Marquardt on the Golden Decagon and human facial beauty. Interview by Dr. Gottlieb. *J Clin Orthod*. 2002; 36: 339-347.

26. Howells DJ, Shaw WC. The validity and reliability of ratings of dental and facial attractiveness for epidemiologic use. *Am J Orthod*. 1985; 88(5): 402-408. doi: [10.1016/0002-9416\(85\)90067-3](https://doi.org/10.1016/0002-9416(85)90067-3)

27. Amoric M. The golden number: applications to cranio-facial evaluation. *Funct Orthod*. 1995; 12(1): 18-21. Web site. <http://europepmc.org/abstract/med/8613109>. Accessed April 1, 2016

28. Phillips C, Trentini CJ, Douvartzidis N. The effect of treatment on facial attractiveness. *J Oral Maxillofac Surg*. 1992; 50(6): 590-594. doi: [10.1016/0278-2391\(92\)90439-7](https://doi.org/10.1016/0278-2391(92)90439-7)

29. Hasanreisoglu U, Berksun S, Aras K, Arslan I. An analysis of maxillary anterior teeth: facial and dental proportions. *J Prosthet Dent*. 2005; 94(6): 530-538. doi: [10.1016/j.prosdent.2005.10.007](https://doi.org/10.1016/j.prosdent.2005.10.007)