

## Mini Review

### \*Corresponding author

**Syed Fayyaz Hussain, MBChB, MD, FRCP**

Consultant Respiratory Physician  
Department of Respiratory Medicine  
Kettering General Hospital NHS  
Foundation Trust

Rothwell Road, Kettering  
Northamptonshire  
NN16 8UZ, UK

E-mail: [syed.hussain@kgh.nhs.uk](mailto:syed.hussain@kgh.nhs.uk);  
[syed-fayyaz.hussain@nhs.net](mailto:syed-fayyaz.hussain@nhs.net)

Volume 1 : Issue 3

Article Ref. #: 1000EMOJ1112

### Article History

Received: May 16<sup>th</sup>, 2015

Accepted: July 2<sup>nd</sup>, 2015

Published: July 6<sup>th</sup>, 2015

### Citation

Sandoo VW, Ward T, Hussain SF. Evaluation and initial management of pulmonary embolism during pregnancy and the puerperium. *Emerg Med Open J.* 2015; 1(3): 72-76. doi: [10.17140/EMOJ-1-112](https://doi.org/10.17140/EMOJ-1-112)

### Copyright

©2015 Hussain SF. This is an open access article distributed under the Creative Commons Attribution 4.0 International License (CC BY 4.0), which permits unrestricted use, distribution, and reproduction in any medium, provided the original work is properly cited.

# Evaluation and Initial Management of Pulmonary Embolism during Pregnancy and the Puerperium

**Vikas Waqaas Sandoo, MBChB, BSc & MSc<sup>1</sup>, Thomas Ward, MBChB & BSc<sup>1</sup> and Syed Fayyaz Hussain, MBChB, MD & FRCP<sup>2\*</sup>**

<sup>1</sup>Academic Foundation Year 2 Doctor, Kettering General Hospital NHS Foundation Trust, Rothwell Road, Kettering, Northamptonshire, NN16 8UZ, UK

<sup>2</sup>Consultant Respiratory Physician, Kettering General Hospital NHS Foundation Trust, Rothwell Road, Kettering, Northamptonshire, NN16 8UZ, UK

### ABSTRACT

There is an increased risk of venous thromboembolism during pregnancy. The increased risk begins in the first trimester and remains until six weeks postpartum. This paper provides an update on diagnosing and managing pulmonary embolism in pregnancy. Initial workup includes a clinical assessment, baseline blood test, electrocardiogram and a chest radiograph. D-dimer test is not recommended during pregnancy and puerperium. Doppler ultrasound of lower limb is recommended in the presence of a clinical suspicion of deep vein thrombosis. Definitive diagnosis of pulmonary embolism is established with radiological imaging. The preferred imaging modality is isotope perfusion scan with a normal chest radiograph and computed tomographic pulmonary angiography if chest radiograph is abnormal. Therapeutic low molecular weight heparin is the anticoagulant of choice during pregnancy. Warfarin is contraindicated during pregnancy but can be used postpartum. Duration of therapy is at least three months and should continue for six weeks postpartum. An algorithm for diagnosis and management is suggested.

**KEYWORDS:** Pulmonary embolism; Pregnancy; Puerperium.

### INTRODUCTION

The prevalence of Venous thromboembolism (VTE) is 4 to 10 times higher in pregnancy than age matched non-pregnant women.<sup>1</sup> The increased risk of VTE extends from the first trimester until six weeks postpartum.<sup>2</sup>

In developed countries, Pulmonary Embolism (PE) is a leading cause of maternal mortality.<sup>2</sup> Between 2006-2008, 261 women in the UK died directly or indirectly related to pregnancy. The overall maternal mortality rate was 11.39 per 100,000 maternities. Direct deaths decreased from 6.24 per 100,000 maternities in 2003-2005 to 4.67 per 100,000 maternities in 2006-2008 (p=0.02) confidential enquiries into Maternal Death in the UK 'Saving Mothers' Lives', recorded 18 deaths (rate per 100,000 maternities 0.79, 95% Confidence Interval (CI) 0.49-1.25) due to VTE over a 3-year period from 2006 to 2008.<sup>3</sup> Recent review of confidential enquiries into maternal deaths and morbidity 2009-2012 confirmed that VTE remains the leading cause of maternal deaths, with 26 deaths between 2010 and 2012 (rate 1.08, 95% CI 0.71-1.59).<sup>4</sup>

Assessment of a pregnant female with suspected PE is challenging for the front line medical staff. Diagnostic imaging required to confirm or exclude PE is associated with radiation risk to mother and foetus. Missed diagnosis is associated with a high risk of mortality with loss of two lives. A good knowledge of pathophysiological changes in pregnancy, risks and

benefits of investigations at each stage of assessment, when to seek specialist advice and working in partnership with the patient will help individualise assessment and treatment options.

## PATHOPHYSIOLOGY

Pregnancy is a prothrombotic state. Physiological changes occur during pregnancy, notably an increase in plasma coagulation factors, fibrinogen and *Von Willebrand* factor, all of which disrupt the normal homeostatic balance. One retrospective cohort study<sup>5</sup> reported a previous history of thrombosis as being the most significant individual risk factor for VTE. Another recent cohort study showed 17-fold higher risk of VTE during hospital admission not related to delivery, with highest risk in third trimester, remaining significantly higher up to 28 days post-discharge.<sup>6</sup> The risk was highest for women staying three or more days but a fourfold increased risk persisted for hospital stays of less than three days. Risk factors for VTE are summarised in Table 1.

Patient related	Pregnancy related
Previous episode of VTE	Hyperemesis
Obesity (Body mass index >30)	Multiple pregnancy
Age >35 years	Ovarian Hyperstimulation Syndrome
Antiphospholipid syndrome	Surgery / instrumentation
Family history of VTE*	Major postpartum bleed (>1 litre)
Medical co-morbidity**	Parity ≥3

VTE in first-degree relatives (spontaneous or associated with contraceptive use or pregnancy).  
\*\*Medical conditions such as diabetes, sickle cell anaemia, nephritic syndrome, acute inflammatory states and heart or lung disease.

Table 1: Patient and pregnancy related risk factors for venous thromboembolism.

## CLINICAL PRESENTATION

Signs and symptoms such as breathlessness and leg swelling are associated with late pregnancy and may mimic those of VTE. Other presenting symptoms include chest pain, palpitations, haemoptysis, dizziness or syncope. Tachycardia and tachypnoea may be the only abnormal findings on examination. Hypotension and syncope are seen with massive PE. Pregnancy associated deep vein thrombosis predominantly occurs in the left leg.<sup>7</sup>

## INITIAL ASSESSMENT

The initial evaluation aims to assess the risk of PE, exclude alternate diagnoses and develop a patient-centred management plan.

Use of pre-test probability assessment score is not recommended, as it is not evidence based. Reports suggest that a negative D-dimer may be able to rule out PE in many pregnant patients by using pre-test probability score and age-based adjustment threshold of positive D-Dimer level.<sup>8</sup> However, guidelines do not recommend D-dimer since there is a high false positive rate (80-100%) from second trimester onwards and a negative

test cannot always exclude VTE.<sup>9</sup>

Baseline blood tests include full blood count, coagulation screen, renal function and liver function. Mild to modest elevation of inflammatory markers (neutrophil count and C-reactive protein) can be seen with venous thromboembolism and not necessarily indicate an infection.

Chest radiograph with appropriate shielding poses negligible risk to the foetus at any stage of pregnancy and should be performed in all cases of suspected PE to exclude alternate diagnoses (e.g. pneumonia, pneumothorax). It is likely to be normal in most patients with acute PE but may show features suggestive of PE (atelectasis, effusion, oligemic lung fields or decreased vascular markings).

ECG usually shows sinus tachycardia. Large PE may lead to right bundle branch block, right axis deviation, p pulmonale (tall P waves in lead II) or S1Q3T3 pattern (may also be seen in normal pregnancy). An urgent bedside echocardiogram showing right ventricular dilatation and dysfunction is suggestive of massive PE.

Arterial blood gas analysis may show low partial pressure of oxygen (PaO<sub>2</sub>) with normal or low partial pressure of carbon dioxide (PaCO<sub>2</sub>). Alveolar arterial (A-a) gradient reflects the difference between alveolar and arterial oxygen concentration and is increased in PE (normal value under 2 kPa or 15 mm Hg for young adults). A-a gradient can be calculated using a simplified formula

$$A-a \text{ gradient} = (FiO_2 - [PaCO_2 \times 1.2]) - PaO_2$$

(FiO<sub>2</sub> is fraction of inspired O<sub>2</sub> that is 21% on room air)

Thrombophilia screen and lupus anticoagulant are not recommended before commencing anticoagulant therapy as the information will not influence immediate management and results are affected by both pregnancy and acute thrombosis.

## DIAGNOSIS

Baseline investigations cannot confirm the diagnosis of PE. Suspicion of PE should prompt senior review to determine the need and choice of diagnostic imaging and to initiate anticoagulant therapy. Diagnostic imaging should be performed the same day or within 24 hours to determine the need for continued anticoagulant therapy.

Until recently, bilateral Doppler ultrasound of the legs was the recommended initial imaging study for suspected PE as it posed no radiation risk and may detect silent Deep Vein Thrombosis (DVT). It is rarely positive in the absence of clinical signs of DVT and may delay further diagnostic imaging. Recent guidelines recommend Doppler ultrasound only in presence of

signs and symptoms of DVT.<sup>10,11</sup>

Choice of imaging then varies between isotopes perfusion scan and CT Pulmonary Angiogram (CTPA); opinions and availability vary. Discussion with radiologists is crucial to select the best imaging protocol for each patient.

Isotope perfusion scanning is recommended when the chest radiograph is normal since the likelihood of an underlying lung disease is low in young patients. Isotope perfusion scan is part of the traditional V/Q scan however the ventilation component is omitted and the perfusion scan performed with half the dose of isotope to minimise radiation. Isotope perfusion scan has a high negative predictive value and a negative scan excludes significant PE. Limitations of Isotope perfusion scan include lack of availability out of hours and need for CTPA when indeterminate.

CTPA is preferred when the chest radiograph is abnormal or isotope scan is not available. An abnormal CXR should prompt senior review to ascertain an alternate diagnosis. CTPA cannot be performed in patients with renal impairment and contrast allergy. Iodinated contrast used in CTPA can potentially affect neonatal thyroid with a need to check thyroid function in neonates. Another limitation of CTPA is related to the increased cardiac output during pregnancy, which may lead to non-diagnostic examination due to contrast dilution and poor opacification of the pulmonary arteries. CTPA may show an alternate cause of symptoms but in these cases chest radiograph may be sufficient to establish an alternate diagnosis.

There is understandable anxiety among physicians and patients about risk of radiation to mother and foetus. When possible, the patient should be involved in decision-making and informed written consent taken before the procedure. CTPA delivers higher dose of radiation to the mother in particular to the breast tissue. This would be of concern in very young women and those with a strong family history of breast cancer. The lifetime risk of breast cancer in women of reproductive age is 0.5% (1 in 200) and following CTPA has an estimated lifetime risk of 0.6% (1 in 175), an increase in relative risk of 13.6%.<sup>12</sup> Compared to CTPA, Isotope scan delivers higher doses of radiation to the foetus. Following exposure during pregnancy, the risk of cancer to the child up to the age of 15 is estimated at 1 in 280,000 after isotope scan compared to less than 1 in million after CTPA.

## MANAGEMENT

Current clinical guidelines agree the need to initiate empiric anticoagulation with Low Molecular Weight Heparin (LMWH) when clinical suspicion of PE is high. Both LMWH and unfractionated heparin do not cross the placenta but LMWH is the preferred choice. LMWH is easier to administer, considered more effective and associated with lower risks of side effects such as heparin induced thrombocytopenia and osteopo-

rosis. There is increased renal clearance and protein binding of LMWH and a higher daily dose in twice daily administration has traditionally been recommended for enoxaparin and dalteparin. Recent studies suggest once daily dose may be adequate (Table 2). Tinzaparin can be given 175 units/kg once daily. Danaparoid is an acceptable alternative to patients who develop adverse reactions to LMWH.<sup>13</sup> Novel oral anticoagulants (NOACs) are not recommended during pregnancy and puerperium.

Booking weight	Enoxaparin	Dalteparin
<50 kg	40 mg twice daily or 60 mg once daily	5,000 iu twice daily or 10,000 iu once daily
50-69 kg	60 mg twice daily or 90 mg once daily	6,000 iu twice daily or 12,000 iu once daily
70-89 kg	80 mg twice daily or 120 mg once daily	8,000 iu twice daily or 16,000 iu once daily
90-109 kg	100 mg twice daily or 150 mg once daily	10,000 iu twice daily or 20,000 iu once daily
110-125 kg	120 mg twice daily or 180 mg once daily	12,000 iu twice daily or 24,000 iu once daily
>125 kg	Discuss with haematologist	Discuss with haematologist

Table 2: Initial daily dose of LMWH during pregnancy.<sup>9</sup>

The need for monitoring heparin therapy with peak anti-Xa activity should be discussed with a haematologist. Monitoring is recommended for under-weight (<50 kg) and over-weight (>90 kg) patients, recurrent VTE or other complicating comorbid medical conditions such as impaired renal function.

Warfarin is contraindicated during pregnancy as it crosses the placenta. It is associated with an increased risk of characteristic embryopathy in the first trimester, central nervous system abnormalities during any trimester, maternal and foetal haemorrhage, miscarriage and stillbirth.

Heparin and Warfarin are safe to use in the postpartum period, neither is excreted in breast milk. Patients should be offered a choice between LMWH and Warfarin, as LMWH does not require regular monitoring.

Anticoagulation therapy should be continued for the duration of pregnancy and six weeks post partum with a minimum total duration of 3 months. Longer duration of anticoagulation is required for women suffering from recurrent VTE, antiphospholipid syndrome or thrombophilia. We recommend that anticoagulant therapy during pregnancy and thereafter should be under the supervision of a haematologist (Table 3).

An algorithm for the diagnosis and initial management of PE during pregnancy and puerperium is shown in Figure 1.

## RECOMMENDATIONS FOR FURTHER RESEARCH

- Reliable strategies to rule out PE during pregnancy minimising the need for diagnostic imaging.

Study	Overview	Evaluation
Saving mothers lives <sup>3,4</sup>	<ul style="list-style-type: none"> <li>Overall a statistically significant decrease in the maternal death rate between 2006-2008 and 2009-2012 in the UK.</li> <li>VTE remains a leading cause of direct maternal death.</li> </ul>	<ul style="list-style-type: none"> <li>Longest running programme of confidential enquiries into maternal deaths worldwide</li> <li>Each woman's care examined by between ten and fifteen expert reviewers</li> </ul>
American thoracic Society/Society of Thoracic Radiology clinical practice guideline <sup>10</sup>	<ul style="list-style-type: none"> <li>D-dimer not to be used to exclude PE in pregnancy</li> <li>Bilateral venous ultrasound if DVT suspected</li> <li>CXR recommended as the first radiation associated procedure</li> <li>Lung V/Q scan is the preferred test in the setting of normal CXR</li> <li>CTPA is advised with abnormal CXR or non-diagnostic V/Q scan</li> </ul>	<ul style="list-style-type: none"> <li>Multi-disciplinary panel of experts reviewed the available evidence</li> <li>The majority of the studies used for this guideline, were off a low level of evidence. Much of the studies were conducted on patients from the general population.</li> <li>However all members of the expert panel agreed with the strong recommendations devised</li> </ul>
Royal College of Obstetricians and Gynaecologists guidelines <sup>11</sup>	<ul style="list-style-type: none"> <li>D-dimer test not recommended in pregnancy</li> <li>Doppler ultrasound only if DVT suspected</li> <li>Ventilation perfusion scan or CTPA to objectively confirm PE</li> <li>Treat with LMWH until VTE excluded</li> <li>Neither LMWH nor warfarin contraindicated in breastfeeding.</li> </ul>	<ul style="list-style-type: none"> <li>Randomized controlled trials, systematic reviews and meta-analyses from 2006–2013 reviewed</li> <li>Lack of level 1 evidence in pregnant population, most data comes from non-pregnant patients.</li> <li>Recommendations mostly extrapolated from studies in non-pregnant patients.</li> </ul>

DVT= Deep Vein Thrombosis; CTPA= Computed-tomographic pulmonary angiography; LMWH= Low Molecular Weight Heparin; PE= Pulmonary Embolism; V/Q scan= Ventilation/perfusion scan; VTE= Venous thromboembolism.

Table 3: Overview and evaluation of the literature.

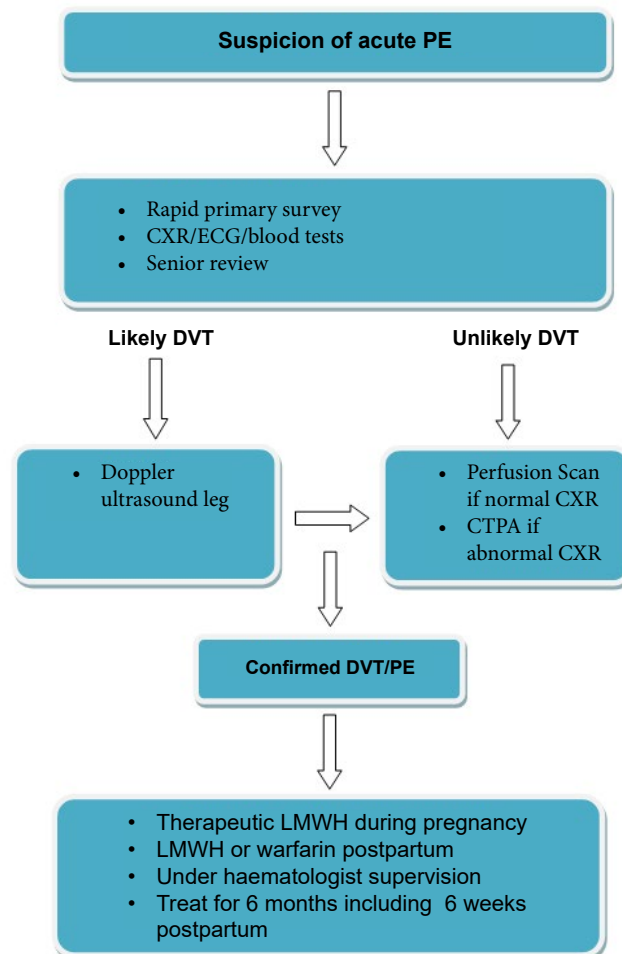


Figure 1: Diagnosis and management of acute pulmonary embolism (PE) during pregnancy and the puerperium.

- Feasibility and safety of ambulatory care management of suspected PE in pregnancy.
- Effectiveness of newer diagnostic imaging techniques that minimise radiation risk in pregnancy.
- Optimising and monitoring of anticoagulant therapy in pregnancy.
- Longitudinal studies to assess the risk of radiation during pregnancy.

**KEY POINTS**

- Risk for venous thromboembolism is increased during pregnancy and puerperium.
- Baseline blood tests, ECG and chest radiograph are insufficient to establish a diagnosis of PE.
- Clinical suspicion of PE requires diagnostic imaging with Isotope perfusion scan or CT pulmonary angiogram; both are associated with radiation risk.
- During pregnancy LMWH is the anticoagulant of choice as warfarin is contraindicated.

**CONFLICTS OF INTEREST**

The authors declare no conflicts of interest with this submission.

**ACKNOWLEDGEMENT**

We wish to thank Dr. Steve Peterson, Consultant Radiologist, Kettering General Hospital for expert review of the manuscript.

**REFERENCES**

1. Pomp ER, Lenselink AM, Rosendaal FR, Doggen CJM. Pregnancy, the postpartum period and prothrombotic defects: risk of venous thrombosis in the MEGA study. *J Thromb Haemost.* 2008; 6: 632-637. doi: [10.1111/j.1538-7836.2008.02921.x](https://doi.org/10.1111/j.1538-7836.2008.02921.x)
2. Heit JA, Kobbervig CE, James AH, Petterson TM, Bailey KR, Melton LJ 3rd. Trends in the incidence of venous thromboembolism during pregnancy or postpartum: a 30-year population-based study. *Ann Intern Med.* 2005; 143: 697-706. doi: [10.7326/0003-4819-143-10-200511150-00006](https://doi.org/10.7326/0003-4819-143-10-200511150-00006)
3. Cantwell, R. *et al.* Saving mothers' lives: reviewing maternal deaths to make motherhood safer: 2006-2008. The eighth report of the confidential enquiries into maternal deaths in the United Kingdom. *BJOG.* 2011; 1-203. doi: [10.1111/j.1471-0528.2010.02847.x](https://doi.org/10.1111/j.1471-0528.2010.02847.x)
4. Knight M, Kenyon S, Brocklehurst P, Neilson J, Shakespeare J, Kurinczuk JJ. on behalf of MBRRACE- UK. Saving lives, improving mothers' care - lessons learned to inform future maternity care from the UK and Ireland confidential enquiries into maternal deaths and morbidity 2009-12. Oxford: National Perinatal Epidemiology Unit, University of Oxford, 2014.
5. De Stefano V, Martinelli I, Rossi E, et al. The risk of recurrent venous thromboembolism in pregnancy and puerperium without antithrombotic prophylaxis. *Br J Haematol.* 2006; 135: 386-391. doi: [10.1111/j.1365-2141.2006.06317.x](https://doi.org/10.1111/j.1365-2141.2006.06317.x)
6. Sultan AA, West J, Tata LJ, Fleming KM, Nelson-Piercy C, Grainge MJ. Risk of first venous thromboembolism in pregnant women in hospital: population based cohort study from England. *BMJ.* 2013; 347: f6099. doi: [10.1136/bmj.f6099](https://doi.org/10.1136/bmj.f6099)
7. Ray JG, Chan WS. Deep vein thrombosis during pregnancy and the puerperium: a meta-analysis of the period of risk and the leg of presentation. *Obstet Gynecol Surv.* 1999; 54: 265-271.
8. Kline JA, Kabrhel C. Emergency evaluation for pulmonary embolism, Part 2: Diagnostic Approach. *J Emerg Med.* 2015; 49(1): 104-117. doi: [10.1016/j.jemermed.2014.12.041](https://doi.org/10.1016/j.jemermed.2014.12.041)
9. Damodaram M, Kaladindi M, Luckit J, Yoong W. D-dimers as a screening test for venous thromboembolism in pregnancy: is it of any use? *J Obstet Gynaecol.* 2009; 29(2): 101-113. doi: [10.1080/01443610802649045](https://doi.org/10.1080/01443610802649045)
10. Leung AN, Bull TM, Jaeschke R. An official American Thoracic Society/Society of Thoracic Radiology clinical practice guideline: evaluation of suspected pulmonary embolism in pregnancy. *Am J Respir Crit Care Med.* 2011; 184: 1200-1208. doi: [10.1164/rccm.201108-1575ST](https://doi.org/10.1164/rccm.201108-1575ST)
11. Royal College of Obstetricians and Gynaecologists. Thromboembolic disease in pregnancy and the puerperium. Acute management. *Green-top Guideline No. 37b* 2015.
12. Shahir K, Goodman LR, Tali A, Thorsen KM, Hellman RS. Pulmonary embolism in pregnancy: CT pulmonary angiography versus perfusion scanning. *Am J Roentgenol.* 2010; 195: W214-W220. doi: [10.2214/AJR.09.3506](https://doi.org/10.2214/AJR.09.3506)
13. Magnani HN. An analysis of clinical outcomes of 91 pregnancies in 83 women treated with danaparoid (Orgaran). *Thromb Res.* 2010; 125: 297-302. doi: [10.1016/j.thromres.2009.06.006](https://doi.org/10.1016/j.thromres.2009.06.006)