Openventio PUBLISHERS

ISSN 2379-4046

EMERGENCY MEDICINE

Open Journal

December 2020. Volume 6, Issue 1

www.openventio.org

ISSN 2379-4046

EMERGENCY MEDICINE
Open Journal

Openventio PUBLISHERS

CONTENTS

ISSN 2379-4046

EMERGENCY MEDICINE

Open Journal

Openventio PUBLISHERS

Opinion

Wound Care and Healthcare

Lydia A. Corum, RN, MSN, CWCN*

Wound Care Program Director

***Corresponding author**
Lydia A. Corum, RN, MSN, CWCN
Wound Care Program Director; E-mail: lydia.meyers317@gmail.com

Article information
Received: June 2nd, 2020; **Revised:** August 10th, 2020; **Accepted:** August 13th, 2020; **Published:** September 2nd, 2020

Cite this article
Corum LA. Wound care and healthcare. *Emerg Med Open J.* 2020; 6(1): 1-2. doi: 10.17140/EMOJ-6-154

A case was reported in the wake of stepping on a sharp nail in a board where the patient was given a Tetanus shot and sent home with advice to apply triple antibiotic cream twice a day and wrapping the injury with gauze along with oral antibiotics. The patient was suggested to soak his foot in Dakin's Solution..

The patient returns after 2 weeks to the emergency room (ER), limping and not bearing weight on the injured foot. The patient states that he had been doing the dressing changes and noted the area was becoming odorous. He was unable to walk on the foot or get his boots on for work. The foot was swollen and odorous with an enormous amount of discharge from the wound. The foot was soaked in Dakins by the staff. The surgeon was called and the ulcer was examined. Upon instruction, an magnetic resonance imaging (MRI), culture, labs, intravenous (IV) antibiotics, and admission, with surgery scheduled for in AM. The patient was found to be diabetic. Aware of this the surgeon and the internist assigned to the case, continue the work on to include a cardiologist and vascular surgeon. . Amputation was performed which led to a major change in the patient's life. The patient failed to return to his previous occupation and could not support his family.

Prior to the coronavirus disease 2019 (COVID-19) virus, admission to hospital for wound care patients takes place every day. This practice changed drastically after COVID-19 despite the focus of the hospital to take care of patients that needed care. The COVID-19 virus caused an increased number of deaths, severe health conditions, and many were at the risk of acquiring the COVID-19 virus. Many wound care patients lacked care. The hospitals were confused about choosing to close the wound clinics due to the lack of personnel resources and lack of patient visits.[1] The wound care community could not allow this situation to continue. The fear that wound patients would face an increase in infections, decrease in healing, or increase in amputation rates. The community looked for ways to change the system and wound clinics reopened to a new world.[2] There still remain many problems for the future of wound care. This paper highlights what has caused the problems, how the new normal will help the present, and what needs to happen in the future.

Health care has been facing challenges for many years. From the time of the depression become known to the days when it was found a need for Medicaid. This country has seen a need to provide healthcare for all. Our system is not a healthy one, compared to care in other countries. We are numbered with the cost of healthcare per person in the company with the quality of care.[3] The COVID-19 virus only has brought to light many problems and the ways to continue to move this country forward.[4] Changes are usually difficult. Many in the healthcare community are less appreciative of this change. The COVID-19 virus has started the change and a strong leader needs to push it forward. Leaders in the healthcare system will have the vision to move the system forward. Seeing the big picture, bringing those important people with them, and pushing the system forward.[3]

Some leaders are pushing for universal care, as used in other countries. This system is based on the population working as ours is. This can be a good system or not. The answer to our problems is not to use others, but to refine our system. To just throw away and scrap does not make sense. There are many times and many cases of abuse in the system. Changing the abuses will help improve care and push forward more funds.[2]

As healthcare continues to face a major crisis, the wound care community faces its first drastic change. When the epidemic and lockdown hit the US, wound care was pushed to being a non-essential part of healthcare. This increased the hardship of many patients with wounds and ulcers as they cannot find a resource for healing. Seeing life as being locked in a house suffering long days of being unable to be around others. The odor, pain, itch, leakage, and increased chance of infection, have locked these patients into their home.[5] The closing of wound clinics would be devastating

to the wound care community. Many patients go through a wound clinic in a single day, and that includes the use of hyperbaric oxygen therapy (HBOT). Many clinics are healing wounds of the patients. To have the ability to access to the clinics is drastically important.[6] The ER would do their best to serve their patients that relieve future visits and helps to assure the patients are getting the treatment that they need. This will reduce hospital costs and financial costs.

The new normal with wound care was static for many years. The government was more focused on the other diagnoses. However, there was no focus on what was happening in wound care. Wound Clinics are needed to help with patient retention, increased patient satisfaction, and increased outpatient revenue. What COVID- 19 has changed to become the new normal is Telemedicine, decreased visits in the wound clinic, and different rules for home health care. Telemedicine is to help assess wounds without making visits.[7] Allowing patients to be admitted into home healthcare, even if the patient is not homebound. More patients are able to have oversight of the wound progression and if the patient needs to be seen before the next appointment. The decrease in the number of clinic visits and how patients are seen in the clinic allows more time between visits, fewer patients seen in the clinic, and short wait times.[6] This would increase the need for more wound clinics and increase the need for more rooms. There is a need for hand sanitizer, with masks for all entering the clinic, how patients are seen, what is available in the clinic, and how staff enters the room. The changes happening is only the beginning of what needs to happen with the coming future.[8]

The focus of future wound care will need to be on patient satisfaction, quality, and financial stewardship. This new world is being monitored by central monitoring system (CMS) and the audits being performed.[9] With the present situation, many hospitals are looking at how to handle wound care patients, surgical debridements, and keeping patients from being admitted to the hospital.[6] The concern of many wound care clinicians is to reduce the risk of infections. Many are scheduling surgical debridements as outpatient, and outpatient surgical centers. Those patients admitted with wounds and ulcers are seen by a team of clinicians. This minimizes the chances of exposure to bacteria and viruses. Rules of home healthcare are being lifted so that many patients, who are not homebound can be helped by the nurses coming to assess. Telemedicine is being used to interact with those wound clinicians who have the expertise and understanding from the homes of patients with wounds. This could be the future of wound care or many may come up with better ideas with time.[6]

The future of wound care depends on many factors now and in the future. The treatment of the new viruses are not over. Also, there is a need to monitor people with ulcers and wounds. There will be better monitoring and care as time goes on. These need to be thoughtful, long-term with proper planning in the future. The plan to help with controlling financial stewardship will be the main focus. The focus of continuing quality of care, patient satisfaction, and financial stewardship. Evidence-based care needs to be the focus and wound care clinicians must continue to seek education, seminars, and conferences. More ideas should be acquired as well as new lessons. One should never stop listening, learning and becoming better.

REFERENCES

1. Lazarevski L. Wound Care During COVID-19. woundsource Web site. www.woundsource.com/blog/wound-care-during-covid-19. Accessed June 1, 2020.

2. Harriet J. Considerations and recommendations regarding the COVID-19 virus for wound centers. *Today's Wound Clinic.* 2020; 14(4): 18-21.

3. Jane G. *Practical Guide to Qualitative Healthcare.* Indiana, USA: Author Solutions; 2015.

4. Kurani N, McDermott D. How Does the U.S. Healthcare System Compared to Other Countries?. ealthsystemtracker Web site. https://www.healthsystemtracker.org/chart-collection/quality-u-s-healthcare-system-compare-countries/. Accessed June 1, 2020.

5. Sharon B, Ayello EA. *Wound Care Essentials: Practice Principles.* South Holland, Netherlands: Wolters Kluwer; 2016.

6. Samuel NT, Collins N. Avoiding unintended consequences for the complex wound patient in the fight against COVID-19. *Today's Wound Clinic.* 2020; 14(4): 26-29.

7. Rogers LC, Armstrong DG, Capotorto J, Fife CE, Garcia JR, Gelly H, et al. Wound center without walls: The new model of providing care during the COVID-19 pandemic. *Wounds.* 2020; 32 (7).

8. Workman WT. A closer look at hyperbaric safety and training. *Today's Wound Clinic.* 2020; 14(5): 22-23.

9. Knicole E. Update on medicare/medicaid audits in the wake of COVID-19. *Today's Wound Clinic.* 2020; 14(5): 24-27.

ISSN 2379-4046

EMERGENCY MEDICINE
Open Journal

Openventio PUBLISHERS

Case Report

Electrical Injury and Prolonged Cardiac Arrest: A Case Report of Complete Neurological Recovery

Uma Hariharan, MBBS, DNB, PGDHM, CCEPC, FICA, MNAMS, DESA[1*];Vinoth Natarajan,MBBS, MD[2]

[1]*Anaesthesiology, Dr. Ram Manohar Lohia Hospital and Atal Bihari Vajpayee Institute of Medical Sciences-PGIMER, New Delhi, India*
[2]*Anaesthesiology and Intensive Care, MGM Health Care, Chennai, Tamil Nadu, India*

[*]***Corresponding author***
Uma Hariharan, MBBS, DNB, PGDHM, CCEPC, FICA, MNAMS, DESA
Associate Professor, Anaesthesiology, Dr Ram Manohar Lohia Hospital and Atal Bihari Vajpayee Institute of Medical Sciences-PGIMER, New Delhi, India;
E-mail: uma1708@gmail.com

Article information
Received: August 29th, 2020; **Accepted:** Ocotober 14th, 2020 ; **Published:** October 17th, 2020

Cite this article
Hariharan U, Natarajan V. Electrical injury and prolonged cardiac arrest: A case report of complete neurological recovery. *Emerg Med Open J.* 2020; 6(1): 3-5.
doi: 10.17140/EMOJ-6-155

ABSTRACT

Introduction
Sudden cardiac arrest continues to have a high mortality rate. Out of hospital cardiac arrest (OHCA) has a poor outcome compared to those occurring in a healthcare setup due to lack of awareness and appropriate resources. The most common rhythm abnormality in OHCA is ventricular fibrillation which requires early defibrillation, ideally on the location.

Case Report
A 19-years male was witnessed by lay bystanders to have become unresponsive following contact with an electric lighting pole on the road median in Chandigarh. A passer-by medical resident detected no pulse and initiated chest compression. Since there was no immediate return of spontaneous circulation and aetiology suggested a defibrillate rhythm. The patient was taken in the car and rushed to a tertiary care centre, 10-minutes away. Cardiopulmonary resuscitation (CPR) was interrupted during transport for lack of adequate personnel. Ventricular fibrillation was noted and shock was delivered along with inotropes. Around 26-minutes into the resuscitation, the patient had the return of spontaneous circulation. After post-cardiac arrest care in intensive care unit (ICU), he was extubated and discharged home in 1-week with full neurological recovery.

Discussion
Recovery of full neurologic function could be explained by the alternating presence of stable and unstable cardiac rhythms and in part at least brought about by immediate attempts at resuscitation. The report seeks to review these aspects of emergency care besides highlighting the need for both immediate and accurate emergency medical services such as lay responder training, public access defibrillation and responsive transport systems for such patients.

Keywords
Sudden cardiac arrest; Out of hospital cardiac arrest; Ventricular fibrillation; Early defibrillation; Electrical injury.

INTRODUCTION

Survival from the out of the hospital cardiac arrest is less than 15% and it is even very low in developing nations. Out of hospital cardiac arrest (OHCA) has poor outcome compared to those occurring in a healthcare setup due to lack of awareness and appropriate resources. The most common rhythm abnormality in out of hospital cardiac arrest is ventricular fibrillation which requires early defibrillation, ideally on the location.[1] We described here a case of a young adult male who sustained electrical shock injury while crossing the road, followed by cardiac arrest which was revived by prolonged effective cardiopulmonary resuscitation (CPR) resulting in a complete neurological recovery.

CASE DESCRIPTION

A 19-years male was witnessed by lay bystanders to have become unresponsive following contact with an electric lighting pole on the road median. A passer-by medical resident detected no pulse and initiated chest compressions. The patient was immediately

rushed to the nearest hospital and CPR was continued during the transport. Patient was received in Emergency Department and current American College of Cardiology/American Heart Association (ACC/AHA) Advanced Cardiac Life Support (ACLS) PROTOCOLS were followed. Ventricular fibrillation was noted on rhythm assessment and direct-current (DC) shock of 200 J was delivered, followed by continuation of CPR. By this time, Airway was secured with endotracheal tube of appropriate size. After 4 boluses of adrenaline, Amiodorane 150 mg infusion and also 4 times of DC shock, the patient had the return of spontaneous circulation around 26-minutes into the resuscitation. Then, noradrenaline and adrenaline infusions were started and the patient was shifted to the intensive care unit (ICU). Patient was connected to mechanical ventilation in ICU, central line and arterial line were secured. Mild acidosis was present in arterial blood gas and correction was given. All basic investigations and echocardiography were taken and founds to be normal for this patient. Then patient was gradually weaned off from the ventilator, extubated and shifted to ward. And also he was discharged home within 1-week with full neurological recovery. On follow-up after 15-days in Out-Patient-Department (OPD), he was perfectly normal with mild generalised bodyache only for which he was prescribed some analgesics too.

DISCUSSION

Electrical shock injuries cause a wide range of injuries from nil damage to serious life-threatening conditions like sudden death, depending upon the voltage and the duration of the current passing through the body. The response of cardiac muscle to electroshock results in loss of its function and leads to fibrillation. Ventricular fibrillation is the most common rhythm disturbance following the electric shock injury.[2] Most of the cardiac arrests are reverted back to the normal rhythm if the resuscitation efforts started within 10-minutes. After that, there will be the decrease in the perfusion of vital organs resulting in the serious consequences. But in our case, even though proper resuscitative efforts were started nearly after 12-minutes, the patient had the complete neurological recovery at the time of discharge. Emergency Medical Service personnel and ambulances were not available immediately and hence the patient was taken to nearest hospital by bystander medical resident. Cervical stabilization and chest compressions had not been maintained properly during transportation due to lack of adequate personnel. Wik et al[3] in 2003 suggested to give a prime importance to early defibrillation than chest compressions but however recent study done by Hyuang et al[4] in 2014 gave equal importance to both chest compression and defibrillation for the out of hospital cardiac arrest cases. And also, recent ACLS update 2015 also emphasizes that whenever automatic external defibrillator (AED) is immediately available, defibrillation should be given as soon as possible for witnessed cardiac arrest. If it is not available, then it is reasonable to initiate chest compressions until the defibrillator equipment is being retrieved and applied. But in this case, defibrillation was given once after we had reached the hospital which was approximately 16-minutes from cardiac arrest scenario. Add-ons such as hypothermia had not been given to this patient which is contrary to the mild therapeutic hypothermia requirement at the post-return of spontaneous circulation (ROSC) status suggested by Puri et al.[5] A recent high quality study compared temperature management at 36 °C and at 33 °C and found outcome to be similar for both.[6] Recovery of full neurologic function in this case could be explained by the alternating presence of stable and unstable cardiac rhythms of the victim and in part at least brought about by immediate attempts at resuscitation. Other reasons could be young age, witnessed arrest, proximity to hospital, lack of traffic with good road and also the people familiar with the hospital. This report envisages the importance of early chest compressions initiated by medical student on witnessing a cardiac arrest victim and also depicts the usefulness of providing early sophisticated treatment like defibrillation. Automated external defibrillators are the one which provides the effective treatment to the out of the hospital cardiac arrest victim and installation of it in common public gathering places would prevent the unwanted deaths of such victims. Many developed nations have included the installation of automated external defibrillators in common places in their laws itself. Further efforts in this direction are needed in developing nations like India.

CONCLUSION

Patient's sustained cardiac arrests following electrical injury are readily covered without any neurological deficits if sophisticated treatment is administered at the earliest possible time with good post-resuscitative care. Installing the automated external defibrillators in common places should be carried out effectively and also the training programmes for the special group of people how to use it properly should also be started to reduce the incidence of unwanted deaths from out of the hospital reach cardiac arrests.

SOURCE OF FUNDING

Nil

CONSENT

Written informed consent was taken from the patient for reporting this critical event and successful management.

CONFLICTS OF INTEREST

The authors declare that they have no conflicts of interest.

REFERENCES

1. Fröhlich GM, Lyon RM, Sasson C, Crake T, Whitbread M, Indermuehle A, et al. Out-of-hospital cardiac arrest-optimal management. *Curr Cardiol Rev*. 2013; 9: 316-324. doi: 10.2174/1573403x10666140214121152

2. Ahmad M, Shabbir K. Electrical shock survival after prolonged cardiopulmonary resuscitation. *J Coll Physicians Surg Pak*. 2013; 23: 502-503.

3. Wik L, Hansen TB, Fylling F, Steen T, Vaagenes P, Auestad BH,

et al. Delaying defibrillation to give basic cardiopulmonary resuscitation to patients with out-of-hospital ventricular fibrillation: A randomized trial. *JAMA*. 2003; 289: 1389-1395. doi: 10.1001/jama.289.11.1389

4. Huang Y, He Q, Yang LJ, Liu GJ, Jones A. Cardiopulmonary resuscitation (CPR) plus delayed defibrillation versus immediate defibrillation for out-of-hospital cardiac arrest. *Cochrane Database Syst Rev*. 2014; 2014(9): CD009803. doi: 10.1002/14651858.CD009803.pub2

5. Puri GD, Shyam KS, Mishra AK, Madhavan JS. Complete neurological recovery after delayed onset resuscitation in a normothermic witnessed arrest. *Perfusion*. 2013; 28: 253-235. doi: 10.1177/0267659112469550

6. Nielsen N, Wetterslev J, Cronberg T, Erlinge D, Gasche Y, Hassager C, et al. Targeted temperature management at 33°C versus 36°C after cardiac arrest. *N Engl J Med*. 2013; 369: 2197-2206. doi: 10.1056/NEJMoa1310519

ISSN 2379-4046

EMERGENCY MEDICINE
Open Journal

Openventio PUBLISHERS

Mini Review

Nebulized Tranexamic Acid for Hemoptysis

Veerle Leenaerts, MD*

Internal Medicine Resident at AZ Klina, Antwerp Metropolitan Area, Belgium

***Corresponding author**
Veerle Leenaerts, MD
Internal Medicine Resident at AZ Klina, Antwerp Metropolitan Area, Belgium; E-mail: Veerle.Leenaerts2@klina.be

Article information
Received: November 9th, 2020; **Revised:** November 28th, 2020; **Accepted:** December 1st, 2020 ; **Published:** December 1st, 2020

Cite this article
Leenaerts V. Nebulized tranexamic acid for hemoptysis. *Emerg Med Open J.* 2020; 6(1): 6-8. doi: 10.17140/EMOJ-6-156

ABSTRACT

The synthetic antifibrinolytic drug, tranexamic acid, is widely used intravenously, orally and topically to treat various bleeding complications. In recent years, there has been increasing evidence of its use as inhalation drug for hemoptysis. In this review, the available literature about aerosolized tranexamic acid is listed.

BACKGROUND

Hemoptysis is a common symptom in the emergency department.[1] It is defined as the expectoration of blood originating from the tracheobronchial tree or lung parenchyma.[1,2] It is a symptom of diverse respiratory diseases such as lung cancer, infections and vasculitis.[1,3,4] The severity can vary, ranging from immediate life-threatening hemorrhage to minimal blood-streaked sputum.[3] Treatment options are diverse and mostly based on the underling disease, for example radiotherapy for bronchial carcinoma, immunosuppressives for vasculitis or antibiotics for infections.[3,4] For massive hemoptysis, interventional procedures such as angiographic bronchial artery embolization and various endobronchial interventions are used.[1,3,5]

Tranexamic acid is a cheap, synthetic drug with anti-fibrinolytic activity based on inhibiting the activation of plasminogen.[3] It is especially used intravenously, orally and topically to prevent and treat various bleeding complications, but only a few studies have investigated the effect of tranexamic acid as an inhalation drug for hemoptysis.[2] In this review, the available literature about aerosolized tranexamic acid for both massive and non-massive hemoptysis is listed.

MASSIVE HEMOPTYSIS

Massive hemoptysis is defined as hemoptysis that is more than 200 milliliters in 24-hours or hemoptysis that cause respiratory or hemodynamic instability.[3] Review of the literature about the use of inhaled tranexamic acid for massive hemoptysis showed there are only case reports and case series available (Table 1). All cases except one demonstrated at least improvement and often resolution of the bleeding after administration of nebulized tranexamic acid in patients of very different ages with varying underlying etiologies of the massive hemoptysis. There were no adverse events reported.[2,4-10]

NON-MASSIVE HEMOPTYSIS

Non-massive hemoptysis is defined as hemoptysis less than 200 milliliters in 24-hours without respiratory of hemodynamic instability.[3] Table 2 shows the available literature about nebulized tranexamic acid in non-massive hemoptysis. Calvo et al[11] showed in a case series of 4 males with moderate hemoptysis due to lung cancer or bronchiectasis that bleeding stopped after inhalation of tranexamic acid. One patient experienced bronchoconstriction as side effect which easily resolved after administration of a bronchodilator. In a randomized controlled trial of Wand et al[3] 47 adults with non-massive hemoptysis of various underlying etiologies were randomized for getting nebulized tranexamic acid or nebulized normal saline. In the tranexamic acid group, the bleeding was stopped more frequently at day 5 and there was a shorter hospital stay than in the normal saline group. Moreover there was no need for invasive procedures in the tranexamic acid group while 18.2% of patients required angiography or bronchoscopy in the normal saline group.

DISCUSSION

There are some case reports and case series about the use of nebulized tranexamic acid in massive hemoptysis. Most showed improvement or even resolution of the bleeding after administration.[2,4-10] Caution is needed since there is a high-risk of reporting bias as negative results are not often published. For non-

Table 1. *Publications Regarding Inhaled Tranexamic for Massive Hemoptysis*

Authors	Study Design	Study Population	Intervention	Results
Solomonov et al[5]	Case series with 6 cases	Middle aged men and women with massive hemoptysis due to lung cancer (2), other types of cancer (3) or trombopenia (1)	500 mg tranexamic acid dissolved in water, sodium hydroxide or hydrochloric acid administered 3-4 x/day via inhalation (4) or *via* the bronchoscope (2). The duration of the therapy varied from one single dose up to 3-months	In all cases, the bleeding stopped with the first dose of tranexamic acid. No adverse events.
Hankerson et al[6]	Case report	46-years-old man with massive hemoptysis *via* tracheostomy tube due to lung cancer	Inhalation of 1000 mg tranexamic acid dissolved in 100 ml normal saline over 30-45-minutes	Bleeding stopped 15-minutes after administration
Patel et al[7]	Case series with 2 cases	One 75-years-old woman with massive hemoptysis due to bronchiectasis and one 79-years-old man with hemoptysis due to thrombocytopenia and chronic obstructive lung disease	500 mg nebulized tranexamic acid every 8-hours for a minimum of 48-hours	The bleeding stopped without other interventions.
Bernardo et al[8]	Case series with 11 cases	Eleven children aged 0-18-year with pulmonary hemorrhage, mostly due to congenital heart disease, renal failure, malignancy and liver failure. All but one patient was intubated.	Inhalation of 250-500 mg tranexamic acid every 6-12-hours	Improvement of bleeding after 1 dose in all patients except 1. No adverse events.
Komura et al[2]	Case report	69-years-old woman with massive hemoptysis post-chemotherapy for lung cancer on rivaroxaban. No effect of nebulized epinephrine.	Nebulization of 1000 mg tranexamic acid in 20 ml of normal saline	Bleeding stopped 10-minutes after tranexamic acid. No recurrence of bleeding.
Ng et al[9]	Case report	30-years-old man with massive hemoptysis due to pulmonary tuberculosis. Bronchoscopy, angiography and intravenous tranexamic acid had failed.	48-hours of nebulized tranexamic acid (dose not mentioned in article)	Bleeding stopped after 48-hours
Modi et al[4]	Case report	70-years-old woman with massive hemoptysis due to microscopic polyangiitis.	Inhaled tranexamic acid (dose not mentioned in article) in combination with pulse steroids	Bleeding stopped after first dose of tranexamic acid
Alabdrabalnabi et al[10]	Case series with 3 cases	Three 14-66-years-old females with massive hemoptysis due to systemic lupus, vasculitis or anticoagulation. Two of them got intravenous tranexamic acid without resolution of bleeding.	Inhaled tranexamic acid 500 mg 3 x/day	Improvement in bleeding in all cases.

Table 2. *Publications Regarding Inhaled Tranexamic for Non-Massive Hemoptysis*

Authors	Study Design	Study Population	Intervention	Results
Calvo et al[11]	Case series	Four males, 58-84y old with moderate hemoptysis due to bronchiectasis (1) or lung cancer (3)	250-500 mg nebulized tranexamic acid 2-3x/day over 15 minutes	Bleeding stopped after 6-48 hours. One patient had bronchoconstriction as side effect, resolved after administration of a bronchodilator.
Wand et al[3]	Randomized controlled trial	47 adult patients with non-massive hemoptysis of various etiologies	Intervention: 500 mg nebulized tranexamic acid 2x/d Placebo: nebulized normal saline	More frequent resolution of hemoptysis within 5 days in the intervention group. No need to interventional procedures in the intervention group. Shorter hospital stay in the intervention group.

massive hemoptysis there is 1 randomized controlled trail which showed beneficial effect of inhalation of tranexamic acid on bleeding time, need for invasive procedures and length of hospital stay.[3] There is no ideal dosing known for aerosolized tranexamic acid. Moreover there are no comparative studies between intravenous, oral and nebulized tranexamic acid for hemoptysis. Further research with high quality randomized controlled trials is needed. In the meantime, nebulized tranexamic acid should be considered for patients with both massive and non-massive hemoptysis since there is some evidence, it is cheap and there are little side effects.

CONCLUSION

There is some evidence for the use of nebulized tranexamic acid in both massive and non-massive hemoptysis of various underlying causes. The only reported side effect is bronchoconstriction, easily resolved with administration of a bronchodilator. Therefore, aerosolized tranexamic acid must be considered. Further research is needed.

REFERENCES

1. Larici AR, Franchi P, Occhipinti M, Contegiacomo A, del Ciello A, Calandriello L, et al. Diagnosis and management of hemoptysis. *Diagn Interv Radiol.* 2014; 20: 299-309. doi: 10.5152/dir.2014.13426

2. Komura S, Rodriguez RM, Peabody CR. Hemoptysis? Try inhaled tranexamic acid. *J Emerg Med.* 2018; 54(5): e97-e99. doi: 10.1016/j.jemermed.2018.01.029

3. Wand O, Guber E, Guber A, Shochet GE, Israeli-Shani L, Shritrit D. Inhaled tranexamic acid for hemoptysis treatment. A randomized controlled trial. *Chest.* 2018; 154(6): 1379-1384. doi: 10.1016/j.chest.2018.09.026

4. Modi R, Chu A. Inhaled tranexamic acid in vasculitis-induced massive hemoptysis. *Chest.* 2019; 156(4): A1315. doi: 10.1016/j.

chest.2019.08.1179

5. Solomonov A, Fruchter O, Zuckerman T, Brenner B, Yigla M. Pulmonary hemorrhage: A novel mode of therapy. *Respir Med.* 2009; 103(8): 1196-2000. doi: 10.1016/j.rmed.2009.02.004

6. Hankerson MJ, Raffetto B, Mallon WK, Shoenberger JM. Nebulized tranexamic acid as a noninvasive therapy for cancer-related hemoptysis. *J Palliat Med.* 2015; 18(12): 1060-1062. doi: 10.1089/jpm.2015.0167

7. Patel M, Abbas F, Sheppard T. Hemoptysis controlled with the use of inhaled tranexamic acid: A case series. *Crit Care Med.* 2016; 44(12S): 1887.

8. Bernardo E, Anders M, Schmees L, Resendiz K. Inhaled tranexamic acid for pulmonary hemorrhage in critically ill pediatric patients. *Crit Care Med.* 2018; 47(1S): 1202.

9. Ng BH, Faisal AH, Soo CI, Andrea YL. Inhaled tranexamic acid: an alternative treatment for active hemoptysis. *Chest.* 2019; 155(4S): 74A. doi: 10.1016/j.chest.2019.02.348

10. Alabdrabalnabi F, Alshahrani M, Ismail N. Nebulized tranexamic acid for recurring hemoptysis in critically ill patients: Case series. *Int J Emerg Med.* 2020; 13(1): 45. doi: 10.1186/s12245-020-00304-x

11. Calvo GS, De Grande-Orive I, Padilla DL. Inhaled tranexamic acid as an alternative for hemoptysis treatment. *Chest.* 2016; 149(2): 604. doi: 10.1016/j.chest.2015.10.016

ISSN 2379-4046

EMERGENCY MEDICINE
Open Journal

Openventio PUBLISHERS

Case Report

Macroscopic White Blood Cell Casts: An Extremely Rare Presentation of Klebsiella Pyelonephritis

Larry B. Mellick, MD*; Kimberly M. Rathbun, MD

Department of Emergency Medicine, University of South Alabama, USA

***Corresponding author**
Larry B. Mellick, MD
Professor, Division Chief, Department of Emergency Medicine, University of South Alabama, USA; Tel. 706-533-2931;
E-mail: lmellick@health.southalabama.edu

Article information
Received: November 3rd, 2020; **Revised:** December 10th, 2020; **Accepted:** December 17th, 2020 ; **Published:** December 21st, 2020

Cite this article
Mellick LB, Rathbun KM. Macroscopic white blood cell casts: An extremely rare presentation of Klebsiella pyelonephritis. *Emerg Med Open J*. 2020; 6(1): 9-10.
doi: 10.17140/EMOJ-6-157

ABSTRACT

In this case report, we present a patient with severe pyelonephritis who presented complaining of passing worm-like tissue from his penis. This patient was passing macroscopic ureteral white blood cell casts resulting from a severe pyelonephritis caused by *Klebsiella pneumoniae*.

Keywords
Acute pyelonephritis; White blood cell casts; Urinary tract infections; Urinary tract infection (UTI); Ureteral casts.

OVERVIEW

White blood cell casts are extremely rare and only one previous report was found in our non-systematic review of the literature.

CASE REPORT

A 33-year-old previously healthy man presented to the emergency department with a one-week history of painful urination, body aches, fatigue, nausea, vomiting, and chills. On the morning of presentation, he reported passing worm-like "tissue" that "shot out" of his penis following an intense urge to urinate (Figure 1). At presentation, he was afebrile, and his vital signs were within normal limits. His physical examination was remarkable only for tenderness to palpation of the left lower abdominal quadrant and left flank. Urinalysis, urine culture, blood cultures, complete blood count and a computerized tomography (CT) of the abdomen and pelvis were ordered. The specimen was sent for culture and pathologic examination.

Laboratory testing demonstrated a leukocytosis of 20,600 white blood cells/mm^3. The urinalysis was nitrite negative, the leukocyte esterase was reported as "moderate" and the microscopic examination demonstrated too numerous to count white blood cells. The abdominal CT scan documented a severe left pyelonephritis with early intrarenal abscess formation and a suspected ureteral cast protruding into the bladder. The patient's u-

Figure 1. *One of Several Long white Cell Casts Passed Through the Urethra of this Patient*

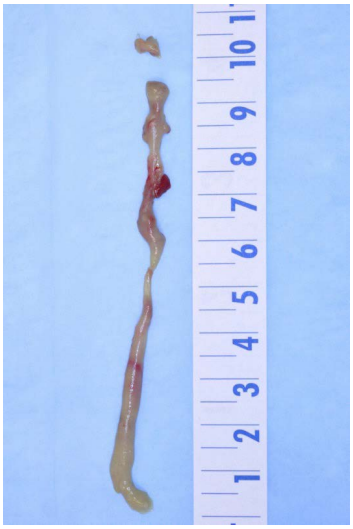

rine culture grew Gram-negative lactose-fermenting bacilli, and one of two blood cultures was positive for *Klebsiella pneumoniae*. A portion of the tissue specimen was sent for culture and grew *Klebsiella pneumoniae*. The pathology report described "*mostly degenerated fibrinopurulent debris with abundant granulocytes, lymphocytes, and histiocytes*". It also reported "*some filamentous organisms and amorphous, refractile material present*". The final pathology assessment was that the material most likely represented a tubular cast formed in the patient's ureter by abundant purulent material secondary to his pyelonephritis. The patient was treated with piperacillin and tazobactam and made a full recovery. Neither the CT scan on admission nor a second CT scan several days later demonstrated any anatomical variations or abnormalities.

DISCUSSION

This case describes a macroscopic ureteral white blood cell cast resulting from a severe pyelonephritis. Urinary tract infections and pyelonephritis, a complicated urinary tract infection, are common maladies treated in the emergency department. A population-based study of acute pyelonephritis in the United States found overall annual pyelonephritis rates (out patient) of 10-13 cases per 10,000 females and 2-3 cases per 10,000 males.[1] While it is common to find microscopic white blood cell casts in the urine of patients diagnosed with pyelonephritis,[2] macroscopic white blood cell casts that form of the ureter in association with pyelonephritis appear to be extremely rare. This is the first report of a macroscopic ureteral white blood cell cast since 1901 when it was first described in the British Medical Journal.[3]

The most frequent cause of acute complicated urinary tract infectionsis *Escherichia coli*. Other uropathogens causing pyelonephritis are Enterobacteriaceae (such as *Klebsiella spp.* and *Proteus spp.*), Pseudomonas, enterococci, and staphylococci (methicillin-sensitive *Staphylococcus aureus* [MSSA] and methicillin-resistant *S. Aureus* [MRSA]).[1] Our patient was previously healthy and had no other known comorbidities or risk factors for a complicated pyelonephritis leading to the more severe disease presentation.

CONCLUSION

While renal corticomedullary abscess, perinephric abscess, emphysematous pyelonephritis, and papillary necrosis are recognized complications of pyelonephritis, the development of large, worm-like white cell casts is extremely rare. In fact, our patient appears to be only the second case of white blood cell casts reported in the literature.

CONSENT

No consent was required for this deidentified case report and single case reports are exempt from institutional review board (IRB) review.

REFERENCES

1. Czaja CA, Scholes D, Hooton TM, Stamm WE. Population-based epidemiologic analysis of acute pyelonephritis. *Clin Infect Dis*. 2007; 45(3): 273-280. doi: 10.1086/519268

2. Ringsrud KM. Casts in the urine sediment. *Lab Med*. 2001; 32(4): 191-193. doi: 10.1309/KJ5E-V5FE-MAHR-KXT2

3. White JA. A case of renal colic attended by the passage of casts of the ureter (Ureteritis Membranacea). *Br Med J*. 1901; 1(2088): 14-15. doi: 10.1136/bmj.1.2088.14-a