

Review

*Corresponding author

David V. Gauvin, PhD

Neurobehavioral Sciences Division
MPI Research, Inc.

54943 North Main Street

Mattawan, MI 49071, USA

Tel. +1 269-668-3336 X 1613

Fax: +1 269-668-4151

E-mail: david.gauvin@mpiresearch.com

Volume 2 : Issue 2

Article Ref. #: 1000OTLOJ2114

Article History

Received: April 7th, 2016

Accepted: May 6th, 2016

Published: May 9th, 2016

Citation

Gauvin DV, Yoder J, Tapp RL, Cole PI. Defining “best practices” for critical endpoints in preclinical screening of new chemical entities for ototoxicity liability. *Otolaryngol Open J.* 2016; 2(2): 58-69. doi: [10.17140/OTLOJ-2-114](https://doi.org/10.17140/OTLOJ-2-114)

Copyright

©2016 Gauvin DV. This is an open access article distributed under the Creative Commons Attribution 4.0 International License (CC BY 4.0), which permits unrestricted use, distribution, and reproduction in any medium, provided the original work is properly cited.

Defining “Best Practices” for Critical Endpoints in Preclinical Screening of New Chemical Entities for Ototoxicity Liability

David V. Gauvin, PhD^{1*}; Joshua Yoder, BS¹; Rachel L. Tapp, BS¹; Phaedra I. Cole, DVM, MS, DACVP²

¹Neurobehavioral Sciences Department, MPI Research, 54943 North Main Street, Mattawan, MI 49071, USA

²Pathology Department, MPI Research, 54943 North Main Street, Mattawan, MI 49071, USA

ABSTRACT

Introduction: Ototoxicity has been defined as the tendency of certain therapeutic agents and other chemical substances to cause functional impairments and cellular degeneration of the tissues of the inner ear resulting in hearing loss.

Objectives: This review is intended to provide details of a standardized preclinical assessment for ototoxicity under the current US FDA guidance documents that represents “industry best practices” for new drug application review of all new chemical entities being developed for human use.

Methods: A literature review was conducted to assimilate study strategies that represent “Industry Best Practices” for the conduct of preclinical ototoxicity evaluation for submission to regulatory drug approval agencies.

Conclusion: We have proposed a systems-approach and protocol criteria for the valid and reliable assessment of auditory function that can be easily included as a screening tool for ototoxicity within the Tiered Structure of preclinical assays required for approval of any chemical entity targeted for human use.

KEYWORDS: Ototoxicity; Auditory Brainstem Response (ABRs); Cytocochleagram; Histopathology; Otic Microscopy; Best practices.

INTRODUCTION

Defining the Problem

There are over 130 drugs or drug combinations that have a known risk liability for auditory dysfunction in humans.¹⁻⁴ In 2001, Palomar Garcia et al conducted a comprehensive literature review through 10 years of peer-reviewed publications to investigate the prevalence of drug-induced ototoxicity.⁵ Cochlear and vestibular hair cell damage can be induced by numerous other factors such as acoustic trauma, aging, blast wave, irradiation, infection, heavy metals, pesticides, herbicides, organic solvents or gene mutations.⁶

There are currently no systematic or regulatory requirements for any standard preclinical studies conducted of new molecular entities (NCEs) that include analysis of all peripheral and central vestibular structures or auditory sensory organs before drug approval. Major obstacles in vestibular and hearing research include post-mortem tissue acquisition as well as neuropathological characterization prior to new drug application submission to the US Food and Drug Administration. Furthermore, inner ear structures are “safely” buried in the hardest bone of the human body and the cochlea and vestibular structures lie in different anatomical planes.^{7,8} Any test article-related toxicity induced in this small compartment containing these critical end organs is rarely discovered during standard preclinical protocols

on the journey to drug approval.

Part of the requisite risk analysis required for NDA review is to first identify the hazard. The objectives of hazard identification are to 1) produce a qualitative understanding of the potential for the system to present a risk (hearing loss, tinnitus, hyperacusis), and then 2) highlight the sources of that risk (cell damage inducing sensorineuronal deafness, or physical damage or inflammation of ossicles inducing conductive hearing loss). Once the hazard has been identified, hazard assessment is conducted. At this stage the aim is to understand and describe the plausible and critical pathways by which the substances reach the targets, the fate of the substance in the environmental media through which they are transported and the characteristics of the targets at risk (for example, apoptosis versus necrosis, secondary inflammatory responses, etc.). And the final step in the process is exposure estimation. For the small compartment of the VIIIth cranial nerve this is a challenge.

Regulatory Perspective

In July, 2001, the US FDA⁷ adopted and provided approval of the ICH S7A Guidelines, titled, "Safety Pharmacology Studies for Human Pharmaceuticals" that were approved in November of 2000 by the regulatory bodies of the European Union, Japan, and USA.⁹ More recently, the FDA published a notice adopting its own guidance titled, "Non clinical Safety Evaluation of Reformulated Drug Products and Products Intended for Administration by an Alternate Route: Guidance for Industry and Review Staff; Good Review Practice".¹⁰ In it and for the first time, this guidance specifically gives details on preclinical toxicology screening for "otic" products which includes auditory brainstem response (ABR) and cytochleogram evaluations. Interestingly, there is no legally defined or administrative policies (regulations) that clearly delineates what constitutes an acceptable ABR evaluation or sets the criteria for the processes, staining techniques, or details (full or partial cell count) of an acceptable cytochleogram.

It's the intent of the drug regulators to allow for Industry to determine best practices. Selection of experimental variables should be based on "best judgment", experience, education, historical control data, and the reliability and validity of the resulting practices. The purpose of this review is to characterize what we believe should be the "industry best practice" with respect to both ABR evaluations, otic histopathology, and cytochleogram parameters that will be the basis for sound and reliable drug safety determination of NCEs during the NDA process.

METHODOLOGIES AND PROCEDURES

Auditory Brainstem Response Evaluations for Regulatory Review

Regulatory agencies require an objective measure of functional

changes in auditory thresholds in intact animals that can be temporally-linked to the magnitude and duration of exposure to NCEs. At least two measures of drug-induced deficits are used in the regulatory risk assessment of auditory toxicology. The degree of change in ABR data should be consistent with the post-life analysis of cellular damage defined using the cytochleograms.

The ABR test produces a short acoustic (sound) stimulus such as a "chip", "tone", "pulse", etc., to the experimental subject and then measures *via* cutaneous electrodes the auditory evoked potentials from the inner ear, the auditory nerve and the brainstem. The test uses an automatic detection algorithm to determine if an ABR is evoked in response to the short acoustic stimulus. The data acquisition of the ABR-recordings takes place from the surface electrodes mounted at specific recording points on the animal. The analogue ABR-recordings are amplified in the external preamplifier connected to the electrodes. The amplified analogue ABR-recordings are converted into a digital signal in the Analog to Digital Converter. The digital ABR-recordings undergo data processing handled by the PC to improve the ABR-recordings. The ABR-recordings are displayed on the monitor for the operator. All ABR-recordings are then stored on the computer hard drive for later examination and diagnosis. The ABR is not a measure of perceptual deafness, only that the transduction of air wave pressure changes to electrical signals by the cochlea, and the transmission of those electrical nerve pulses are transmitted effectively to the brain, the forward progression from cochlea to brain cortex represents the process of normal information processing. The specific wave form frequencies to test are based on convention, laboratory experience, and published reports of auditory sensory ranges for the species being used.

Auditory brainstem response evaluations have been recorded in guinea pigs,^{11,12} mice,¹³⁻¹⁵ rats,¹⁶ cats,¹⁷⁻²⁰ and non-human primates.²¹ The ABR is an electrophysiological recording of transient responses following the onset of a sound stimulus presented to the ear while recording the events using standard EEG scalp electrodes. The recorded EEG voltage changes arise from within or in close proximity to various auditory brain stem nuclei and neural pathways. Psychophysical tuning curves are generated by repeated presentations of a select frequency signal (tone) at varying sound pressure levels (intensity=loudness). A minimum of 500 presentations at each step of frequency and intensity should be averaged for each subject. An evoked response requires an approximate 10 msec window of recording beginning at a sweep time of zero. This allows the AB, which spans approximately 1 to 6 msec to be visualized.

The use of animals to predict ototoxicity is intended to diminish or prevent similar cellular changes induced by drug exposures in an unsuspecting human population prescribed the drug therapeutically. Consistent and relatively more stable recordings can be achieved with the use of needle electrodes, or with chronically implanted, mechanically stabilized electrodes in animals when compared to human recording sessions. Human recordings are generally conducted with the awake patient of one

in natural sleep. As a general rule, animal ABRs are never made with awake animals (except with the use of radio telemetry). Recording ABRs under anesthesia minimizes the undue influence of motor or movement artifacts in the EEG and under anesthesia complex and highly resolved parametric sequences of stimulation can be presented within a single session. Standard purpose-bred laboratory animals provide a smaller absolute head size and concomitant smaller brain, with proportionately thinner bone, muscle, and skin which provide a more favorable situation for recording the electrical impulses elicited by externally presented auditory stimuli. The evoked response detected on the scalp of an anesthetized laboratory animal tends to have larger absolute magnitudes as compared to humans, and there are more favorable signal-to-noise ratios in the signal detection.²² Therefore, the overall gain required in the computer software amplifier system can be reduced and the amount of averaging of the number of stimulus-response pairings required to extract a clear and reliable response is less than that typically required from human subjects.

The brainstem evoked responses should be recorded from a minimum of three scalp electrodes by standard waveform analysis systems. These represent a series of sound volume or intensity-dependent neural potentials which originate and are time-locked or phase-locked to primary auditory pathways from transduction to central mediated information processing nuclei. The recorded and amplified scalp voltage waveforms have an identifiable series of peaks and troughs with latencies of approximately 10 msec from the stimulus onset.

Because neural synchrony is the basic requirement to produce an ABR, tone-burst sounds must be short (usually 4 or 5 cycles long) with relatively fast rise/fall times. The intervals between peaks are approximately 1 msec. For a given experimental subject, the peak latencies for any given stimulus or tone are unchanging over successive trials or recording sessions. Reliable waveforms can be recorded and reproduced over repeated presentations of the identical sound stimulus. There is general agreement that the brainstem response recordings reflect a series of neural events that when averaged and summarized provide 5 distinct peaks and troughs that represent a series of neural codes from the initial transduction of sound energy to electrical energy within the cochlea (Wave 1), the combined output of sensory cell voltage potentials to the cochlear nucleus (Wave II), and further transmission of the neural code to the superior olivary nucleus (Wave III) to areas around and within the inferior colliculus of the brainstem (Waves IV and V).

Since the critical biomarker in toxicity testing is the structural/anatomical changes that can be linked to the duration and magnitude of exposures to an NCE, the selection of Wave I, originating from within the cochlea is the major covariate in the analysis. Wave I of the ABR reflects the graded, generator potential of sensory hair cells within the cochlea. As summarized by Buchwald based on the preponderance of data detailed in published reports appearing in peer-reviewed scientific journals,

Wave I of the ABR is produced by acoustic generator potentials of hair cells within the cochlea of cats,^{17,18,23-26} rats,²⁴ mouse,¹³⁻¹⁵ non-human primate²¹ and guinea pigs.^{11,12}

The middle ear is separated from the outer ear by the tympanic membrane (ear drum). The tympanic membrane is composed of three layers. From inside, the membrane is covered by a mucous membrane formed by the pavement epithelium; in the middle layer there are blood vessels which regulate the degree of the stratum's thickness. The auditory ossicles are a set of bones of tight tolerance connected together by tensor muscles. Changes to the elasticity of the tympanum, inflammation within the middle ear that compromises the muscle tension and close tolerance between the malleus, incus, and stapes that make up the ossicles may produce significant changes in auditory thresholds as measured by the ABR but do not induce any cell injury within the cochlea. Therefore, ABR changes in frequency thresholds may not be definitive evidence of direct cytotoxicity in the cochlea. To differentiate between the ABR threshold shifts due to conductive hearing losses and sensorineuronal cytotoxicity associated with drug administrations, the cytochleogram becomes critical. Such objectively verifiable electrophysiological data can then be compared to the degree of cell injury or cell death verified post-mortem using standardized histopathology of prepared auditory tissues that are the basis of the cytochleogram.

There are a variety of computer-based software programs that can be utilized for the collection, consolidation, and archiving of ABR data for regulatory review. In general, ABR testing of auditory function is conducted with industry-standard processes and systems whose 1) design qualifications have been tested and published in the extant scientific literature, 2) have a long history of factory acceptance testing, and 3) have been engineered to include startup testing and calibration each time the software is engaged. Most systems in use within preclinical testing environments do not fully comply with the FDA's equipment validation process regulations. Therefore, in most institutions, this portion of the ototoxicity study is exempted from compliance to Good Laboratory Practice Guidelines.

The reliability of system integrity, sensitivity and compliance can be assessed within each testing site by demonstrating Test 1 vs. Test 2, or Rater 1 vs. Rater 2 reliabilities of the ABR data sets. Figure 1, below, show comparative evaluations of ABR data from a proof-of-concept comparison scored by a professional, doctoral-degreed, university electrophysiology professor, with a 30-year record of active auditory research that was compared to threshold determinations of well-trained undergraduate ABR technicians assessing the relative auditory thresholds of three different frequencies in guinea pigs using industry standard software computer systems.

These data demonstrate the comparative auditory thresholds determined by ABR evaluations conducted by a qualified, industry expert-in-the field with three decades of

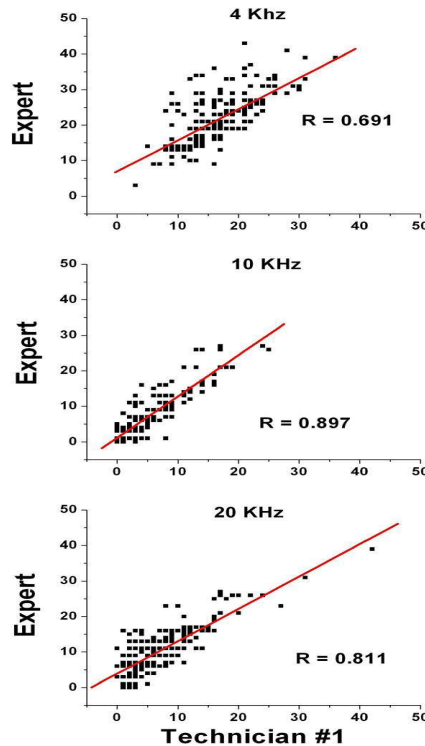


Figure 1: Inter-rater reliability for Sensory Threshold determinations using ABR Wave I functions generated at 4, 10, and 20 kHz pure sound wave stimuli in male guinea pigs. Correlation coefficients were generated by linear fit functions between a well-experienced electrophysiologist and a trained ABR technician for the subjective determination of sound thresholds (limens). All correlations representing Rater 1 vs. Rater 2 reliabilities were best fitted using straight line functions that were statistically significant, showing excellent agreement between the two raters.

electrophysiological monitoring of biological systems as a tenured professor in hearing research at a major U.S. University compared to a trained contract research industry technician using the same proprietary software data collection systems. Significant inter-rater reliabilities were demonstrated.

Thresholds for Wave I in standard ABRs measured with short tone “pips” as a function of frequency; defined as a short duration (15 ms) stimulus presented with a short rise/fall (0.1 ms) were presented to both ears individually and serially (left ear first, out of convention). Stimulus presentations with the lowest frequency (4 kHz) were conducted first and then in ascending order up to 32 kHz. The initial default intensity for each frequency was set at 80 dB and the intensity was lowered in 10 dB units until flattening of the Wave I signal was diminished. The 10 dB default value can be adjusted with experience. The frequency presentations were then tested in 5 dB increments to achieve the best sensory threshold (limen) for each animal. Each test session is scheduled to present a stimulus event (specific frequency and intensity) a minimum of 500 times to each animal (we generally use 1,000 to 2,000 presentations to average). Common practice on auditory function studies is to select three to four frequencies from the species-specific audiogram representing low, mid, and high frequencies within the sensitive hearing range. It is important to select a range of low to high frequency tones to examine function in various areas

of the cochlea, and because the ABR evaluation can be used as a diagnostic tool when the appropriate frequencies are selected for use on study. A tone-pip that is greater than 2 wavelengths in duration at the lowest frequency tested (4 kHz: 0.00025 seconds) requires a minimum of 0.5 msec to complete. This 4 kHz signal has four cycles within 1 msec rise-time. Figure 2, below, shows the Wave I ABR thresholds conducted in over 2500 guinea pigs in our laboratory. Group mean thresholds and S.E.M.s are shown for the guinea pig auditory spectrum in over 2500 animals.

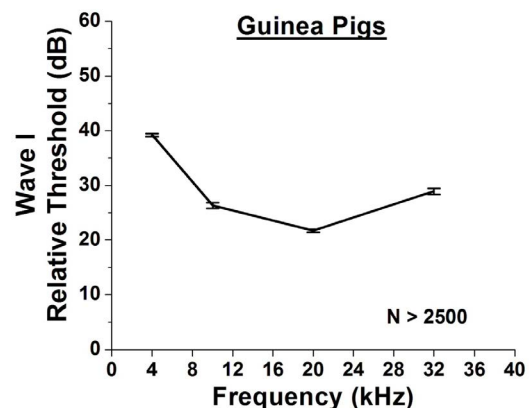


Figure 2: Pure tone audiograms for guinea pigs. Auditory threshold estimates for over 2,500 male guinea-pigs using Wave 1 ABR analysis. Each sound intensity from 80 dB to 0 dB were presented 512 times for 4, 10, 20, and 32 kHz pure sound tones in 10 dB steps. Each symbol represents the group mean Wave 1 threshold +/- 1 S.E.M.

Upward shifts in the Wave I thresholds following drug administration suggests hair cell loss or conductive hearing loss as a result of inflammation, or impedance of inner ear ossicle movements. In contrast, downward shifts in the ABR functions would suggest hyperacusis or increased sensitivity to a specific frequency range. Shifts in auditory thresholds can be reliably assessed under standard laboratory conditions within research environments that also conduct preclinical safety evaluation screening for NDA submissions.

Cytocochleogram Parameters for Regulatory Review

A review of the published literature leads back to the seminal book published in 1966 from members of the Department of Otolaryngology, University Hospital, in Uppsala, Sweden.²⁷ The book gave detailed descriptions of tissue surface preparations to produce a map, which they were the first to call a “cytocochleogram”, showing hair cell damage along the length of the uncoiled basilar membrane. The standard procedure in the Uppsala laboratory was to examine cochlear segments sequentially from the four turns of the organ of Corti, for example base to one-half turn, 0.5 to 1.5 turns, 1.5 to 2.5 turns, and 2.5 to 3.5 turns. For “standard” species, they prepared continuous, complete cochlea grams from the base to the apex. In their original treatise, Engström, Ades, and Andersson²⁶ demonstrated excellent inter-rater reliability (~0.95) for cell counts of inner and outer hair cells in their standard configuration of base to 0.5 turns, 0.5 to 1.5, 1.5 to 2.5, and 2.5 to 3.5 cochlear turns.

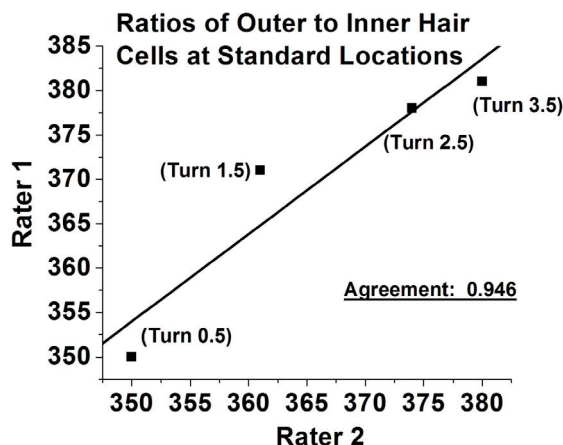


Figure 3: Inter-rater reliability for the ratio of outer to inner hair cell counts by two microscopy technicians at 0 to 0.5, 0.5 to 1.5, 1.5 to 2.5, and 2.5 to 3.5 mm of the guinea pig cochlea. Correlation coefficients were generated by linear fit functions between two readers in the Engström, Ades, & Andersson mapping of the cochlea (cf page 62). Correlations representing Rater 1 vs. Rater 2 reliabilities were best fitted using straight line functions that were statistically significant, showing excellent agreement between the two raters.

As reviewed by Santi,²⁸ with the advent of the electron microscope and the development of tissue fixation and embedding processes, Bohne²⁹ and Spoendlin & Brun³⁰ improved the methods for producing surface preparations of the whole organ of Corti so that they could be examined by both light and transmission electron microscopy. In 1986 Santi²⁸

published a relatively rapid method for fixation, embedding, trimming and mounting of the complete length of the organ of Corti that could be placed on a single slide that would be well-suited for light microscopy computer-assisted analysis to determine the number of “normal” and damaged hair cells. In spite of these pioneers in the field of cytopathology, in 2016 the harvesting, decalcification of the protective bone encasement of the tissue, as well as the surface preparation of the organ of Corti remains a meticulous, time-consuming, and challenging task.

Over the last five decades of examination and processing of the auditory sensory system there have been some generalized findings that may support the development of a standard process of neuropathological analyses that will provide convincing and compelling, scientifically-sound, and legally defensible data regarding the relative safety of any new NCE that will support NDA review by the FDA. Hawkins & Johnsson³¹ reported that:

- 1) For reasons still not adequately understood, the hair cells at the extreme basal end of the cochlea are most often affected by the cytotoxic actions of the test agent. While scattered cell losses have been documented elsewhere along the continuum from base to apex, the early signs of ototoxicity of an NCE are identified by complete loss of outer hair and inner hair cells in the first 2 to 3 mm of the basilar membrane. In the Hawkins & Johnsson study,^{31(p.176)} shortly following amino glycoside exposures a great majority of hair cells were still present above 5 mm. They concluded that it is not uncommon to find scattered losses of outer hair cells from the first to third row in untreated control animals – especially guinea pigs and cats.
- 2) With respect to chemical cytotoxicity from cisplatin and/or the aminoglycosides, the loss of hair cells typically starts at the first row of outer hair cells. The progression of damage usually shows greater loss of outer hair cells from the first row when compared to the second cell row. As the cellular signs of damage progresses, first row cells are lost followed in time by swollen and distorted second row cells; the third row of outer hair cells and the row of inner hair cells may still show intact and functioning cell integrity.³²
- 3) In acoustic trauma (noise-induced deafness) the progression of functional changes and cell death is slightly different from chemical induced damage. The damage is initially noted in the first row of outer hair cells then the inner hair cell, followed by the second and third rows of outer hair cells. The spatial distribution of damage to the outer hair cells in row 1 and its associated inner hair cells differed in that the inner hair cells show damage mainly in the vicinity of the tonotopic exposure location and the outer hair cells damage spreads from the base (ear drum section) of the membrane up to the tonotopic area of maximal wave deflection.³³
- 4) As the full expression of a NCEs cellular toxicity is identified within the cochlea, the parade of progression of

cellular death from base to apex on the basilar membrane seems to be both dose- and time-dependent. With increasing doses or prolonged administration, cell death progressively increases.³² In most cases, cochlear neurons degenerate secondarily after the inner hair cell loss.³⁴ As the sensory neurons die-out, disordered scarring of the reticular lamina, including the head plates of the pillar cells follows. In severe ototoxicity, localized lesions of the organ of Corti may occur in which all of the sensory and supporting elements have disappeared. This helps to categorize the quantitative destruction of cochlea in conjunction with the pathologist's qualitative reads.

While these facts may serve as a "rule of thumb" for establishing standardized protocols for tissue processing in an ototoxicity study, the extent of outer hair cell loss should not be inferred simply from duration or dose level of exposures. The progression of damage from amino glycoside antibiotic and cisplatin toxicity appears similar in that the initial insult is seen at the tympanic end (base) of the basilar membrane and then progresses up the length of the cochlea to the apex. The cilia seem to be first affected in the death or injury cascade. The first row of outer hair cells seems to show toxicity before the second and third rows. Following outer hair cell death the cascade of cell death is then expressed in the inner hair cells. With hair cell integrity compromised, cell death evolves to include spiral ganglion cells. It remains a requirement to perform some cellular count of complete hair cell loss down some specified length of the uncoiled or processed organ of Corti (cytococheogram).

Information on the hair cell density of the guinea pig cochlea is scarce in the literature.^{35,36} Detailed information was given by Burda³⁷ (ten cochleas processed, including the hook¹), who demonstrated the hair cell density that is dependent on the relative distance from the apex and the averaged value of hair cell density for the whole cochlea. The averaged values of hair cell density can be compared directly, whereas, the spatial dependence can only be compared qualitatively due to the divergent presentation (sector-wise vs. stepped distances of the cochlea length). For the whole cochlea, Burda³⁷ found an average of 360.6 outer hair cells per millimeter and 100.4 inner hair cells per millimeter of basilar membrane. Linss, Linss, Emmerich & Richter³⁸ showed excellent agreement with these cell counts by reporting average values of 389 outer hair cells per millimeter (all three rows) and 101 inner hair cells per millimeter of basilar membrane. Qualitatively, Burda³⁷ found two segments of the basilar membrane showing maximal hair cell densities. One is located at the apex (helicotrema end) and the other about 30% of the cochlea length from the base. Linss, Linss, Emmerich & Richter³⁸ results also confirmed this spatial dispersion.

The table below lists the averaged group lengths of the guinea pigs organ of Corti reported in the published scientific

¹The "hook" area of the cochlea was previously referred to as the "cochlear hamulus" and is located at its base by the tympanic membrane and oval window near the temporal bone where it bends or "hooks" downward. This specific region is critically important in placement of cochlear implants.

literature appearing in peer-reviewed journals.

Basilar Membrane Length	Reference
20.8 mm	39
18.8 mm	40
20.32±0.69	41
18.17±/ - 0.15 mm	42
21.79 mm	43
18.6 mm	44
20.5±0.6	37
18.5 mm	45
18.8±/ - 0.5 mm	46

According to Solntseva,⁴⁰ in the guinea pig (*Cavia porcellus*) the cochlea forms 4.5 turns. The average length of the total basilar membrane is approximately 18.8 mm and its average length for each of the turns is: 8.5, 4.8, 3.4, and 2.1 mm, respectively. The average number of hair cells in the guinea pig is 8,399, of which 1,899 are inner hair cells and the remaining 7,040 are outer hair cells. In the lower cochlear turn the number of inner hair cells is 874; in the second turn 437; in the third turn 403, and the fourth turn has 124; the remaining half turn of the apical end has 61 cells.

As described by Santi²⁸ and colleagues,⁴⁶⁻⁴⁸ cell counting of the entire cochlea is extremely time-consuming. Identifying and counting all of the cochlear hair cells on serial sections of imbedded and processed slides under a light microscope can add weeks to months onto the study timeline depending on the number of trained technicians and available microscopes dedicated to the project. In addition to the sheer number of cells to be counted in a full cytococheogram, the position of the slide must be repositioned to reflect the density changes along the length of the basilar membrane. Most of the analysis of minimal to moderate damaged cochlea is spent counting normal hair cells. The process may be more efficient by concentrating on hair cell damage rather than counting normal hair cells.

Proposed Process for Cytococheogram Evidence of Ototoxicity Liability for NDA Submission

As stated above, current health agency administrative and regulatory policies provide little information on what defines a "cytococheogram". While decades of ototoxicity research results have accumulated there is no clear definition of how to construct a standard cochleogram.⁴¹ The need for these data are critical to the FDA's statutory responsibility for drug labelling prior to NDA approval, and for its regulatory responsibilities established by Congress to ensure the health-impact and safety of all new products entering the market place. The relative issue in regard to risk assessment pertains to the risk to benefit ratio of the new drug when compared to current treatments. The FDA may approve a new drug knowing that it has the potential to induce hearing loss, if the health benefit of the drug outweighs the deleterious influence of hearing loss in the targeted population, however, they must have a constant concern for "black box warning" or training material content to doctors who prescribe the drug if preclinical biomarkers suggest a potential

for ototoxicity. The issue here is not so much on how much hearing loss is induced by a given drug because that will be an empirically-driven quantitative measure based on dose and duration of treatments. The focus for risk liability is simply, “Is there damage or not?”

So the goal in preclinical safety screening of new drugs for selective damage to the VIIIth cranial nerve compartment is simply to demonstrate a valid and reliable predictor of cell death in the cochlea following local or systemic exposure to the new drug entity. As described above, most cell damage whether by chemical (drug) or physical insult (loud noise) appears to originate near the basal end of the cochlea – not the apex. Demonstrative evidence of selective cell damage at the base of the cochlea is a relatively reliable measure of ototoxicity liability. If cell death is induced there, and shows dose-dependency within a study, or time-dependency between studies, then sufficient, credible evidence exists determinative of labelled warnings on the product advertising and packaging materials.

Ototoxicity Screening/Testing

Screening for ototoxic effects should be routinely carried out in short-term and subchronic toxicity studies with an appropriate species, preferably guinea pig, for 1) any new chemical entity that has the ability to penetrate an intact tympanic membrane; 2) is expected to reach the middle or inner ear during clinical use, 3) is introduced directly to those regions, or 4) has demonstrated renal toxicity during preclinical screening toxicology studies, or 5) is structurally similar to any other known ototoxicant and is administered systemically.

The ototoxicity screen should be age appropriate and would typically include: (1) specific histopathological examination of tissue samples representative of major areas of the VIIIth cranial nerve compartment, including cochlea, tympanic cavity, ossicles, semicircular canals, and Eustachian tubes.

Ototoxicity Screening Studies

The study reports should include an assessment of the potential for the test substance to adversely affect the structural or functional integrity of the sensory and transductive organs of the ear, adverse effects of the integrity of vestibular function or associated balance disorder syndromes. In regards to risk assessment analysis for regulatory review and product labelling, any cell damage or loss in the basilar end of the cochlea that is not demonstrated in vehicle control or aged match cohorts is sufficient evidence to warrant further testing or “Black Box” warnings on the label of the marketed product.

Neuropathology: Collection, Processing and Examination of Tissue Samples

A gross middle ear assessment should be performed using a

dissecting microscope. During this assessment, the middle ear should be opened by removing regions of the temporal bone to reveal the ossicles. The presence of white or red discoloration, fluid, edema/swelling, or redness should be noted and rated. Integrity and appearance of the tympanic membrane should also be required. A instrument (i.e. forceps) should be used to gently apply pressure to the ossicles and their mobility is noted and rated in the pathology record. Photo-micrographs should be taken when necessary to demonstrate representative observations. Ratings, where required (i.e., for assessments of edema, erythema, and ossicle mobility), should be performed on a scale of (0) Not Present, (1), Minimal, (2) Moderate, and (3) Severe (or other suitable grading criteria). Ossicle mobility may be limited to simple rating as present or not present. Comments may be added to any of these ratings for further description of the finding at the discretion of the rater. The ossicles should be prepared for histological evaluation by light microscopy.

To provide for adequate sampling as well as optimal preservation of cellular integrity for the detection of neuropathological alterations, tissue should be prepared for histological analysis using *in situ* perfusion and paraffin and/or plastic embedding procedures. Paraffin embedding is acceptable for tissue samples from the central nervous system including cranial nerves. Plastic embedding of tissue samples from the central nervous system is encouraged, when feasible.

a. Histopathology: Histopathological evaluation should be conducted for the Organ of Corti (cytococholeogram) and middle and inner ear structures (Otic Microscopy) for all animals in ototoxicity screening studies. Our laboratory reserves one ear for cytococholeogram and the alternate ear for otic histopathology for every animal on study. We have also included non-treated age-, breeder-, gender-, and generational-matched cohorts for comparisons as well.

b. Fixation and processing of tissue: The neural tissue should be fixed by *in situ* perfusion with an appropriate aldehyde fixative. As described above, any gross abnormalities of tympanum, internal and external auditory canal, inner ear structures such as the ossicles, and vestibular labyrinthine body should be noted.

i) Fixation: Following perfusion flush of saline and perfusion fixation with paraformaldehyde (or other applicable perfusion media), the middle and inner ears should be collected intact and fixed in paraformaldehyde for a predetermined functional time interval (i.e. 1 to hours). Tissues should then be transferred to a lower concentration of paraformaldehyde, and stored refrigerated until analyzed. The bullae should be subsequently dissected free of the remaining temporal bone, opened to allow observation, access to the middle ear, and to accommodate decalcification. The tissue block should than be placed in decalcification solution.

ii) Decalcification: The hard bony material must be decalcified

using a gentle decalcification solution (for example, 10% EDTA) for tissue harvesting and processing. When the tip of a probe or fine tipped forceps encounters little resistance, the decalcification procedure will be considered complete.

iii) Trimming: Fine tipped rongeurs, scissors, forceps and blades are used to further trim the bone of the middle ear.

iv) Embedding: A modified version of ethanol fixation and paraffin embedding of otic tissue allows for clear visualization of natural fluorescence of reporter proteins needed for cellular differentiation and identification while maintaining excellent tissue morphology of inner ear tissues. Tissues can be dehydrated in step-wise processes using such agents as ethanol and then subsequently followed by exposures to xylenes. Specimens are generally allowed to come to room temperature prior to being permeated with paraffin by repeated immersions in 4 paraffin baths at 56 °C. Blocks of paraffin embedded tissue are then stored refrigerated in the dark until use. Sections of tissue 5 to 10 µm thick can be mounted and dried for review.

For plastic sectioning, the bullae need to be dehydrated through a graded series of alcohols and embedded in plastic, either Methacrylate or EPON-like resin (e.g., EMBED 812, or paraffin).

v) Sectioning: Prepared blocks should be trimmed and initial paraffin or plastic sections be used for orientation. Blocks should be aligned and several micron sections cut on the microtome. Periodic sections should be stained (see below) and assessed under a dissection or light microscope, to further align the block and determine when sections containing ossicles are observed, and then every third or fourth section should be mounted on a glass slide. This process should be continued until sections containing all the ossicles are obtained. Sections should then be stained with appropriate stains (i.e. H&E, Richardson's and/or Paragon) and cover slipped.

c. Otic Microscopy: Many systemically administered drugs will have access to the functional organization and operations of middle and inner ear systems. The FDA's guidance document does suggest direct dose administrations into the middle ear as a method to ensure adequate concentration delivery required for the full assessment of toxicological effects. Therefore, it is essential to include an assessment of the direct and inflammatory effects of such administrations on the mucosa and structures of the middle ear following the direct intra tympanic administration of the drug. Our standard protocol includes otic microscopy on one ear and cytocholeogram analysis of the alternate ear from both control and drug treated cohorts.

The result of otic microscopy may be employed to confirm or refute any ABR findings suggestive of conductive hearing loss. When approaching the evaluation of the middle

ear, it is important to identify the structures intrinsic to sound conduction. If the temporal bone is oriented precisely, it is possible to collect sections of the tympanic membrane, ossicular chain, tensor tympani, round window, cochlea, and middle ear mucosa. Evaluation of these structures will provide insight into how the drug is interacting with the milieu of the middle ear. Signs of inflammation, fibrosis, and necrosis can result from direct administration of drugs into the middle ear, either by intra tympanic injections or, in the laboratory setting, by inner ear cannula injections. Detailed examination of the ossicles, round window, cochlea (bone, stria, organ of corti), auditory nerve, spiral ganglion, middle ear, and Eustachian tubes are essential in this analysis. Close and detailed examination of this portion of the small compartment of the auditory structures is critical in the identification of conductive disturbances that are reflected in augmented hearing thresholds in the ABR but are due to mechanical, inflammatory, or direct toxic effects on the conductive portions of transducing air pressure waves to nerve impulses.

The bone surrounding the structures of the inner ear is unique and embryologically distinct.⁴⁹ This bone is called the endochondral bone and forms the otic capsule. It is a primitive form of bone with dense extracellular matrix components. The footplate of the stapes is derived from otic capsule material and in pathological states the footplate may be exceptionally dense, thickened, and fixed to the surrounding oval window. The remaining bone tissues of the inner ear (ossicles) and temporal bone (mastoid cavity) are more similar to cranial and lamellar bone histologically. The otic capsule is extremely dense and with little porosity in terms of its micro architecture. The surface of this bone should be smooth and marble-like. In contrast, cortical bone (substantia compacta) is punctuated by pockets of fluid and cellular materials. Cortical bones and lamellar bones (substantia spongiosa) are the two bone types making up the calvarial vault. Observation and evaluation of the calvarial vault is essential in determining the role of conductive disturbances to changes in ABR thresholds. These evaluations are limited to the otic microscopy section of the post life tissue processing protocol.

Representative sections should be assessed using a light microscope under low and high magnifications for each bullae. Based on at least three sections from each animal, ossicles should be graded as normal or pathology noted. Photos should be taken when necessary to demonstrate representative lesions.

Detailed dissection procedures should be conducted per standard operating procedure guidelines of the institution. The tissue samples should be post-fixed and processed according to standardized published histological protocols. Tissue blocks and slides should be appropriately identified when stored. Histological sections should be stained for hematoxylin and eosin (H&E), phalloidin, or a comparable stain according to standard published protocols.

d. Cytocholeogram Microscopic Review: This level of analysis

is specifically called out in the FDA guidance document. As stated above, our laboratory generally conducts cytochleograms on one ear and otic microscopy on the other. The details of the cytochleogram are based on previous work by Viberg & Canlon.⁴¹

The Organ of Corti should be fixed and stained with phalloidin (actin staining), or equivalent fluorescent stain. The cochlea should be uncoiled, trimmed, and placed on slides for reading. The length of the cochlea should be measured and documented in the study record. Tissues from all animals in the control and a minimum of 3 dose groups should be examined. Based on the etiology of chemical induced ototoxicity, quantitative screening procedures should include a complete total inner and outer hair cell count for a minimum cochlear distance of 40% of the full membrane as measured from basal end. The total number of hair cells and/or the total number of lost cells per unit area of the basilar membrane can be plotted as a function of percent distance from the cochlea apex and graphically plotted to establish the cytochleogram.

e. Otic Histological Qualitative examination: Representative histological sections from the otic microscopy designated ear tissue samples should be examined microscopically by an appropriately trained pathologist for evidence of any treatment-related alterations. Particular attention should be paid to regions known to be sensitive to neurotoxic insult or those regions likely to be affected based on the results of functional tests. Such treatment-related alterations should be clearly distinguished from artifacts resulting from influences other than exposure to the test substance (age, mechanical damage related to high noise exposure, dosing procedure, etc.). A stepwise examination of tissue samples is recommended. In such a stepwise examination, sections from the high dose group are first compared with those of the control group. It is good practice to include tissues from vehicle control injection cohorts, sham (untreated) controls, and drug treated cohorts in each study, especially in those that utilize intratympanic administration of test article.

If no neuropathological alterations are observed in samples from the high dose group, subsequent analysis of lower dose groups is not required. If alterations are observed in samples from the high dose group, samples from the intermediate and low dose groups are then examined sequentially. If treatment related effects are noted in any dose group an ototoxic risk should be assumed.

f. Description of the Process for Review of Pathology Data: Detailed descriptions and diagnostic criteria of pathology data should be standard operating procedure. Occasionally, a reviewing pathologist is asked to examine all of the pathology findings in a study. All information available to the reviewing pathologist should be made available to the peer review pathologist.

The report should include a narrative that provides an

overview of the pathology findings from the study pathologist's perspective as well as other observations documented during the study. A discussion that includes qualitative description of lesions and that highlights differences among treated and control groups are an essential part of the interpretation and evaluation of ototoxicity data. Remarks about possible pathogenesis, strengthened by references to the scientific literature, could be an important part of the pathologists or Study Director's narrative. Significant events, such as incidences of stereotypic behaviors associated with vestibular and balance disorders, and the impact of such events on the study outcome should be discussed. Differences in the incidence of key histopathologic findings among groups should be discussed; if observed differences are not regarded as treatment-related, then the basis for this conclusion should be provided.

It should be remembered that ototoxic events never occur in isolation. There is ample evidence that cytotoxic drugs may also have angiotoxic effects in the same tissue.³¹ Affected damaged capillaries may collapse upon themselves and give the appearance of an intravascular strand linking two normal-appearing vessels, or it may disappear completely, and leaving an avascular channel (AVC). The AVCs are also found in the spiral ligament and in certain other tissues of normal guinea pigs, presumably as the result of the same process of gradual devascularization that occurs in human labyrinthine tissues with aging. Hair cell loss is also accompanied by protrusion of the supporting cells into Nuel's space and the tunnel of Corti, resulting in a disturbed micro architecture of the organs of Corti and eventually in complete replacement of the sensory epithelium by a single layer of epithelial cells.⁵⁰⁻⁵⁷

g. Evaluation of data: The findings from the ototoxicity screening battery should be evaluated in the context of preceding and/or concurrent toxicity studies and any correlated functional and histopathological findings (i.e. renal toxicity). The evaluation should include the relationship between the doses of the test substance and the presence or absence, incidence and severity, of any sensorineuronal or conductive hearing loss effects. The evaluation should include appropriate statistical analyses, for example, parametric tests for continuous data and nonparametric tests for the remainder. Choice of analyses should consider tests appropriate to the experimental design, including repeated measures. There may be many acceptable ways to analyze data. Statistical analysis comparing total cellular counts of treatment vs. control animals at each turn of the cochlea or distance from apex or tympanum must be made and supplied. The report must include pre vs. post exposure ABR threshold evaluations (i.e., Wave 1 thresholds) of intact animals, cytochleograms of a minimum of 40% of cochlea distance, with respect to basal end of the membrane, and any gross necropsy findings and lesions observed.

CONCLUSION

Far too many drugs are being approved based on risk assessment

platforms that do not include the requirements of processing and evaluation of structures associated with the VIIIth cranial nerve. Drug-induced hearing loss, tinnitus, or balance disorders pose a significant impact on the quality of life and dose compliance of those prescribed a drug by their physician with the assumption that the drug is safe. Preclinical auditory safety assessments are not part of the core battery of regulatory-required tests conducted during product development and approval. We have proposed a systems-approach and protocol criteria for the valid and reliable assessment of auditory function that can be easily included as a screening tool for ototoxicity within the Tiered Structure of preclinical assays required for approval of any chemical entity targeted for human use.

CONFLICTS OF INTEREST

The authors have no conflicts of interest to declare.

AUTHORS CONTRIBUTION

All contributors assisted in literature review, consolidation and preparation of the manuscript.

FUNDING

Development of all data discussed in this manuscript was funded by MPI Research.

REFERENCES

1. Seligmann H, Podoshin L, Ben-David J, Fradis M, & Goldsher M. Drug-induced tinnitus and other hearing disorders. *Drug Saf.* 1996; 14(3): 198-212. doi: [10.2165/00002018-199614030-00006](https://doi.org/10.2165/00002018-199614030-00006)
2. Ryan W, & Sachin D. Drug induced ototoxicity. *Clinical & Experimental Pharmacology.* 2014; 4: 1-5. doi: [10.4172/2161-1459.1000e132](https://doi.org/10.4172/2161-1459.1000e132)
3. O’Conner KDJ, & Mastaglia FL. Drug induced disorders of the nervous system. In: Aminoff MJ, & Josephson A, editors, *Aminoff’s neurology and general medicine*, 5th edn. Waltham, MA: Academic Press; 2014: 685-711. doi: [10.7861/clinmedicine](https://doi.org/10.7861/clinmedicine)
4. Wrześniok D, Buszman E, & Matusiński B. Drugs ototoxicity. Part II. Loop diuretics, nonsteroidal anti-inflammatory drugs, antineoplastic and antimalarial drugs. *Wiad Lek.* 2003; 56(7-8): 369-374. Web site. <http://europepmc.org/abstract/med/14969167>. Accessed April 14, 2016.
5. Palomar García V, Abdulghani Martínez F, Bodet Agustí E, Andreu Mencia L, Palomar Asenjo V. Drug-induced ototoxicity: current status. *Acta Otolaryngol.* 2001; 121(5): 569-572. doi: [10.1080/00016480121545](https://doi.org/10.1080/00016480121545)
6. Yu J, Ding D, Wang F, Jiang H, Sun H, Salvi R. Pattern of hair

- cell loss and delayed peripheral neuron degeneration in inner ear by a high-dose intratympanic gentamicin. *J Otolaryngol.* 2014; 9:126-135. doi: [10.1016/j.joto.2014.12.001](https://doi.org/10.1016/j.joto.2014.12.001)
7. Hawkins JE. Drug ototoxicity. In: Keidel WD, & Neff WD, eds. *Handbook of Sensory Physiology*, New York, USA; Berlin, Heidelberg: Springer-Verlag; 1976: 707-748.
8. Broesel S, Laub C, Averdam A, Bender A & Elstner M. Molecular aging of the mammalian vestibular system. *Ageing Res Rev.* 2016; 26: 72-80. doi: [10.1016/j.arr.2015.12.007](https://doi.org/10.1016/j.arr.2015.12.007)
9. United States Food and Drug Administration, Department of Health and Human Services. International Conference on Harmonisation; Guidance on S7A Safety Pharmacology Studies for Human Pharmaceuticals; Notice of Availability. *Fed Regist.* 2001; 66 (135): 36791-36792. Web site. <https://www.gpo.gov/fdsys/pkg/FR-2001-07-13/pdf/01-17498.pdf>. Accessed April 14, 2016.
10. United States Food and Drug Administration, Department of Health and Human Services. Nonclinical safety evaluation of reformulated drug products and products intended for administration by an alternative route; Guidance for Industry and Review Staff; Notice of Availability. *Fed Regist.* 2015; 80(208): 66013-66014. Web site. <https://www.federalregister.gov/articles/2015/10/28/2015-27418/nonclinical-safety-evaluation-of-reformulated-drug-products-and-products-intended-for-administration>. Accessed April 14, 2016.
11. Doble RA, Berlin CI. (1979) Binaural interaction in brainstem evoked response. *Arch Otolaryngol.* 1979; 105(7): 391-398. doi: [10.1001/archotol.1979.00790190017004](https://doi.org/10.1001/archotol.1979.00790190017004)
12. Gardi JN, Berlin CI. A preliminary report on the origin(s) of the Binaural-interaction components of the guinea pig ABR: Possible origins. *Arch Otolaryngol.* 1981; 107: 164-168.
13. Henry KR, Chole RA. Cochlear electrical activity in the C57BL/6 and CBA/J mice. *Acta Oto-Laryngol* (Stockholm). 1978; 86: 366-374.
14. Henry KR. Auditory nerve and brain stem volume-conducted potentials evoked by pure-tone pips in the CBA/J laboratory mouse. *Audiology.* 1979; 18(2): 93-108. doi: [10.3109/00206097909072623](https://doi.org/10.3109/00206097909072623)
15. Henry KR. Auditory brainstem volume conducted responses. Origins in the laboratory mouse. *J Am Audit Soc.* 1997; 4(5): 173-178. Web site. http://journals.lww.com/ear-hearing/Abstract/1979/03000/Auditory_Brainstem_Volume_Conducted_Responses_.3.aspx. Accessed April 14, 2016.
16. Schorn VF, Lennon VA, Bickford RG. Brainstem auditory evoked responses (BAERs) in the rat – Effect of field extension, asphyxia and autoimmune encephalomyelitis. *Soc Neurosci*

Abstr. 1976; 2: 1-9.

17. Buchwald JS, Huang CM. Far-field acoustic response: Origins in the cat. *Science*. 1975; 189(4200): 382-384. doi: [10.1126/science.1145206](https://doi.org/10.1126/science.1145206)

18. Achor LJ, Starr A. (1980) Auditory brain stem responses in the cat. I. Intracranial and extracranial recordings. *Electroencephal Clin Neurophysiol*. 1980; 48(2): 154-173. doi: [10.1016/0013-4694\(80\)90301-6](https://doi.org/10.1016/0013-4694(80)90301-6)

19. Gardi JN, Merzenich MM. The effect of high pass noise on the scalp recorded frequency following response (FFR) in humans and cats. *J Acoust Soc Amer*. 1979; 65: 1491-1500. doi: [10.1121/1.382913](https://doi.org/10.1121/1.382913)

20. Gardi JN, Merzenich MM, McKean C. Origins of the scalp recorded frequency following response in the cat. *Audiology*. 1979; 18(5): 353-381. doi: [10.3109/00206097909070062](https://doi.org/10.3109/00206097909070062)

21. Allen AR, Starr A. Auditory brain stem potentials in the monkey (M. mulatta) and man. *Electroencephal Clin Neurophysiol*. 1978; 45(1): 53-63. doi: [10.1016/0013-4694\(78\)90341-3](https://doi.org/10.1016/0013-4694(78)90341-3)

22. Merzinich MM, Gardi JN, Vivion MC. Animals, Chapter 15. In: Moore EJ, ed. *Bases of Auditory Brain-Stem Evoked Responses*. New York, USA; Grune & Stratton; 1983: 391-412.

23. Buchwald JS. Auditory evoked responses in clinical populations and in the cat. *Auris Nasus Larynx*. 1983; 10(2): 87-95. doi: [10.1016/S0385-8146\(83\)80033-9](https://doi.org/10.1016/S0385-8146(83)80033-9)

24. Jewett DL. Volume-conducted potentials in response to auditory stimuli as detected by averaging in the cat. *Electroencephal Clin Neurophysiol*. 1970; 28(6): 609-618. doi: [10.1016/0013-4694\(70\)90203-8](https://doi.org/10.1016/0013-4694(70)90203-8)

25. Lev A, Sohmer H. Sources of averaged neural-responses recorded in animals and human subjects during cochlear audiometry. (Electro-cochleogram). *Archiv für klin experim Ohren- Nasen- und Kehlkopfheilkunde*. 1972; 201(2): 79-90. doi: [10.1007/BF00341066](https://doi.org/10.1007/BF00341066)

26. Jewett DL, Romano MN. Neonatal development of auditory system potentials from the scalp of rat and cat. *Brain Research*. 1972; 36(1): 101-115. doi: [10.1016/0006-8993\(72\)90769-X](https://doi.org/10.1016/0006-8993(72)90769-X)

27. Engström H, Ades HW, Andersson A. *Structural Pattern of the Organ of Corti. A Systematic Mapping of Sensory Cells in the Neural Elements*. Baltimore: Williams and Wilkins; 1966.

28. Santi PA. Organ of Corti surface preparations for computer-assisted morphometry. *Hearing Research*. 1986; 24(3): 179-187. doi: [10.1016/0378-5955\(86\)90017-1](https://doi.org/10.1016/0378-5955(86)90017-1)

29. Bohne B. Location of small cochlear lesions by phase

contrast microscopy prior to thin sectioning. *Laryngoscope*. 1972; 82(1): 1-16. doi: [10.1002/lary.5540820101](https://doi.org/10.1002/lary.5540820101)

30. Spoendlin H, Brun J. The block-surface technique for evaluation of cochlear pathology. *Archives of Oto-rhino-laryngology*. 1974; 208(2): 137-145. doi: [10.1007/BF00453927](https://doi.org/10.1007/BF00453927)

31. Hawkins JE, L-G Johnsson. Histopathology of cochlear and vestibular ototoxicity in laboratory animals. In: Lerner SA, Matz GJ, Hawkins Jr. JE, eds. *Aminoglycoside Ototoxicity*. Boston: Little, Brown and Company; 1981; 175-196.

32. Van Ruijven M.W.M., de Groot, JCMJ, Smoorenburg GF. Time sequence of degeneration pattern in the guinea pig cochlea during cisplatin administration. A quantitative histological study. *Hear Res*. 2004; 1979(1-2): 44-54. doi: [10.1016/j.heares.2004.07.014](https://doi.org/10.1016/j.heares.2004.07.014)

33. Robertson D, Johnstone BM. Acoustic trauma in the guinea pig cochlea: early changes in ultrastructural and neural thresholds. *Hear Res*. 1980; 3(2): 167-179. doi: [10.1016/0378-5955\(80\)90044-1](https://doi.org/10.1016/0378-5955(80)90044-1)

34. Pirvola U, Xing-Qun L, Virkkala J, et al. Rescue of hearing, auditory hair cells, and neurons by CEP-1247/KT7515, an inhibitor of c-Jun N-terminal kinase activation. *J Neurosci*. 2000; 20(1): 43-50. Web site. <http://www.jneurosci.org/content/20/1/43.short>. Accessed April 14, 2016.

35. Fernandez C. The innervation of the cochlea (guinea pig). *The Laryngoscope*. 1951; 61(12): 1152-1172. doi: [10.1288/00005537-195112000-00002](https://doi.org/10.1288/00005537-195112000-00002)

36. Fernandez C. Dimensions of the cochlea (guinea pig). *J Acoust Soc Amer*. 1952; 24: 519-523. doi: [10.1121/1.1906929](https://doi.org/10.1121/1.1906929)

37. Burda H. Guinea pig cochlear hair cell density; its relation to frequency discrimination. *Hear Res*. 1984; 14(3): 315-317. doi: [10.1016/0378-5955\(84\)90058-3](https://doi.org/10.1016/0378-5955(84)90058-3)

38. Linss V, Linss W, Emmerich E, & Richter F. (The cochleogram of the guinea pig. *Eur Arch Otorhinolaryngol*. 2007; 264(4): 369-375. doi: [10.1007/s00405-006-0190-z](https://doi.org/10.1007/s00405-006-0190-z)

39. Hoffman R, Segenhout JM, Wit HP. Three-dimensional reconstruction of the guinea pig inner ear; comparison of OPFOS and light microscopy; applications of 3D reconstruction. *Journal of Microscopy*. 2009; 233(2): 251-257. doi: [10.1111/j.1365-2818.2009.03115.x](https://doi.org/10.1111/j.1365-2818.2009.03115.x)

40. Solntseva GN. Chapter 3. Structure of the mammals inner ear. In: Belkovich VM, ed. *Morphology of the Auditory and Vestibular Organs in Mammals With Emphasis on Marine Species*. Sofia-Moscow-Leiden-Boston, Netherland; Co-published by Pensoft Publishers and Brill Academic Publishers; 2007: 76-97.

41. Viberg A, Canlon B. The guide to plotting a cochleogram. *Hear Res.* 2004; 197(1-2): 1-10. doi: [10.1016/j.heares.2004.04.016](https://doi.org/10.1016/j.heares.2004.04.016)
42. Shinomori Y, Spack DS, Jones DD, Kimura RS. Volumetric and dimensional analysis of the guinea pig inner ear. *Ann Otol Rhino Laryngol.* 2001; 110(1): 91-98. doi: [10.1177/000348940111000117](https://doi.org/10.1177/000348940111000117)
43. Thorne M, Salt AN, DeMott JE, Henson MM, Henson OW Jr., Gewalt JL. Cochlear fluid space dimensions for six species derived from reconstructions of three-dimensional magnetic resonance images. *Laryngoscope.* 1999; 109(10): 1661-1668. doi: [10.1097/00005537-199910000-00021](https://doi.org/10.1097/00005537-199910000-00021)
44. Wada H, Sugawara M, Kobayashi T, Hozawa K, Takasaka T. Measurement of guinea pig basilar membrane using computer-aided three-dimensional reconstruction system. *Hear Res.* 1998; 120(1-2): 1-6. doi: [10.1016/S0378-5955\(98\)00007-0](https://doi.org/10.1016/S0378-5955(98)00007-0)
45. von Békésy G. *Experiments in Hearing.* NY; McGraw-Hill; 1989.
46. Santi PA, Blair A, Bohne BA, Lukkes J, Nietfeld J. The digital cytochochleogram. *Hear Res.* 2004; 192: 75-82.
47. Santi PA, Mitchell WH, Harrison RG. A computer-assisted morphometric analysis of the organ of Corti. *Hear Res.* 1986; 24(3): 189-201. doi: [10.1016/0378-5955\(86\)90018-3](https://doi.org/10.1016/0378-5955(86)90018-3)
48. Santi PA, Rapson I, Voie A. Development of the mouse cochlea database (MCD). *Hear Res.* 2008; 243(1-2): 11-17. doi: [10.1016/j.heares.2008.04.014](https://doi.org/10.1016/j.heares.2008.04.014)
49. Bast TH. (1930) Ossification of the otic capsule in human fetuses. *Contribut Embryol.* 1930; 21: 53-82.
50. Estrem SA, Babin RW, Ryu JH, Moore KC. Cis-diamminedichloroplatinum (II) ototoxicity in the guinea pig. *Otolaryngol - Head Neck Surg.* 1981; 89(4): 638-645. Web site. <http://europepmc.org/abstract/med/6793976>. Accessed April 14, 2016.
51. Nakai Y, Konishi K, Chang KC, Ohashi K, Morisaki N, Minow Y et al. Ototoxicity of the Anticancer Drug Cisplatin: An Experimental Study. *Acta Otolaryngol (Stockholm).* 1982; 93(1-6): 227-232. doi: [10.3109/00016488209130876](https://doi.org/10.3109/00016488209130876)
52. Tange RA. Differences in the cochlear degeneration pattern in the guinea pig as a result of gentamicin and cis-platinum intoxication. *Clin Otolaryngol.* 1984; 9(6): 323-327. doi: [10.1111/j.1365-2273.1984.tb01515.x](https://doi.org/10.1111/j.1365-2273.1984.tb01515.x)
53. Tange RA, Conjin EAJG, van Zejeilil LGPM. The corticotoxic effect of cis-platinum in the guinea pig. *Arch Otorhinolaryngol.* 1982; 237: 17-26.
54. Konishi T, Gupta BN, Prazma J. Ototoxicity of cis-dichlorodiammine platinum(II) in guinea pigs. *Am J Otolaryngol.* 1983; 4(1): 18-26. doi: [10.1016/S0196-0709\(83\)80003-9](https://doi.org/10.1016/S0196-0709(83)80003-9)
55. Cardinaal RM, De Groot JCMJ, Huizing EH, Veldman JE, Smoorenburg GF. Dose-dependent effects of 8-day cisplatin administration upon the morphology of the albino guinea pig cochlea. *Hear Res.* 2000; 144(1-2): 135-146. doi: [10.1016/S0378-5955\(00\)00059-9](https://doi.org/10.1016/S0378-5955(00)00059-9)
56. Cardinaal RM, De Groot JCMJ, Huizing EH, Veldman JE, Smoorenburg GF. Cisplatin-induced ototoxicity: Morphological evidence of spontaneous outer hair cell recovery in albino guinea pig. *Hear Res.* 2000; 144(1-2): 137-156. doi: [10.1016/S0378-5955\(00\)00060-5](https://doi.org/10.1016/S0378-5955(00)00060-5)
57. Laurell G, Bagger-Sjoberg D. Dose-dependent inner ear changes after IV administration of cisplatin. *J Otolaryngol.* 1991; 20(3): 158-167. Web site. <http://europepmc.org/abstract/med/1870163>. Accessed April 14, 2016.