ISSN 2473-4799

Openventio
PUBLISHERS

DERMATOLOGY

Open Journal

| December 2021 | Volume 6 | Issue 1 |

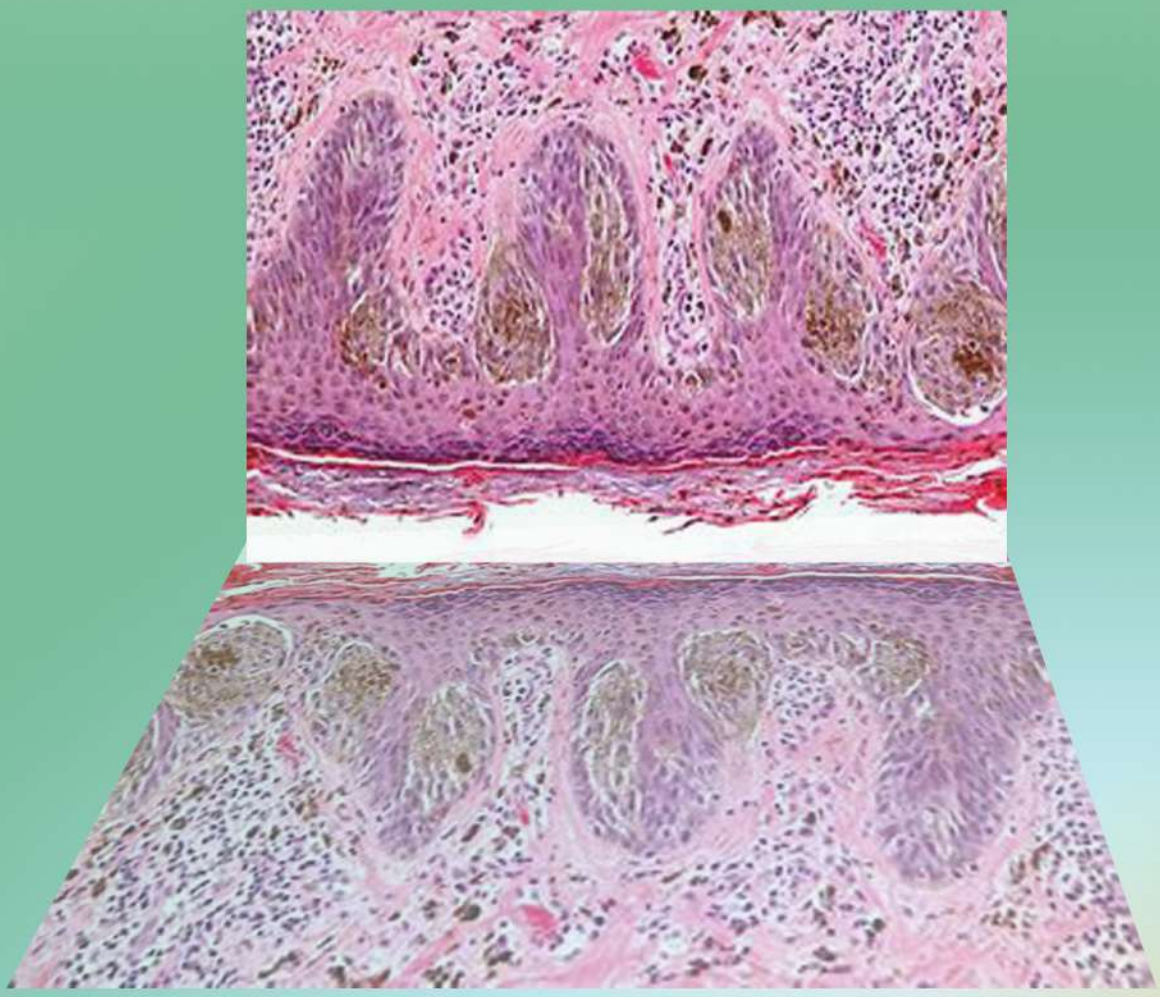

www.openventio.org

ISSN 2473-4799

DERMATOLOGY
Open Journal

Openventio
PUBLISHERS

CONTENTS

Case Series

1. Natural Honey as a Safe and Efficacious Alternative to Skin Grafting Post-Surgical Excision for Necrotizing Fasciitis at Primary Care Level: A Preliminary Study 1-7

   – *Badryia Al Lenjawi, Rasheed Prieiyl, Diovanni Mendoza, Lowlwa Al Meslamani and Hashim Mohamed**

Original Research

2. Clinical Descriptive Study of Psoriasis in India: Triggers, Morbidities and Coincidences 8-14

   – *Piyu P. Naik**

Case Report

3. A Case of Progestogen Hypersensitivity 15-17

   – *Mai Hasegawa, Takasuke Ogawa*, Tatsuo Fukai, Rie Ueki and Shigaku Ikeda*

Case Series

4. The Dermoscopic “Chromosome Arms Sign” for Terra Firma-Forme Dermatosis 18-20

   – *Mario Cutrone, Julie Van Gysel and Ramon Grimalt**

ISSN 2473-4799

DERMATOLOGY
OpenJournal

Openventio PUBLISHERS

Case Series

Natural Honey as a Safe and Efficacious Alternative to Skin Grafting Post-Surgical Excision for Necrotizing Fasciitis at Primary Care Level: A Preliminary Study

Badryia Al Lenjawi, MD[1]; Rasheed Prieiyl, MD[2]; Diovanni Mendoza, MD[1]; Lowlwa Al Meslamani, MD[2]; Hashim Mohamed, MD[3*]

[1]*Hamad Medical Corporation, Doha, Qatar*
[2]*Primary Healthcare Corporation, Doha, Qatar*
[2]*Weill Cornell Medical College-Qatar, Doha, Qatar*

***Corresponding author**
Hashim Mohamed, MD
Associate Professor, Senior Consultant Family Medicine, Weill Cornell Medical College-Qatar, Doha, Qatar; E-mail: fmcc2000@gmail.com

Article information
Received: November 9th, 2020; **Revised:** December 14th, 2020; **Accepted:** December 17th, 2020; **Published:** January 2nd, 2021

Cite this article
Al Lenjawi B, Prieiyl R, Mendoza D, Al Meslamani L, Mohamed H. Natural honey as a safe and efficacious alternative to skin grafting post-surgical excision for necrotizing fasciitis at primary care level: A preliminary study. *Dermatol Open J*. 2021; 6(1): 1-7. doi: 10.17140/DRMTOJ-6-143

ABSTRACT

Necrotizing fasciitis is a soft tissue bacterial infection that spreads rapidly resulting in the destruction of muscles, skin, and underlying tissue. Necrotizing fasciitis is defined as a fast and progressive inflammatory infection of the fascia leading to secondary necrosis of the subcutaneous tissue moving along the facial plane. Fournier gangrene is a type of necrotizing fasciitis involving the scrotum and perineal area. Patients suffering from acute necrotizing fasciitis require an effective regimen which includes surgical removal of devitalized tissues, systemic antimicrobials and mitigating underlying systemic disease processes. The burden of treating wounds following surgical debridement, on the other hand, can be challenging especially in the third world where resources are scarce resulting in suboptimal wound coverage and function. At primary care level we had the opportunity of using natural honey in 5 patients with non-healing wounds in either the lower limb or scrotum due to acute necrotizing fasciitis. This natural non-invasive approach offers a cost-effective and efficacious alternative to dermatotraction, skin grafting and negative pressure wound therapy. In these patients, the use of natural honey led to the restoration of the appearance and function of the fasciotomy wound especially in patients with co-morbidities or those refusing skin grafting due to cost, religious factors, etc. The authors present the clinical results followed by a discussion on the therapeutic properties of natural honey. This case series demonstrates the efficacy of topical raw honey as a catalyst for speeding the healing process by secondary intention thereby offering a safe and efficacious alternative for managing various wounds resulting from acute necrotizing fasciitis.

Keywords
Natural honey; Necrotizing fasciitis; Primary care; Wounds.

INTRODUCTION

Necrotizing fasciitis is considered a life-threatening situation for patients with diabetes and presents a clinical challenge for clinicians worldwide. Necrotizing fasciitis is defined as a fast and progressive inflammatory infection of the fascia leading to secondary necrosis of the subcutaneous tissue moving along the facial plane. Fournier gangrene is a type of necrotizing fasciitis involving the scrotum and perineal area.[1] The main feature of necrotizing fasciitis include an aggressive progressive inflammatory infection involving the fascia complicated by a secondary necrosis of the subcutaneous tissues.[1,2] A variety of surgical procedures and or medical conditions can lead to necrotizing fasciitis including cardiac catheterization[3] and vein sclerotherapy[4]; or it may be idiopathic, as in penile or scrotal necrotizing fasciitis or secondary to contaminated skin wounds. Bacteria responsible for necrotizing fasciitis include aerobic bacteria, anaerobes, or mixed flora.[5] The incidence of necrotizing fasciitis has been increasing due to an increase in patients with immuno compromised status such as those with diabetes mellitus, alcoholism, cancer neutropenia, etc. Patients with diabetes are more prone to have local ischemia, hypoxia and compromised host defenses favoring the development of necrotizing fasciitis. Patients with diabetes are at risk in more than 90% of cases for life-threatening progressive bacterial gangrene. Diabetes is associated with around 20-40% of patients with necrotizing fasciitis and around 80% of those who suffer from Fournier gangrene are people with diabetes. Delayed diagnosis and surgical debridement can lead to huge open wounds, amputations, and even death.

Openventio PUBLISHERS

Standard management entails surgical debridement of necrotic and de vascularized tissue, intravenous antibiotic treatment, and hyperbaric oxygen.[6,7] After the necrotizing fasciitis is tackled and the patient is stabilized medically, attention of health care professionals can then focus on promoting the healing process of the debrided wound. Various options are available for wound closure which include, healing by secondary intention, delayed surgical closure or split-thickness skin grafting. At times some patients may refuse surgical intervention, advanced wound products due to high cost or religious and cultural reasons and as a result they may opt for alternative therapies. This case series demonstrates the efficacy of topical raw honey as a catalyst for speeding the healing process by secondary intention thereby offering a safe and efficacious alternative for managing various wounds resulting from acute necrotizing fasciitis.

CASES

Case 1

History and diagnosis: A 45-year-old Egyptian man with type II diabetes mellitus, presented to the accident and emergency department complaining of a swelling and blistering of posterior neck region. He was afebrile on admission and did not report any history of fever or chills. Outpatient medications included Metformin 500 mg three times a day, Aspirin 100 mg and Esomperazole 40 mg. On physical examination, the patient had a temperature of 99 ºF and the posterior neck region showed a dusky bullous lesions and erythema of 6×7 cm. His fasting glucose was 10 mmol/L, creatinin 95 mmol/L, Glycosylated haemoglobin 7% white blood count was 11.4 with a differential of 89% neutrophils, 11% lymphocytes, 2% monocytes, and 3% bands. An X-ray of the posterior neck region did not demonstrate any presence of subcutaneous air. Based on the clinical examination he was diagnosed as having necrotizing fasciitis and received IV ceftriaxone and clindamycin and the surgical team was consulted.

Treatment: The patient was immediately taken to the operating room for surgical management. Post-operatively, a wet-to-dry dressing was applied to the wound bed and the patient was admitted to the main surgical ward with intravenous ceftriaxone 1 gram daily. When offered a split-thickness skin graft, the patient refused the procedure. Five days later the patient discharged with amoxicillin-calvulanate 625 mg tid for one-week and the patient was told to continue dressing at the health center. On presentation the patient had a wound of 12×10×3 cm with necrotic base (Figure 1A). The decision was made to debride the wound and apply honey impregnated cotton gauze packing into the deep wound space on a daily basis. Basis this amounted to 10 gram per change of dressing. Daily fasting blood glucose levels remained in the range of 7-8 mmol/L during the dressing period Four-weeks later the wound size area decreased by 90% (Figure 1B). Six-weeks later the wound almost healed by 98% (Figure 1C). Post treatment six weeks later the glycosylated haemoglobin level remained at 7% with a fasting glucose level of 7.5 mmol/L.

Figure 1. *A) On Presentation B) Four-Weeks Later Area is Reduced by 90% C) Six-Weeks Later Wound Area is Reduced by 98%*

A B C

Case 2

History and diagnosis: A 55-years-old male Sudanese patient, with type II DM, coronary artery disease, morbid obesity, chronic renal impairment, presented to A/E with fever, myalgia, pain and swelling of his scrotum. The patient denied any history of recent travel, intercourse, preceding genitourinary injury or symptoms or any notable lapses in personal hygiene. The patient was fully conscious but looked ill and in pain, with chills and rigors along with a rectal temperature of 104.3 °F. His blood pressure was 85/50 mmHg, heart rate was 116 beats/min, and respiratory rate was 22 breaths/min along with an oxygen saturation of 99% on room air. His biochemical profile was as follows: fasting glucose level of 12 mmol/L, glycosylated haemoglobin of 11%, creatinin 154 mmol/L. The patient medication to control blood sugar included, Gliclazide 120 mg daily, Pioglitazone 30 mg daily and Glargine basal insulin of 16 units subcutaneously at evening time.

Treatment: On physical examination there was significant erythema, edema, and calor of the scrotum. A provisional diagnosis of Fournier's gangrene was provided, surgical team on call was consulted, followed by rapid intravenous (IV) fluid resuscitation with 5% dextrose normal saline was started along with, IV clindamycin, and ampicillin/sulbactam. His initial A/E investigations were significant for leukocytosis of 13,000/mm^3 and a lactate of 2.3 mEq/L. Subsequently he was transferred to the operating room where anoscopy and cystoscopy showed source of infection or signs of gangerous extension from the bladder or rectum. He underwent surgical debridement of the scrotum with good post-operative recovery. Blood cultures were positive for strains of *Streptococcus pyogens* and *Staphylococcus aureus*. During his hospital stay the wound was dressed with Betadine solution and dry gauze on a daily basis. The wound was not improving in a satisfactory fashion despite his long stay in the hospital which was around three months!. As a result the patient has asked to be discharged home. He was given a follow-up appointment in outpatient clinic after one-week with the option of skin grafting. The patient refused skin grafting and came to Um Gwailinah Health Center for dressing. On presentation the wound was 5×8 cm showing slough and necrotic tissue (Figure 2A) with no signs of infection such as fever, swelling, redness or pain at the wound site.The wound was cleaned with normal saline, natural honey was applied directly on the wound and covered with a petroleum jelly based barrier dressing adaptic be-

Openventio PUBLISHERS

fore being covered by cotton gauze. His fasting glucose level values were in the range of 9-12 mmol/L despite educating him about his diet and exercise and intensifying his basal insulin to 32 units in the evening. The idea of introducing a glycerin based dressing is to prevent natural honey from coming off the wound and being absorbed on the secondary cotton gauze. The honey dressing was changed on a daily basis meanwhile the patient was warned against the possibility of mild stinging sensation due to the acidic nature of honey. Four-weeks later the wound has decreased in size by 70% with health granulation tissue and normal skin (Figure 2B). The patient and staff both expressed satisfaction at the level of progress including the hospital surgeons and advice the patient to continue with the honey dressing. Six-weeks later the wound has healed by 98% (Figure 2C) and one week later there was complete healing (Figure 2D) with no scar formation. His glycosylated haemoglobin level was 11% at the end of the treatment.

Figure 2. *A) On Presentation B) Four Weeks Later Wound Size Reduced by 70% C) Six weeks Later the Wound D) Seven Weeks Later Complete Healing*

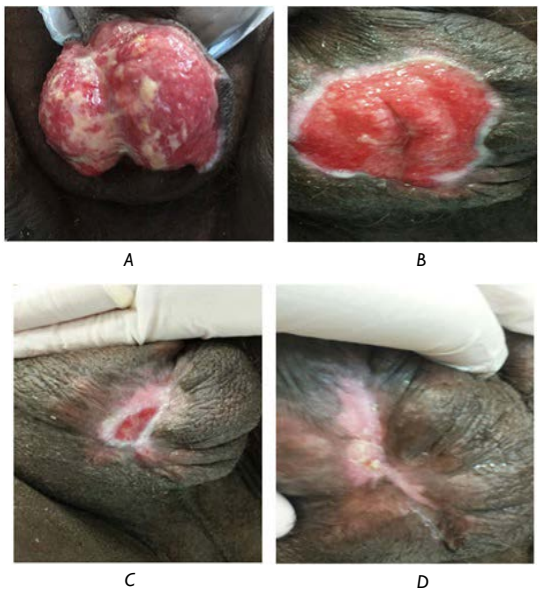

Case 3

A 72-year-old male Sudanese patients with type II diabetes mellitus, hypertension, obesity presented to the accident and emergency department complaining of a swelling and blistering of the dorsum of the right foot. His medications included Gliclazide 60 mg, Atorvastatin 40 mg, Aspirin 100 mg and Sitagliptin 100 mg. On examination the patient had a body temperature of 36.6 °C, blood pressure of 113/70 mmHg, heart rate of 93 beats/min and a respiratory rate of 18/min. Right foot examination revealed a swelling and redness on the dorsum of the foot with palpable crepitus. laboratory findings revealed a white blood cell (WBC) count of 440/mm^3 with 32% polymorphonuclear cells and platelet count of 140,000/mm^3. Serum lactate was 5.8 mmol/L; sodium, total protein/albumin, 3.9/1.6 g/dL; 29 mmol/L; and random blood glucose of 15 mmole/L. The patient had no evidence of coagulopathy with international normalized ratio 1.1 and a prothrombin time of 11.5 seconds. His glycosylated haemoglobin level was 13% at the time of admission to the hospital.

An intensive care unit (ICU) admission was arranged with basal bolus insulin comprising Glargine insulin 32 units subcutaneously at night and rapid acting insulin Aspart 10 units subcutaneously prior to main meals. This was coupled with fluid resuscitation and intravenously administered broad-spectrum antibiotics including teicoplanin (400 mg), metronidazole (1,500 mg) and meropenem (500 mg). The patient was rushed to the operating room, where an incision was made over the dorsum of the right foot and exploration of the fascia revealed an inflamed and necrotic tissue with collection of pus. At the time aerobic and anaerobic cultures were sent for sensitivity and biopsy. Fasciectomy was performed and the fascia was excised sharply, exposing the underlying muscles and tendons (Figure 3A). The patient was stabilized over night and was discharged next day and given an appointment for skin grafting on the 10th post-operative day. Upon presentation the right dorsum of the foot showing extensor digitorum longus tendon, rolled under edges of the wound and blood clots (Figure 3C). On presentation to our health center the wound was cleaned with normal saline, dressed with a total of 20 grams of natural honey and covered with adaptic a petroleum jelly impregnated gauze and a cotton gauze was placed to secure the wound. Fasting glucose level was 9 mmol/L on his first visit. After wards the wound was wrapped and secured with cotton bandage. One-week later the wound started to fill from down upwards with healthy granulation tissue covered with a thin layer of serous fluid with the wound edges attaining a well-defined, attached tissue (Figure 3B). Two -eeks later, the wound reduced by 50% in size with healthy granulation tissue covering the extensor digitorum longus (Figure 3c). The wound has completely healed with no contracture at 4-weeks (Figure 3D). During daily dressing his average fasting blood glucose level was around 8 mmol/L, and his gycosylated haemoglobin levels were 12%.

Figure 3. *A) On Presentation; B) One Week Later Showing Healthy Granulation C) Two Weeks Later Wound is Reduced the Wond is Reduced by 50% D) Four-Weeks Later Complete Healing is Evident with No Contracture*

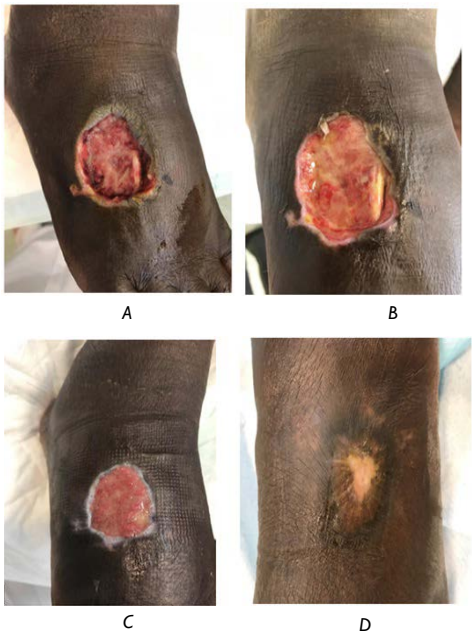

Case 4

A 58-years-old male with type II diabetes, hypertension, obesity, diabetic retinopathy, peripheral neuropathy and chronic heavy smoker smoking 20 cigarettes per day for the last 30-years. The patient was diagnosed with necrotizing fasciitis and had surgery performed on his right lower limb and had been dressing his wound in the main hospital inpatient wound clinic for the last three-months prior to his presentation to our health center. On presentation to our health center the patient had a fasting glucose level of 12 mmol/L, creatinin 170 mmol/L and a glycosylated haemogobin of 10%. His daily regimen included, Gliepiride 6 mg daily, Pioglitazone 15 mg daily and Vildagliptin 50 twice daily, Clopidogrel 75 mg and Rosuvastatin 10 mg daily. The attending family physician looking after the wound had decided to intensify his medications by introducing basal insulin (Glargine) 14 units subcutaneously at night and introducing bolus insulin 10 units subcutaneous before each main meal. On examination the wound had a lot of necrotic tissue, slough and was extending from above the medial malleolus and extending down to the dorsal aspect of the right foot (Figure 4A). The whole lower limb was washed with the antiseptic solution Chlorhexidine Gluconate 4% from the anterior tuberosity to the toes. Afterwards the wound was washed with normal saline and necrotic tissue was debrided using a surgical blade (Figure 4A). Post-debridement the wound had around 10 gram of natural honey applied to it and covered with (Adaptic™) which is a primary non-adhering dressing composed of petroleum jelly impregnated knitted cellulose acetate fabric. This dressing works as a barrier keeping honey in the wound bed and preventing it from being absorbed onto the secondary cotton gauze which is directly applied over it to secure the wound. Thereafter, the wound was covered with cotton bandage and the patient was scheduled for daily change of the dressing. One month later the wound had reduced by 50% in size (Figure 4B). The patient had continued to attend on a daily basis, however on one occasion the wound has developed a greenish color discharge which was considered *pseudomonas aeruginosa* and a swab was taken and sent for culture and sensitivity which was positive for *pseudomonas aeroginosa*. Meanwhile the wound was irrigated on a daily basis with 1% acetic acid in order to clear the contaminated wound bed followed by normal saline. *Pseudomonas aeruginosa* is inhibited by the application of 1-5% acetic acid concentration *via* lowering the pH of the wound thereby inhibiting the growth of bacteria including *pseudomonas aeruginosa*. The acetic acid irrigation was continued for another week till no more green discharge is seen. Post-irrigation another wound swab was taken which showed no growth. Two-months later the wound has reduced by 75% (Figure 4C). The patient started to come only once every three-days as his work was not allowing him to go for daily dressing. Three months later the wound has almost healed with 97% reduction in size and normal skin formation with no contracture (Figure 4D). The patient managed to attain a glycosylated haemoglobin of 8% and an average fasting glucose of 8 mmol/L after intensifying his therapy at the three-month follow-up appointment but unfortunately, the patient did not show up for further inspection and dressing.

Figure 4. *A) On Presentation the Wound had been Debrided as Seen by Bleeding Grooves in the Wound B) Wond Size Reduction by 50% C)Wound size Reduction by 75% with Evident with New Skin Formation D) Wound almost Healed with 97% Reduction*

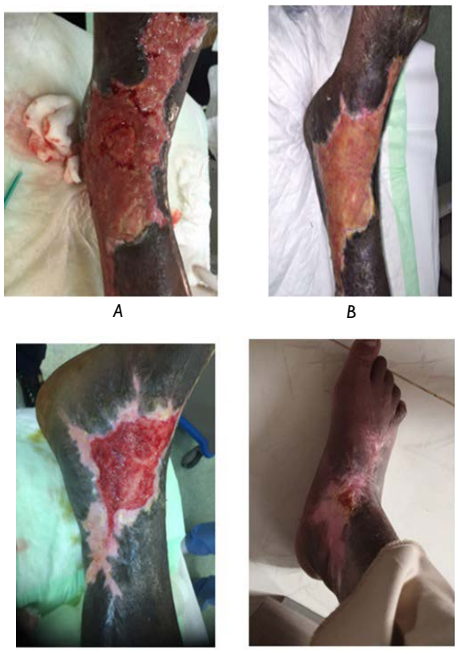

Case 5

A 62-years-old male with hypertension, type II diabetes, diabetic nephropathy, obesity, hyperlipidemia, diabetic retinopathy, peripheral neuropathy presented to our health center after being discharged from the main hospital. His medications were as follow Metformin-Sitaglptin 100/50 mg twice daily, Pioglitazone 15 mg daily and Dapagliflozin 10 mg daily, Atorvastatin 80 mg daily and Aspirin 100 mg daily. His biochemical profile was as follows: fasting glucose level of 7.5 mmol/L, glycosylated haemoglobin of 8%, creatinin 100 mmol/L. The patient was diagnosed with necrotizing fasciitis and had surgery performed on his left lower limb extending from above the ankle joint anteriorly down to the dorsum of the left foot. The patient left the hospital and was asked to do daily dressing at the health center with the plan of having s kin flap in two-weeks time. On inspection the wound is showing lower, extensor retinaculum and anterior tibial tendon, and extensor digitorum brevis, slough, necrotic tissue, extending down to the dorsal aspect of the left foot (Figure 5A). The wound did not show any signs of infection such as erythema, foul smell, swelling, tenderness and as result no antibiotics were prescribed. The wound was irrigated with normal saline followed by debridement of necrotic tissue using a surgical blade followed by application of natural honey to the wound area and covered with (Adaptic™) a petroleum jelly impregnated dressing. Thereafter, the wound was covered with cotton bandage with a daily change schedule. One-month later the wound had decreased in size by 90% in size (Figure 5B) with complete healing achieved six-weeks later (Figure 5C). Post-healing his average fasting glucose was 7% and his glycosylated haemoglobin remained at 8%.

Openventio PUBLISHERS

Figure 5. *A) A Wound Showing Extensive Slough Necrotic Tissue and Exposed Tendons B) 90% Reduction in 4-Weeks C) Complete Healing without Contracture*

Mechanism of Action of Honey

A broad spectrum of wounds including burns, acute and chronic wounds, psoriasis, pressure ulcers and chronic diabetic foot ulcers have been successfully treated by honey.[8-12] Although, in the medical literature, its wound healing properties is exclusively related to its antibacterial activity, nonetheless honey has anti-inflammatory as well as immunomodulatory properties which clearly aids in the healing process of various types of wounds and skin conditions including being an efficacious alternative to skin grafting.[13] Depending on wound conditions, honey being present in the wound environment is able to either stimulate or inhibit the release of the various cytokines including tumor necrosis factor-α, interleukin-1β, interleukin-6) from macrophages and human monocytes.[14] Additionally, in the presence of honey fibroblasts, human keratinocytes, are positively affected leading to cell-proliferation and migration, chemotaxis and collagen matrix production, ultimately leading to reepithelization and wound closure. Honey also releases H_2O_2 at 1:1000 concentration adequate enough to kill pathogens without compromising the healthy granulating cells, provides adequate amount of moisture without leading to dryness or maceration, vitamins and provides a sound barrier against external pathogens.[15-17] Honey also aids in wound healing by providing a low pH, anti- inflammatory action and an osmotic gradient just enough to dehydrate the bacterial cell wall without compromising the cellular matrix of wounds.[18,19] The amount of honey placed on various wounds depended on the size of the wound, however, the investigator applied enough amount to cover the whole surface area of the wound. The purity of honey was established through the food laboratory of the Ministry of Health which confirmed its purity, lack of bacterial spores (including botulism toxins), fungi and viruses. The water content was 14% with 35% fructose, 25% glucose and 26% sucrose.

Necrotizing fasciitis is characterized by lack of specific symptoms and lack of reliable laboratory parameters therefore it is imperative that patients with suspected signs and symptoms of necrotizing fascitis be rushed to the operating room. Mortality rate varies from 6% when patients undergo operation within 12 h of onset of signs and symptoms, but rises to 30% after 24 h.[20] It is recommended that the first surgical intervention should aim at removing all of the necrotic tissue.[21-25] However, at times several surgical debridement may be necessary with the use of a vacuum-assisted closure device (VAC) in between where the patient is possibly booked for a flap surgery at alter stage.[23] Various alternative therapeutic options have been including intravenous immunoglobulin and hyperbaric oxygen, however, their efficacy remains controversial.[22] Unfortunately not every patient can afford to have the commodity of a skin flap surgery especially in the World and War III stricken regions where resources are scarce and plastic surgery is considered a luxury. In these circumstances natural honey can replace flap surgery since it stimulates the growth and proliferation of fibroblasts even on fibrous tissues such the plantar aponeurosis.[13] Furthermore, honey exerts its action primarily by two actions. First, it increases vascularity and wound bed cell growth through angiogenesis acting as a Natural VAC System whereby it speeds the healing process especially in deep wounds. Honey used in deep wounds must be used *via* impregnating cotton gauze with it and the clinician must make sure the wound dressing material (honey impregnated cotton gauze) fills the wound bed in order to stimulate cells to grow against resistance.[13] Second, honey may act as natural skin flap offering a viable alternative to classical skin flap especially when patients cannot afford it, refuse having operation, or have multiple comorbidities precluding them from benefiting from it. Honey's ability to replace skin flap is related to its ability to stimulates angiogenesis, epithelial cell growth, fibroblast growth and ultimately tissue regeneration with minimal hypertrophy and scarring. The majority of surgical incisions heal by primary intention, i.e. stitches or clips are used to close together the edges of a surgical incision until the cut edges merge. Healing by secondary intention is said to occur when an open wound begins to heal from the base upwards, through the formation of new tissue. Many types of dressings and topical agents are available in the market but few have been rigorously evaluated in randomized clinical trials. Many clinical studies have demonstrated the efficacy of honey in the treatment of a variety of wounds including burns,[26] diabetic foot ulcers,[27] pressure injuries,[28] ostomy wounds,[29] cancerous wounds,[30] radiation burns[30] along with dermatological cases including palmo-plantar psoriasis,[22] seborrhoeic dermatitis,[31] and acne vulgaris.[32] Recent meta-analysis has shown the superiority of honey compared to conventional therapies in relation to burns[33] and diabetic foot ulcers specifically.[34] Healing by secondary intention is an often underused and underestimated reconstructive modality. Spontaneous healing versatility becomes ostensible when it is adopted to heal previously repaired wounds complicated by infection, dehiscence, and graft loss or flap necrosis.

Zitelli[35] has confirmed statistically through his clinical trial that moist environment accelerates re-epithelization which is the main component of healing by secondary intention, as a result he suggested the use of antibacterial ointment to minimize desiccation, pain and necrosis. Raw honey offers a safe and efficacious alternative to antibacterial ointments and petroleum based products since it has almost 16% of its content as water produces hydrogen peroxide, flavanoids, minerals, vitamins, stimulates angiogenesis *via* its osmotic gradient and promotes epithelization.

Limitation of the Studies

Most studies addressing the use of honey in clinical settings had

small number of participants, lacked double blinding, originated from single centers and lacked long-term follow-up. These factors can be attributed to the fact that health establishments are used to utilizing advanced wound products much of which lack rigorous scientific basis for their efficacy and depend on intensive marketing targeting health professionals mainly wound care specialists worldwide. Additionally, health care professionals are usually skeptic about the use of complementary and alternative medicine (CAM) due to the fact tat most medical and nursing schools fail to include (CAM) into their curricula and worse still health care professionals utilizing (CAM) are not supported with grants when it comes to undertaking multi-center randomized clinical trials.

CONCLUSION

Natural raw honey use in wounds post-fasciotomy may offer a viable alternative especially in the third world where resources are scarce, however, a randomized controlled trial involving a comparative group with the use of advanced wound product is needed to confirm such a conclusion.

CONSENT

The authors have received written informed consent from the patient.

CONFLICTS OF INTEREST

The authors declare that they have no conflicts of interest.

REFERENCES

1. Misiakos EP, Bagias G, Patapis P, Sotiropoulos D, Kanavidis P, Machairas A. Current concepts in the management of necrotizing fasciitis. *Front Surg*. 2014. 1: 36. doi: 10.3389/fsurg.2014.00036

2. Hakkarainen TW, Kopari NM, Pham TN, Evans HL. Necrotizing soft tissue infections: Review and current concepts in treatment, systems of care, and outcomes. *Curr Probl Surg*. 2014; 51(8): 344-362. doi: 10.1067/j.cpsurg.2014.06.001

3. Federman DG, Kravetz JD, Kirsner RS. Necrotizing fasciitis and cardiac catheterization. *Cutis*. 2004; 73(1): 49-52.

4. Chan HT, Low J, Wilson L, Harris OC, Cheng AC, Athan E. Case cluster of necrotizing fasciitis and cellulitis associated with vein sclerotherapy. *Emerg Infect Dis*. 2008; 14(1): 180-181. doi: 10.3201/eid1401.070250

5. Kihiczak GG, Schwartz RA, Kapila R. Necrotizing fasciitis: A deadly infection. *J Eur Acad Dermatol Venereol*. 2006; 20(4): 365-369. doi: 10.1111/j.1468-3083.2006.01487.x

6. Urschel JD. Classic diseases revisited: necrotizing soft tissue infections. *Postgrad Med J*. 1999; 75: 645-649.

7. Perry B, Floyd WE. Gas gangrene and necrotizing fasciitis in the upper extremity. *J Surg Orthop Adv*. 2001; 13(2): 57-68.

8. Mohamed H, Salma MA, Allenjawi B, Barakat N, Gouda Z, Abdi S, et al. Natural honeyas an adjunctive alternative in the management of diabetic foot ulcers. *Wound Practice and Research*. 2012; 20(4). 212-216.

9. Mohamed H, El Lenjawi B, Salma MA, Abdi S. Honey based therapy for the management of a recalcitrant diabetic footulcer. *J Tissue Viability*. 2014; 23(1): 29-33. doi: 10.1016/j.jtv.2013.06.001

10. Mohamed H, Salma MA, AL-Lenjawi B, Mohammad A, Jouda Z, Abdi S, et al. Enhancing primary healing post ray amputation in a diabetic patient: Efficacy of natural honey. *The Journal of Diabetic Foot Complication*. 2014; 6(2): 13-18.

11. Mohamed H, Salma MA, Al-Lenjawi B, Abo Gouda Z, Hussain Z, Al-Majid S, et al. Efficacy of natural honey in the management of second degree burn complicated by acute dermatitis in a diabetic patient. *J Diabetes Metab*. 2014; 5: 5.

12. Salma MA, Abo Salama M, Al-Lenjawi B, Hassan I.Using honey in post-excision malignant melanoma ulcers. *Journal of Lymphoedema*. 2012; 7(1): 41-44.

13. Majtan J. Honey: An immunomodulator. *Wound Repair Regen*. 2014; 22: 187-192. doi: 10.1111/wrr.12117

14. Mohamed H, Salma MA, Al-Lenjawi B, Abdi S, Gouda Z, Barakat N, et al. The efficacy and safety of natural honey on the healing of foot ulcers: A case series. *Wounds*. 2015; 27(4): 103-114.

15. Mohamed H, Abo Salma M, Al-Lenjawi B, Abo Gouda Z, Hussain Z. The efficacy of natural honey in the management of second degree burn complicated by acute dermatitis in a diabetic patient. *J Diabetes Metab*. 2014; 5(373): 1000373. doi: 10.4172/2155-6156.1000373

16. Al-Lenjawi B, Mohamed H, Salma MA, Gouda ZA. Natural honey in the management of thermal burn of the foot in a type 2 diabetic patient: A case report. *Dermatol Open J*. 2016; 1(1): 14-18. doi: 10.17140/DRMTOJ-1-105

17. Mohamed H. Successful healing of diabetic foot ulcers and various etiology ulcers with natural honey: An alternative paradigm in wound healing. *J Diab Rel Dis*. 2016; 1(1): 107. doi: 10.5812/ircmj.41939

18. Samarghandian S, Farkhondeh T, Samini F. Honey and health: A review of recent clinical research. *Pharmacognosy Res*. 2017; 9(2): 121-127. doi: 10.4103/0974-8490.204647

19. Al-Meslamani L, Al-Lenjawi B, Al-Majid S, Mohamed H. Palmoplantar psoriasis successfully treated with raw natural honey: A case report. *Dermatol Open J*. 2019; 4(1): 1-6. doi: 10.17140/DRMTOJ-4-133

20. Wong C-H, Chang H-C, Pasupathy S, Khin L-W, Tan J-L, Low

C-O. Necrotizing fasciitis: Clinical presentation, microbiology and determinants of mortality. *J Bone Joint Surg Am*. 2003; 85-A: 1454-1460.

21. Elliott DC, Kufera JA, Myers RA. Necrotizing soft tissue infections. Risk factors for mortality and strategies for management. *Ann Surg*. 1996; 224: 672-683. doi: 10.1097/00000658-199611000-00011

22. Anaya DA, Dellinger EP. Necrotizing soft-tissue infection: diagnosis and management. *Clin Infect Dis*. 2007; 44: 705-710. doi: 10.1086/511638

23. Heitmann C, Pelzer M, Bickert B, Menke H, Germann G. [Surgical concepts and results in necrotizing fasciitis]. *Chirurg*. 2001; 72: 168-173. doi: 10.1007/s001040051287

24. Nagoba B, Wadher B, Kulkarni P, Kolhe S. Acetic acid treatment of pseudomonal wound infections. *Eur J Gen Med*. 2008; 5: 104-106. doi: 10.29333/ejgm/82586

25. Greener B, Hughes AA, Bannister NP, Douglass J. Proteases and pH in chronic wounds. *J Wound Care*. 2005; 14: 59-61. doi: 10.12968/jowc.2005.14.2.26739

26. Zbuchea A. Up-to-date use of honey for burns treatment. *Ann Burns Fire Disasters*. 2014; 27(1): 22-30.

27. Shukrimi A, Sulaiman AR, Halim AY, Azril A. A comparative study between honey and povidone iodine as dressing solution for wagner type II diabetic foot ulcers. *Med J Malaysia*. 2008; 63(1): 44-46.

28. Jull AB, Cullum N, Dumville JC, Westby MJ, Deshpande S, Walker N. Honey as a topical treatment for wounds. *Cochrane Database Syst Rev*. 2015; (3): CD005083. doi: 10.1002/14651858.CD005083.pub4

29. Lund-Nielsen B, Adamsen L, Gottrup F, Rorth M, Tolver A, Kolmos HJ. Qualitative bacteriology in malignant wounds— a prospective, randomized, clinical study to compare the effect of honey and silver dressings. *Ostomy Wound Management*. 2011; 57: 28-36.

30. Shoma A, Eldars W, Noman N, Saad M, Elzahaf E, Abdalla M, et al. Pentoxifylline and local honey for radiation-induced burn following breast conservative surgery. *Curr Clin Pharmacol*. 2010; 5(4): 251-256. doi: 10.2174/157488410793352021

31. Mohammed HA, Al-Lenjawi B, Mendoza D. Seborrheic dermatitis treatment with natural honey. *Wounds International*. 2018; 9: 36-38.

32. Eady EA, Layton AM, Cove JH. A honey trap for the treatment of acne: Manipulating the follicular microenvironment to control. Propionibacterium acnes in Human Health and Disease [Special Issue]. *Bio Med Research International*. 2013; doi: 10.1155/2013/679680

33. Wijesinghe M, Weatherall M, Perrin K, Beasley R. Honey in the treatment of burns: a systematic review and meta-analysis of its efficacy. *N Z Med J*. 2009; 122(1295): 47-60.

34. Wang C, Guo M, Zhang N, Wang G. Effectiveness of honey dressing in the treatment of diabetic foot ulcers: A systematic review and meta-analysis. *Complement Ther Clin Pract*. 2019; 34: 123-131. doi: 10.1016/j.ctcp.2018.09.004

35. Zitelli JA. Wound healing by secondary intention. A cosmetic appraisal. *J Am Acad Dermatol*. 1983; 9(3): 407-415. doi: 10.1016/s0190-9622(83)70150-7

ISSN 2473-4799

DERMATOLOGY
OpenJournal

Openventio PUBLISHERS

Original Research

Clinical Descriptive Study of Psoriasis in India: Triggers, Morbidities and Coincidences

Piyu P. Naik, MD*

Department of Dermatology, Saudi-German Hospitals and Clinics, Dubai, UAE

***Corresponding author**
Piyu P. Naik, MD
Department of Dermatology, Saudi-German Hospitals and Clinics, Dubai, UAE; Tel. +971562173323; ORCID: 0000-0002-6499-4062; E-mail: drpiyu85@gmail.com

Article information
Received: April 25th, 2021; **Revised:** June 15th, 2021; **Accepted:** June 18th, 2021; **Published:** June 21st, 2021

Cite this article
Naik PP. Clinical descriptive study of psoriasis in India: Triggers, morbidities and coincidences. *Dermatol Open J.* 2021; 6(1): 8-14. doi: 10.17140/DRMTOJ-6-144

ABSTRACT

Background
Psoriasis is a T-cell mediated chronic inflammatory, a papulosquamous disease involving complex interactions between the innate and adaptive immune system and commonly manifested by skin lesions. It is characterized by hyperproliferation of keratinocytes and inflammatory infiltration in the epidermis and dermis. Chronic psoriasis can be a risk factor for developing comorbid diseases that share common immune pathophysiology and can be triggered by environmental factors in genetically susceptible individuals.

Aim
To study the clinico-demographic profile, determine the most common triggering factors and determine comorbidities' coexistence in patients with psoriasis at a tertiary care centre.

Study Design
A cross-sectional study.

Methods
A teaching hospital-based cross-sectional study including 231 psoriasis patients visiting skin outpatient department (OPD) was conducted by the dermatology departmentat Sri Krishna hospital, Karamsad, India following acceptance of the study proposal by the human research ethics committee. This study was outcome of the dissertation topic of the author during dermatology residency. Total 5 qualified dermatologists working in the dermatology department and 3 resident doctors took part in the study as evaluators. After taking informed consent, detailed history regarding aggravating factors, progress and morbidities was taken with clinical examinations, and the diagnosis was purely clinical. Data were analysed using statistical package for the social sciences (SPSS).

Result
Our study revealed a peak incidence of psoriasis in the fourth and fifth decade of life with male preponderance (1.9:1). The most commonly found psoriasis type was psoriasis vulgaris, and chronic plaque psoriasis and the most common site of involvement was extensors and trunk. Pruritis was the most disabling complaint (91.34%), and the disease course was progressive. Aggravating factors included stress, winter season, implant insertion, smoking, alcohol consumption, tobacco chewing and obesity. Koebner phenomenon was commonly found with implant insertion in psoriasis patients (76.2%). Family history was one of the well established risk factors for developing psoriasis (14.2%). Our study's most commonly found nail changes were pitting (35.49%) and dystrophic changes (18.61%). Palmoplantar keratoderma (4.76%) and vitiligo (4.76%) were the most commonly found dermatological condition with psoriasis and have been associated with various comorbidities such as cardiovascular disorder, metabolic syndrome, psoriatic arthritis and psychiatric disorders. As it was a cross-sectional study, no controls were used.

Conclusion
The study shows male preponderance and extensors, trunk as common sites of psoriatic lesion presentation. Aggravating factors included stress, winter season, implant insertion, smoking, alcohol consumption, tobacco chewing and obesity. Screening is encouraged for symptoms of psoriatic arthritis, cardiovascular diseases and metabolic syndromes in psoriasis patients due to its predilection with systemic comorbidities.

Keywords
Psoriasis; Comorbidities; Cardiovascular disease; Metabolic syndrome; Risk factor; Triggers.

Openventio PUBLISHERS

INTRODUCTION

Psoriasis is a non-contagious chronic inflammatory papulosquamous skin disease characterized by sharply demarcated erythematous plaques with a whitish scale.[1,2] Psoriasis can appear at any age, but two peaks of onset are the third and fifth decades of life.[3-6] It has affected 125 million people worldwide and significantly impacts the physical and emotional quality of life.[7-9] Psoriasis has a polygenic inheritance pattern with multiple alleles being encoded by a single gene resulting in multi-focal disease manifestations.[10-14]

Epidermal proliferation is the earliest pathogenic feature in psoriasis. There is an increase in deoxyribonucleic acid (DNA) synthesis and mitotic activity in the basal layer. The cells rapidly divide, move to the surface and shed as incomplete keratinized scales.[15-17] Migration of neutrophils into epidermis and collection in subcorneal spaces leads to micro-abscesses formation.[18-20] Cluster of differentiation 4 (CD4+) and CD8+ T-cells found in the epidermis and dermis play an essential role in developing cutaneous lesions by releasing T helper type 1 (Th1)/Th17 mediators like interferon-gamma (IFN-γ), interleukin 2 (IL2), IL17, IL23 and TNF-α, which acts on keratinocytes.[21-23]

Differences in the prevalence of psoriasis in various countries suggest genetic and environmental factors affecting the onset of this condition.[24,25] The *primary susceptibility locus of psoriasis is psoriasis susceptibility gene 1* (*PSORS 1*) in the major histocompatibility complex on chromosome 6p21.[26-28] In genetically susceptible individuals, several exogenous factors such as skin aggression, infection, stress, alcohol and drugs and endogenous factors like allergies and hormonal changes can trigger the eruption.[29-34]

Classically associated comorbidities with psoriasis which are described in literature are psoriatic arthritis, Crohn's disease, uveitis and psychiatric disorders. Newly emerging comorbidities associated with psoriasis are metabolic syndrome, cardiovascular disease, erectile dysfunction, celiac disease, nonalcoholic fatty liver disease (NAFLD), osteoporosis and Parkinson's disease.[35-38] Association between psoriasis and diabetes was first reported by Strauss in 1897, followed by Reed et al in 1961, who observed an association between psoriasis and heart disease.[39,40]

MATERIALS AND METHODS

This was a teaching hospital-based cross-sectional study conducted for two-years. A total of 231 patients visiting dermatology outpatient department (OPD) in tertiary care centres of Charutar Arogya Mandal, India were recruited for this study. The study proposal was approved by the human research ethics committee, and informed written consent was taken from the study participants.

Detailed history regarding triggering factors, disease progression, and associated co-morbidities and socio-demographic information was recorded. Disease diagnosis was purely clinical. Data were analysed using statistical package for the social sciences (SPSS).

RESULTS

Based on the data analysis of 231 study participants, the majority of the affected patients were males (66.23%) with a peak incidence in the fourth (23.38%) and fifth (22.51%) decades of life (Table 1). Among the study subjects, 12.21% had psoriasis Vulgaris and 9.95% presented with chronic plaque psoriasis. Other types of psoriasis observed were guttate (1.73%), palmoplantar (1.73%), inverse (1.73%), psoriatic erythroderma (1.73%), scalp psoriasis (0.86%), elephantine psoriasis (1.29%), single plaque psoriasis (1.29%) and plantar psoriasis (0.43%).

Table 1. *Age Group and Gender Distribution of Study Subjects with Psoriasis*

Age Group (in Years)	Male	Female	Total
0-10	3 (1.96%)	5 (6.41%)	8 (3.46%)
11-20	10 (6.54%)	12 (15.38%)	22 (9.52%)
21-30	17 (11.11%)	19 (24.36%)	36 (15.58%)
31-40	41 (26.80%)	13 (16.67%)	54 (23.38%)
41-50	37 (24.18%)	15 (19.23%)	52 (22.51%)
51-60	28 (18.30%)	10 (12.82%)	38 (16.45%)
>61	17 (11.11%)	4 (5.13%)	21 (9.09%)
Total	153 (66.23%)	78 (33.77%)	231 (100%)

Collected data showed most common sites involved for psoriatic skin lesions were the lower limbs (77.48%) and upper limbs (67.53%), while genitals (9.95%) were least frequently involved. Frequencies of involvement of rest body sites were described in Figure 1.

Figure 1. *Frequencies of Body Site Involvement by Psoriatic Skin Lesions in this Study*

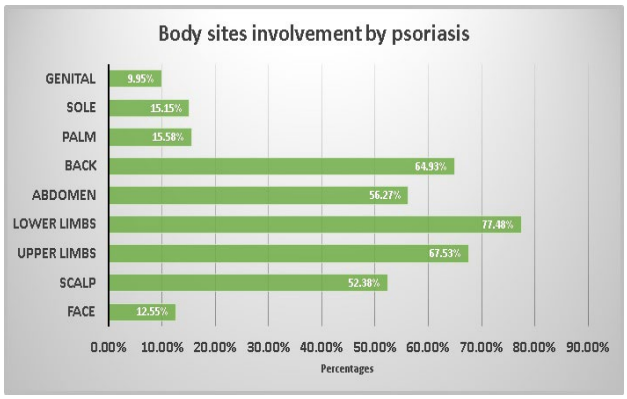

88.74% reported the course of the disease as progressive. 48.05% affected individuals belonged to the middle class based on socioeconomic status and occupation were farmer (22.20%), labourer (22.87%), businessman (15.69%) and private sector (16.99%).

Disease triggering factors involved smoking (32.9%), alcohol (15.2%), tobacco (24.2%), itching (91.34%), winter season (70.12%) and stress (51.08%). Koebner phenomenon was ob-

served in patients with history of any implant insertion in 57.14% of subjects with significant correlation (Table 2).

Table 2. *History of Implant Insertion and its Correlation with Koebner Phenomenon*

Koebner phenomenon	History of implant insertion in body		Total
	No	Yes	
No	96 (44.04%)	3 (23.08%)	99 (42.86%)
Yes	122 (55.96%)	10 (76.92%)	132 (57.14%)
Total	218 (94.28%)	13 (5.62%)	231 (100%)

34.19% of the patients undertook allopathic treatment for psoriasis, while others underwent treatment using alternate medicine courses such as Ayurveda, homeopathy or combination (Figure 2).

Figure 2. *Mode of Treatment Opted during the Course of Disease*

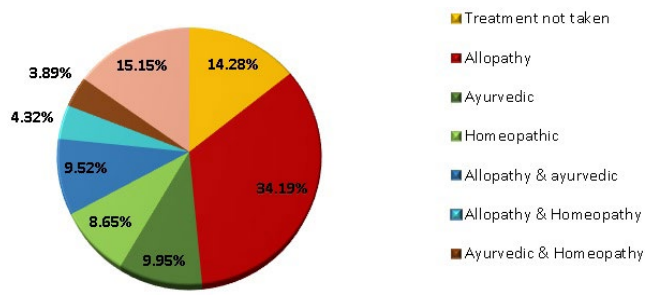

Patient history revealed 28.44% were antihypertensive medications. Other drugs taken by subjects included non-steroidal anti-inflammatory drugs (NSAIDs) (18.34%), lipid-altering agent (13.76%), steroids (11.92%), anti-diabetics (8.25%), anti-psychotic (6.42%), anti-thyroid (5.5%) and drugs for chronic obstructive pulmonary disease (COPD) (7.3%).

85.28% of patients reported no family history of psoriasis, while 14.42% were genetically predisposed, and among them, 12.13% had first-degree relatives with psoriasis.

Types of joint affected in psoriatic patients were knee joint (20.34%), peripheral mono or asymmetrical oligoarticular (14.71%), distal interphalangeal (11.68%) and axial affection (2.16%).

Nail and oral changes in psoriasis patients are depicted in Table 3 and Figure 3.

Table 3. *Nail Changes in Psoriasis Patients*

Nail changes	Hand nail (Number %)	Foot nail (Number %)
Pitting	82 (35.49%)	41 (17.74%)
Onycholysis	13 (5.62%)	5 (2.16%)
Subungual hyperkeratosis	13 (5.62%)	18 (7.79%)
Salmon patch	3 (1.29%)	0
Onychomycosis	26 (11.25%)	15 (6.49%)
Transverse ridges	10 (4.32%)	9 (3.89%)
Vertical bands	22 (9.52%)	15 (6.49%)
Beaus line	7 (3.03%)	9 (3.89%)
Dystrophic changes	15 (6.49%)	43 (18.61%)
Leukonychia	2 (0.86%)	0
Pincer nail	1 (0.43%)	1 (0.43%)
Pterygium	2 (0.86%)	0
Twenty nail dystrophies	2 (0.86%)	2 (0.86%)
Koilonychia	4 (1.73%)	1 (0.43%)

The most common systemic comorbidity identified in these psoriasis patients is hypertension which was observed in 9.95% of subjects. Other notable comorbidities observed were COPD, hypercholesterolemia, diabetes mellitus (DM), thyroid disorder, depression, renal calculi, ischemic heart disease (IHD), pleural effusion and tuberculosis, glaucoma, vocal cord carcinoma, lower respiratory tract infection (LRTI), Vitamin A deficiency, anaemia, piles, hepatitis and multiple fractures with kyphoscoliosis (Table 4). The most common dermatological condition found in psoriasis patients is palmoplantar keratoderma (4.76%), followed by vitiligo (4.76%).

Figure 3. *Frequency of Oral Changes in Psoriasis Patients*

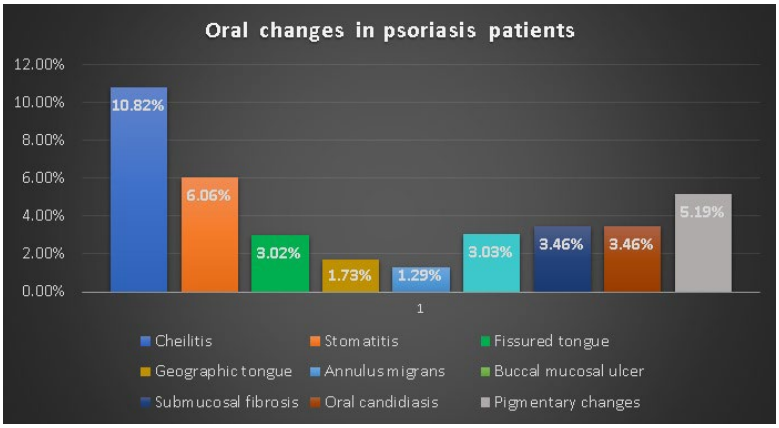

Openventio PUBLISHERS

Table 4. *The Systemic Conditions Identified with Psoriasis in the Study Population*

Systemic Condition	Percentage
Hypertension	9.95%
Chronic obstructive pulmonary disease	3.03%
Hypercholesterolemia	3.03%
Diabetes mellitus	3.03%
Thyroid disorder	2.16%
Depression	1.29%
Renal calculi	1.29%
Ischemic heart diseases	0.86%
Pleural effusion and tuberculosis	0.43%
Glaucoma	0.43%
Vocal cord carcinoma	0.43%
Lower respiratory tract infection	0.43%
Vitamin A deficiency	0.43%
Anaemia	0.43%
Piles	0.43%
Hepatitis	0.43%
Multiple fractures with kyphoscoliosis	0.43%

Another dimension of this study was to see the prevalence of human leukocyte antigen (HLA)-B57 alley in these psoriasis patients. HLA-B57 was positive in 83 patients (35.93%) out of 231 total cases. Infect, of all 113 cases of psoriasis with arthropathy, 69 patients (61.06 %) showed presence of HLA-B57.

Fetching the ultrasonography abdomen data also revealed interesting findings. One hundred ninety-six (196) patients were screened by ultrasound scanning of upper abdomen for presence of non-alcoholic fatty liver disease in all of these psoriasis cases after asking details of alcohol consumption. Rest 35 cases gave history of seldom alcohol intake, so they were excluded of this section of study. One hundred and seventy-three (173) cases out of 196 screened showed variable degrees of NAFLD (Figure 4).

Figure 4. *Prevalence of Non-alcoholic Fatty Liver Disease in Study Population*

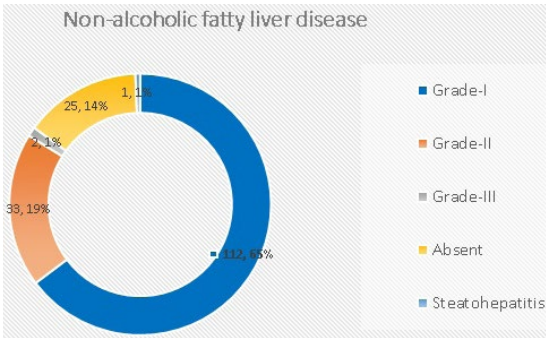

DISCUSSION

The prevalence of psoriasis varies across different countries, suggesting the influence of ethnicity, genetic background and environmental factors on the disease onset. As per the reports published across the world, prevalence varied from 0 to 11.8%. The prevalence of psoriasis in the USA and Canada were 4.6% and 4.7%, respectively.[41] Hospital-based studies done by Okhandiar et al[41] stated that psoriasis' incidence ranged between 0.44 and 2.2%. The report also speculated that extreme temperature, genetic background and dietary habits might be associated with the incidence of psoriasis. Our study showed male to female ratio as 1.9:1, male preponderance was noted in a study conducted by Okhandiar et al[41] and Bedi[42] who noted the male to female ratio as 2.46:1 and 2.5:1, respectively.

The peak incidence of disease onset is fourth and fifth decades of life in our study, and similar results were observed in studies conducted in the Faroe Islands and Denmark[3,4] and the studies done in North India by Okhandiar et al[41] and Bedi[42]. However, psoriasis with onset prior to the age of 40-years is linked with genetic susceptibility and recurrent as well as severe course.[43]

The role of genetic predisposition in psoriasis' etiopathogenesis has been observed in studies reported by Faber et al.14.42% were genetically predisposed, and among them, 12.13% had first-degree relatives with psoriasis based on the reports collected in our study, and familial incidence was also seen in data published by Bediand Kaur et al.[42-44]

Clinical classification of psoriasis can be broadly classified into non-pustular and pustular psoriasis with different clinical phenotypes of each, and the most common clinical type is classic chronic plaque-type psoriasis. Precise clinical recognition of subtype is essential to reflect upon disease activity and choice of treatment. In our study, most of the patients presented with chronic plaque-type psoriasis, and similarly, data analysed by Bedi[42] of 530 psoriasis patients revealed that 90% had chronic plaque phenotype. The most common sites of involvement were trunk and limbs in our study and the study conducted by Bedi[42]; however, Kaur et al[45] reported scalp as the most typical site of presentation followed by limbs.[41,44] While psoriasis causes cosmetic disability, it also leads to morbidity due to pruritus and burning sensation, as observed in our study in 91.34% subjects and 95% cases reported by Okhandiar et al.[41] The itching was significant in 81% of patients reported by Bedi[42] and 65% of patients in the study by Kaur et al.[45]

Nail involvement is common, initial, and at times the only site of involvement and the morphology depends on whether nail matrix, nail bed or hypochondrium is involved. Pitting was the most common nail change observed in our study. Similar results were observed by Kaur et al[45] in a study involving 167 patients, and the changes observed were onycholysis, discoloration and subungual hyperkeratosis.[44] Ghosal et al[46] observed nail involvement in 100 psoriatic patients with pitting and subungual hyperkeratosis as the most common presentation.

Jean Louis Alibert first recognized arthritis in association

with psoriasis in 1818; psoriatic arthritis was clearly defined in 1973 by Moll et al.[47] Polyarticular pattern simulating RA was observed by Rajendran et al[48] and Ray et al.[49]

Palmoplantar keratoderma and vitiligo were the common dermatological conditions associated with psoriasis in our study. Similarly, Sandhu et al[50] noted vitiligo in 38 out of 4700 psoriatic patients. Data from several studies in western literature revealed the association of psoriasis with systemic conditions such as metabolic syndrome. Our study also showed high prevalence of systemic disorders in the psoriasis patients (Table 4). The higher prevalence of metabolic syndrome in psoriatic patients than patients with other skin conditions was relatively higher in a study conducted by Gisondi et al.[51]

Many research studies in the past have been done to describe correlation between HLA-B57 and autoimmune diseases as well as psoriasis. Similar recent study done by Cassia et al.[52] showed 23.6% presence of HLA-B57 in psoriasis patients, while this study shows 35.93% prevalence of HLA-B57 in study population. Moreover, high (61.06%) positivity rate of HLA-B57 in psoriatic arthritis study group could be potentially studied in future research to monitor musculo-skeletal involvement of psoriasis.

Ultrasonography of upper abdomen is an excellent tool to evaluate solid organs including liver. Newer high resolution sonography probes can quantify fat level grading in liver easily. General diffuse increase in liver echogenicity with preserved periportal and diaphragmatic echogenicity is labelled as grade-I fatty changes. Similar findings with obscuration of periportal echogenicity is graded as II while rarefaction of periportal and diaphragmatic echogenicity is labelled as grade III. Associated coarsened echotexture of liver will lead to diagnosis of steatohepatitis which could lead to end-stage liver cirrhosis.[53,54] 88.26% positivity of NAFLD shows significant correlation between the diagnosis of psoriasis and NAFLD. Cheaper and easy nature of ultrasound could be handy in all psoriasis patients to identify "at-risk" cases as stages I to III always occur in serial progression and fatty changes without signs of coarse parenchyma are still reversible.

CONCLUSION

This descriptive study shows male preponderance and extensors, trunk as a common sites of psoriatic lesion presentation. Aggravating factors included stress, winter season, implant insertion, smoking, alcohol consumption, tobacco chewing and obesity. Screening is encouraged for symptoms of psoriatic arthritis, cardiovascular diseases and metabolic syndromes in psoriasis patients due to its predilection with systemic comorbidities. HLA-B57 could be studied as potential disease severity identifier marker in psoriatic arthritic cases. High prevalence of NAFLD in psoriasis study population states the need of using ultrasonography in all psoriasis cases to pin down "at-risk" cases where cirrhosis could be imminent.

DECLARATIONS

Ethical Approval

The ethical approval was taken from ethical committee at Sri Krishna Hospital, Karamsad, India.

Consent to Participate

The author have received written informed consent from the patient.

Consent for Publication

Taken from all participants.

Supporting Data

All data and references present.

Funding Sources

This article was self-funded and no other source of funding present.

Acknowledgments

The author thanks all resilient patients of psoriasis.

REFERENCES

1. Boehncke WH, Schon MP. Psoriasis. *Lancet.* 2015; 386: 983-994. doi: 10.1016/S0140-6736(14)61909-7

2. Nestle FO, Kaplan DH, Barker J. Psoriasis. *N Engl J Med.* 2009; 361: 496-509. doi: 10.1056/NEJMra0804595

3. Lomholt G. Prevalence of skin diseases in a population: A census study from the Faroe Islands. *Dan Med Bull.* 1964; 11: 1-7.

4. Brandrup F, Green A. The prevalence of psoriasis in Denmark. *Acta Derm Venereol.* 1981; 61(4): 344-346. doi: 10.1136/bmjopen-2018-028116

5. Christophers E. Psoriasis - epidemiology and clinical spectrum. *Clin Exp Dermatol.* 2001; 26(4): 314-320. doi: 10.1046/j.1365-2230.2001.00832.x

6. Gudjonsson JE, Elder JT. Psoriasis: Epidemiology. *Clin Dermatol.* 2007; 25(6): 535-546. doi: 10.1016/j.clindermatol.2007.08.007

7. National Psoraisis Foundation®. Web site: https://www.psoriasis.org/cure_known_statistics. Accessed October 1, 2015.

8. Kurd SK, Gelfand JM. The prevalence of previously diagnosed and undiagnosed psoriasis in US adults: Results from NHANES 2003-2004. *J Am Acad Dermatol.* 2009; 60: 218-224. doi: 10.1016/j.jaad.2008.09.022

9. Rapp SR, Feldman SR, Exum ML, Fleischer AB, Reboussin DM. Psoriasis causes as much disability as other major medical diseases. *J Am Acad Dermatol.* 1999; 41(3 pt 1): 401-407. doi: 10.1016/s0190-9622(99)70112-x

10. Watson W, Cann HM, Farber EM, Nall ML. The genetics of psoriasis. *Arch Dermatol.* 1972; 105(2): 197-207.

11. Elder JT, Nair RP, Guo SW, Henseler T, Christophers E, Voorhees JJ. The genetics of psoriasis. *Arch Dermatol.* 1994; 130(2): 216-224.

12. Henseler T. Genetics of psoriasis. *Arch Dermatol Res.* 1998; 290(9): 463-476.

13. Bhalerao J, Bowcock AM. The genetics of psoriasis: A complex disorder of the skin and immune system. *Hum Mol Genet.* 1998; 7(10): 1537-1545. doi: 10.1093/hmg/7.10.1537

14. Bowcock AM, Barker JN. Genetics of psoriasis: The potential impact on new therapies. *J Am Acad Dermatol.* 2003; 49(2 Suppl): S51-S56. doi: 10.1016/s0190-9622(03)01135-6

15. Braun-Falco O, Christophers E. Structural aspects of initial psoriatic lesions. *Arch Dermatol Forsch.* 1974; 251(2): 95-110. doi: 10.1007/BF00560390

16. Van de Kerkhof PC, Van Erp PE. The role of epidermal proliferation in the pathogenesis of psoriasis. *Skin Pharmacol.* 1996; 9(6): 343-354. doi: 10.1159/000211445

17. Hatta N, Takata M, Kawara S, Hirose T, Takehara K. Tape stripping induces marked epidermal proliferation and altered TGF-alpha expression in non-lesional psoriatic skin. *J Dermatol Sci.* 1997; 14(2): 154-161. doi: 10.1016/s0923-1811(96)00567-1

18. Burks JW, Montgomery H. Histopathologic study of psoriasis. *Arch Derm Syphilol.* 1943; 48(5): 479-493. doi: 10.1001/archderm.1943.01510050003001

19. Gordon M, Johnson WC. Histopathology and histochemistry of psoriasis. I. The active lesion and clinically normal skin. *Arch Dermatol.* 1967; 95(4): 402-407.

20. Murphy M, Kerr P, Grant-Kels JM. The histopathologic spectrum of psoriasis. *Clin Dermatol.* 2007; 25(6): 524-528. doi: 10.1016/j.clindermatol.2007.08.005

21. Austin LM, Ozawa M, Kikuchi T, Walters IB, Krueger JG. The majority of epidermal T cells in Psoriasis Vulgaris lesions can produce type 1 cytokines, interferon-gamma, interleukin-2, and tumor necrosis factor-alpha, defining TC1 (cytotoxic T lymphocyte) and TH1 effector populations: A type 1 differentiation bias is also measured in circulating blood T cells in psoriatic patients. *J Invest Dermatol.* 1999; 113(5): 752-759. doi: 10.1046/j.1523-1747.1999.00749.x

22. Lima HC, Kimball AB. Targeting IL-23: Insights into the pathogenesis and the treatment of psoriasis. *Indian J Dermatol.* 2010; 55(2): 171-175. doi: 10.4103/0019-5154.62760

23. Krueger JG, Fretzin S, Suárez-Fariñas M, Haslett PA, Phipps KM, Cameron GS, et al. IL-17A is essential for cell activation and inflammatory gene circuits in subjects with psoriasis. *J Allergy Clin Immunol.* 2012; 130(1): 145-54.e9. doi: 10.1016/j.jaci.2012.04.024

24. Parisi R, Symmons DP, Gri_ths, CE, Ashcroft DM, IMPACT project team. Global epidemiology of psoriasis: A systematic review of incidence and prevalence. *J Invest Dermatol.* 2013; 133: 377-385. doi: 10.1038/jid.2012.339

25. Michalek IM, Loring B, John SM. A systematic review of worldwide epidemiology of psoriasis. *J Eur Acad Dermatol Venereol.* 2017; 31: 205-212. doi: 10.1111/jdv.13854

26. Trembath, R.C, Clough, R.L, Rosbotham, J.L, Jones, A.B, Camp, R.D, Frodsham, A, et al. Identification of a major susceptibility locus on chromosome 6p and evidence for further disease loci revealed by a two-stage genome-wide search in psoriasis. *Hum Mol Genet.* 1997; 6: 813-820. doi: 10.1093/hmg/6.5.813

27. Burden AD, Javed S, Bailey M, Hodgins M, Connor M, Tillman D. Genetics of psoriasis: Paternal inheritance and a locus on chromosome 6p. *J Invest Dermatol.* 1998; 110: 958-960. doi: 10.1046/j.1523-1747.1998.00213.x

28. Sagoo GS, Tazi-Ahnini R, Barker JW, Elder JT, Nair RP, Samuelsson L, Taupe, H, Trembath, R.C, Robinson, D.A, Iles, M.M. Meta-analysis of genome-wide studies of psoriasis susceptibility reveals linkage to chromosomes 6p21 and 4q28-q31 in Caucasian and Chinese Hans population. *J Invest Dermatol.* 2004; 122: 1401-1405. doi: 10.1111/j.0022-202X.2004.22607.x

29. Camargo CM, Brotas AM, Ramos-e-Silva M, Carneiro S. Isomorphic phenomenon of Koebner: Facts and controversies. *Clin Dermatol.* 2013; 31(6): 741-749. doi: 10.1016/j.clindermatol.2013.05.012

30. Noah PW. The role of microorganisms in psoriasis. S*emin Dermatol.* 1990; 9(4): 269-276.

31. Poikolainen K, Reunala T, Karvonen J, Lauharanta, Kärkkäinen P. Alcohol intake: A risk factor for psoriasis in young and middle aged men? *BMJ.* 1990; 300(6727): 780-783. doi: 10.1136/bmj.300.6727.780

32. Jankovic S, Raznatovic M, Marinkovic J, Jankovic J, Maksimovic N. Risk factors for psoriasis: A case-control study. *J Dermatol.* 2009; 36(6): 328-334. doi: 10.1111/j.1346-8138.2009.00648.x

33. Kanda N, Watanabe S. Regulatory roles of sex hormones in cutaneous biology and immunology. *J Dermatol Sci.* 2005; 38(1): 1-7. doi: 10.1016/j.jdermsci.2004.10.011

34. Lipozencić J, Milavec-Puretić V, Pasić A. Contact allergy and psoriasis. *Arh Hig Rada Toksikol.* 1992; 43(3): 249-254.

35. Birkenfeld S, Dreiher J, Weitzman D, Cohen AD. Celiac disease

associated with psoriasis. *Br J Dermatol.* 2009; 161: 1331-1334. doi: 10.1111/j.1365-2133.2009.09398.x

36. Gisondi P, Targher G, Zoppini G, Girolomoni G. Non-alcoholic fatty liver disease in patients with chronic plaque psoriasis. *J Hepatol.* 2009; 51: 758-764. doi: 10.1016/j.jhep.2009.04.020

37. Miele L, Vallone S, Cefalo C, La Torre G, Di Stasi C, Vecchio FM, et al. Prevalence, characteristics and severity of non-alcoholic fatty liver disease in patients with chronic plaque psoriasis. *J Hepatol.* 2009; 51: 778-786. doi: 10.1016/j.jhep.2009.06.008

38. Goulding JM, Price CL, Defty CL, Hulangamuwa CS, Bader E, Ahmed I. Erectile dysfunction in patients with psoriasis: Increased prevalence, an unmet need, and a chance to intervene. *Br J Dermatol.* 2011; 164: 103-109. doi: 10.1111/j.1365-2133.2010.10077.x

39. Strauss H. Zur Lehre von der neurogenen und der thyreogenen Glykosurie [German]. *Dtsch Med Wochenschr.* 1897; 20: 309-312. doi: 10.1055/s-0029-1204973

40. Reed WB, Becker SW, Rohde R, Heiskell CL. Psoriasis and arthritis. Clinicopathologic study. *Arch Dermatol.* 1961; 83: 541-548. doi: 10.1001/archderm.1961.01580100005001

41. Okhandiar RP, Banerjee BN. Psoriasis in the tropics: An epidemiological survey. *J Indian Med Assoc.* 1963; 41: 550-556.

42. Bedi TR. Psoriasis in north India. Geographical variations. *Dermatologica.* 1977; 155: 310-314. doi: 10.1159/000250983

43. Smith AE, Kassab JY, Payne CMR, Beer WE. Bimodality in age of onset of psoriasis, in both patients and their relatives. *Dermatology.* 1993; 186: 181-186. doi: 10.1159/000247341

44. Farber EM, Nall L. The Natural history of psoriasis in 5,600 patients. *Dermatologica.* 1974; 148: 1-18. doi: 10.1159/000251595

45. Kaur I, Handa S, Kumar B. Natural history of psoriasis: A study from the Indian subcontinent. *J Dermatol.* 1997; 24: 230-234. doi: 10.1111/j.1346-8138.1997.tb02779.x

46. Ghosal A, Gangopadhyay D, Chanda M, Das N. Study of nail changes in psoriasis. *Indian J Dermatol.* 2004; 49: 18-21.

47. Moll JM, Wright V. Psoriatic arthritis. *Semin Arthritis Rheum.* 1973; 3: 55-78. doi: 10.1016/0049-0172(73)90035-8

48. Rajendran CP, Ledge SG, Rani KP, Madhavan R. Psoriatic arthritis. *J Assoc Physicians India.* 2003; 51: 1065-1068.

49. Ray SPC, Singh T, Kaur I, Suri S, Sehgal S, Kaur S. Clinical profile of psoriatic arthropathy. *Indian J Dermatol Venereol Leprol.* 1990; 56: 200-2003.

50. Sandhu K, Kaur I, Kumar B. Psoriasis and vitiligo. *J Am Acad Dermatol.* 2004; 51: 149-150. doi: 10.1016/j.jaad.2003.12.014

51. Gisondi P, Tessari G, Conti A, Piaserico S, Schianchi S, Peserico A, et al. Prevalence of metabolic syndrome in patients with psoriasis: A hospital-based case-control study. *Br J Dermatol.* 2007; 157: 68-73. doi: 10.1111/j.1365-2133.2007.07986.x

52. Cassia FF, Cardoso JF, Porto LC, Ramos-e-Silva M, Carneiro S. Association of HLA alleles and HLA haplotypes with psoriasis, psoriatic arthritis and disease severity in a miscegenated population. *Psoriasis (Auckl).* 2021; 11: 41-51. doi: 10.2147/PTT.S258050

53. Singh D, Das CJ, Baruah MP. Imaging of non alcoholic fatty liver disease: A road less travelled. *Indian J Endocrinol Metab.* 2013; 17(6): 990-995. doi: 10.4103/2230-8210.122606

54. Gandha N, Wibawa LP, Jacoeb TNA, Sulaiman AS. Correlation between psoriasis severity and nonnlcoholic fatty liver disease degree measured using controlled attenuation parameter. *Psoriasis (Auckl).* 2020; 10: 39-44. doi: 10.2147/PTT.S272286

ISSN 2473-4799

DERMATOLOGY
OpenJournal

Openventio PUBLISHERS

Case Report

A Case of Progestogen Hypersensitivity

Mai Hasegawa, PhD; Takasuke Ogawa, MD, PhD*; Tatsuo Fukai, MD, PhD; Rie Ueki, MD, PhD; Shigaku Ikeda, MD, PhD

Department of Dermatology, Juntendo University Graduate School of Medicine, 2-1-1 Hongo, Bunkyo-ku, Tokyo 113 8421, Japan

***Corresponding author**
Takasuke Ogawa, PhD
Assistant Professor, Department of Dermatology, Juntendo University Graduate School of Medicine, 2-1-1 Hongo, Bunkyo-ku, Tokyo, 113-8421, Japan; Tel. +81-(0)3-3813-3795; E-mail: t-ogawa@juntendo.ac.jp

Article information
Received: June 1st, 2021; **Revised:** June 14th, 2021; **Accepted:** June 21st, 2021; **Published:** June 23rd, 2021

Cite this article
Hasegawa M, Ogawa T, Fukai T, Ueki R, Ikeda S. A case of progestogen hypersensitivity. *Dermatol Open J.* 2021; 6(1): 15-17. doi: 10.17140/DRMTOJ-6-145

ABSTRACT

Progestogen hypersensitivity (PH) is a cyclical dermatosis that occurs in fertile women during the luteal phase of the menstrual cycle. The clinical presentation is variable and non-specific. We report the case of a 42-year-old woman with a 10-year history of itchy skin lesions that recurred monthly. Determined with her basal body temperature chart, her skin symptoms were related to progesterone surges. Skin examinations revealed multiple and extensive monomorphic red papules, mainly on her arms and legs, as well as on her chest and back. She had no history of associated fever or dyspnea. Her hair, nails and mucous membranes were normal. A blood test at the time of the worst skin eruption revealed mild elevation of serum thymus and activation-regulated chemokines and eosinophilia. Her total serum IgE level was normal. She showed a delayed skin reaction to progesterone. Ultra-low-dose combined oral contraceptives (COCs) improved her symptoms by suppressing ovulation. Accordingly, a diagnosis of progestogen hypersensitivity was made. A T-helper (Th)2 response rather than a Th1 response was suggested to be involved in this case. Atopic dermatitis (AD) can be classified into the major extrinsic type with high serum IgE levels and the minor intrinsic type with normal IgE levels. PH and AD share similarities in that they present with eczema, IgE-mediated sensitization and delayed hypersensitivity responses, and their pathophysiology remains to be fully elucidated because of their heterogeneous aspects. The symptoms of this case were in line with IgE-low AD rather than IgE-high AD, which implicates endogenous progesterone as a trigger.

Keywords
Progestogen hypersensitivity; Woman's issues; Dermatitis; Diagnosis.

INTRODUCTION

Progestogen hypersensitivity (PH) is a condition that typically occurs in women in childbearing years with a spectrum of symptoms, which includes urticaria with or without angioedema, dermatitis, and systemic anaphylaxis.[1] PH, also known as autoimmune progesterone dermatitis, was first described by Shelly et al[2] in 1964. In 2016, Foer et al[3] proposed the name PH because it is more likely a hypersensitivity reaction than an autoantibody reaction. The term, "progestogen," encompasses both natural progesterones and synthetic progestins, which can be triggers of the disease.[3] Because the pathogenesis of this disorder is unclear, there is no established method for the diagnosis of PH. A history of cutaneous eruptions beginning 3-10-days before the menstrual cycle that persists for several days into menses suggests a diagnosis of PH. The diagnosis is confirmed by the demonstration of progesterone sensitization. A therapeutic response with combined oral contraceptive (COC)) provides confirmation of the diagnosis of PH.[1,3]

CASE REPORT

The patient was a 42-year-old Japanese woman (gravidity, 0; parity, 0) with no remarkable medical history who presented with systemic red papules, which had recurred monthly for 10-years (Figure 1). The systemic skin eruption appeared approximately 7-days before menses, was worst on the first day of the period, and resolved spontaneously following menstruation without leaving post-inflammatory hyper/hypopigmentation. Previously unsuccessful medical managements included topical and oral steroids and antihistamines. A skin examination revealed multiple and extensive monomorphic red papules that were mainly located on her arms and legs, as well as on her chest and back . The lesions were pruritic and were not associated with fever or dyspnea. Her hair, nails and mucous membranes were normal. A blood test on the first-day of the period revealed mild elevation of serum thymus and activation-regulated chemokine (TARC) 1766 pg/mL; normal <450 pg/mL) and eosinophilia (eosinophil 560 /μL; normal 70-440 /μL). Her

Openventio PUBLISHERS

total serum IgE level was within the normal limits. A biopsy specimen from the right femur revealed spongiosis with perivascular inflammation. The results of intradermal testing (125 mg/mL of progesterone and 5 mg/mL of estrogen at dilutions of 1:1,000, 1:100, and 1:10 respectively, with saline solution as a control) were all negative until 48-hours later. At five-days after the test, at the same time as the cyclical eruption started to occur, strong erythema appeared in the skin challenge area. Since she had complained of not only eruptions but also premenstrual syndrome, she was prescribed ultra-low-dose COCs containing drospirenone and ethinyl estradiol. After the initiation of this treatment both her cutaneous and emotional symptoms showed improvement. In the present case, the patient's symptoms were related to progesterone surges (Figure 2). She had progesterone sensitization with a delayed skin reaction at the intradermal testing site. The ultra-low-dose COCs improved her symptoms by suppressing ovulation. Based on these clinical findings, a diagnosis of progestogen hypersensitivity was made.

Figure 1. *A Clinical Picture*

The Eruption on the Lower Limbs on the First Day of the Menstrual Period

Figure 2. *The Relationship between the Menstrual Cycle and Dermatitis*

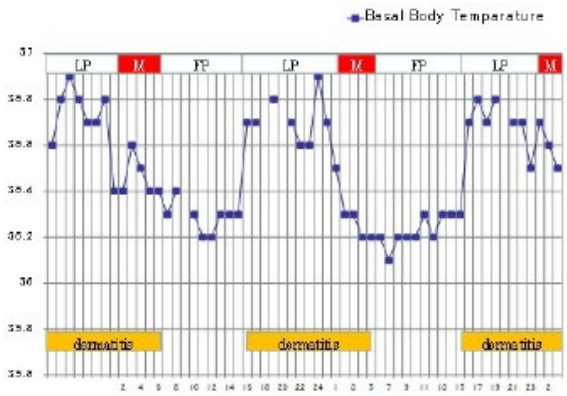

The skin eruption appeared approximately 7-days before menses (at the beginning of the luteal phase), was worst on the first day of the period, and spontaneously resolved following menstruation without leaving post-inflammatory hyper/hypopigmentation.

DISCUSSION AND CONCLUSION

The pathogenesis of PH remains unclear but likely involves multiple mechanisms. Specific IgE to progesterone was measured in some cases, while delayed hypersensitivity was shown in others.[1] The increased serum TARC, eosinophilia and the normal level of serum IgE at the time of the worst skin eruption and the delayed skin reaction suggest that T-helper (Th)2 response rather than a Th1 response was involved in this case.

Atopic dermatitis (AD) can be classified into the major extrinsic type with high serum IgE levels and the minor intrinsic type with normal IgE levels. AD is well known to be a Th2-polarized disease; however, the intrinsic type shows less Th2-skewing or relative overproduction of Th1 cytokine IFN-γ.[4] In a Japanese study, patients with IgE-low AD differed from those with IgE-high AD by their increased frequency of Th1-cells and lower TARC levels (mean±SD: IgE-high AD, 2430±2820 pg/mL; IgE-low AD, 851±771 pg/mL).[5]

Progestogen hypersensitivity and AD share similarities in that they present with eczema, IgE-mediated sensitization and delayed hypersensitivity responses, and the fact that their pathophysiology has not been fully elucidated because of their heterogeneous aspects.[1,5] The symptoms of case suggest IgE-low AD rather than IgE-high AD, which implicates endogenous progesterone as a trigger.

CONSENT

The authors have received written informed consent from the patient.

CONFLICTS OF INTEREST

The authors declare that they have no conflicts of interest.

REFERENCES

1. Jonathan A. Bernstein. progestogen sensitization: A unique female presentation of anaphylaxis. *Curr Allergy Asthma Rep.* 2020; 20: 4. doi: 10.1007/s11882-020-0900-4

2. Shelley WB, Preucel RW, Spoont SS. Autoimmune progesterone dermatitis. Cure by oophorectomy. *JAMA.* 1964; 190: 35-38. doi: 10.1001/jama.1964.03070140041004

3. Foer D, Buchheit KM, Gargiulo AR, Lynch DM, Castells M, Wickner PG. Progestogen hypersensitivity in 24 cases: Diagnosis, management, and proposed renaming and classification. *J Allergy ClinImmunol Pract.* 2016; 4(4): 723-79. doi: 10.1016/j.jaip.2016.03.003

4. Tokura Y. Extrinsic and intrinsic types of atopic dermatitis. *J Dermatol Sci.* 2010; 58: 1-7. doi: 10.1016/j.jdermsci.2010.02.008

5. Kabashima-Kubo R, Nakamura M, Sakabe J, Sugita K, Hino

R, Mori T, et al. A group of atopic dermatitis without IgE elevation or barrier impairment shows a high Th1 frequency: Possible immunological state of the intrinsic type. *J Dermatol Sci*. 2012; 67: 37-43. doi: 10.1016/j.jdermsci.2012.04.004

ISSN 2473-4799

DERMATOLOGY
OpenJournal

Openventio PUBLISHERS

Case Series

The Dermoscopic "Chromosome Arms Sign" for Terra Firma-Forme Dermatosis

Mario Cutrone, MD[1]; Julie Van Gysel, MD[2]; Ramon Grimalt, MD, PhD[3*]

[1]*The Pediatric Operations Unit, Ospedaledell'Angelo, Venice, Italy*
[2]*Department of Dermatology. Free University of Brussels, Brussels, Belgium*
[3]*Universitat Internacional de Catalunya, Barcelona, Spain*

[*]***Corresponding author***
Ramon Grimalt, MD, PhD
Faculty of Medicine and Health Sciences, Universitat Internacional de Catalunya, Barcelona, Spain; Tel. 00 34 617301661; E-mail: rgrimalt@uic.es

Article information
Received: May 30th, 2021; **Revised:** July 15th, 2021; **Accepted:** July 16th, 2021; **Published:** July 23rd, 2021

Cite this article
Cutrone M, Van Gysel J, Grimalt R. The dermoscopic "chromosome arms sign" for terra firma-forme dermatosis. *Dermatol Open J.* 2021; 6(1): 18-20.
doi: 10.17140/DRMTOJ-6-146

ABSTRACT

Introduction
Terra firma-forme dermatosis (TFFD) belongs to the group of "dirty dermatoses" and represents a not well-known and surely underestimated skin condition.

Clinical Cases
We present 2 cases of TFFD and present clinical and dermatoscopical findings.

Results
We present specific dermatoscopical findings of TFFD.

Conclusion
We propose the denomination "chromosome arms" sign for Terra firma-forme dermatosis.

Keywords
Terra firma-forme dermatosis; Dirtydermatoses; Dermatoscopy; Chromosome arms; Duncan's dermatosis.

INTRODUCTION

Terra firma-forme dermatosis (TFFD) belongs to the group of "dirty dermatoses" and represents a not well-known and surely underestimated skin condition. Firstly described by Duncan, Tschen and Knox in 1987, it accounts for a few case series in the literature and has a still undefined aetiology.

TFFD might result from delayed keratinocyte maturation, which leads to the retention of keratinocytes/melanin within the epidermis,[1] but not all authors agree with this idea.

When TFFD or Duncan's dirty dermatosis is clinically suspected, clearance of the dermatosis follows rubbing the affected skin with 70% isopropyl alcohol.

As suggested by Errichetti et al[1] wiping the lesions in the clinic may be quite embarrassing for the patients, hence the need of other diagnostic approaches.

We here report the dermoscopic findings in 2 cases affected with TFFD.

CASE SERIES

Clinical Case 1

A 9-year-old girl presented to our clinic with the presence of a not well-defined patch of brownish discoloration on the lateral and frontal part of the neck. The mother stated that the lesions have been present for the last 10-months (Figure 1).

The paediatrician who sends us the patient had the suspect of nevus epidermicus or akantosis nigricans. Insulinemia test was performed and showed normal results.

On clinical observation a reticulated and pigmented not well-defined area was seen.

With the idea to perform academical teaching we approached the patient with our dermatoscope.

Figure 1. *A Typical Clinical Case of TFF Dermatitis in a A 9-Year-Old Girl*

We used a manual polarized device (DermLite DL3; 3Gen, San Juan Capistrano, CA, USA) without immersion. For the images we adapted a Nikon Cool Pix IV camera

Under the dermatoscope we found a very peculiar aspect (Figure 2) that we believe that clearly resemble chromosome arms.

Figure 2. *Dermoscopy Showed Findings that Suggested Chromosomes so the Proposed Term the Dermoscopic "Chromosome Arms" Sign for Terra Firma-Forme Dermatosis was Coined*

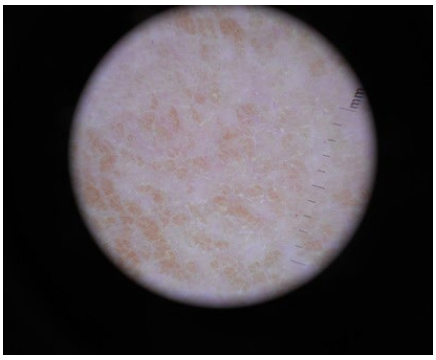

The patient was rubbed using a gauze embedded with a cleansing agent and clinical and dermatoscopial images immediately normalized.

Clinical Case 2

A 11-year-old male presented to our clinic with of a not well-defined patch of brownish discoloration bilaterally present on the retroauricular region (Figure 3). The mother stated that the lesions have been present for the last 6-month and that were resistant to normal shampooing and detergent.

Under the dermatoscope we found a very similar aspect that we like to call it "chromosome arms".

The patient was also rubbed using a gauze embedded with a cleansing agent and clinical and dermatoscopial images immediately normalized (Figure 4).

Figure 3. *A 11-Year-Old with a Not Well-Defined Patch of Brownish Discoloration Bilaterally Present on the Retroauricular Region*

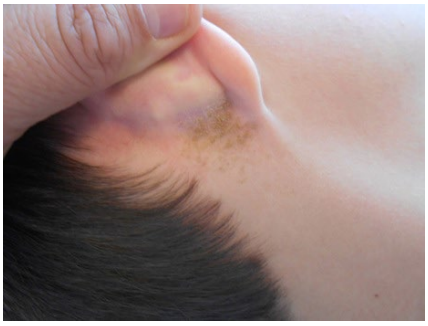

Figure 4. *Dermoscopy after Rubbing the Lesions Using a Gauze Embedded with a Cleansing Agent Shows Resolution of the Problem*

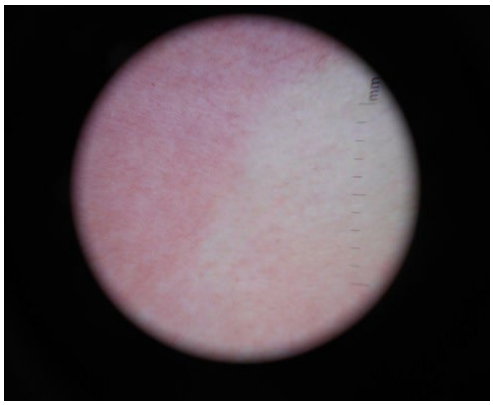

DISCUSSION

TFFD and dermatosis neglecta (DN) both share same clinical findings and for some authors one could be included in the other.[2-7]

From our point of view DN is a different condition not only because the brownish discoloration does not get rid with an alcohol swap but also for the clinical findings.

Usually in DN the lesions show a dirty appearance, secondary to the progressive accumulation of sebum, sweat, corneocytes, and other debris, resulting in hyperpigmented, waxy plaques with cornflake-like scales.

Also under dermoscopy both entities cleary differ.

In TFFD previous reports have described the dermatoscopycal findings as "*large polygonal plate-like brown scales arranged in a mosaic pattern*"[1] and also irregularly distributed cornflake-like dark brown scales.

The cited authors[1] suggest that such a variability could

be explained by the different histological background of these conditions, with papillomatosis, acanthosis, and compact orthohyperkeratosis typical of TFFD[3] resulting in a more regular "polygonal plate-like" scaling pattern and prominent basket-weave hyperkeratosis, along with possible epidermal atrophy and diminution of rete pegs, seen in DN[4] being responsible for a more irregular "cornflake-like" scaling pattern.

The dermoscopic findings detected in our TFFD case are in line with data reported in previous cases,[2-8] thus confirming the reliability of dermoscopy in assisting the diagnosis of this condition by showing this extremely peculiar chromosome arms aspect

In dermatosis neglecta three prior dermoscopic reports have been described in the literature, revealing a pattern similar to that of TFFD.[1] However, the diagnosis of DN in such patients was not confirmed by a positive soap water swab test,[1] thereby not ruling out the diagnosis of TFFD.

In the differential diagnosis we believe that dermoscopy might be useful not only for distinguing between DN and TFFD but also in the confront amb other scalling and brownish dermatosis like pityriasis versicolor often shows fine whitish scaling (commonly localized in the skin furrows) associated with a pigmented network composed of brown stripes or a diffuse brownish pigmentation; confluent and reticulated papillomatosis typically displays fine whitish scaling associated with brownish, homogeneous, more or less defined, polygonal, flat globules separated by whitish/pale striae creating a cobblestone appearance or brownish areas presenting a 'sulci and gyri' pattern; friction melanosis usually features brownish structureless areas arranged in a reticular fashion; and macular amyloidosis commonly reveals a central whitish or brown hub surrounded by various configurations of brownish pigmentation, including fine radiating streaks, dots, leaf-like projections, and bulbous projections.[9]

From our point of view DN is a different condition not only because the brownish discoloration does not get rid with an alcohol swap but also for the clinical findings.

Usually in DN the lesions show a dirty appearance, secondary to the progressive accumulation of sebum, sweat, corneocytes, and other debris, resulting in hyperpigmented, waxy plaques with cornflake-like scales.

The chromosome arms sign is only visible in TFFD.

CONCLUSION

We believe that dermoscopy is getting more and more useful and new and easy to remember signs might be handy for the clinician on approaching doubtful dermatoses like TFFD. Also the need of not embarrassing patients through the swap method of "wiping off" the disease will indeed help our empathically approach to this diagnosis.

Following this observation we hence propose the term the chromosome arms sign for the diagnosis of TFFD without the need of "cleaning" the patient with an alcohol swap.

The pediatrician with no need to send the patient to the dermatologist could properly diagnose this condition. Dermatoscopes are getting more accessible and in each pediatric department, at least one of these devices should be available.

CONSENT

The authors have received written informed consent from the patients.

CONFLICTS OF INTEREST

The authors declare that they have no conflicts of interest.

REFERENCES

1. Errichetti E, Stinco G. Dermoscopy in terra firma-forme dermatosis and dermatosis neglecta. *Int J Dermatol*. 2017; 56: 1481-1483. doi: 10.1111/ijd.13686

2. Greywal T, Cohen PR. Terra firma-forme dermatosis: A report often individuals with Duncan's dirty dermatosis and literaturereview. *Dermatol Pract Concept*. 2015; 5: 29-33. doi: 10.5826/dpc.0503a08

3. Saha A, Seth J, Sharma A, Biswas D. Dermatitis neglecta – – a dirtydermatosis: Report of three cases. *Indian J Dermatol*. 2015; 60: 185-187. doi: 10.4103/0019-5154.152525

4. Gusdorf L, Cribier B. Clinicopathological aspects of terra firma-forme dermatosis. *Ann Dermatol Venereol*. 2016; 143: 446-452. doi: 10.1016/j.annder.2016.02.023

5. Lucas JL, Brodell RT, Feldman SR. Dermatosis neglecta: A series of case reports and review of other dirty-appearing dermatoses. *Dermatol Online J*. 2006; 12: 5. doi: 10.5070/D304V3R596

6. Abdel-Razek MM, Fathy H. Terra firma-forme dermatosis: Case series and dermoscopic features. *Dermatol Online J*. 2015; 21: 13030/qt4rq5x48c.

7. Martın-Gorgojo A, Alonso-Usero V, Gavrilova M, Jordá-Cuevas E. Dermatosis neglectaorterra firma-forme dermatosis. *Actas Dermosifiliogr*. 2012; 103: 932-934. doi: 10.1016/j.adengl.2011.12.006

8. Unal E, Guarneri C, Chokoeva AA, Wollina U, Tchernev G. Terra firma-forme dermatosis. *Wien Med Wochenschr*. 2017; 167: 66-69. doi: 10.1007/s10354-016-0519-1

9. Errichetti E, Stinco G. Dermoscopy in general dermatology: A practical overview. *Dermatol Ther (Heidelb)*. 2016; 6: 471-507. doi: 10.1007/s13555-016-0141-6