

Research

***Corresponding author**

Barakat Adeola Animasahun, MB, BS, MPH, FWACP
Senior Lecturer
Department of Paediatrics and Child Health
Lagos State University College of Medicine, Ikeja
Lagos, Nigeria
Tel. +2348037250264
E-mail: deoladebo@yahoo.com

Volume 2 : Issue 3

Article Ref. #: 1000HROJ2119

Article History

Received: September 19th, 2015

Accepted: October 12th, 2015

Published: October 12th, 2015

Citation

Animasahun BA, Akinbami MO, Awe O. Clinical characteristics of children with pulmonary vein abnormalities in a tertiary centre in an urban community in Nigeria. *Heart Res Open J.* 2015; 2(3): 109-114. doi: [10.17140/HROJ-2-119](https://doi.org/10.17140/HROJ-2-119)

Copyright

©2015 Animasahun BA. This is an open access article distributed under the Creative Commons Attribution 4.0 International License (CC BY 4.0), which permits unrestricted use, distribution, and reproduction in any medium, provided the original work is properly cited.

Clinical Characteristics of Children with Pulmonary Vein Abnormalities in a Tertiary Centre in an Urban Community in Nigeria

Barakat Adeola Animasahun^{1*}, Motunrayo O Akinbami² and Olugbenga Awe³

¹Senior Lecturer, Department of Paediatrics and Child Health, Lagos State University College of Medicine, Ikeja, Lagos, Nigeria

²Senior Registrar, Department of Paediatrics and Child Health, Lagos State University College of Medicine, Ikeja, Lagos, Nigeria

³Registrar, Department of Paediatrics and Child Health, Lagos State University College of Medicine, Ikeja, Lagos, Nigeria

ABSTRACT

Background: Pulmonary vein abnormalities are rare. Prompt intervention is needed to salvage the children affected. There are very few reports on occurrence of pulmonary vein abnormalities among Nigerian and African children. The aim of this study is to report the clinical characteristics of Nigerian children with Pulmonary vein abnormalities.

Method: A prospective study involving consecutive subjects diagnosed with pulmonary venous abnormalities using echocardiography at the Lagos State University Teaching Hospital (LASUTH), Nigeria between January 2007 and December 2014. Data were analysed using Microsoft Excel program supplemented by Megastat statistical package. Statistical significance was set at p -value < 0.05.

Results: There were 21 cases of pulmonary venous abnormalities, which accounted for 2.07% of cases of congenital heart disease and 6 per 100,000 of the total children that presented in LASUTH during the study period, with male to female ratio of 0.8:1. Sixteen (76.2%) of the studied subjects presented in infancy and five (23.8%) cases presented above one year of age. The commonest indication for echocardiography was cyanosis, other mode of presentation were breathlessness, recurrent respiratory tract infection, congestive cardiac failure and murmur. Total anomalous pulmonary venous return accounted for 66.7%, Cor triatriatum was seen in 6 subjects (28.6%) and a case of Partial Anomalous Pulmonary Venous Connection (PAPVC) was seen (4.8%). Most of the subjects had other associated cardiac defects.

Conclusion: The prevalence of pulmonary vein abnormalities among Nigerian children is comparable to that in other parts of the world. High degree of suspicion is needed to enable prompt diagnosis and intervention.

KEYWORDS: Pulmonary; Venous; Abnormalities; Children; Nigeria.

ABBREVIATIONS: LASUTH: Lagos State University Teaching Hospital; PAPVC: Partial Anomalous Pulmonary Venous Connection; TAPVC: Total Anomalous Pulmonary Venous Connection; CHD: Congenital Heart Disease; LUTH: Lagos University Teaching Hospital; APVC: Abnormal Pulmonary Venous Connection; GE: General Electric; MDCT: Multi Detector Computed Tomography.

INTRODUCTION

Pulmonary veins abnormalities include total and partial anomalous pulmonary venous connection, cor triatriatum and pulmonary vein stenosis or hypoplasia/atresia.

Total Anomalous Pulmonary Venous Connection (TAPVC) is a cyanotic congenital

heart defect in which all the pulmonary veins are connected to the right atrium or the tributaries of the systemic veins. It accounts for 1 to 3 percent of congenital heart disease.¹ It is the fifth commonest cyanotic congenital heart disease.² The incidence of TAPVC is 1:15,000 live births.² It is classified into supracardiac, cardiac, infracardiac and mixed pattern based on the site of anomalous venous union. There is a 3:1 male preponderance in infants with infradiaphragmatic lesion.³ There is a natural history of death in 80% of symptomatic infants with TAPVC that present before the age of one year.⁴

Cortriatriatum is a rare congenital cardiac anomaly in which a fibromuscular membrane divides the atrium into two. This results in abnormal incorporation of the pulmonary venous structures into the right or left atrium. It accounts for 0.1% of Congenital Heart Disease (CHD).⁵

Partial anomalous pulmonary venous return (PAPVC) is a rare CHD with one or pulmonary veins connects to the venous circulation. The estimated prevalence rate is 0.5% of the general population. It is commonly associated with atrial septal defect.⁶

Congenital pulmonary vein stenosis and hypoplasia/atresia is a rare cause of neonatal pulmonary oedema and can present later in life with pulmonary artery hypertension or hemotypsis.⁷ In a seven years population based study in Atlanta by Reller, et al.² TAPVC was seen in 0.95% of infants with congenital heart disease with a prevalence of 0.8 per 10,000 live births.

In a retrospective analysis of patients with anomalous pulmonary venous return in India by Vimal Raj, et al.⁸ anomalous pulmonary connection occurred in 10.3% of subjects with CHD. TAPVC and PAPVC occurred in 6 and 4.3% percent of the studied subjects respectively. Out of the subjects with TAPVC, supracardiac type was the commonest.

In a retrospective study by Chinawa, et al.⁹ in Enugu, Nigeria, data of 71 children with CHD aged 6 months to 12 years that presented between January 2007 to April 2015 were analysed. Only one case of TAPVC was seen which accounted for in 1.4% of the studied subjects.

Okoromah, et al.¹⁰ in Lagos University Teaching Hospital (LUTH), Nigeria did a two years prospective study on children with CHD aged 3 to 192 months, a case of TAPVC (2.4%) was seen among the 41 cases of cyanotic CHD. A case of Cortriatriatum was also documented. No other form of Abnormal Pulmonary Venous Connection (APVC) was seen. There have been other reports on Congenital Heart Disease in Nigeria, but no case of APVC was mentioned.^{11,12}

In Nigeria, there are very few Paediatric centres with echography machine with doppler facility and expertise which may explain why only very few cases of abnormal pulmonary venous connections have been reported. To the best of the au-

thors knowledge, there has been no report in Nigeria on the clinical characteristics of children with anomalous or abnormal pulmonary venous connections hence the need for this study which aim to describe the clinical characteristics of subjects with abnormal pulmonary venous connections to be able emphasize the need to look out for these subjects to enable improved outcome by early diagnosis and prompt intervention in these subjects.

SUBJECTS AND METHODS

The study was a prospective study of consecutive subjects diagnosed with abnormal pulmonary venous connections using echocardiography at the Lagos state university teaching hospital (LASUTH), Nigeria between January 2007 and December 2014 as part of a large study. LASUTH serves as a major referral centre form both private and public hospitals within Lagos and other neighbouring states.

Transthoracic echocardiography was done by a Paediatric Cardiologist using a General Electric (GE) Vivid I machine ref number 14502 WP SN 2084 with an appropriate size probe. All subjects referred for echocardiography had clinical evaluation, physical examination, chest radiograph, electrocardiogram before echocardiography.

Subjects bio-data and indications for echocardiography and echocardiographic findings were analysed using Microsoft Excel program supplemented by Megastat statistical package. Mean, standard deviation and other parameters were generated as necessary for continuous data. Means of continuous variables were compared using the student t test and proportions using chi-square test. The coefficients of correlation and associated p-values were derived. Statistical significance was set at p-value <0.05.

RESULTS

A total of 315,150 children less than 13 years presented at the Paediatric department of LASUTH as both in and out patients within the study period, out of which 1495 had echocardiography done for various indications. Among the total children that had echocardiography done, 354(23.7%) of them had structurally normal heart and 1141(76.3%) had structural heart defect. Among the children with structural heart defect, 1011(88.6%) of them had congenital heart defect and 130(11.4%) of them had acquire heart defect. There were 21 cases of pulmonary venous abnormalities within the studied period, which accounted for 2.07% of cases of congenital heart disease and 6 per 100,000 of the total children that presented in LASUTH within the study period.

Of the 21 cases seen, 16(76.2%) of the studied subjects presented in infancy and 5(23.8%) cases were diagnosed above one year of age. The mean age at diagnosis of all subjects was 8.01±25 months. The mean age at diagnosis for boys was 8.7±3.1 months and 7.5±3.2 months for girls. There was

no statistical significance for the age at diagnosis between both sex ($p=0.804$). This is highlighted in Table 1. Among the studied subjects, 57.1% were female and 42.9% were male with male to female ratio of 0.8:1.

Age group of subjects	Frequency	Percentage
<1 month	5	23.8
1 month-12 months	11	52.4
>12 months	5	23.8
Total	21	100.0

Table 1: Age of subjects at presentation.

The commonest indication for echocardiography was a suspicion of cyanotic congenital heart disease based on cyanosis at presentation. This accounted for 38.1% of echocardiography evaluation. Seven subjects (28.6%) presented with breathlessness. Five subjects (23.8%) presented with recurrent respiratory tract infection and had echocardiography done on suspicion acyanotic CHD. One of the subjects was evaluated on account of congestive cardiac failure which accounted for 4.8% of the indication for echocardiography while another had echocardiography done after presenting with murmur. Indication for echocardiography is shown in Figure 1.

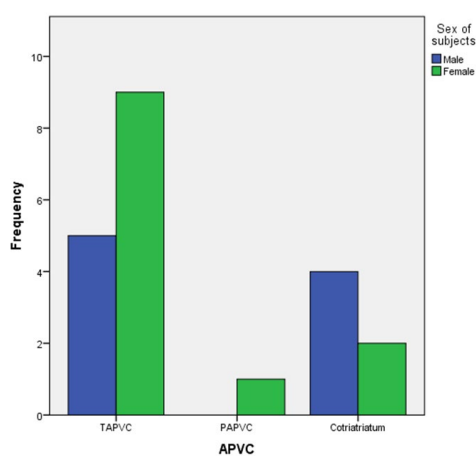


Figure 1: Sex distribution of the types of pulmonary vein abnormalities in subjects.

Total anomalous pulmonary venous return accounted for 66.7% of the subjects with APVC. Cortriatrium was seen in 6 subjects (28.6%) and a case of PAPVC was seen (4.8%). The mean age at diagnosis of TAPVC was 8.4 ± 4.2 months. The child with PAPVC was diagnosed at 8.5 months of age. Mean age at diagnosis of cortriatrium was 7.0 ± 5.1 months. There was not statistical significance at the age of diagnosis of the APVC with a p value of 0.917. These are highlighted in Tables 2 and 3.

Out of the 14 cases with TAPVC, supracardiac type was seen 12 subjects (85.7%) and 2 patients (14.3%) had mixed TAPVC.

No other associated cardiac anomaly was seen in 6 (42.8%) out of the 14 subjects with TAPVC. ASD was seen in

3 subjects diagnosed with TAPVC. Cortriatrium alone occurred in 4 (66.7%) out of 6 subjects with the cardiac lesion. The only subject with PAPVC had associated large secundum ASD. Associated cardiac anomalies are highlighted in Figure 1.

Indications for Echocardiography	Frequency	Percentage
Recurrent RTI	5	23.8
Cyanosis	8	38.1
Murmur	1	4.8
Breathlessness	7	28.6
CCF	1	4.8
Total	21	100.0

RTI: Respiratory Tract Infection.

Table 2: Indication for echocardiography.

Types of APVC	Frequency	Percentage
TAPVC	14	66.7
PAPVC	1	4.8
Cortriatrium	6	28.6
Total	21	100.0

Table 3: Types of pulmonary venous abnormalities in the subjects.

DISCUSSION

Anomalous pulmonary venous connection is a rare congenital heart disease with a lethal natural course because of progressive pulmonary artery hypertension and heart failure.¹³ In this study, 6 per 100,000 of the total children that presented in LASUTH within the study period had abnormal pulmonary vein connections. A prevalence of 1 in 15,000 live births was reported for TAPVC by Reller, et al.² among children in Atlanta. Abnormal pulmonary vein connections was found in 2.07% of cases with CHD in the current study. This is low compare to finding in a study by Vimal Raj, et al.⁸ in an eight years retrospective study where APVC accounted for 10.3% of cases with CHD. The larger number of cases of congenital heart diseases, geographical differences, differences in methodology including mode of diagnosis with Doppler echocardiography compared with Multi Detector Computed Tomography (MDCT) and Cardiac Magnetic Resonance which are more sensitive used by Vimal Raj, et al.⁸ Cardiac Multi detector computed tomography (MDCT) and Cardiac Magnetic Resonance evaluation is still at fetal stage in Nigeria.

A major finding in this study is that about one quarter of the subjects (23.8%) with diagnosis of APVC within one month of life. This may account for why earlier reports from the country reported fewer cases since these reports were on subjects

older than three months generally.^{9,10} Another probable reason for the lower prevalence reported in the earlier studies may be lack of doppler facility in the echocardiography machine used.⁷ Although the proportion reported in this study proportion is lower than the earlier report by Correa-Villasenor¹ where 98% of subjects with TAPVC presented during the neonatal period. This emphasises the need for more surveillance for these subjects to enable early diagnosis. In the current study about a quarter of the subjects were diagnosed after infancy. This is quite late considering the fact that the disease is a progressive one which requires early intervention.⁷ The presentation of this group of subjects is also late when compared to the study by El-Said, et al.¹⁴ where 20 (57%) out of 35 subjects had diagnosis of TAPVC by 6 weeks of life. In the study by El-Said, et al.¹⁴ surgical intervention before six months resulted in high mortality but early and intensive medical treatment resulted in a favourable outcome. Most patients with TAPVC were found to be asymptomatic at birth and majority died within first year of life if surgical repair was not implemented.¹⁴

In this study, 57.1% of the subjects were female but there was no statistical significant difference in the sex of studied subject. Male preponderance has been documented in some cases of TAPVC.¹⁵⁻¹⁷ whereas there appears to be no sex prevalence in some other reports.¹⁷

Two third of the subjects (66.7%) had TAPVC, while PAPVC occurred in one patient (4.8%). This is similar to the report by Ussiri, et al.¹⁵ where TAPVC was seen in 60% of the studied subjects and PAPVC in 40% of the cases. TAPVC is said to be the commonest form of APVC occurring ten times more than PAPVC¹⁸ as documented also in this report. Among subjects with TAPVC, supracardiac lesion was seen in 86% of cases while mixed lesion occurred in 14% of the cases. This is not surprising because supracardiac lesion is the commonest form of TAPVC but mixed type has the worst prognosis. Vimal Raj, et al.⁸ and Ussiri, et al.¹⁵ also documented higher proportion of the supracardiac type among the Indian children. Although, it occurred in 46% and 43.6% respectively.

The diagnosis of TAPVC was made much earlier than PAPVC in cases seen in this study. The earliest diagnosis of APVC seen was in subjects with cortriatrium although there was no statistical significant difference in the age at diagnosis. The earlier presentation of subjects with TAPVC may be due to the fact the timing and severity of symptoms in Pediatric patients with pulmonary vein abnormalities depend largely on the number of pulmonary veins involved and the severity of obstruction to individual pulmonary veins. Since all the four pulmonary veins are involved in TAPVC, they are more likely to have more severe symptoms which will necessitate earlier presentation. This finding is similar to the study by Ussiri, et al.¹⁵ where the mean age at presentation was 21.6 months for TAPVC and 135.2 months for PAPVC. (Table 4) The mean age at diagnosis of cortriatrium in this study was 7.0±5.1 months. This is similar to a mean age of 6 months documented by Alphonso, et al.¹⁹

Form of APVC	N	Age at presentation in weeks (Mean± SD)	p-value
TAPVC	15	35.57±11.86	0.971
PAPVC	1	36.00±00	
Contriatrium	6	30.17±20.57	

Table 4: Types of pulmonary venous abnormalities and mean age of presentation in months.

The commonest indication for diagnosis in this study was cyanosis (38.1%). The reason for low prevalence of cyanosis in these subjects is not immediately clear but may be due to the fact that about that proportion presented in the neonatal period when cyanosis may not be so visible to the naked eye at that age due to patency of the duct at that age and coexisting lesions such as ASD which can help improve mixing of blood at the atrial level in them.¹⁷ In a study by Tubianosa, et al.²⁰ all patients that had TAPVC correction presented with cyanosis and 83% of them had congestive cardiac failure. Breathlessness was the second commonest indication for diagnosis in this study but this was found as the commonest indication in a study by Am-mash, et al.²¹ on subjects with PAPVC.

TAPVC is usually an isolated cardiac anomaly and associated complex cardiac lesion is seen in 30% of the cases.²² Mortality with complex anomalies exceeds 50% than in patients with isolated TAPVC. In this study, isolated TAPVC was seen in 42.9% of the cases. In 57.1% of the cases, other associated cardiac lesions were seen. The commonest associated cardiac lesion was ASD. Other cardiac lesions seen were VSD, TGA, PDA and DORV.

ASD is a common associated cardiac lesion with PAPVC.²³ ASD was seen in the only subject that was diagnosed with PAPVC in this study. Cortriatrium is often associated with other congenital cardiac anomalies with ASD being the commonest.²⁴ In this study, isolated cortriatrium was seen in 4 out of 6 subjects. Two subjects each had a VSD and ASD as an associated anomaly. (Table 5)

Other associated cardiac anomalies	Frequency	Percentage
TAPVC only	6	28.6
Contriatrium only	4	19.0
TAPVC and ASD	3	14.3
TAPVC and VSD	1	4.8
Cortriatrium with VSD	1	4.8
Cortriatrium with ASD	1	4.8
PAPVC and ASD	1	4.8
TAPVC and TGA	1	4.8
TAPVC, ASD and PDA	1	4.8
TAPVC, VSD, ASD, PDA and TGA	1	4.8
TAPVC, ASD, Single Ventricle and DORV	1	4.8
Total	21	100.0

Table 5: Other associated cardiac anomalies in subjects with pulmonary vein abnormalities.

CONCLUSION

The prevalence of pulmonary vein abnormalities among Nigerian children is comparable to that in other parts of the world. High degree of suspicion is needed to enable prompt diagnosis and intervention.

CONFLICTS OF INTEREST

The authors declare that they have no conflicts of interest.

ACKNOWLEDGEMENT

The patient, parent, caregivers and all health workers involved in the care of these patients are gratefully acknowledged.

FINANCIAL DISCLOSURE

The study was sponsored by both authors.

CONSENT

Informed consent was obtained from the parent and caregivers before being included in the study.

AUTHOR'S CONTRIBUTION

BA Animasahun was the project leader, Study concept and design was done by BA Animasahun.

Acquisition of data was done by Animasahun. Animasahun, Akinbami and Awe participated in the analysis and interpretation of data and drafted the manuscript. Critical revision of the manuscript for important intellectual content, administrative, technical, and material and financial support were done by all the authors.

REFERENCES

- Correa-Villasenor A, Ferences C, Boughman JA, Neill CA. Total anomalous pulmonary venous return: familial and environmental factors. The Baltimore-Washington Infant Study Group. *Tetatology*. 1991; 44(4): 415-428.
- Reller MD, Strickland MJ, Riehle-Colarusso T, et al. Prevalence of congenital heart defects in Metropolitan Atlanta, 1998-2005. *JPediatr*. 2008; 153: 807. doi: [10.1016/j.jpeds.2008.05.059](https://doi.org/10.1016/j.jpeds.2008.05.059)
- Kirklin JW. Total anomalous pulmonary venous connection. Cardiac surgery. 3rd ed. New York: Churchill Livingstone. 2011: 753-759.
- Newfeldt EA, Wilson A, Paul MH, Reisch JS. Pulmonary vascular disease in total anomalous pulmonary venous drainage. *Circulation*. 1980; 61: 103.
- Niwayama G. Cor triatriatum. *Am Heart J*. 1960; 59: 291317.
- Senocak F, Ozme S, Bilgic A, Ozkutlu S, Ozer S, Saraçlar M. Partial anomalous pulmonary venous return. Evaluation of 51 cases. *Jpn Heart J*. 1994; 35: 43-50.
- Latson LA, Prieto LR. Congenital and acquired pulmonary vein stenosis. *Circulation*. 2007; 115: 103-108. doi: [10.1161/CIRCULATIONAHA.106.646166](https://doi.org/10.1161/CIRCULATIONAHA.106.646166)
- Vimal R, Varun B, Vinay B, Karthik G, Venkatramen B. Prevalence and pattern of total and partial anomalous pulmonary venous connection in Indian patients with congenital heart disease. *J of Cardiovascular Magnetic Resonance*. 2015; 17(Suppl 1): 222.
- Chinawa JM, Eze JC, Obi I, et al. Synopsis of congenital cardiac disease among children attending University of Nigeria Teaching Hospital Ituku Ozalla, Enugu. *BMC Research Notes*. 2013; 6: 475. doi: [10.1186/1756-0500-6-475](https://doi.org/10.1186/1756-0500-6-475)
- Okoromah CAN, Ekure EN, Lesi FEA, Okunowo WA, Tijani BO, Okeiyi JC. Prevalence, profile, and predictors of malnutrition in children with congenital heart defects: a case-control observational study. *Arch Dis Child*. 2011; 96(4): 354-360. doi: [10.1136/adc.2009.176644](https://doi.org/10.1136/adc.2009.176644)
- Kolo PM, Adeoye PO, Omotoso AB, Afolabi JK. Pattern of congenital heart disease in Ilorin. *The Niger Postgrad Med J*. 2012; 19(4): 230-234.
- Bode-Thomas F, Okolo SN, Ekedigwe JE, Kwache IY, Adewunmi O. Paediatrics echocardiography in JOS University Teaching Hospital: Problem, prospects and preliminary Audit. *Nigerian J of Paediatrics*. 2003; 30: 143-149.
- Ping-Yao Wang, Be-Tau Hwang, Jen-Her Lu, et al. Significance of pulmonary venous obstruction in total anomalous pulmonary venous return. *J Chin Med Assoc*. 2004; 67: 331-335.
- El Said G, Charles MD, Mullins E, McNamara DG. Management of total anomalous pulmonary venous return. *Circulation*. 1972; 45: 1240-1250.
- Ussiri EV, Nyawawa ETM, Mannam EC, SAjja LR, Bhas-kara Raju DS, Pathuri SN. Pattern of anomalous pulmonary venous connection as seen at Care Hospital, Hyderabad-India. *East and Central African Journal of Surgery*. 2006; 2(2): 18-22.
- Noori NM, Meraji M, Mohamed MHK, Mohaghi H, Alizadeh SM, Sadeghi GM. Surgical outcome for correction of TAPVC in children. *Iranian Heart J*. 2001; 2: 15-18.
- Geva T, Van Praag S. Anomalies of the Pulmonary Veins: In: Moss Adams heart disease in infants, children, and adolescents. 7th ed. William and Wilkins, Baltimore, 2008: 762-792.

18. Snellen HA, Van Ingen HC, Hoefsmit EC. Pattern of anomalous pulmonary venous drainage. *Circulation*. 1968; 38: 45-63.

19. Alphonso N, Norgaard MA, Newcomb A, d'odekem Y, Brizard CP, Cochrane A. Cor triatriatum: presentation, diagnosis and long-term surgical results. *Ann Thorac Surg*. 2005; 80(5): 1666-1671. doi: [10.1016/j.athoracsur.2005.04.055](https://doi.org/10.1016/j.athoracsur.2005.04.055)

20. Tubianosa GT, Luuides S. Casas Ma. Profile and outcome of total anomalous pulmonary venous return surgery: 5 year study. *Philippine J of Cardiology*. 2006; 34(1): 37-41.

21. Ammash NM, Seward JB, Warres CA, Heidi M Connolly, Patrick W O' Leang, Gordon K Daniel-son. Partial anomalous pulmonary venous connection: diagnosis by transesophageal echocardiography. *J of the American College of Cardiology*. 1997; 29(6): 1351-1358. doi: [10.1016/S0735-1097\(97\)82758-1](https://doi.org/10.1016/S0735-1097(97)82758-1)

22. Emmel M, Sreeram N. Total Anomalous pulmonary vein connection: diagnosis, management, and outcome. *Current treatment option in Cardiovascular medicine*. 2004; 6: 423-429. doi: [10.1007/s11936-004-0026-3](https://doi.org/10.1007/s11936-004-0026-3)

23. Senocak F, Ozme S, Bilgic A, Ozkutlu s, Ozer S, Saraclar M. Partial anomalous pulmonary venous return-evaluation of 51 cases. *Jpn Heart J*. 1994; 35: 43-50.

24. Humpl T, Reineker C, Manlhiot C, Dipchand AI, Coles JG, Crindle MC. Cor triatriatum sinistrum in childhood. A single institution's experiences. *Canadian J of Cardiology*. 2010; 26(7): 371-376.