

## Short Communication

### \*Corresponding author

Steven R. Lindheim, MD, MMM

Professor of Obstetrics and Gynecology  
Director

Division of Reproductive Endocrinology  
and Infertility Miami Valley Hospital  
128 Apple Street

Suite 3800 Weber CHE Dayton  
OH 45409, USA

Tel. (937) 208-2301

Fax: (937) 222-7255

E-mail: [steven.lindheim@wright.edu](mailto:steven.lindheim@wright.edu)

Volume 2 : Issue 5

Article Ref. #: 1000GOROJ2126

### Article History

Received: March 12<sup>th</sup>, 2016

Accepted: April 19<sup>th</sup>, 2016

Published: April 25<sup>th</sup>, 2016

### Citation

Coyne K, Winter III TC, Maxwell R, Lindheim SR. Changing the algorithm in the evaluation of pelvic anatomy in the infertile patient: is hysterosalpingo contrast sonography with saline-air device the appropriate test for everyone? *Gynecol Obstet Res Open J.* 2016; 2(5): 126-128. doi: [10.17140/GOROJ-2-126](https://doi.org/10.17140/GOROJ-2-126)

### Copyright

©2016 Lindheim SR. This is an open access article distributed under the Creative Commons Attribution 4.0 International License (CC BY 4.0), which permits unrestricted use, distribution, and reproduction in any medium, provided the original work is properly cited.

# Changing the Algorithm in the Evaluation of Pelvic Anatomy in the Infertile Patient: Is Hysterosalpingo Contrast Sonography With Saline-Air Device the Appropriate Test for Everyone?

Kathryn Coyne, MS<sup>1</sup>; Thomas C. Winter III, MD<sup>2</sup>; Rose Maxwell, PhD<sup>1</sup>; Steven R. Lindheim, MD, MMM<sup>1\*</sup>

<sup>1</sup>Department of Obstetrics and Gynecology, Wright State University, Boonshoft School of Medicine, Dayton, OH, USA

<sup>2</sup>Department of Radiology, University of Utah, Salt Lake City, UT, USA

The evaluation of the fallopian tubes is an essential part of the infertility workup, with abnormalities related to the fallopian tubes accounting for up to 40% of female subfertility.<sup>1</sup> Laparoscopy is still considered the gold standard in the diagnostic evaluation of fallopian tubes, though the hysterosalpingogram (HSG) has long been recognized as complementary to laparoscopy, since tubal anatomy can be distinctly be seen.<sup>2</sup> That said, previous investigations using laparoscopy as the gold standard demonstrate HSG has a sensitivity and specificity of 53% and 87%, respectively, for any tubal pathology and 46% and 95%, respectively, for bilateral tubal pathology.<sup>3</sup>

In last few years, there has been a move away from these methods and towards the use of Hysterosalpingo Contrast Sonography (HyCoSy). Laparoscopy mandates regional or general anesthesia and incurs significant operative costs and risks.<sup>4</sup> In contrast, while HSG obviates the need for hysteroscopy and/or laparoscopy, it is associated with exposure to ionizing radiation and the need for iodinated contrast material.<sup>5-8</sup> While HyCoSy has been advocated as an alternative to the HSG since the 1980s, its use in evaluating tubal patency has been limited as the normal fallopian tube is a poor sonic reflector, devoid of the defined interfaces that produce clear organ outlines.<sup>9-11</sup> Various agents to enhance transvaginal ultrasound visualization of the fallopian tubes have been described; however, given storage issues, expense, and lack of FDA approval, it has obviated their routine use in the office setting. Others have substituted a mixture of saline and/or air for more elaborate distending media: some vigorously shake a syringe of saline and air creating air bubbles immediately before infusion, while others have described filling a syringe with both air and saline and tilting the syringe with the intermittent infusion of air followed by saline in increments of 1-3 mL.<sup>12-14</sup> Recently, the FDA approved saline-air devices, which create and deliver a constant alternating pattern of saline and air as a continuous stream in a controlled fashion allowing for fallopian tube evaluation under ultrasound guidance.<sup>15</sup>

The allure of the HyCoSy-saline-air device (HyCoSy-SAD) is that: 1) it is a relatively quick and non-invasive procedure that can be done in the office setting and does not require exposure to ionizing radiation; 2) a number of studies, including a meta-analysis, have demonstrated concordance rates of 83% to 100% and a diagnostic accuracy of 65% to 85% between HyCoSy-SAD, laparoscopy, and HSG in establishing tubal patency when detecting tubal pathology<sup>2,8-19</sup>; and 3) the low cost of air and saline solutions makes this particular HyCoSy procedure attractive to determine tubal patency (price points range from USD 10-40 for the SIS catheter and USD 90-150 for the saline-air device).

However, caution needs to be heeded when embracing new technology and discarding gold standards. Work by our research team concurs with reports from other investigators that

Algorithm for Initial Infertility Assessment

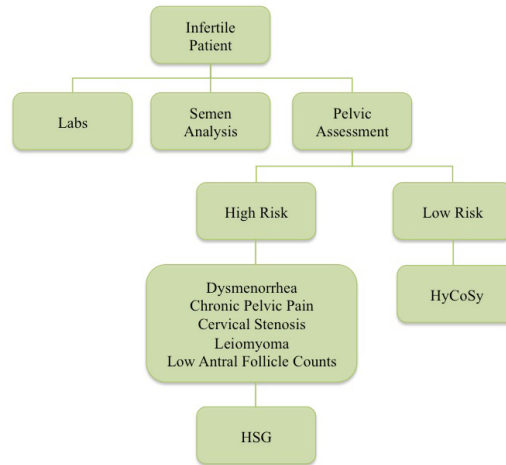


Figure 1: Algorithm for Initial Infertility Assessment. The initial workup for an infertile patient should include labs, semen analysis, and a pelvic assessment. If the patient presents with risk factors for poor visualization under HyCoSy, pelvic assessment should be executed firstly with hysterosalpingogram (HSG). If the patient carries low risk, pelvic assessment may proceed directly with HyCoSy.

Risk factors Associated with Indeterminate-Inconclusive HyCoSy-SAD

- Dysmenorrhea
- Cervical Stenosis
- Uterine Fibroids
- Low Antral Follicle Counts

Figure 2: Risk Factors associated with Indeterminate-Inconclusive HyCoSy-SAD. The risk factors for poor visualization resulting in indeterminate-inconclusive HyCoSy-SAD include dysmenorrhea, cervical stenosis, uterine fibroids (leiomyoma), and low antral follicle counts.

indicate a high degree of concordance with HSG when using a HyCoSy-SAD to detect tubal patency; however, the converse is not true with respect to tubal occlusion.<sup>20</sup> Indeterminate or inconclusive studies using the HyCoSy-SAD tend to be associated with patients with cervical stenosis, as air bubbles are less likely to traverse the cervix and ascend upwards towards the fallopian tubes, and with diminished ovarian reserve, where smaller ovaries may make it harder to track the air-bubbles. In our experience, there is nearly a two times greater likelihood of incorrectly reading a fallopian tube as occluded on HyCoSy-SAD, and between 5-10% of seemingly normal HyCoSy-SAD studies are identified as phimotic or having loculated spill on HSG. Unlike the distinct tubal anatomy seen with the HSG, distinct tubal architecture cannot be delineated with HyCoSy-SAD unless a hydrosalpinx is seen on ultrasound.

Perhaps before we leap to the HyCoSy-SAD as a first-step procedure of choice in the assessment of tubal patency, we should consider creating an algorithm and triaging patients based upon risk factors (Figure 1). The HSG should be considered in patients with cervical stenosis and without easily apparent ovaries. Other risk factors for an unsuccessful HyCoSy-SAD study to be considered should be severe dysmenorrhea (indicating possible endometriosis and/or pelvic adhesions) and uterine

fibroids, which make identification of the uterine cornua and ovaries challenging (Figure 2). While the HyCoSy-SAD allows for the simple delivery of saline and air as a continuous stream in a controlled fashion, further refinement with proper patient selection may advance this procedure as a useful first-line modality in the evaluation of tubal patency and reduce the false positives and negative studies.

CONFLICTS OF INTEREST: None.

REFERENCES

1. Bradshaw KD, Carr BR. Modern diagnostic evaluation of the infertile couple. In: Carr BR, Blackwell RE, eds. *Textbook of Reproductive Medicine*. 2<sup>nd</sup> ed. East Norwalk, CT, USA: Appleton & Lange; 1998: 443-452.
2. Al-Badawi IA, Fluker MR, Bebbington MW. Diagnostic laparoscopy in infertile women with normal hysterosalpingograms. *J Reprod Med*. 1999; 44: 953-957.
3. Okonofua FE, Essen UI, Nimalaraj T. Hysterosalpingography versus laparoscopy in tubal infertility: comparison based on findings at laparotomy. *Int J Gynaecol Obstet*. 1989; 28: 143-147.

4. Musich JR, Behrman SJ. Infertility laparoscopy in perspective: review of five hundred cases. *Am J Obstet Gynecol.* 1982; 143: 293-303.
5. Siegler AM. Hysterosalpingography. In: Wallach E, Zacur H, eds. *Reproductive Medicine and Surgery.* 1<sup>st</sup> ed. St Louis, MO, USA: Mosby-Year Book; 1995: 481-508.
6. Karande VC, Pratt DE, Balin MS, Levrant SG, Morris RS, Gleicher N. What is the radiation exposure to patients during a gynecoradiologic procedure? *Fertil Steril.* 1997; 67: 401-403. doi: [10.1016/S0015-0282\(97\)81931-0](https://doi.org/10.1016/S0015-0282(97)81931-0)
7. Strandell A, Bourne T, Bergh C, Granberg S, Asztely M, Thorburn J. The assessment of endometrial pathology and tubal patency: a comparison between the use of ultrasonography and X-ray hysterosalpingography for the investigation of infertility patients. *Ultrasound Obstet Gynecol.* 1999; 14: 200-204. doi: [10.1046/j.1469-0705.1999.14030200.x](https://doi.org/10.1046/j.1469-0705.1999.14030200.x)
8. Darby SC, Wall BF. The genetically significant dose from diagnostic radiology in Great Britain. *Radiography.* 1981; 47: 200-202.
9. Nannini R, Chelo E, Branconi F, Tantini C, Scarselli GF. Dynamic echohysteroscopy: a new diagnostic technique in the study of female infertility. *Acta Eur Fertil.* 1981; 12: 165-171.
10. Richman TS, Viscomi GN, de Cherney A, Polan ML, Alcebo LO. Fallopian tubal patency assessed by ultrasound following fluid injection. Work in progress. *Radiology.* 1984; 152: 507-510. doi: [10.1148/radiology.152.2.6539931](https://doi.org/10.1148/radiology.152.2.6539931)
11. Mitri FF, Andronikou AD, Perpinyal S, Hofmeyr GJ, Sonnendecker EW. A clinical comparison of sonographic hydrotubation and hysterosalpingography. *Br J Obstet Gynaecol.* 1991; 98: 1031-1036. doi: [10.1111/j.1471-0528.1991.tb15342.x](https://doi.org/10.1111/j.1471-0528.1991.tb15342.x)
12. Volpi E, Zuccaro G, Patriarca A, Rustichelli S, Sismondi P. Transvaginal sonographic tubal patency testing using air and saline solution as contrast media in a routine infertility clinic setting. *Ultrasound Obstet Gynecol.* 1996; 7: 43-48. doi: [10.1046/j.1469-0705.1996.07010043.x](https://doi.org/10.1046/j.1469-0705.1996.07010043.x)
13. Chenia F, Hofmeyr GJ, Moolla S, Oratis P. Sonographic hydrotubation using agitated saline: A new technique for improving fallopian tube visualization. *Br J Radiol.* 1997; 70: 833-836. doi: [10.1259/bjr.70.836.9486049](https://doi.org/10.1259/bjr.70.836.9486049)
14. Jeanty P, Besnard S, Arnold A, Turner C, Crum P. Air-contrast sonohysterography as a first step assessment of tubal patency. *J Ultrasound Med.* 2000; 19: 519-527. Web site. <http://www.jultrasoundmed.org/content/19/8/519.long>. Accessed March 11, 2016.
15. Malik S, Always SM, Gustafson K, Sanfillippo JS. Evaluation of tubal patency with the femvue™ saline air device: are we ready to move back to the office. *Fertil Steril.* 2013; 100(3): S38. doi: [10.1016/j.fertnstert.2013.07.729](https://doi.org/10.1016/j.fertnstert.2013.07.729)
16. Singh M, Diamond MP, Awonuga A, Shavell V, Bolnick J, Puscheck EE. An office-based observational study of 10 female infertility evaluations performed using sono HSG with the FemVue Saline-Air Device. *Fertil Steril.* 2013; 100(3): 100(3): S34. doi: [10.1016/j.fertnstert.2013.07.730](https://doi.org/10.1016/j.fertnstert.2013.07.730)
17. Exacoustos C, Zupi E, Carusotti C, Lanzi G, Marconi D, Arduini D. Hysterosalpingo-contrast sonography compared with hysterosalpingography and laparoscopic dye perturbation to evaluate tubal patency. *J Am Assoc Gynecol Laparosc.* 2003; 10: 367-372. doi: [10.1016/S1074-3804\(05\)60264-2](https://doi.org/10.1016/S1074-3804(05)60264-2)
18. Deichert U, Schleif R, van de Sandt M, Juhnke I. Transvaginal hysterosalpingo-contrast-sonography (Hy-Co-Sy) compared with conventional tubal diagnostics. *Hum Reprod.* 1989; 4: 418-424. Web site. <http://humrep.oxfordjournals.org/content/4/4/418.short>. Accessed March 11, 2016.
19. Hamed HO, Shahin AY, Elsamman AM. Hysterosalpingo-contrast sonography versus radiographic hysterosalpingography in the evaluation of tubal patency. *Int J Gynaecol Obstet.* 2009; 105: 215-217. doi: [10.1016/j.ijgo.2009.02.001](https://doi.org/10.1016/j.ijgo.2009.02.001)
20. Robertshaw IM, Sroga JM, Batcheller AE, et al. Hysterosalpingo-contrast sonography with a saline-air device is equivalent to hysterosalpingography only in the presence of tubal patency. *J Ultrasound Med.* 2016; 35: e1-e8.