

## Brief Research

### Corresponding author

**Masafumi Koshiyama, MD, PhD**  
Professor  
Department of Women's Health  
Graduate School of Human Nursing  
The University of Shiga Prefecture  
Shiga, 522-8533, Japan  
Tel. +81-749-28-8664  
Fax: +81-749-28-9532  
E-mail: [koshiyamam@nifty.com](mailto:koshiyamam@nifty.com)

Volume 3 : Issue 1

Article Ref. #: 1000WHOJ3117

### Article History

Received: December 16<sup>th</sup>, 2016

Accepted: January 6<sup>th</sup>, 2017

Published: January 6<sup>th</sup>, 2017

### Citation

Koshiyama M, Ukita S, Ueda M, et al. Cesarean hysterectomy for abnormal placentation using balloon occlusion of the common iliac artery: Case series. *Women Health Open J.* 2017; 3(1): 15-20. doi: [10.17140/WHOJ-3-117](https://doi.org/10.17140/WHOJ-3-117)

### Copyright

©2017 Koshiyama M. This is an open access article distributed under the Creative Commons Attribution 4.0 International License (CC BY 4.0), which permits unrestricted use, distribution, and reproduction in any medium, provided the original work is properly cited.

# Cesarean Hysterectomy for Abnormal Placentation Using Balloon Occlusion of the Common Iliac Artery: Case Series

**Masafumi Koshiyama, MD, PhD<sup>1,2</sup>; Shingo Ukita, MD<sup>2,3</sup>; Masashi Ueda, MD<sup>2,4</sup>; Kenji Hishikawa, MD<sup>2,5</sup>; Yoko Furukawa, CNM<sup>1</sup>; Yumi Itaya, CNM, PhD<sup>1</sup>; Yumiko Watanabe, CNM<sup>1</sup>; Natsuko Motooka Meguro, CNM<sup>1</sup>; Haruko Horiuchi, CNM<sup>1</sup>; Makiko Oowaki, CNM<sup>1</sup>**

<sup>1</sup>Department of Women's Health, Graduate School of Human Nursing, The University of Shiga Prefecture, Shiga, Japan

<sup>2</sup>Department of Obstetrics and Gynecology, Otsu Red Cross Hospital, Shiga, Japan

<sup>3</sup>Medical Corporation Sesezaji Ukita Clinic, Shiga, Japan

<sup>4</sup>Department of Gynecology and Obstetrics, Graduate School of Medicine, Kyoto University, Kyoto, Japan

<sup>5</sup>Department of Obstetrics and Gynecology, Shonan Kamakura General Hospital, Kanagawa, Japan

## ABSTRACT

**Objective:** To investigate the management and safety of cesarean hysterectomy using common iliac artery balloon occlusion (CIABO) for placenta percreta/increta/accreta.

**Patients and Methods:** We performed 4 cesarean hysterectomies at 33-36 weeks of gestation. All 4 patients had undergone cesarean section previously and had placenta previa. The patients then underwent cesarean hysterectomy using CIABO.

**Results:** Two patients were ultimately diagnosed with placenta percreta, one with placenta increta and 1 with placenta accreta. The actual invasive depth of the placenta tended to be deeper than had been diagnosed before surgery. The volume of blood loss in the 3 patients whose balloons were placed in the common iliac artery from the start ranged from 1361-3851 ml (including amniotic fluid and fewer amounts of bleeding than these), and these patients received only autologous blood transfusion. All 4 patients were ultimately discharged from the hospital without any complications.

**Conclusion:** We were able to control the blood loss well using CIABO during cesarean hysterectomy. We confirm that our method of managing cesarean hysterectomy for abnormal placentation can be conducted safely.

**KEY WORDS:** Cesarean hysterectomies; Common iliac artery balloon occlusion; Placenta percreta; Placenta accrete; Placenta accreta.

**ABBREVIATIONS:** CIABO: Common Iliac Artery Balloon Occlusion; IIABO: Internal Iliac Artery Balloon Occlusion.

## INTRODUCTION

The rates of abnormal placentation, such as placenta accreta, increta, and percreta, have increased.<sup>1,2</sup> The condition in which the placenta invades the entire depth of the uterine wall is called "placenta percreta". Placenta accreta and increta are less severe variants of the same condition.<sup>3,4</sup> The major risk factors of abnormal placentation are a placenta previa and previous cesarean section.<sup>5,6</sup> The recent increased frequency of cesarean section has resulted in a high incidence of abnormal placentation.

Placenta accreta, increta, and percreta often result in massive peripartum hemorrhaging and are sources of maternal morbidity and mortality in modern obstetrics.<sup>7-10</sup> In particular,

uterine rupture and profuse hemorrhaging have been associated with placenta percreta.<sup>11</sup> Placenta percreta represents the most difficult management situation of these disorders.

The options for treating abnormal placentation include both conservative and extirpative approaches.<sup>12</sup> The generally accepted treatment for the most severe form of abnormal attachment of the placenta is cesarean hysterectomy without attempts to detach the placenta. Recently, the role of interventional radiology in the field of obstetrical hemorrhaging has been widely investigated. Preoperative internal iliac artery balloon occlusion (IIABO) has been widely performed to reduce the blood loss during cesarean hysterectomy.<sup>13-16</sup>

We herein report the safe performance and management of cesarean hysterectomy using common iliac artery balloon occlusion (CIABO).

#### PATIENTS AND METHODS

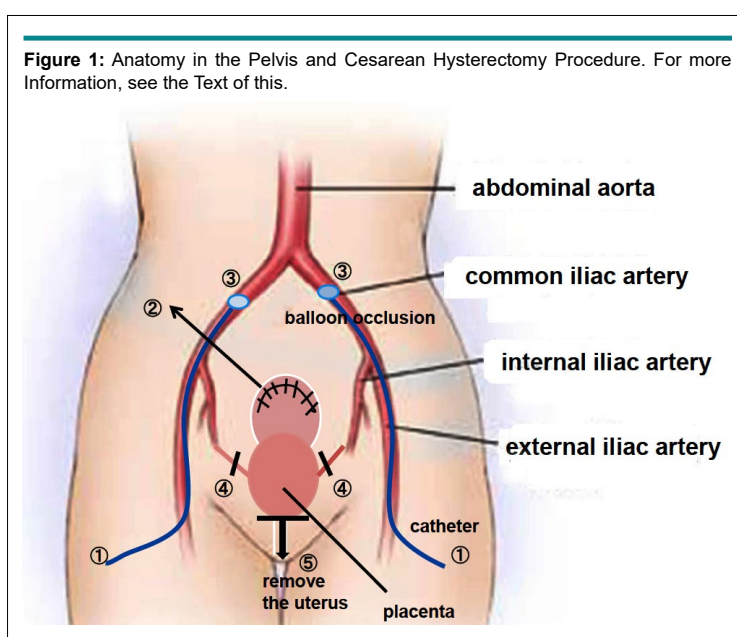
Four patients who underwent cesarean hysterectomy at 33-36 weeks of gestation using balloon occlusion at Otsu Red Cross Hospital, (Shiga, Japan) from 2009-2013 were recruited for the study. We informed the patients and their families of all of the risks involved in the surgery. All the 4 patients had previously undergone cesarean section. They had placenta previa and myometrial involvement on old operation scars. The myometrial invasion depths of the placenta were determined on ultrasonography (US) and magnetic resonance imaging (MRI). All the 4 patients then underwent cesarean hysterectomy using CIABO (In one case, the balloon was moved from the internal iliac artery to the common iliac artery in order to reduce blood loss). The

study protocol was approved by the ethics committee of Otsu Red Cross Hospital, Otsu, Shiga Prefecture, Japan.

#### Procedure of Cesarean Hysterectomy

Prior to the surgery, no infiltrations of the placenta into the mucosa of the urinary bladder were shown by cystoscopy, and bilateral ureteral stent-catheters were inserted by urologists. Under general anesthesia, the balloon catheters were inserted *via* the bilateral femoral arteries and fixed in the common iliac arteries in the operation room by radiologists (Figure 1). During cesarean hysterectomy, these balloons were not inflated. The surgeons started the cesarean section, followed by a vertical incision of the abdominal skin and transverse uterine fundal incision. In case 1 alone, the balloons were first fixed in the internal iliac arteries, but were subsequently moved to the common iliac arteries due to a large amount of blood loss.<sup>17</sup>

As soon as the child was born, the balloons in the bilateral common iliac arteries were inflated. The uterine incision was sutured without detaching the placenta. This was followed by performing a total abdominal hysterectomy as shown in Figure 1. The procedure entailed; ligating and cutting of the uterine arteries at the point of intersection with the ureter. Incision of recto-cervical fold of peritoneum was made to have access to the posterior vaginal fornix followed by a circumferential incision of the vagina at the level of the vaginal fornices. Ligating and cutting the bilateral round ligaments and ligament ovaries were performed. We then incised the left and right connective tissues of the uterus (the sites of ascending and descending branches of uterine arteries) in the upper direction. We were then able to remove the uterus completely. While repairing the incisions, the



**Table 1:** The Clinical Data of 4 Patients Treated with Cesarean Hysterectomy using Balloon Occlusion of the Common Iliac Artery.

Patient	Case 1 <sup>17</sup>	Case 2	Case 3	Case 4
Age	36 yr	32 yr	35 yr	33 yr
Clinical diagnosis	Preg. 35 w 6 d previous 4 times c-sec total placenta previa s/o placenta increta	Preg. 35 w 5 d previous 1 time c-sec total placenta previa s/o placenta accreta	Preg. 36 w 0 d previous 1 time c-sec total placenta previa s/o placenta increta	Preg. 33 w 5 d previous 1 time c-sec total placenta previa s/o placenta accreta
Balloon position	internal iliac a. =>common iliac	common iliac a.	common iliac a.	common iliac a.
Occluded time	1 hr 15 min	56 min	50 min	55 min
Blood loss	7720 ml (including amniotic fluid)	3781 ml (including amniotic fluid)	3851 ml (including amniotic fluid)	1361 ml (including amniotic fluid)
Blood transfusion	Autologous blood 1200 ml MAP 10 iu, FFP 10 iu	Autologous blood 1050 ml	Autologous blood 1750 ml	Autologous blood 1200 ml
Complication	None	None	None	None
Surgical time	2 hr 49 min	3 hr 43 min	4 hr 25 min	2 hr 48 min
Pathologic diagnosis	Placenta percreta	Placenta increta	Placenta percreta	Placenta accreta

bilateral catheters were removed.

The success of these procedures was evaluated based on the amount of blood loss and presence of complications.

## RESULTS

The clinical data of 4 patients treated with cesarean hysterectomy using balloon occlusion of the common iliac artery are shown in Table 1.

The patients' ages ranged from 32-36 years old (mean 34 years old). Two were ultimately diagnosed with placenta percreta, 1 with placenta increta and one with placenta accreta. There was only a case where the clinical diagnosis before surgery corresponded to the final diagnosis after surgery. The actual invasive depth of the placenta was deeper than that estimated before surgery in three cases. On comparing the diagnoses before and after surgery, the final diagnoses were worse after surgery in three cases. All of the placentas were attached to the old operation scars. However, the myometrial invasion depths of the placentas were found to have not been accurately determined on US and MRI.

As we previously reported, we were unable to control the massive bleeding with IIABO.<sup>17</sup> We therefore, immediately moved the balloon from the internal iliac artery to the common iliac artery. Because of our experience with case 1, we placed the balloon in the common iliac arteries from the start of the operation in cases 2-4.

Regarding the outcomes of cesarean hysterectomy, the total volume of blood lost was 7720 ml in case 1, 3781 ml in case 2, 3851 ml in case 3 and 1361 ml in case 4. The volume of blood lost in the 3 patients whose balloons were placed in the common

iliac artery from the start of the surgery ranged from 1361-3851 ml (including amniotic fluid and fewer amounts of bleeding than these), and these patients received only autologous blood transfusion (1050 ml, 1200 ml and 1750 ml; mean 1333 ml). The time of occlusion of the common iliac arteries ranged from 50 min to 1h 15 min with intervals of 10 min for deflating the balloons.

Complications did not occur in any of the 4 patients treated with these methods and management strategies. Our staff (midwives and doctors) visited the patients many times and also supported their mental healing. The 4 patients were discharged from our hospital on the 7<sup>th</sup> or 8<sup>th</sup> post-operative day. Post-operative evaluation of the patients 30 days after the surgery did not reveal any complications with all mothers and children being in good health.

## DISCUSSION

Although, the impact of morbidly abnormal placentation on pregnancy outcomes has been well-described, no randomized trials and few studies have examined the management of pregnancies complicated by this disorder. As a result, the recommendations for its management are based on case series and reports, personal experience and expert opinion.

The options for treating abnormal placentation include both conservative and extirpative approaches. O'Brien et al<sup>12</sup> reported that conservative treatment was preferred in hemodynamically stable patients. However, the patients treated with such conservative therapy are at continued risk of massive hemorrhaging and require prolonged intensive observation. Postpartum hemorrhage necessitating hysterectomy has been observed from 3 hours to 7 weeks after delivery in women who were initially managed conservatively.<sup>18,19</sup> In contrast, the extirpative approach is completed within a certain period and usually re-

quires an adjuvant hemostatic technique, such as pre-operative placement of balloon occlusion.<sup>13-16</sup> In our hospital, we have safely performed cesarean hysterectomies using arterial balloon occlusion. The size of their balloons should be optimally tailored to the anatomically targeted vessels being occluded using pre-operative MRI, because a poorly occluded vessel will yield incomplete hemostasis and increased hemorrhage.<sup>20</sup>

As we previously reported in case 1,<sup>17</sup> we attempted to perform IIABO to treat patients with placenta percreta. However, massive vaginal bleeding suddenly occurred due to detachment of the placenta following uterine contraction during cesarean hysterectomy. A quick shift from IIABO to CIABO was very effective in reducing the volume of blood loss. The use of IIABO in patients has reported no improved surgical outcomes compared with patients without the treatment.<sup>21,22</sup> Failure of IIABO can be explained by the presence of extensive anastomosis bridging the internal and external iliac arteries.<sup>23</sup> We therefore, subsequently performed CIABO during cesarean hysterectomy (cases 2-4). Theoretically, proximal balloon occlusion of the large vessels such as the aorta and common iliac arteries is more effective for hemostasis. However, it is possible to cause the potential risk of ischemia to the extremities if prolonged occlusion is required in these cases.<sup>20</sup>

In cases 2-4, we were able to control the hemorrhage using CIABO during cesarean hysterectomy (range of blood loss: 1361-3851 ml including amniotic fluid). Regarding blood transfusion, we were able to use autologous blood alone in cases 2-4. In addition, all of the patients were discharged from our hospital without any complications, such as thrombus, embolism, coagulopathy, severe anemia, hematoma, infection or organ disorders. Balloon occlusion has been thought not to stop blood flow completely.<sup>24</sup>

While a few other reports have also described the superiority of CIABO to other methods,<sup>23,25-28</sup> rare cases complicated by thrombosis have been reported after CIABO, necessitating conservative managements with a heparin drip.<sup>28-30</sup> Therefore, the occlusion time should be as short as possible.

Following cesarean hysterectomy, the patients are at risk for complications, such as persistent coagulopathy, anemia, thromboembolism and other organ disorders, and death. As such, the patients may experience anxiety or even post-traumatic stress disorder. They may also experience pain, uterine loss, numbness, and issues in communicating or bonding with their baby. These patients therefore, require close monitoring, sometimes in an intensive-care setting.<sup>31</sup> Psychiatrists, special midwives and social workers should focus on the mental health care of these patients. We were unable to follow the patients for more than a month after surgery because we could not set up a system of the further examination. Understanding patients' experiences with emergency peripartum hysterectomy can help practitioners not only address patients' initial complications but also provide needed long-term support.<sup>32</sup>

## CONCLUSIONS

CIABO during cesarean hysterectomy was effective in controlling blood loss in 4 cases and can be conducted safely. Given that only 4 cases were managed using this technique in this study, further evaluation of the efficacy and outcomes of CIABO is needed. Patients treated with cesarean hysterectomy should be managed by close monitoring in an intensive-care setting with ample support for their mental healthcare.

## CONFLICTS OF INTEREST

The authors declare that they have no conflicts of interest.

## REFERENCES

1. Weckstein LM, Masserman JSH, Gaitte TJ. Placenta accrete: A problem of increasing clinical significance. *Obstet Gynecol.* 1986; 69: 480-482. Web site. <https://www.ncbi.nlm.nih.gov/pubmed/3808530>. Accessed December 15, 2016
2. Khan M, Sachdeva P, Arora R, Bhasin S. Conservative management of morbidity adherent placenta- A case report and review literature. *Placenta.* 2013; 34: 963-966. doi: [10.1016/j.placenta.2013.04.016](https://doi.org/10.1016/j.placenta.2013.04.016)
3. Morison JE. Placenta accrete. A clinicopathologic review of 67 cases. *Obstet Gynecol Annu.* 1978; 7: 107-123. Web site. <https://www.ncbi.nlm.nih.gov/pubmed/662213>. Accessed December 15, 2016.
4. Miller D, Chollet JA, Goodwin TM. Clinical risk factors for placenta previa-placenta accrete. *Am J Obstet Gynecol.* 1997; 177: 210-214.
5. Kistner RW, Hertig AT, Reid DE. Simultaneously occurring placenta previa and placenta accrete. *Surg Gynecol Obstet.* 1952; 94: 141-151. Web site. <https://www.ncbi.nlm.nih.gov/pubmed/14901248>. Accessed December 15, 2016.
6. Clark SL, Koonings PP, Phelan JP. Placenta previa accrete and prior cesarean section. *Obstet Gynecol.* 1984; 66: 89-92. Web site. <https://www.ncbi.nlm.nih.gov/pubmed/4011075>. Accessed December 15, 2016.
7. Rossi AC, Lee RH, Chmait RH. Emergency postpartum hysterectomy for uncontrolled postpartum bleeding: A systematic review. *Obstet Gynecol.* 2010; 115: 637-644. doi: [10.1097/AOG.0b013e3181cfc007](https://doi.org/10.1097/AOG.0b013e3181cfc007)
8. Wright JD, Pri-Paz S, Herzog TJ, et al. Predictors of massive blood loss in women with placenta accrete. *Am J Obstet Gynecol.* 2011; 205: 38e1-6. doi: [10.1016/j.ajog.2011.01.040](https://doi.org/10.1016/j.ajog.2011.01.040)
9. Bateman BT, Mhyre JM, Callaghan WM, Kukina EV. Peripartum hysterectomy in the United States: Nationwide 14 year

- experience. *Am J Obstet Gynecol.* 2012; 206: 63 e1-8. doi: [10.1016/j.ajog.2011.07.030](https://doi.org/10.1016/j.ajog.2011.07.030)
10. Eshkoli T, Weintraub Ay, Sergienko R, Sheiner E. Placenta accrete: Risk factors, perinatal outcomes, and consequences for subsequent births. *Am J Obstet Gynecol.* 2013; 208: 219.e1-e7. doi: [10.1016/j.ajog.2012.12.037](https://doi.org/10.1016/j.ajog.2012.12.037)
11. Lloyd-Jones R, Winterton WR. Spontaneous rupture of the uterus due to placenta percreta: A case report. *J Obstet Gynecol Br Common.* 1961; 68: 273-276. Web site. <https://www.ncbi.nlm.nih.gov/pubmed/8697340>. Accessed December 15, 2016.
12. O'Brien JM, Barton JR, Donaldson ES. The management of placenta percreta: Conservative and operative strategies. *Am J Obstet Gynecol.* 1996; 175: 1632-1638. doi: [10.1016/S0002-9378\(96\)70117-5](https://doi.org/10.1016/S0002-9378(96)70117-5)
13. Dubois J, Garel L, Grignon A, Lemay M, Leduc L. Placenta percreta: Balloon occlusion and embolization of the internal iliac arteries to reduce intraoperative blood losses. *Am J Obstet Gynecol.* 1997; 176: 723-726. Web site. <https://www.ncbi.nlm.nih.gov/pubmed/9077641>. Accessed December 15, 2016.
14. Ojala K, Perälä J, Kariniemi J, Ranta P, Raudaskoski T, Terkay A. Arterial embolization and prophylactic catheterization for the treatment for severe obstetric hemorrhage. *Acta Obstet Gynecol Scand.* 2005; 84: 1075-1080. doi: [10.1111/j.0001-6349.2005.00727.x](https://doi.org/10.1111/j.0001-6349.2005.00727.x)
15. Tan CH, Tay KH, Steah K, et al. Perioperative endovascular internal iliac artery occlusion balloon placement in management of placenta accreta. *AJR.* 2007; 189: 1158-1163. doi: [10.2214/AJR.07.2417](https://doi.org/10.2214/AJR.07.2417)
16. Carnevale FC, Kondo MM, de Oliveira Sousa W Jr, et al. Perioperative temporary occlusion of the internal iliac arteries as prophylaxis in cesarean section at risk of hemorrhage in placenta accreta. *Cardiovasc Intervent Radiol.* 2011; 34: 758-764. doi: [10.1007/s00270-011-0166-2](https://doi.org/10.1007/s00270-011-0166-2)
17. Hishikawa K, Koshiyama M, Ueda M, et al. Exchange of intraoperative balloon occlusion of the internal iliac artery for the common iliac artery during cesarean hysterectomy in a patient with placenta percreta. *Am J Case Rep.* 2013; 14: 409-411. doi: [10.12659/AJCR.889449](https://doi.org/10.12659/AJCR.889449)
18. Jaffe R, DuBeesheter B, Sherer DM, Thompson EA, Woods JR Jr. Failure of methotrexate for the term placenta percreta. *Am J Obstet Gynecol.* 1994; 171: 558-559. doi: [10.1016/0002-9378\(94\)90300-X](https://doi.org/10.1016/0002-9378(94)90300-X)
19. Veenstra M, Spinder T, Dekker GA, van Geijjin HP. Post partum intra-abdominal hemorrhage due to placenta percreta. *Eur J Onstet Gynecol.* 1995; 62: 253-256. doi: [10.1016/0301-2115\(95\)02183-8](https://doi.org/10.1016/0301-2115(95)02183-8)
20. Knuttinen MG, Jani A, Gaba RC, Bui JT, Carrillo TC. Balloon occlusion of the hypogastric arteries in the management of placenta accrete: A case report and review of the literature. *Semin Intervent Radiol.* 2012; 29: 161-168. doi: [10.1055/s-0032-1326924](https://doi.org/10.1055/s-0032-1326924)
21. Levine AB, Kuhlman K, Bonn J. Placenta accreta: Comparison of cases managed with and without pelvic artery balloon catheters. *J Matern Fetal Med.* 1999; 8: 173-176. doi: [10.1002/\(SICI\)1520-6661\(199907/08\)8:4<173::AID-MFM7>3.0.CO;2-V](https://doi.org/10.1002/(SICI)1520-6661(199907/08)8:4<173::AID-MFM7>3.0.CO;2-V)
22. Bodner LJ, Noshier JL, Gribbin C, Siegel RL, Beale S, Scorza W. Balloon-assisted occlusion of the internal iliac arteries in patients with placenta accreta/percreta. *Cardiovasc Intervent Radiol.* 2006; 29: 354-361. doi: [10.1007/s00270-005-0023-2](https://doi.org/10.1007/s00270-005-0023-2)
23. Shih JC, Liu KL, Shyu MK. Temporary balloon occlusion of the common iliac artery: New approach to bleeding control during cesarean hysterectomy for placenta percreta. *Am J Obstet Gynecol.* 2005; 193: 1756-1758. doi: [10.1016/j.ajog.2005.08.033](https://doi.org/10.1016/j.ajog.2005.08.033)
24. Matsubara S, Nonaka H, Kobayashi M, Kuwata T, Fujii H. Intrauterine balloon occlusion during cesarean hysterectomy for placenta previaaccreta: The internal or common iliac artery? *Acta Obstet Gynecol Scand.* 2014; 93: 122-123. doi: [10.1111/aogs.12273](https://doi.org/10.1111/aogs.12273)
25. Clausen C, Stensballe J, Albrechtsen CK, Hansen MA, Lonn L, Langhoff-Roos J. Balloon occlusion of the internal iliac arteries in the multidisciplinary management of placenta percreta. *Acta Obstet Gynecol Scand.* 2013; 92: 386-391. doi: [10.1111/j.1600-0412.2012.01451.x](https://doi.org/10.1111/j.1600-0412.2012.01451.x)
26. Nishida Y, Hirakawa T, Utsunomiya Y, Tsusue H, Narahara H. Transfundal uterine incision performed with prophylactic common iliac artery balloon occlusion for patient with placenta previatotalis. *Clin Med Insights Case Rep.* 2012; 5: 93-97. doi: [10.4137/CCRep.S9777](https://doi.org/10.4137/CCRep.S9777)
27. Minas V, Gul N, Shaw E, Mwenenchanya S. Prophylactic balloon occlusion of the common iliac arteries for the management of suspected placenta accreta/percreta: Conclusions from a short case series. *Arch Gynecol Obstet.* 2015; 291: 461-465. doi: [10.1007/s00404-014-3436-9](https://doi.org/10.1007/s00404-014-3436-9)
28. Chou MM, Kung HF, Hwang JI, Chen WC, Tseng JJ. Temporary prophylactic intravascular balloon occlusion of the common iliac arteries before cesarean hysterectomy for controlling operative blood loss in abnormal placentation. *Taiwan J Obstet Gynecol.* 2015; 54: 493-498. doi: [10.1016/j.tjog.2014.03.013](https://doi.org/10.1016/j.tjog.2014.03.013)
29. Sewell MF, Rosenblum D, Ehrenberg H. Arterial embolus during common iliac balloon catheterization at cesarean hysterectomy. *Obstet Gynecol.* 2006; 108: 746-748. doi: [10.1097](https://doi.org/10.1097)

/01.AOG.0000201992.80130.2c

30. Matsueda S, Hidaka N, Kondo Y, Fujiwara A, Fukushima K, Kato K. External iliac artery thrombosis after common iliac artery balloon occlusion during cesarean hysterectomy for placenta accreta in cervico-isthmic pregnancy. *J Obstet Gynecol Res.* 2015; 41: 1826-1830. doi: [10.1111/jog.12777](https://doi.org/10.1111/jog.12777)

31. Brigham and Women's Hospital. Caring for the placenta accreta patient. Web site. [http://www.brighamandwomens.org/De-](http://www.brighamandwomens.org/Departments_and_Services/obgyn/Medical_Professionals/caring-for-placenta-accerta-patient.aspx#pageheadline)

[partments\\_and\\_Services/obgyn/Medical\\_Professionals/caring-for-placenta-accerta-patient.aspx#pageheadline](http://www.brighamandwomens.org/Departments_and_Services/obgyn/Medical_Professionals/caring-for-placenta-accerta-patient.aspx#pageheadline). Accessed June 30, 2016.

32. de la Cruz CZ, Coulter ML, O'Rourke K, Alio PA, Daley EM, Mahan CS. Women's experiences, emotional responses, and perceptions of care after emergency peripartum hysterectomy: A qualitative survey of women from 6 months to 3 years postpartum. *Birth.* 2013; 49: 256-263. doi: [10.1111/birt.12070](https://doi.org/10.1111/birt.12070)