

## Case Report

### \*Corresponding author

**Abhijit Swami**

Associate Professor of Medicine  
Silchar Medical College  
Silchar, Assam, India

E-mail: [drabhijitswami@gmail.com](mailto:drabhijitswami@gmail.com)

Volume 2 : Issue 3

Article Ref. #: 1000HARTOJ2111

### Article History

Received: July 26<sup>th</sup>, 2015

Accepted: August 7<sup>th</sup>, 2015

Published: August 10<sup>th</sup>, 2015

### Citation

Swami A, Thakuria R, Kharat S. Cerebral toxoplasmosis in a treatment naive HIV patient with high CD4 count responding to treatment with a regime of cotrimoxazole and pyrimethamine: do we need to start prophylaxis for toxoplasmosis at a higher CD4 count? *HIV/AIDS Res Treat Open J.* 2015; 2(3): 72-75. doi: [10.17140/HARTOJ-2-111](https://doi.org/10.17140/HARTOJ-2-111)

### Copyright

©2015 Swami A. This is an open access article distributed under the Creative Commons Attribution 4.0 International License (CC BY 4.0), which permits unrestricted use, distribution, and reproduction in any medium, provided the original work is properly cited.

# Cerebral Toxoplasmosis in a Treatment Naive HIV Patient with High CD4 Count Responding to Treatment with a Regime of Cotrimoxazole and Pyrimethamine: Do We Need to Start Prophylaxis for Toxoplasmosis at a Higher CD4 Count?

Abhijit Swami<sup>1\*</sup>, Riturag Thakuria<sup>2</sup> and Sumit Kharat<sup>3</sup>

<sup>1</sup>Associate Professor of Medicine, Silchar Medical College, Silchar, Assam, India

<sup>2</sup>Assistant Professor of Medicine, Silchar Medical College, Silchar, Assam, India

<sup>3</sup>Registrar of Medicine, Silchar Medical College, Silchar, Assam, India

### ABSTRACT

Cerebral toxoplasmosis is one of the commonest opportunistic infection of the nervous system in HIV patients. We present a case of gradual onset hemiparesis in an ART naïve HIV patient with high CD4 count who was subsequently diagnosed to be a case of cerebral toxoplasmosis based on radiological and serological investigations. The patient responded to a regime of Cotrimoxazole and Pyrimethamine. His CD4 count at diagnosis was 299/ $\mu$ l. HAART was started after completion of treatment of cerebral toxoplasmosis. Prophylaxis against toxoplasmosis is recommended with cotrimoxazole if the CD4 count is below 200/ $\mu$ l. However, in this case as the patient had developed toxoplasmosis at a CD4 count value above the cut-off value for prophylaxis for cerebral toxoplasmosis, it may be worth considering to starting prophylaxis at a higher CD4 count than 200/ $\mu$ l and continuing for a longer time than the current guidelines.

**KEYWORDS:** Cerebral toxoplasmosis; Opportunistic infections; HAART; Cotrimoxazole.

**ABBREVIATIONS:** HAART: Highly Active Antiretroviral Therapy; IgG: Immunoglobulin G; ELISA: Enzyme-linked immunosorbent assay.

### INTRODUCTION

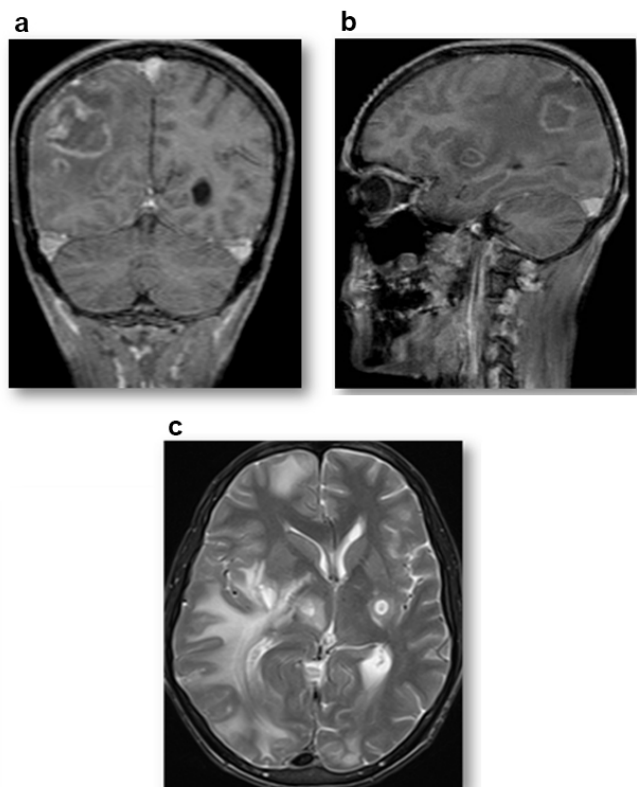
Opportunistic infections are often the presenting diagnosis in patients with HIV/AIDS. Though most of the opportunistic infections occur at low CD4 counts, we present a case of cerebral toxoplasmosis presenting with progressive hemiparesis, who was subsequently diagnosed to have HIV infection with a CD4 count of 299/ $\mu$ l and made good recovery with a regime comprising of pyrimethamine, sulfadoxime and cotrimoxazole. The case is of interest as cerebral toxoplasmosis has been rarely reported with high CD4 count in treatment naïve HIV patients. The completeness of recovery with commonly available drugs before the initiation of Highly Active Antiretroviral Therapy (HAART), thereby makes a case for initiation of prophylaxis with cotrimoxazole for toxoplasmosis at higher CD4 count in HIV infected patients.

### CASE HISTORY

A 47 year old trucker was admitted with history of progressive weakness of right half of the body with headache that started about four weeks back. The patient had become non-

ambulatory a week before the admission and was unable to feed or clothe himself on his own. His speech had become slurred. He had history of contact with multiple sexual partners. Examination revealed a male patient of BMI 23.5 kg/m<sup>2</sup> with normal blood pressure and pulse rate. He was conscious with Grade 3 upper motor neuron type of weakness of both upper and lower limbs on right side along with dysarthria. Early papilledema was seen on both eyes on examination.

CT scan of head - both plain and contrast enhanced, showed multiple ring enhancing lesions on both sides of brain with surrounding cerebral edema. He tested positive for HIV 1. Subsequent MRI of brain showed multiple target lesions on both sides of the brain. The CD4 count of the patient was 299/μl. Blood examination of the patient showed mild normocytic, normochromic anemia with normal biochemical parameters. He tested negative for Hepatitis B and C. Chest X-ray and ultrasound examination of abdomen did not reveal any pathology. He tested positive for IgG anti toxoplasma antibody (Figure 1).



**Figure 1:** a) MRI showing cerebral toxoplasmosis on right frontoparietal region – sagittal section. b) MRI T1 image (coronal section) showing multiple lesions. c) T2 weighted image showing cerebral toxoplasmosis.

A diagnosis of Stage IV HIV infection with toxoplasma encephalitis was made. The patient was initiated on a regime of pyrimethamine 200 mg and sulfadoxime 4 gm (Day 1) in two divided doses followed by pyrimethamine 50 mg and sulfadoxime 1 gm and cotrimoxazole double strength – 2 tabs thrice daily from Day 2. Inj. dexamethasone 8 mg IV thrice daily was started for cerebral edema. Folic acid supplementation was also given.

The patient responded to treatment and by the end of 2<sup>nd</sup> week was able to walk with support. Follow-up CT scan of head showed resolution of the lesion by 3<sup>rd</sup> week. The dose of dexamethasone was gradually tapered and the patient was continued on cotrimoxazole double strength tablets with pyrimethamine and sulfadoxime for a total four weeks of therapy. HAART was started 2 weeks after completion of treatment of toxoplasma encephalitis.

## DISCUSSION

Cerebral toxoplasmosis is a major cause of morbidity and mortality among HIV-infected patients, particularly from developing countries.<sup>1</sup> Cerebral toxoplasmosis is an HIV-indicative event in 35% of patients and an AIDS-defining event in 75% of cases.<sup>2</sup> Globally, *T. gondii* causes the most common focal brain lesion in HIV-infected patients.<sup>3</sup> In most of the studies, incidence of toxoplasma encephalitis have been reported with CD4 count of less than 100 cells/μl.<sup>4</sup> In a study involving 97 HIV patients with toxoplasma encephalitis, the median CD4 count was 68 cells/μl.<sup>5</sup> Similar findings have been observed in studies from Puerto Rico and Brazil where toxoplasma encephalitis was observed in patients with low CD4 count.<sup>6,7</sup> The incidence of toxoplasmosis varies by country and depends on the prevalence of *T. gondii* infection in the general population. *T. gondii* has an unusual clonal population structure consisting of three widespread lineages known as I, II, and III. Differences in genotypes of *T. gondii* isolates, races and ethnicities and the mode of transmission also seem to influence the occurrence of the infection.<sup>8</sup>

Cerebral toxoplasmosis causes unifocal or, more commonly, multifocal lesions and, less frequently, diffuse encephalitis. Patients usually present with subacute symptoms. The clinical manifestations depend on the location and number of lesions. More frequent complaints include: headache (49-63%), fever (41-68%), focal deficits (22-80%), seizures (19-29%), mental confusion (15-52%), ataxia (15-25%), lethargy (12-44%), cranial nerve palsies (12-19%) and visual alterations (8-15%). Other manifestations include dysarthria, cognitive dysfunction, raised intracranial pressure and involuntary movements. The definitive diagnosis of cerebral toxoplasmosis requires the presence of the tachyzoite form of the parasite in cerebral tissue to be directly demonstrated by brain biopsy. In clinical practice, presumptive cerebral toxoplasmosis diagnosis depends on an association of serological, clinical and radiological findings.<sup>9</sup> Detection of Immunoglobulin G (IgG) is possible within 2 weeks of infection using the Enzyme-linked immunosorbent assay (ELISA) test.

Diagnosis is confirmed with a response to empiric anti-*Toxoplasma* therapy. A favorable clinical and radiological response is expected within 10-14 days of specific treatment.<sup>10</sup>

The treatment of *T.gondii* infection is usually by a combination of pyrimethamine, sulfadiazine and leucovorin though

alternative regimes include pyrimethamine plus clindamycin, cotrimoxazole and atovaquone plus pyrimethamine.<sup>11</sup> Three randomized double-blinded trials of cerebral toxoplasmosis treatment have been published comparing pyrimethamine plus sulfadiazine with pyrimethamine plus clindamycin<sup>12</sup> and pyrimethamine plus sulfadiazine with cotrimoxazole.<sup>13</sup> In a review of these studies The Cochrane Collaboration did not identify any superior regimen among these three combinations for cerebral toxoplasmosis treatment.<sup>14</sup> With sulfadiazine being not available widely, cotrimoxazole has been used in treatment of Toxoplasmosis. Cotrimoxazole has been used as an alternative treatment for toxoplasma encephalitis because it is inexpensive, well-tolerated, and as effective as pyrimethamine-sulfadiazine, which is the first-line drug regimen. The drug has been found effective (85.5%) with a relatively low incidence of side effects (22%; 7.4% requiring treatment interruption). Relapses did occur in some patients and the risk factors for relapse was poor treatment and/or prophylaxis adherence.<sup>15</sup> The safety of cotrimoxazole has also been established in treatment of congenital toxoplasmosis which is one of the most common causes of fetal death.<sup>16</sup>

HIV Patients with CD4 count <100 cells/ $\mu$ L are given prophylaxis against *T.gondii* with a single double-strength-tablet daily dose of cotrimoxazole and continued till CD4 count >200/ $\mu$ L for more than 6 months.<sup>17</sup> However, in a recent study, *T.gondii* cases have been reported in patients with high CD4 count >200/ $\mu$ L with 299 cases Per Year Follow up (PYFUP)<sup>18</sup> with more than 50 cases reported at CD4 count >500/ $\mu$ L PYFU. Toxoplasma encephalitis has also been reported in patients with CD4 count >300 cells/ $\mu$ L but these patients had a history of CD4 count of <100 cells/ $\mu$ L at one stage and the rise of CD4 count was attributed to HAART. These cases of toxoplasma encephalitis occurring with of high CD4 count have been attributed to persistence of immune dysfunction in spite of HAART<sup>19,20</sup> or poor compliance. As toxoplasma encephalitis responds well to cotrimoxazole, it may be worth considering starting prophylaxis for toxoplasmosis at higher CD4 count (>200/ $\mu$ L) that may be continued till CD4 count remains well over 200/ $\mu$ L for a longer period.

## CONCLUSION

Cerebral toxoplasmosis has been rarely been reported in treatment naïve HIV patients with CD4 count >200  $\mu$ L. As cerebral toxoplasmosis respond well to a combination of cotrimoxazole and pyrimethamine in a HIV patient, it may be worth considering to start prophylaxis against toxoplasmosis with cotrimoxazole at a CD4 count higher than 200/ $\mu$ L as cases of toxoplasmosis have been reported with higher CD4 count.

**CONFLICTS OF INTEREST:** None.

## CONSENT

The patient has provided written permission for this publication.

## ACKNOWLEDGEMENTS

Department of Radiology, Silchar Medical College, Assam, India.

## REFERENCES

1. Pereira-Chioccola VL, José Ernesto L, Su C. Toxoplasma gondii infection and cerebral toxoplasmosis in HIV-infected Patients. *Future microbiol.* 2009; 4(10): 1363-1379. doi: [10.2217/fmb.09.89](https://doi.org/10.2217/fmb.09.89)
2. Vidal JE, Hernandez AV, Penalva de Oliveira AC, et al. Cerebral toxoplasmosis in HIV-positive patients in Brazil: clinical features and predictors of treatment response in the HAART era. *AIDS Patient Care STDs.* 2005; 19: 626-634. doi: [10.1089/apc.2005.19.626](https://doi.org/10.1089/apc.2005.19.626)
3. Gaspar G, Monereo A, Barros C, et al. Incidence of first episodes of HIV: opportunistic diseases and its changes over time in the period 1987-2001 in the COMESEM Cohort Study. Presented at 14th International AIDS Conference. Barcelona, Spain. 2002.
4. Mohraz M, Mehrkhani F, Jam S, et al. Seroprevalence of toxoplasmosis in HIV(+)/AIDS patients in Iran. *Acta Med Iran.* 2011; 49(4): 213-218.
5. Luma NH, Benjamin Tchaleu BC, Mapoure YN, et al. Toxoplasma encephalitis in HIV/AIDS patients admitted to the Douala general hospital between 2004 and 2009: a cross sectional study. *BMC Research Notes.* 2013, 6: 146. doi: [10.1186/1756-0500-6-146](https://doi.org/10.1186/1756-0500-6-146)
6. Mayor AM, Santos DMF, Dworkin MS, Ríos-Olivares E, Hunter-Mellado RF. Toxoplasmic Encephalitis in an AIDS Cohort at Puerto Rico before and after Highly active antiretroviral therapy (HAART). *Am J Trop Med Hyg.* 2011; 84(5): 838-841. doi: [10.4269/ajtmh.2011.10-0718](https://doi.org/10.4269/ajtmh.2011.10-0718)
7. Nascimento LV, Stollar F, Tavares LB, et al. Risk factors for toxoplasmic encephalitis in HIV-infected patients: a case-control study in Brazil. *Ann Trop Med Parasitol.* 2001; 95(6): 587-593. doi: [10.1080/00034980120073931](https://doi.org/10.1080/00034980120073931)
8. Khan A, Su C, German M, et al. Genotyping of *Toxoplasma gondii* strains from immunocompromised patients reveals high prevalence of type I strains. *J Clin Microbiol.* 2005; 43: 5881-5887. doi: [10.1128/JCM.43.12.5881-5887.2005](https://doi.org/10.1128/JCM.43.12.5881-5887.2005)
9. Mamidi A, DeSimone JA, Pomerantz RJ. Central nervous system infections in individuals with HIV-1 infection. *J Neurovirol.* 2002; 8: 158-167.
10. CDC. Guidelines for the prevention and treatment of oppor-

- tunistic infections in HIV-infected adults and adolescents. Recommendations from the Centers for Disease Control and Prevention, the National Institutes of Health, and the HIV Medicine Association of the Infectious Diseases Society of America. Website: <http://www.guideline.gov/content.aspx?id=45359> 2009; Accessed April 10, 2009.
11. Dannemann B, McCutchan JA, Israelski D, et al. Treatment of toxoplasmic encephalitis in patients with AIDS. A randomized trial comparing pyrimethamine plus clindamycin to pyrimethamine plus sulfadiazine. *The California Collaborative Treatment Group. Ann. Intern. Med.* 1992; 116(1): 33-43. doi: [10.7326/0003-4819-116-1-33](https://doi.org/10.7326/0003-4819-116-1-33)
12. Katlama C, Mouthon B, Gourdon D, et al. Atovaquone as long-term suppressive therapy for toxoplasmic encephalitis in patients with AIDS and multiple drug intolerance. *Atovaquone Expanded Access Group. AIDS.* 1996; 10(10): 1107-1112.
13. Torre D, Casari S, Speranza F, et al. Randomized trial of trimethoprim-sulfamethoxazole versus pyrimethamine-sulfadiazine for therapy of toxoplasmic encephalitis in patients with AIDS. *Italian Collaborative Study Group. Antimicrob. Agents Chemother.* 1998; 42: 1346-1349.
14. Dedicoat M, Livesley N. Management of toxoplasmic encephalitis in HIV-infected adults (with an emphasis on resource-poor settings). *Cochrane Database Syst. Rev.* 2006; 19(3): CD005420. doi: [10.1002/14651858.CD005420.pub2](https://doi.org/10.1002/14651858.CD005420.pub2)
15. Béraud G, Pierre-François S, Foltzer A, et al. Cotrimoxazole for treatment of cerebral toxoplasmosis: an observational cohort study during 1994-2006. *Am J Trop Med Hyg.* 2009; 80(4): 583-587.
16. Derouin F, Jacqz-Aigrain E, Thulliez P, Couvreur J, Lepoint C. Cotrimoxazole for Prenatal Treatment of Congenital Toxoplasmosis? *Parasitology Today.* 2000; 16(6): 254-256.
17. Centers for Disease Control and Prevention, the National Institutes of Health, and the HIV Medicine Association of the Infectious Diseases Society of America. Guidelines for the prevention and treatment of opportunistic infections in HIV-infected adults and adolescents.
18. Mocroft A, Furrer HJ, Miro JM, et al. Opportunistic infections working group on behalf of the collaboration of observational hiv epidemiological research Europe (COHERE) study in EuroCOORD. The incidence of AIDS-defining illnesses at a current CD4 count  $\geq$  200 cells/ $\mu$ L in the post-combination antiretroviral therapy era. *Clin Infect Dis.* 2013; 57(7): 1038-1047. doi: [10.1093/cid/cit423](https://doi.org/10.1093/cid/cit423)
19. Fournier S, Rabian C, Alberti C, et al. Immune recovery under highly active antiretroviral therapy is associated with restoration of lymphocyte proliferation and interferon-g production in the presence of toxoplasma gondii antigens. *The Journal of Infectious Diseases.* 2001; 183: 1586-1591. doi: [10.1086/320706](https://doi.org/10.1086/320706)
20. Antinori A, Larussa D, Cingolani A, et al. Prevalence, associated factors, and prognostic determinants of aids-related toxoplasmic encephalitis in the era of advanced highly active antiretroviral therapy. *Oxford Journals Medicine & Health Clinical Infectious Diseases.* 2004; 39(11): 1681-1691. doi: [10.1086/424877](https://doi.org/10.1086/424877)