

## Research

**\*Corresponding author****Rakesh Gupta, MD, MPhil**

Professor and Head

Department of Pediatrics

Command Hospital (CC)

Lucknow 226002

Uttar Pradesh, India

E-mail: [colrgupta@gmail.com](mailto:colrgupta@gmail.com)

Volume 2 : Issue 1

Article Ref. #: 1000HARTOJ2103

**Article History**Received: February 5<sup>th</sup>, 2015Accepted: March 10<sup>th</sup>, 2015Published: March 11<sup>th</sup>, 2015**Citation**

Badal S, Gupta R, Kumar P, Sharma M, Chhajta DS. Cardiac manifestations in HIV infected children. Are they under diagnosed? *HIV/AIDS Res Treat Open J*. 2015; 2(1): 21-26. doi: [10.17140/HARTOJ-2-103](http://dx.doi.org/10.17140/HARTOJ-2-103)

**Copyright**

©2015 Gupta R. This is an open access article distributed under the Creative Commons Attribution 4.0 International License (CC BY 4.0), which permits unrestricted use, distribution, and reproduction in any medium, provided the original work is properly cited.

# Cardiac Manifestations in HIV Infected Children. Are they under Diagnosed?

**Sachendra Badal<sup>1</sup>, Rakesh Gupta<sup>2\*</sup>, Prabhat Kumar<sup>3</sup>, Mukti Sharma<sup>4</sup> and DS Chhajta<sup>4</sup>**<sup>1</sup>Gd Spl, Department of Pediatrics, Military Hospital Jodhpur, Rajasthan, India<sup>2</sup>Professor and Head, Department of Pediatrics, Command Hospital (CC), Lucknow 226002, Uttar Pradesh, India<sup>3</sup>Professor, Department of Pediatrics and Cardiology, Military Hospital (CTC) Pune, Maharashtra, India<sup>4</sup>Consultant, Department of Pediatrics and Cardiology, Command Hospital (WC), Chandigarh, India**ABSTRACT**

**Background:** The aim of this study was to evaluate cardiac manifestations in HIV-infected children in India.

**Methods & Results:** This was a cross sectional study in HIV positive children up to 18 years of age, at a pediatric HIV clinic of a tertiary care teaching hospital in Maharashtra, India. All children were thoroughly evaluated by detailed history, clinical examination and underwent chest radiograph, Electrocardiograph (ECG) and Echocardiography (Echo). Of the 119 children who completed the study, the male to female ratio was 1.16:1 and the mean age was 8.9 years (range 2-17 years). Cardiovascular abnormalities were detected in 74 (62%) children on echo and / or ECG. Echocardiography alone was abnormal in 44 (36.9%) children and ECG alone was abnormal in 56 (47%) children. However, only 11(9%) children were found to be symptomatic with cardiovascular symptoms. The prevalence of Congenital Heart Disease (CHD) was 4%. The most common ECG abnormality observed in the study was sinus tachycardia in 35 (29%) followed by ST-T changes in 20 (16.8%). The most common echocardiographic abnormality encountered was LV systolic dysfunction seen in 31 (26%) cases, followed by Low LV ejection fraction in 24 (20%) cases. Children with abnormal echo and ECG were in higher WHO clinical and immunological stages (III & IV), however the association between the two was not found to be statistically significant.

**Conclusions:** This study establishes that subclinical cardiac manifestations are prevalent in HIV infected children. More research should be done on the clinical significance of these findings and the need for long-term follow up.

**KEYWORDS:** HIV; Cardiac manifestations; Electrocardiogram; Left ventricular function.

**INTRODUCTION**

Human Immunodeficiency Virus (HIV) is a virus that causes multisystem disease, affecting almost all body systems. The severity of each manifestation varies with organ system and can be related to multiple etiologies.<sup>1</sup> Children infected with HIV may develop a wide range of cardiovascular abnormalities, some of which are known to be associated with poor survival.<sup>2</sup> With the introduction of Anti-retroviral therapy (ART), HIV infection is now recognized as a chronic manageable disease, rather than a terminal illness. As pulmonary diseases and infections in HIV-infected individuals are more effectively prevented and treated, the proportional

morbidity and mortality of cardiovascular diseases among children with HIV/AIDS are increasing.<sup>3</sup> Subclinical cardiac abnormalities in HIV-infected children are common, persistent, and often progressive.<sup>3</sup> The spectrum of cardiovascular manifestations includes tachycardia, LV dysfunction, pericardial effusion, myocarditis, dilated cardiomyopathy, endocarditis, coronary artery disease, pulmonary hypertension, vasculitis, aneurysm formation, and cardiac tumors.<sup>3</sup> Multifactorial etiologies like autoimmunity, autonomic dysfunction, abnormal ventricular growth, HIV infection per se or other associated viral infection and/or side effects from ART may be causative and/or further exacerbate the cardiac morbidities. This study intends to evaluate cardiac manifestations among HIV infected children in India and their correlation with HIV disease status.

## Methods

### Study Design and Patients

This cross sectional study was conducted among HIV infected children up to 18 years of age for a period of 2 years from September 2009 to August 2011 at a pediatric HIV clinic of a tertiary care teaching hospital in Maharashtra, India. Ethical clearance was obtained from an institutional ethical committee. The diagnosis of HIV, clinical categorization and immunological categorization were based on WHO guidelines.

After obtaining informed consent of the parent/caregiver, children were enrolled in the study. A detailed history was obtained from the parents or care giver and a thorough clinical examination was done to detect any systemic manifestation as per predetermined criteria. All testing was done as per protocol based on NACO guidelines. The subjects were evaluated for cardiovascular abnormalities by chest X ray, Electrocardiography (ECG) and Echocardiography (Echo).

### Outcomes:

1. Cardiac manifestations were studied with respect to abnormality detected, clinically, chest-X-ray, ECG or Echocardiography.
2. Cardiac manifestations were correlated with WHO clinical and immunological categories of the subjects.

### Echocardiography:

An experienced pediatric cardiologist using the Hewlett Packard Sonos 2000 model echo machine performed echocardiography, following the criteria of the American Society of Echocardiography.<sup>4</sup> Long parasternal views with M-mode were used for measuring the heart chamber dimensions in diastole and systole. The variables studied on echo included the following: Left ventricular end-diastolic dimension (LVDD); Left ventricular end-systolic dimension (LVSD), inter ventricular septal

thickness/posterior wall segment thickness (IVS/PWS), Left Ventricular Fractional Shortening (LVFS), Left Ventricular Ejection Fraction (LVEF), pericardial effusion and any structural lesion. Specific criteria for diagnosing these entities are below:

- Left Ventricular Fractional Shortening (LVFS) was automatically computed by the Hewlett Packard Sonos 2000 model echo machine, which was also sufficient to assess left ventricular function.<sup>5</sup> The normal range of fractional shortening is 28-44%.<sup>6</sup>
- Estimation of the pulmonary artery systolic pressure was derived from measuring a tricuspid regurgitate jet using Bernoulli's equation.<sup>7,8</sup> A fixed value of right atrial pressure, 5 or 10 mm of Hg, was added to the trans-tricuspid pressure gradient to yield Systolic Right Ventricular Pressure (SRVP). Doppler and color flow studies were done to study valve and orifice pressure gradient and directionality of blood flow.

### Mode of Diagnosis on Echo

The values of parameters assessed on echo were as follows:

- LV systolic dysfunction was defined as LVFS<28%.
- Low LVEF was defined as a reading below 55%.
- Regurgitation was considered mild if the back flow seen on color doppler did not reach the middle, moderate if the flow reached the middle and severe if it exceeded the middle of the receiving chamber.
- Pericardial Effusion (PE) was diagnosed when effusion measured more than 4 mm.

### Statistical Analyses

Data analysis was done by using SPSS (Statistical Package for Social Sciences) using statistical software version 17.0. We calculated correlation coefficient, Chi-square test and Fisher's exact test to find the significance in various parameters. The statistical test was used at 95% confidence interval.

### Results

A total of 130 consecutively enrolled HIV infected children were evaluated in the study. Eleven children were lost to follow up and were excluded. Out of the total 119 children in the study, the largest number of abnormalities was seen in the age group of 5-10 years (41.2%) followed by 10-18 years (39.5%) and <5 years (18.3%). The mean age in the study population was 8.9 years (range 2 - 17 years). The majority of the children were males (53.7%) with male: female ratio of 1.16: 1. The age of HIV diagnosis varied from 6 months to 14 years. The mode of HIV transmission was vertical in 116 (97%) children. Three children

had acquired HIV through transfusion, of which two had thalassemia major. Protein energy malnutrition was observed in 94 (79%) children.

According to WHO clinical staging, the distribution of cases were as follows: - Clinical stage- I, 48 (40%) cases, stage-II, 41(35%), stage-III, 25(21%) and stage- IV, 5(4%) cases and Immunological stage as stage-I in 39 (33%) cases, stage-II 13(11%), stage III-42(35%) and stage IV in 25(21%) cases. The distribution according to WHO Clinical and Immunological staging of study population is shown in figure 1.

### Cardiovascular manifestations

Cardiovascular abnormalities were detected in 74 (62%) children on echo and/or ECG (Figure 2). Abnormalities were detected on echocardiography in 44 (36.9%) and by ECG

in 56 (47%) children. Both echo and ECG were abnormal in 26 (21.8%) children. Chest radiographs detected cardiomegaly in 13 (11%) cases.

### Cardiovascular symptom/signs

Breathlessness was reported in 11 (9%) children in our study, of which 10 had abnormal echo and 7 abnormal ECG findings. Chest pain was reported by 4 children and all of them had abnormal echo in the form of low LV fractional shortening as well as LV dysfunction and ECG showed monofocal ectopics and sinus tachycardia. None of the children or their caretakers reported other cardiac symptoms like cyanosis, edema, palpitations or syncope. Clinical examination revealed tachycardia as the most common finding among the subjects in 43 (36%). No child had an audible murmur or abnormal S2. Hepatomegaly was observed in 52 (43%) children but none had raised JVP or

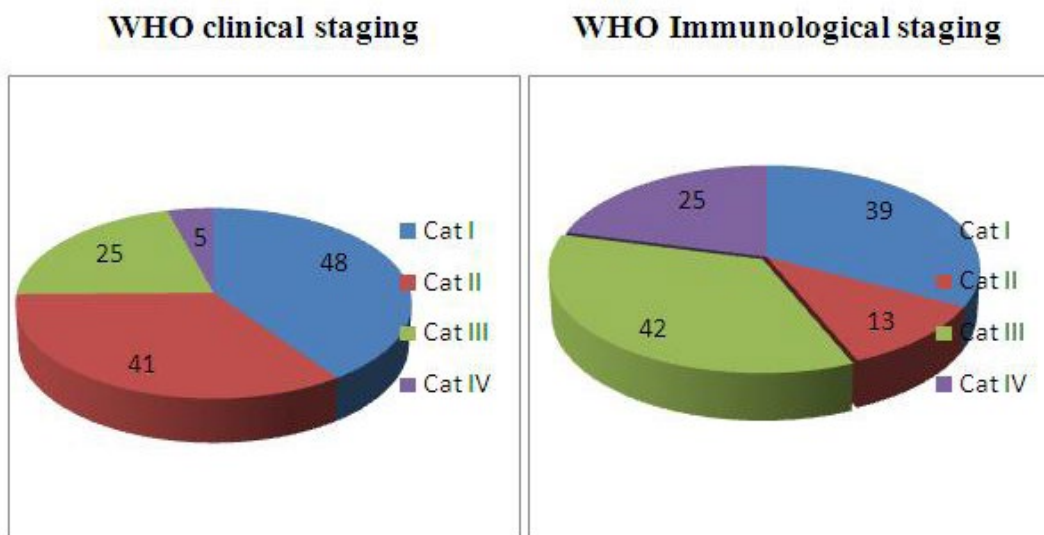


Figure 1: WHO Clinical and Immunological staging of study population at enrolment.

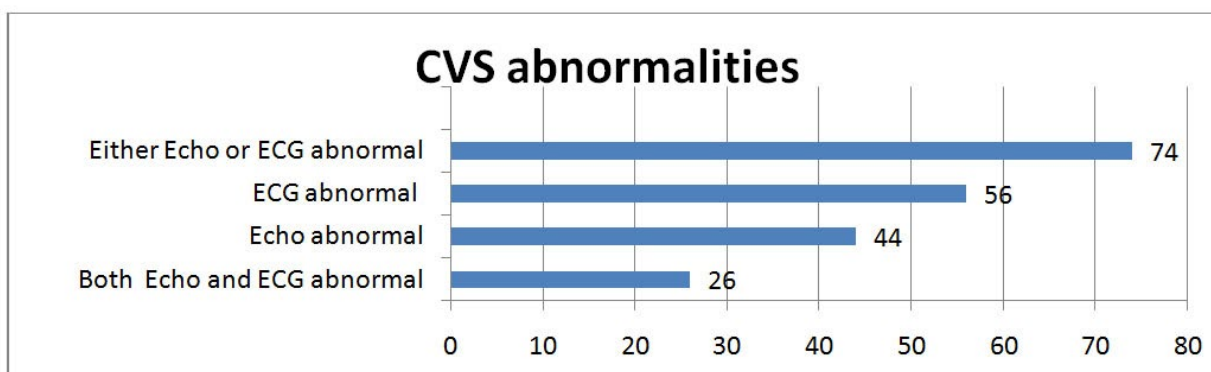


Figure 2: Cardiovascular abnormalities detected in the study.

pedal edema.

**Chest X ray**

In our study 46 (36%) children had an abnormal Chest X Ray. Non Homogenous Opacity (NHO) was the commonest finding seen in 17 (14%) cases, cardiomegaly in 13 (11%), hilar-adenopathy in 9 (7%) cases, bronchiectatic changes in 3 and diffuse reticulonodular infiltration and pleural effusion in 2 each.

**ECG**

ECG abnormalities were detected in 56 (47%) children and the most common ECG abnormality was sinus tachycardia in 35 (29%) followed by ST-T changes in 20 (16.8%). The association was evaluated between ECG findings and clinical staging as well as immunological staging and was not found to be statistically significant. The association between presence of cardiac symptoms and ECG findings was found to be statistically significant as shown in table 1.

S. No.	Cardiac Symptoms	ECG abnormal n= 56 (%)	ECG normal n= 63 (%)	Statistical analysis
1	Present	39(70)	10(15)	Chi-sq -35.388 p< 0.001 significant
2	Absent	17(30)	53(85)	

Table 1: Abnormal Electrocardiography (ECG) with cardiac symptomatology.

**Echocardiography**

Echocardiography was found to be abnormal in 44 (36.9%) children and the most common abnormality detected was LV systolic dysfunction as measured by LV Fractional Shortening (LVFS) in 31 (26%) followed by Left Ventricular Ejection Fraction (LVEF) noted in 24 (20%) children. Congenital heart disease was detected in 5 (4%) children: three had bicuspid aortic valve, one secundum Atrial Septal Defect (ASD) and one Mitral Valve Prolapse (MVP). Two children with bicuspid aortic valve complained of breathlessness and both had abnormal echo parameters (diminished LVFS and low LVEF). Two children in the study had minimal Pericardial Effusion (PE) on echo and both were in clinical stage III. Pericardiocentesis was not done owing to small volume of effusion. One child was initiated on tuberculosis therapy. None of the children had vegetations on echocardiography or any evidence of pulmonary arterial hypertension. The mean echocardiographic parameters and abnormalities noted are depicted in tables 2 and 3.

Abnormal Echo was considered as presence of any of the following abnormalities: low LVEF, diminished LVFS, structural heart disease, pericardial effusion or valvular regurgitation. Although there were more children with abnormal Echo in higher WHO clinical or immunological categories, there was

no statistically significant association between the two. There was similarly no statistically significant association between the clinical or immunological staging with LV fractional shortening or LVEF. The association between presence of cardiac symptoms and abnormal Echo was found to be statistically significant as depicted in table 4.

S. No.	Parameter	Mean ±SD
1	Mean Left ventricular end-systolic dimension (LVSD)	21.9 ± 3.46
2	Mean Left ventricular end-diastolic dimension (LVDD)	33.0 ± 4.58
3	Mean Left Ventricular Fractional Shortening (LVFS) %	33.4 ± 6.41
4	Mean Left Ventricular Ejection Fraction (LVEF) %	60.7 ± 6.54
5	Mean Inter Ventricular Septal thickness (IVS)	7.9 ± 5.0
6	Mean Posterior Wall Segment thickness(PWS)	7.7 ± 1.31

Table 2: Mean parameters on Echocardiography.

S. No	Echocardiographic abnormality	Number of patients	N=119 (%)
1	LV fractional shortening (systolic dysfunction)	31	26.0
2	Low LV Ejection Fraction	24	20.1
3.	Congenital heart disease	5	4.2
4.	Tricuspid regurgitation	3	2.5
5.	Pericardial effusion	2	1.7
6.	Mitral regurgitation	2	1.7

Table 3: Echocardiographic abnormalities in study population.

S. No.	Cardiac symptom and signs	Echo abnormal n=44 (%)	Echo normal n=75 (%)	Statistical analysis
1	Present	27(61)	22(29)	Chi square= 1.52, p<0.001, significant
2	Absent	17(39)	53(71)	

Table 4: Abnormal Echocardiography with cardiac symptom and signs.

Mean Haemoglobin (Hb) of children with low LVEF was 10.2 gm% as compared to mean Hb of 11.0 gm% in children with normal LVEF. The correlation coefficient was 0.279 (p=0.002), so there was a significant but very poor correlation between haemoglobin and LVEF.

**DISCUSSION**

In our study of 119 HIV infected children, subclinical cardiac abnormalities were observed in 74 (62%) children detected either on echo and/or ECG. The most common cardiac symptom reported was breathlessness in 11 (9%) children and



the most common sign on clinical examination was tachycardia observed in 43 (36%) children. In the P2C2 (Pediatric Pulmonary and Cardiovascular complications of vertically transmitted Human Immunodeficiency Virus Infection)<sup>9</sup> study, a prospective multicentre study of 197 HIV-infected children, tachycardia was also the most common clinical finding.<sup>2</sup> The authors found echocardiographic changes in all symptomatic children.

In our study the most common echo abnormality was LV systolic dysfunction observed in 31 (26%) children. This is consistent with other similar studies that have reported a prevalence ranging between 18%-78%.<sup>9-19</sup> Specifically, LV dysfunction of 37% was reported from a Thai study in 2004.<sup>8</sup> The African study reported echocardiographic abnormalities in 51% abnormalities of the study population. In the P2C2 trial fractional shortening was a significant clinical predictor of mortality (RR=1.91,  $p<0.001$ ). The same P2C2 trial later reported abnormalities in 31% of 196 children who underwent echocardiography<sup>9</sup> in subsequent publication. In a Brazilian study 52% of children had echo abnormalities of which only 20% had clinical findings.<sup>10</sup> In our study cardiac abnormalities were more frequently encountered in children with higher immunological category III & IV; however this association was not statistically significant. There was a statistically significant association between the presence of abnormalities in ECG or echo and cardiac symptoms.

The prevalence of Congenital Heart Disease (CHD) was 4% of all the children studied, comparable with previous studies, who reported prevalence of 2-3%<sup>11,12</sup> and this prevalence was higher than that found in the general population of 0.8%.<sup>13</sup> The most common congenital cardiovascular abnormality detected in our study was bicuspid aortic valve; none of the children had a ventricular septal defect, which is the most common form of congenital heart disease in healthy populations and similar studies.<sup>11,12,14</sup>

Pericardial Effusion (PE) was seen in 2 out of the 119 children (1.6%), contrary to 14% to 60% incidence of PE seen in other studies of HIV-infected children.<sup>11,12</sup> Starcet al found no PE in 201 children with HIV, the majority of whom had symptomatic HIV disease.<sup>15</sup> Mild Tricuspid Regurgitation (TR) was found in three cases in our study however there was no evidence of Pulmonary Arterial Hypertension (PAH) in any of these children. None of the children had any vegetations, rheumatic heart disease, and PAH. ECG abnormalities were seen in 56 children (47%), which is comparable to the previously reported similar studies observed abnormal ECG in 26.5% -55% cases.<sup>16,17</sup> The prevalence in our study was much lower than that of Lipshultz, et al. who reported abnormal ECG in 93% children, possibly because 24-hour ambulatory ECG was utilized in that study in addition to the standard 12 lead ECG.<sup>14</sup> The most common ECG abnormality detected in our study was sinus tachycardia commensurate with similar studies.<sup>14,16</sup> The autonomic imbalance and neuropathy, which are present in early HIV infection and progress with worsening HIV disease, are possible explanations

for the sinus tachycardia.<sup>20</sup> In our study 46 (36%) children had abnormal chest X ray, comparable to other similar studies.<sup>8</sup> We did not find any significant cardiac mortality in our study period, which may be explained by the advances in the management of HIV-infected children, such as prophylaxis against secondary infections, effective HAART, nutritional interventions, and closer cardiac monitoring.

## CONCLUSION

This study establishes that subclinical cardiac manifestations are prevalent in HIV infected children. More research should be done on the clinical significance of these findings and the need for long-term follow up.

## LIMITATIONS

The study is confined to an ART center in Maharashtra on a small study population, and larger studies may be conducted to further strengthen the results.

## ACKNOWLEDGEMENTS

SB, RG conceived the study and involved in data collection. PK, MS and DS helped in evaluation of cases, echocardiography. MS, PK and DS supervised the study and revised the manuscript.

## ETHICAL CLEARANCE

Obtained from the Institutional Ethical Committee.

## FUNDING

There was no funding or any type of financial support from any agency.

**COMPETING INTERESTS:** None stated

## REFERENCES

1. Abuzaitoun OR, Hanson IC. Organ specific manifestations of HIV disease in children. *Pediatr Clin North Am.* 2000; 47(1): 109-125. doi: [10.1016/S0031-3955\(05\)70197-8](https://doi.org/10.1016/S0031-3955(05)70197-8)
2. Lipshultz SE, Easley KA, Orav EJ, et al. Cardiac dysfunction and mortality in HIV-infected children: the prospective P2C2 HIV multicenter study. *Circulation.* 2000; 102: 1542-1548. doi: [10.1161/01.CIR.102.13.1542](https://doi.org/10.1161/01.CIR.102.13.1542)
3. De Castro S, Migiliau G, Silvestri A, et al. Heart involvement in AIDS: a prospective study during various stages of the disease. *Eur Heart J.* 1992; 13: 1452-1459.
4. Wyman WL, Tal Geva, Girish SS, Peter CF, et al. Guidelines and Standards for Performance of a Pediatric Echocardiogram:

- A Report from the Task Force of the Pediatric Council of the American Society of Echocardiography. *J Am Soc Echocardiogr.* 2006; 19: 1413-1430. doi: [10.1016/j.echo.2006.09.001](https://doi.org/10.1016/j.echo.2006.09.001)
5. Gutgesell HP, Paquet M, Duff DF, McNamara DG. Evaluation of left ventricular size and function by echocardiography: Results in normal children. *Circulation.* 1977; 56: 457-462. doi: [10.1161/01.CIR.56.3.457](https://doi.org/10.1161/01.CIR.56.3.457)
6. Yock PG, Popp RL. Noninvasive estimation of right ventricular systolic pressure by Doppler ultrasound in patients with tricuspid regurgitation. *Circulation.* 1984; 70: 657-662. doi: [10.1161/01.CIR.70.4.657](https://doi.org/10.1161/01.CIR.70.4.657)
7. Carlos SR, Lisa D, Julio AL, Enrique V. Cardiovascular complications of human immunodeficiency virus infection. *Radio Graphics.* 2006; 26: 213-231. doi: [10.1148/rg.261055058](https://doi.org/10.1148/rg.261055058)
8. Yupada P, Rekwana S. Cardiac manifestations in HIV-infected Thai children. *Annals of Tropical Pediatrics.* 2004; 24: 153-159.
9. Lipshultz SE, Easley KA, Orav EJ, et al. Pediatric pulmonary and cardiovascular complications of vertically transmitted hiv infection study group. Left ventricular structure and function in children infected with human immunodeficiency virus: the prospective p2c2 HIV multicenter study. *Circulation.* 1998; 97: 1246-1256.
10. Maria SBD, Regina CM, Daisy M. et al. Cardiac Longitudinal Study of Children Perinatally Exposed to Human Immunodeficiency Virus Type 1, Federal University of São Paulo - São Paulo, SP - Brazil. *Brazilian Archives of Cardiology.* 2005; 85(4).
11. Lubega S, Zirembuzi GW, Lwabi P. Heart disease among children with HIV/AIDS attending the paediatric infectious disease clinic at Mulago Hospital. *African Health Sciences.* 2005; 5(3): 219-226.
12. Vogel RL, Alboliras ET, McSherry GD, et al. Congenital heart defects in children of HIV positive mothers. *Circulation.* 1988; 78: 11-17.
13. Antia AU, Wilkinson JL, Jaiyesimi F. The cardiovascular system. *Pediatrics in the tropics.* Blackwell. London. 1991; 11: 233-273.
14. Lipshultz SE, Canock S, Sanders P, et al. Cardiovascular manifestations of HIV infection in infants and children. *Am J Cardiol.* 1989; 63: 1489-1497. doi: [10.1016/0002-9149\(89\)90014-3](https://doi.org/10.1016/0002-9149(89)90014-3)
15. Starc TJ, Lipshultz SE, Easley KA, et al. Incidence of cardiac abnormalities in children with human immunodeficiency virus infection: the prospective P2C2 HIV study. *J Pediatr.* 2002; 141: 327-334. doi: [10.1067/mpd.2002.126301](https://doi.org/10.1067/mpd.2002.126301)
16. Bannerman C, Chitsike I. Cor pulmonale in children with HIV infection. *Ann Trop Paediatr.* 1995; 15: 129-134.
17. Issenberg HJ, Charytan M, Rubenstein A. Cardiac Involvement in children with Acquired Immune Deficiency Syndrome. *Am Heart J.* 1986; 110: 710.
18. Shah I, Prabhu SS, Sumitra V, Shashikiran SS. Cardiac dysfunction in HIV infected children: A pilot study. *Indian Pediatrics.* 2005; 42(2): 146-149.
19. Werneck GL, Mesquita ET, Romeo Filho LJ, Ribeiro ML. Doppler echocardiographic evaluation of HIV-positive patients in different stages of the disease. *Arq Bras Cardiol.* 1999; 73: 157-168. doi: [10.1590/S0066-782X1999000800004](https://doi.org/10.1590/S0066-782X1999000800004)
20. Plein D, Van Camp G, Cosyns B, et al. Cardiac and autonomic evaluation in a pediatric population with human immunodeficiency virus. *Clin Cardiol.* 1999; 22: 33-36.