

## Brief Report

### Corresponding author

Vineet Bhatia, MD

Senior Consultant Cardiologist

Department of Cardiology

A 601, Prateek fedora

Sector 61, Noida

Uttar Pradesh, India

Tel. +91-9818168874

E-mail: [vinmonica@yahoo.co.in](mailto:vinmonica@yahoo.co.in)

Volume 2 : Issue 5

Article Ref. #: 1000HROJ2124

### Article History

Received: March 22<sup>nd</sup>, 2016

Accepted: April 1<sup>st</sup>, 2016

Published: April 4<sup>th</sup>, 2016

### Citation

Bhatia V, Minocha A, Arora P, Kaul U. Carcinoid heart disease: classical echocardiographic features. *Heart Res Open J.* 2016; 2(5): 134-136. doi: [10.17140/HROJ-2-124](https://doi.org/10.17140/HROJ-2-124)

### Copyright

©2016 Bhatia V. This is an open access article distributed under the Creative Commons Attribution 4.0 International License (CC BY 4.0), which permits unrestricted use, distribution, and reproduction in any medium, provided the original work is properly cited.

# Carcinoid Heart Disease: Classical Echocardiographic Features

Vineet Bhatia, MD<sup>1</sup>; Anil Minocha, MD<sup>2</sup>; Parneesh Arora, MD<sup>3</sup>; Upendra Kaul, MD<sup>4</sup>

<sup>1</sup>Senior Consultant, Department of Cardiology, Fortis Hospital, Noida, UP, India

<sup>2</sup>Consultant, Department of Cardiology, Fortis Hospital, Noida, UP, India

<sup>3</sup>Principal Consultant, Department of Cardiology, Fortis Hospital, Noida, UP, India

<sup>4</sup>Executive Director and Dean, Fortis Escorts and Fortis Hospital, Vasant Kunj, New Delhi, India

## ABSTRACT

Carcinoid Heart Disease (CHD) is an important and rare cause of acquired valvular heart disease. Clinical examination supplemented with Echocardiographic evaluation may give the first clue towards an underlying carcinoid tumor. We report a case with classical Echocardiographic features of carcinoid heart disease.

## INTRODUCTION

Carcinoid tumors are rare neuro endocrine tumors arising in 1.2 to 2.1% per 1000,000 people in the general population per year.<sup>1</sup> They most commonly originate from the gastrointestinal tract (foregut) or the bronchus (midgut) and usually clinically asymptomatic until metastases are present. The foregut carcinoids metastasize to the liver or abdominal lymph nodes and may present with bowel obstruction. In 20-30% cases they may present with manifestations secondary to the release of vasoactive amines (serotonin, bradykinin and histamine) which are referred to as Carcinoid Syndrome (CS). The classical triad of CS is flushing, diarrhea and bronchospasm. 50% cases of CS develop Carcinoid Heart Disease (CHD) a major cause of morbidity and mortality in such patients especially when hepatic metastases is present.<sup>2</sup> Cardiac involvement is also thought to be secondary to the actions of these vasoactive amines.<sup>3</sup> We recently came across a patient with a fore gut carcinoid with hepatic metastases and CHD who had classical echocardiographic findings of this rare disease. CHD may be the initial presentation in 20% cases of CS. Hence one should be aware of these echocardiographic findings as they may be the first clue of this intriguing disease.

## CASE REPORT

A 62-year old male, known case of foregut carcinoid (arising from the first part of duodenum) with hepatic metastases was referred to us with progressive breathlessness. On examination he had features of right sided heart failure. Transthoracic Echocardiography revealed dilated right atrium (RA) and right ventricle (RV). The anterior and septal leaflets of the tricuspid valve (TV) were thickened, shortened, retracted and fixed in open position giving rise to severe low pressure tricuspid regurgitation (TR) (Figures 1, 2 and 3). On continuous wave doppler, severe TR was characterized by a dagger shaped profile with an early peaked velocity and a rapid decline suggestive of rapid pressure equalization between the right sided cardiac chambers (Figure 4). These features are classical of carcinoid heart disease. The pulmonary and mitral valves were morphologically normal. The RV contractility was reduced however the examination of the left side of the heart was unremarkable. There was mild pericardial effusion. The inferior vena cava was dilated with loss of respiratory collapsibility. Management was initiated with fluid restriction, decongestive therapy with intravenous diuretics with resolution of symptoms. He was also on octreotide which has led to disease stabilization.

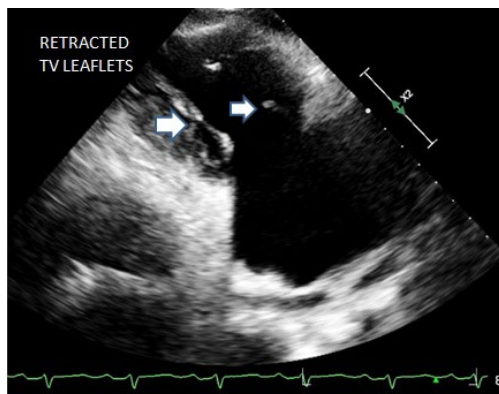


Figure 1: Retracted and shortened leaflets of the Tricuspid valve (TV).

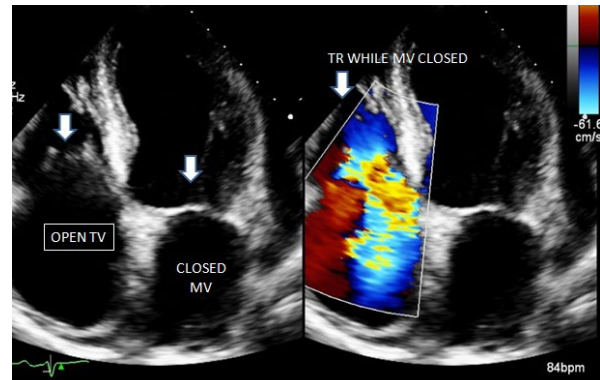


Figure 2: Simultaneous visualization of the Tricuspid valve (TV) and mitral valve (MV) in systole shows an open TV with severe tricuspid regurgitation while the MV is closed.

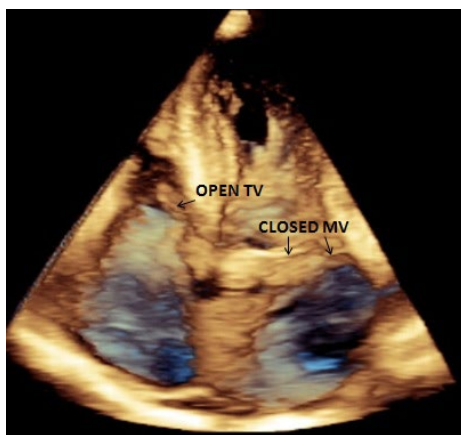

Figure 3: 3D image showing the same features as mentioned in figure 2.

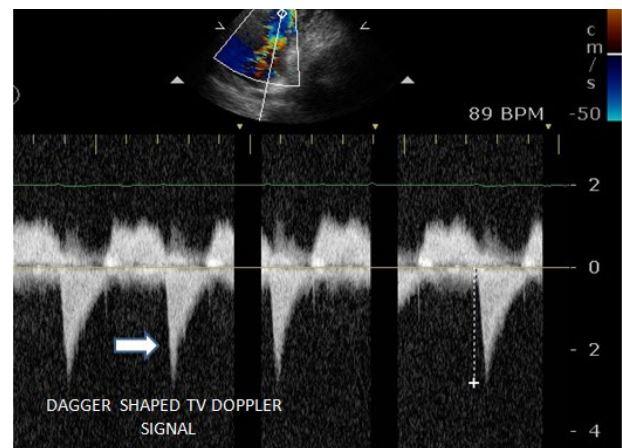


Figure 4: Continuous wave Doppler signal from TV shows dagger shaped profile with early peaked velocity.

## DISCUSSION

In patients with CHD vasoactive substances such as serotonin have been implicated to cause endo-cardial damage and plaque formation which in turn leads to valvular damage. Right heart involvement is more common than left sided because these structures are directly exposed to the vasoactive substances which otherwise undergo protective first pass metabolism in the lungs as in the present case. Though right sided valvular lesions are commonest the cardiac chambers may also be involved.<sup>4</sup> The tricuspid and pulmonary valves are commonly regurgitant and less commonly stenotic. Pulmonic stenosis is commoner than tricuspid stenosis as the pulmonary valve orifice is smaller and the plaques on the valves, in the annulus and sinuses lead to a narrowed pulmonic root.<sup>2,4</sup> Left sided lesions occur in <10% cases and may present with mitral or aortic regurgitation.<sup>2</sup> Myocardial metastasis are rare and may occur in 4% cases<sup>5</sup> while pericardial effusion occurs in 14% cases and patient for a men ovale (PFO) in 7% cases. PFOs are common in patients with left sided involvement (87%) and may be mechanism by which the vasoactive substances reach the left side of the heart by passing the lung.

Without treatment, the median duration of survival

with malignant carcinoid syndrome ranges from 12 to 38 months from the onset of systemic symptoms.<sup>6</sup> The major therapeutic modality in such patients consists of symptom control, usually with a somatostatin analog (octreotide or lanoreotide). Tumor removal is of limited value since patients with carcinoid syndrome typically have metastatic disease and chemotherapy has not had much success. As a result, more aggressive approaches, such as surgical debulking of the liver and hepatic artery embolization, are often used.

The stenotic right sided valves may be subject to balloon valvuloplasty in selected cases but symptom recurrence rates are high. In some cases with extensive structural defects valve surgery may be the only definitive treatment. Patients with carcinoid heart disease usually die as a result of severe tricuspid regurgitation rather than carcinomatosis.<sup>7</sup> An aggressive approach with surgery soon after the onset of cardiac symptoms may be the answer, as delay can result in worsening right ventricular failure and increase the risk of surgery. Peri-operative management may involve the use of an intravenous bolus or infusion of octreotide to reduce the risk of intra operative hypotension. Anti-histamines are also used before surgery to prevent flushing and bronchospasm; corticosteroids can be used to reduce bradykinin production.

In the tricuspid position, mechanical prostheses are believed to be adequately durable and relatively unaffected by the vasoactive substances causing the original valve pathology.<sup>8</sup> However, long-term oral anti-coagulation may pose serious bleeding issues as these patients invariably have extensive hepatic metastases. Bio-prosthetic valve have an edge as anti-coagulation is not needed how ever may undergo early degeneration. Tricuspid valve repair is usually not an option due to severe valvular destruction. There is some debate regarding the optimal surgical management of the pulmonary valve; the two options include valvectomy or valve replacement. Although the data are sparse, a recent small study of 22 patients suggested that pulmonary valve replacement reduced the risk of right heart dilatation post-operatively.<sup>9</sup> CHD is an important cause of acquired valular heart disease in patients with neuroendocrine tumors. CHD warrants aggressive treatment as this condition carries high degree of morbidity and mortality.

**CONFLICTS OF INTEREST:** None.

#### REFERENCES

1. Modlin IM, Sandor A. An Analysis of 8305 cases of carcinoid tumors. *Cancer*. 1997; 79(4): 813-829. doi: [10.1002/\(SICI\)1097-0142\(19970215\)79:4<813::AID-CNCR19>3.0.CO;2-2](https://doi.org/10.1002/(SICI)1097-0142(19970215)79:4<813::AID-CNCR19>3.0.CO;2-2)
2. Pellikka PA, Tajik AJ, Khandheria BK, et al. Carcinoid heart disease. Clinical and Echocardiographic spectrum in 74 patients. *Circulation*. 1993; 87(4): 1188-1196. doi: [10.1161/01.CIR.87.4.1188](https://doi.org/10.1161/01.CIR.87.4.1188)
3. Spatz M. Pathogenetic studies of experimentally induced heart lesions and their relation to carcinoid syndrome. *Laboratory Investigation*. 1964; 13: 288-300.
4. Lundin L, Norheim I, Landelius J, et al. Carcinoid heart disease: relationship of circulating vasoactive substances to ultrasound-detectable cardiac abnormalities. *Circulation*. 1988; 77(2): 264-269. doi: [10.1161/01.CIR.77.2.264](https://doi.org/10.1161/01.CIR.77.2.264)
5. Pandya U , Pellikka P, Enriquez-Sarano M, et al. Metastatic carcinoid tumor to the heart: Echocardiographic-pathologic study of 11 patients. *J Am Coll Cardiol*. 2002; 40(7): 1328-1332. doi: [10.1016/S0735-1097\(02\)02109-5](https://doi.org/10.1016/S0735-1097(02)02109-5)
6. Hajdu SI, Winawer SJ, Myers WP. Carcinoid tumors: A study of 204 cases. *Am J Clin Pathol*. 1974; 61(4): 521-528. doi: [10.1093/ajcp/61.4.521](https://doi.org/10.1093/ajcp/61.4.521)
7. Connolly HM, Nishimura RA, Smith HC, et al. Outcome of cardiac surgery for carcinoid heart disease. *J Am Coll Cardiol*. 1995; 25: 410-416. doi: [10.1016/0735-1097\(94\)00374-Y](https://doi.org/10.1016/0735-1097(94)00374-Y)
8. Fox DJ, Khattar RS. Carcinoid Heart Disease: presentation, diagnosis and management. *Heart*. 2004; 90(10): 1224-1228. doi: [10.1136/hrt.2004.040329](https://doi.org/10.1136/hrt.2004.040329)
9. Defraigne JO, Jerusalem O, Soyeur D, et al. Successful tricuspid valve replacement and pulmonary valvotomy for carcinoid heart disease. *Acta Chiurge Belg*. 1996; 96: 170-176.