

## Research

### \*Corresponding author

**Abdelmounem Eltayeib Abdo**

Consultant Gastroenterologist  
Director of the National Centre of  
Gastroenterology  
Ibn-Sina Hospital  
General Secretary of Panarab  
Director of WGO Khartoum Training  
Center  
Khartoum, Sudan  
E-mail: [munem2002@hotmail.com](mailto:munem2002@hotmail.com)

Volume 1 : Issue 4

Article Ref. #: 1000GOJ1117

### Article History

Received: June 29<sup>th</sup>, 2015

Accepted: September 9<sup>th</sup>, 2015

Published: September 9<sup>th</sup>, 2015

### Citation

Abdo AE, Mohammed DA. Capsule endoscopy: indications, findings and complications among patients with suspected small bowel lesions. *Gastro Open J.* 2015; 1(4): 100-106. doi: [10.17140/GOJ-1-117](https://doi.org/10.17140/GOJ-1-117)

### Copyright

©2015 Abdo AE. This is an open access article distributed under the Creative Commons Attribution 4.0 International License (CC BY 4.0), which permits unrestricted use, distribution, and reproduction in any medium, provided the original work is properly cited.

# Capsule Endoscopy: Indications, Findings and Complications among Patients with Suspected Small Bowel Lesions

**Abdelmounem Eltayeib Abdo<sup>1\*</sup> and Dina Ali Mohammed<sup>2</sup>**

<sup>1</sup>Consultant Gastroenterologist, Director of the National Centre of Gastroenterology, Ibn-Sina Hospital, Director of WGO Khartoum Training Center, Khartoum, Sudan

<sup>2</sup>Consultant Gastroenterologist, Ibn-Sina Hospital, Dhaka 1207, Bangladesh

## ABSTRACT

**Background/Aims:** Until a few years back, evaluation of small bowel pathology was unsatisfactory because of the inability to completely visualize the small bowel mucosa with the available endoscopic and radiological techniques. Since the advent of capsule endoscopy at the beginning of the millennium it became the gold standard for the diagnosis of most diseases of the small intestine. At present capsule endoscopy still have some limitations; it lacks the ability to obtain tissue biopsy or provide endoscopic treatment and cannot be controlled remotely. But the near future foreshadows capsules that can perform drug delivery and tissue sampling. Although, capsule endoscopy is considered a simple, safe, and a non-invasive reliable technique, retention of the capsule is the main complication of the procedure.

**Patients and Methods:** This study was conducted to assess the indications, findings, and complications of CE among patients with suspected small bowel lesions. It also studies the effect of small bowel transit time on the diagnostic yield of the capsular endoscopy and the effect of gastric transit time on complete small bowel examination.

A total of 119 patients with suspected small bowel disease received CE examination at the department of gastroenterology of Ibn-sina and Fedail Hospitals in Sudan, during the period from January 2010 to June 2011.

**Conclusion:** Capsule endoscopy is a very useful diagnostic tool, especially in the presence of a strong suspicion of small bowel pathology. The duration of small bowel transit time during capsule endoscopy does not affect its diagnostic yield. The latter is affected by the underlying indication. Capsule retention was the main complication and in 10% the capsule examination was not complete as the capsule did not reach the ileocecal valve. The gastric transit time was not associated with complete examination rate. Repeating the capsule endoscopy in patients with a previously negative capsule examination and a high suspicion of small bowel pathology may reveal additional finding in the majority of patients.

**KEYWORDS:** Patients; Disease; Capsule endoscopy.

**ABBREVIATIONS:** CD: Crohn's Disease; SPSS: Statistical Package for Social Sciences; GVHD: Graft Versus Host Disease; GISTs: Gastrointestinal stromal tumors.

## INTRODUCTION

Examination of the small bowel lesions represents a great challenge for gastroenterologist due to its length and inaccessibility using natural orifices. It is the only part of the gastrointestinal tract that is not accessible by non-surgical endoscopy. On the other hand, radiological techniques are relatively insensitive for diminutive, flat infiltrative or inflammatory lesions of the small bowel.<sup>1-3</sup>

As currently available diagnostic methods are far from satisfactory results regarding

diagnostic yields, patient comfort and technical ease. The video capsular endoscopy has been developed to allow direct examination of this inaccessible part of the gastrointestinal track in a safe, non-invasive and well-tolerated manner making it superior to the conventional methods, with minimal limitations in the presence of small bowel strictures or obstruction.<sup>4</sup>

Capsule endoscopy is mainly indicated for the evaluation of SB diseases, particularly for the diagnosis of OGIB. CE can be used in a variety of conditions including Crohn's Disease (CD), malabsorption, chronic diarrhea, and evaluation of refractory iron deficiency anemia, abdominal pain, polyposis syndromes, celiac disease, and detection of small bowel tumors. Graft Versus Host Disease (GVHD) is a rare additional indication.

The main risk of CE is capsular retention. The rate of capsule retention varies widely; depending almost on the clinical indications for CE, and ranges from 0% in healthy subjects, to 1.5% in patients with OGIB, to 5% in patients with suspected Chron's disease<sup>5</sup> and 21% in patients with intestinal obstruction.<sup>6</sup> Therefore, CE is contraindicated in patients with known strictures or swallowing disorders.

Currently used capsular endoscopy lack the ability to obtain tissue biopsy or provide endoscopic treatment. But the near future foreshadows capsules able to pass actively through the whole gastrointestinal track, to retrieve views from all organs and to reform drug delivery and tissue sampling.<sup>7-9</sup>

The quality of a CE study was found to be largely dependent upon capsular transit time through the stomach and small bowel. In capsular endoscopic procedure, capsule does not always reach the cecum within battery life in 20-25% of cases.<sup>10</sup> Long gastric transit time has been associated with failure of CE to reach the cecum. Positioning the patient in lateral decubitus and placement of CE in duodenum using endoscope are some of the methods tried to reduce gastric time.<sup>11</sup>

This study was conducted to assess the indications, findings, and complications of CE among these patients. It was done to assess the diagnostic yield of the capsule endoscopy and the complications that may occur in such patients. And to evaluate the effect of small bowel transit time on the diagnostic yield of the capsule endoscopy and assess whether longer gastric transit time would decrease the rate of complete examination of the small bowel.

## METHODOLOGY

We analysed the clinical experience of the MiRo CE in 119 patients with suspected small bowel diseases in the department of gastroenterology at ibn-sina and Fedail Hospitals in Sudan, during the period from January 2010 to June 2011. It is a retrospective and prospective study – the data of the patients underwent capsule taken either from the hospital records or from

the patients performing capsule endoscopy.

## STATISTICAL ANALYSIS

The data was analyzed with Statistical Package for Social Sciences (SPSS). The small bowel transit time of all patients was subdivided to 3 group analyzed to compare the diagnostic yield, P value less than 0.05 was consider as significant.

## RESULTS

One hundred nineteen patients, 69 male and 50 female were enrolled. The main indication for capsule endoscopy was OGIB, the CE identified the cause of bleeding in 39 of the 61 patients (63.9%) presented with obscure GI bleeding and Angiodysplasia was the main finding in such patients comprising 31.1%. Other indications for CE were small bowel diarrhea in 21 patients (17.6%), evaluation of Crohn's disease in 5 patients (4.2), chronic abdominal pain in 18 patients (17.6%), non-responding celiac disease in 3 patients (2.5%) and 4 patients presented with suspicion of small bowel malignancy (Table 1).

In our study angiodysplasia constitute 31.1%, malignancy 3.3%, inflammatory bowel disease 6.6% in addition to 14.8% diagnosed as ulcers and erosions.1.6% with worms and 1.6% with Celiac disease. Gastrointestinal tumors were identified in 9 patients (7.6%). Of those, two patients were examined for OGIB, the other seven patients were examined for non-bleeding indications. The types of tumors diagnosed included two Gastrointestinal stromal tumors (GISTs), three carcinoids, one adenocarcinoma, one gastric lymphoma and the histopathology was not available for two patients.

Capsule endoscopy was indicated in twenty one patients presenting with small bowel diarrhea. Of those a young 28 years old female presenting with alopecia, onchyodystrophy and small bowel diarrhea was diagnosed as Cronkhite – Canada syndrome based on CE finding together with the high clinical suspicion of her treating doctor. The CE revealed multiple jejunum and ileum polyps with a prominent big ampulla of vater.

In another young patient presenting with small bowel diarrhea and fever, colonoscopy showed cecal and descending colonic lesions, but the histopathology was not conclusive. Together with the terminal ilial lesions revealed by CE, tuberculosis was suspected. The patient responded well to antituberculous.

Gastric and small bowel transit time are defined as time interval between the first the last pictures taken in corresponding gastrointestinal tract. The mean small bowel transit time was 5 h 18 min. The duration of the small bowel transit time did not affect the diagnostic yield of the capsule endoscopy. The latter was affected by the underlying indication. The diagnostic yield for small bowel diarrhea, OGIB, and chronic abdominal pain were 80%, 63% and 50% respectively. (Table 2) (Chart 1)

	Indication for capsular endoscopy	Diagnosis								Total
		Normal	Angiodysplasia	Inflammatory bowel disease	Celiac disease	Tumours	Worms	Ulcers/erosions	Others	
OGIB	Count	22	19	4	1	2	1	9	3	61
	% within Indication for capsular endoscopy	36.1%	31.1%	6.6%	1.6%	3.3%	1.6%	14.8%	4.9%	100.0%
IBD	Count	1	0	4	0	0	0	0	0	5
	% within Indication for capsular endoscopy	20.0%	.0%	80.0%	.0%	.0%	.0%	.0%	.0%	100.0%
Chronic abdominal pain	Count	9	2	0	3	0	0	4	0	18
	% within Indication for capsular endoscopy	50.0%	11.1%	.0%	16.7%	.0%	.0%	22.2%	.0%	100.0%
Small bowel diarrhea	Count	4	0	5	5	3	2	0	2	21
	% within Indication for capsular endoscopy	19.0%	.0%	23.8%	23.8%	14.3%	9.5%	.0%	9.5%	100.0%
Non responding celiac disease	Count	1	0	0	1	1	0	0	0	3
	% within Indication for capsular endoscopy	33.3%	.0%	.0%	33.3%	33.3%	.0%	.0%	.0%	100.0%
Suspicion of small bowel tumour	Count	1	0	0	0	3	0	0	0	4
	% within Indication for capsular endoscopy	25.0%	.0%	.0%	.0%	75.0%	.0%	.0%	.0%	100.0%
Others,specify	Count	3	0	1	0	0	0	0	3	7
	% within Indication for capsular endoscopy	42.9%	.0%	14.3%	.0%	.0%	.0%	.0%	42.9%	100.0%
Total	Count	41	21	14	10	9	3	13	8	119
	% within Indication for capsular endoscopy	34.5%	17.6%	11.8%	8.4%	7.6%	2.5%	10.9%	6.7%	100.0%

Table 1: Indication for capsular endoscopy and diagnosis cross tabulation.

Bar Chart

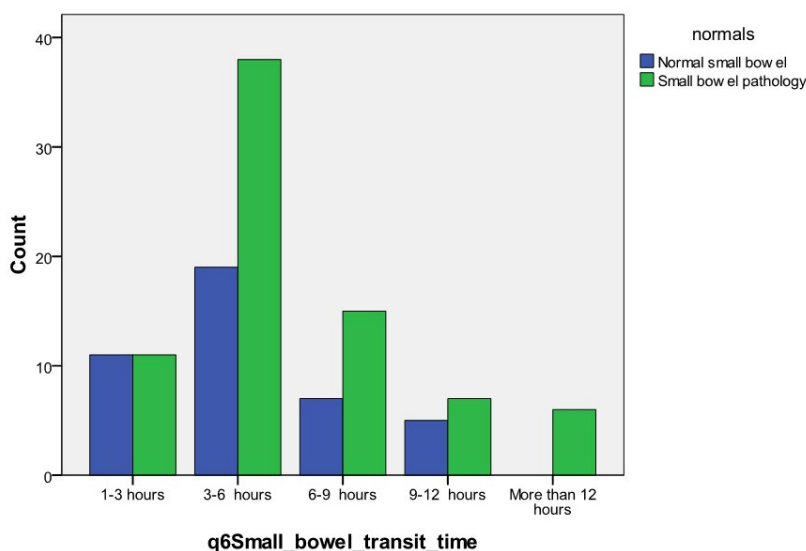


Chart 1: Cross tabulation: Small bowel transit time and diagnosis.

Small bowel transit time		Diagnosis		Total
		Normal small bowel	Small bowel pathology	
1-3 hours	Count	11	11	22
	% within Small bowel transit time	50.0%	50.0%	100.0%
3-6 hours	Count	19	38	57
	% within Small bowel transit time	33.3%	66.7%	100.0%
6-9 hours	Count	7	15	22
	% within Small bowel transit time	31.8%	68.2%	100.0%
9-12 hours	Count	5	7	12
	% within Small bowel transit time	41.7%	58.3%	100.0%
More than 12 hours	Count	0	6	6
	% within Small bowel transit time	.0%	100.0%	100.0%
Total	Count	42	77	119
	% within Small bowel transit time	35.3%	64.7%	100.0%

**Table 2:** Small bowel transit time and normal and small bowel pathology cross tabulation.

Complications occurred in 5.8% of the patients undergoing capsule endoscopy and capsule retention was the main complication. Retention is defined as a capsule remaining in the gastrointestinal for longer than two weeks.

In 10% of patients the capsule examination was not complete as the capsule did not reach the ileocecal valve. The gastric transit time was not associated with complete examination rate. The gastric transit time ranged from 4 minutes to 9 hours. In 5/7 patients (71.4%) the gastric transit time was less than 90 minutes and in the remaining 2 patients it was more than 90 minutes (Table 3).

Number	Gastric transit time	Capsule retention
1	46 min	Yes
2	16 min	Yes
3	14 min	Yes
4	1 hour	No
5	4 hours 47 min	No
6	8 hours 12 min	No
7	21 min	No
8	41 min	Yes
9	1 hour 16 min	No
10	9 hours	No
11	4 min	No
12	9 hours	Yes

**Table 3:** Gastric transit time in patients in which the capsule did not reach the iliocecal valve.

**DISCUSSION**

CE has a good diagnostic yield in patients with obscure

gastrointestinal bleeding which has been reported from 38% up to 93 %.<sup>12</sup> The first clinical trial by Lewis and Swain in 2001 compared capsule endoscopy to push enteroscopy in patients with OGIB. In which twenty patients with OGIB received both capsule endoscopy and push enteroscopy. A site of bleeding was found in 55% of patients using capsule endoscopy compared to 30% for push enteroscopy (p=NS).<sup>13</sup> In our study, CE demonstrated the cause of bleeding in 39 of the 61 patients (63.9%) with obscure GI bleeding. Compared to 73.9% from a study done by Eroy O, et al. in which angiodysplasia comprises 53%, malignancy 6.3% and inflammatory disease 6.3% of the total number of patients presenting with OGIB.<sup>4</sup>

In our study the tumors were 7.6% cases,<sup>9</sup> In a study by Gena M, et al. of 562 patients, 50 patients (8.9%) were diagnosed with small bowel tumors. The types of tumor diagnosed by capsule endoscopy included 8 adenocarcinomas (1.4%), 10 carcinoids (1.8%), 4 gastrointestinal stromal tumors (0.7%), 5 lymphomas (0.9%), 3 inflammatory polyps, 1 lymphangioma, 1 lymphangioectasia, 1 hemangioma, 1 hamartoma, and 1 tubular adenoma. Of the tumors diagnosed, 48% were malignant and the pathology results were not available for 10 patients.<sup>14</sup> It was also observed by Gena M, et al. that 9 of 67 patients (13%) younger than age 50 years who underwent capsule endoscopy for obscure bleeding had small bowel tumors. In our study 8 of the 9 patient diagnosed with small bowel tumors were above 55 years of age with the exception of 35 years old non responder celiac disease who was diagnosed as gastric lymphoma.

In our study Capsule endoscopy was indicated in 21 patients presenting with small bowel diarrhea, one of those patient suspected to have tuberculosis and treated accordingly. A study done by Dinesh K. Bhargava conclude that even though target

biopsy is an effective method of diagnosis, anti-tuberculous chemotherapy may be started on the basis of the endoscopic appearance if there is a high clinical suspicion of tuberculosis,<sup>15</sup> 5 of those patients with small bowel diarrhea diagnosed with suspicion of Crohn's disease, a recent meta analysis of 11 prospective comparative studies compared CE with other modalities found that CE had a better incremental yield, ranging between 15-44% compared with other modalities for both known and suspected Crohn's disease and the ability to detect small bowel mucosal breaks in early Crohn's disease. Fireman, et al. prospectively evaluated 17 patients with suspected Crohn's Disease. Capsule endoscopy found evidence of Crohn's disease (erosion, ulcers and strictures) in 12/17 patients (71%).<sup>16</sup> In our study four patients underwent CE to detect small bowel involvement as part of evaluation for IBD. Evidence of small bowel lesions was seen in two patients. One of which was suspected as Crohn's Disease on colonoscopy, but the histopathology was not conclusive. CE revealed small bowel involvement and confirmed the diagnosis of Crohn's disease. In addition, ten other patients were diagnosed as Crohn's disease, four presented with OGIB; five with small bowel diarrhea and another patient was suspected as Crohn's Disease during laparoscopic cholecystectomy in which the CE revealed proximal jejunal stricture and underlying Crohn's disease.

A young patient presenting with abdominal pain and a high eosinophil count was diagnosed as eosinophilic gastroenteritis based on a duodenal biopsy. CE revealed erythematous friable lesions with ulcerations, together with short villi in the proximal jejunum. These CE changes are non-specific and the definitive diagnosis involves histological evidence of eosinophilic infiltration in biopsy slides. The presence of more than 20 eosinophils per power field on microscopy is needed for diagnosis. As infiltration is often patchy, it can be missed and laparoscopic full thickness biopsy may be required.<sup>17,18</sup>

The MiRo CE used in this study is the smallest CE to date and offers both increased operation time with power saving technology and good image quality. The operation time of MiRo CE is almost 12 hours. A study done by Jeong Youp, et al. demonstrated that the longer the operation time increase the complete examination rate to 90%. A similar percent was obtained from our study (89.9%). Which also showed that the diagnostic yield was not improved by increased small bowel transit time; the p value was 0.1, which was found to be insignificant. A similar observation by Liao, et al. that reducing the capture rate in the stomach increase the complete examination rate, but not the diagnostic yield.<sup>19</sup> In contrast to Jonathan, et al. study which demonstrated that prolonged small bowel transit time during CE is associated with an increased diagnostic yield, probably due to a positive effect on image quality during a "slower" study.<sup>20</sup>

Unlike operation time, diagnostic yield could also be affected by the subjective decision of to whom CE should be utilized. The diagnostic yield of CE would be high with strong suspicion of small bowel disease and low if suspicion is mini-

mal.<sup>21</sup> In Our study, the diagnostic yield was 63.9% when the indication was obscure bleeding compared to 70% obtained from Jeong Youp, et al. study. The highest yield was 80% with small bowel diarrhea and the lowest yield was in the three patients presenting with sub-acute intestinal obstruction, in which CE didn't reveal any abnormalities.<sup>22</sup>

The use of capsule endoscopy for abdominal pain alone is less clear. Multiple studies have found contradictory results. Several abstracts have found the diagnostic yields to be low as four to 11%, while others found the yield to be as high as 54%. This difference is likely due to the heterogeneity of this study population.<sup>23-25</sup> In our study, the diagnostic yield for abdominal pain was found to be 50%.

Delayed gastric emptying defined as gastric transit time more than 90 minutes, was suggested by some reports of being a significant factor for incomplete examination examination.<sup>26,27</sup> In the past, a gastric transit time longer than 90 minutes meant that about 20% of the capsule's time was wasted in the stomach, leaving less than 5 hours for small bowel examination. In contrast, the MiRo CE still had 10 more hours to operate after a gastric transit time of 90 minutes.<sup>22</sup> In this study, the gastric transit time ranged from 4 minutes to 9 hours. In 5/7 patients (71.4%) the gastric transit time was less than 90 minutes and in the other 2(28.5) patients it was more than 90 minutes. However, even with the MiRo CE, an extremely prolonged gastric transit time still caused incomplete examination. In one case the capsule went into the small bowel after 2 hours for a short time and went back to the stomach and remained for another 7 hours. In another patient, the gastric transit time was also 9 hours leaving almost 3 hours for small bowel examination.

In our study, the CE was repeated in 5 patients, two were due to ongoing OGIB and negative results on CE. In patients with a negative CE and persistent OGB, a second look capsule endoscopy may be considered. If this is negative they should be referred for DBE. (recommendation (grade C)).

The second trial revealed underlying small bowel pathology in 4 of the 5 patients. Jones BH, et al. studied the yield of repeating wireless CE in patients with OGIB. And in ten patients with persistent gastrointestinal bleeding and previously negative capsule examination, a repeated study revealed additional findings in 50%.<sup>19</sup>

## CONCLUSION

Capsule endoscopy is a very useful diagnostic tool, especially in the presence of a strong suspicion of small bowel pathology. The main indication for capsular endoscopy was OGIB, and angiodysplasia was found to be the main underlying cause.

Complication occurred in 5.8 % of the patients undergoing capsular endoscopy and capsular retention was the major complication. In 10% of patients the capsular examination was



not complete and the capsule did not reach the ileocecal valve. The gastric transit time was not associated with complete examination rate. The duration of small bowel transit time during capsular endoscopy does not affect its diagnostic yield. The latter is affected by the underlying indication. The diagnostic yield for small bowel diarrhea, OGIB and chronic abdominal pain were 80%, 63% and 50% respectively. Repeating CE in patients with a previously negative capsule examination and a high suspicion of small bowel pathology may reveal additional findings in the majority of patients.

#### CONFLICTS OF INTEREST

None of the authors have conflicts of interest.

#### CONSENT

The authors have obtained written consent from all the patients which includes information and agreement that this data will be published.

#### REFERENCES

1. Rey JF, Ladas S, Alhassani A, Kuznetsov K, ESGE Guidelines Committee. European Society of Gastrointestinal Endoscopy (ESGE). Video capsular endoscopy: update to guidelines (May 2006). *Endoscopy*. 2006; 8: 1047-1053. doi: [10.1055/s-2006-944626](https://doi.org/10.1055/s-2006-944626)
2. Ginsberg GG, Barkun AN, Bosco JJ, et al. Wireless capsule endoscopy (August 2002). *Gastrointest Endosc*. 2002; 56: 621-624.
3. Leighton JA, Goldstein J, Hirota W, et al. Standards of practice Committee of the American Society for Gastrointestinal Endoscopy. Obscure gastrointestinal bleeding. *Gastrointest Endosc*. 2003; 58: 650-655.
4. Ersoy O, Sivri B, Arslan S, Batman F, Bayraktar Y. How much helpful is the capsule endoscopy for the diagnosis of small bowel lesions? *World J Gastroenterol*. 2006; 12(24): 3906-3910. doi: [10.3748/wjg.v12.i24.3906](https://doi.org/10.3748/wjg.v12.i24.3906)
5. Mata A, Liach J, Bordas JM. Wireless capsule endoscopy. *World J Gastroenterol*. 2008; 14: 1969-1971.
6. Pennazio M. Capsular endoscopy: where are we after 6 years of clinical use? *Dig Liver Dis*. 2006; 38: 867-878. doi: [10.1016/j.dld.2006.09.007](https://doi.org/10.1016/j.dld.2006.09.007)
7. Fireman Z, Glukhovskiy A, Scapa E. Future of capsule endoscopy. *Gastrointest Endosc Clin N Am*. 2004; 14: 219-227.
8. El-Matary W. Wireless capsule endoscopy: indications, limitations, and future challenges. *J Pediatr Gastroenterol Nutr*. 2008; 46: 4-12.
9. Swain P. The future of wireless capsule endoscopy. *World J Gastroenterol*. 2008; 14: 4142-4145.
10. Buscaglia JM, Kapoor S, Clarke JO, et al. Enhanced Diagnostic Yield with prolonged small bowel transit time during capsular endoscopy. *Int J Med Sci*. 2008; 5: 303-308. doi: [10.7150/ijms.5.303](https://doi.org/10.7150/ijms.5.303)
11. Almeida N, Figueiredo P, Freire P, et al. The effect of metoprolamide in capsular enteroscopy. *Dig Dis Sci*. 2009.
12. Tang SJ. The utility of capsular endoscopy in obscure gastrointestinal bleeding. *Gastrointest Endosc Clin N Am*. 2004; 14: 87-100.
13. Lewis BS, Swain P. Capsule endoscopy in the evaluation of patients with suspected small intestinal bleeding: results of a pilot study. *Gastrointest Endosc*. 2002; 56: 349-353.
14. Cobrin GM, Pittman RH, Lewis BS. Increased diagnostic yield of small bowel tumors with capsule endoscopy. *Cancer*. 2006; 107(1): 22-27. doi: [10.1002/cncr.21975](https://doi.org/10.1002/cncr.21975)
15. Bhargava DK, Kushwaha AKS, Dasarathy S, Shrinivas DM, Chopra P. Endoscopic diagnosis of segmental colonic tuberculosis. *Gastrointestinal Endoscopy*. 1992; 38(5): 571-574.
16. Fireman Z, Mahajna E, Broide E, et al. Diagnosing small bowel Crohn's disease with wireless capsule endoscopy. *Gut*. 2003; 52: 390-392. doi: [10.1136/gut.52.3.390](https://doi.org/10.1136/gut.52.3.390)
17. Baig M, Qadir A, Rasheed J. A review of eosinophilic gastroenteritis. *Journal of the National Medical Association*. 2006; 98(10): 1616-1619.
18. Talley N, Shorter R, Phillips S, Zinsmeister A. Eosinophilic gastroenteritis: a clinicopathological study of patients with disease of the mucosa, muscle layer, and subserosal tissues. *Gut*. 1990; 31(1): 54-58. doi: [10.1136/gut.31.1.54](https://doi.org/10.1136/gut.31.1.54)
19. Jones BH, Sharma VK, Leighton JA, et al. Yield of repeat wireless video capsule endoscopy (CE) in patients with obscure GI bleeding (OGIB). *Gastroenterology*. 2003; 124: A-244.
20. Buscaglia JM, Kapoor S, Clarke JO, et al. Enhanced Diagnostic Yield with prolonged small bowel transit time during capsular endoscopy. *Int J Med Sci*. 2008; 5: 303-308. doi: [10.7150/ijms.5.303](https://doi.org/10.7150/ijms.5.303)
21. Cheifetz A. The risk of retention of capsular endoscopy in patients with Chron's disease. *Am J Gastroenterol*. 2006; 101(10): 2218-2222. doi: [10.1111/j.1572-0241.2006.00761.x](https://doi.org/10.1111/j.1572-0241.2006.00761.x)

22. Park JY, Kim HM, Choi YA. Longer capsule Endoscopy Operation Time increases the rate of complete examination of the small bowel. *Hepato-Gastroenterology*. 2010; 57: 746-750.

23. Enns R, Mergener K, Brandabur J. Capsule endoscopy (CE): A multicenter, international review and comparison of capsule studies done in three different tertiary care centers. *Gastrointest Endosc*. 2003; 57: AB101.

24. Fireman Z, Eliakim R, Adler S, et al. Capsule endoscopy (CE) in real life-a 4 centers experience of 160 consecutive patients in Israel. *Gastrointest Endosc*, 2003; 57: AB85.

25. Fleischer DE, Leighton JA, Sharma VK, et al. Video capsule endoscopy (VCE) is useful in the evaluation of unexplained abdominal pain (AP). *Gastroenterology*. 2003; 124: A245-A245. doi: [10.1016/S0016-5085\(03\)81232-5](https://doi.org/10.1016/S0016-5085(03)81232-5)

26. Selby W. Complete small-bowel transit in patients undergoing capsule endoscopy: determining factors and improvement with metoclopramide. *Gastrointest Endosc*. 2005; 61: 80-85. doi: [10.1016/S0016-5107\(04\)02462-9](https://doi.org/10.1016/S0016-5107(04)02462-9)

27. Ben-Soussan E, Savoye G, Antonietti M, Ramirez S, Lerebours E, Ducrotte P. Factors that affect gastric passage of video capsule. *Gastrointest Endosc*. 2005; 62: 785-790. doi: [10.1016/j.gie.2005.07.040](https://doi.org/10.1016/j.gie.2005.07.040)