

Case Report

*Corresponding author

Arpit Saxena, MS

Department of ENT

Command Hospital

Lucknow, UP, India

Tel. +91-9532306179

E-mail: arpitsaxenaexam@gmail.com

Volume 2 : Issue 2

Article Ref. #: 1000OTLOJ2115

Article History

Received: May 9th, 2016

Accepted: May 16th, 2016

Published: May 18th, 2016

Citation

Saxena A, Ramesh AV, Mehra PJ, Nikhilesh E. Bilateral internal jugular vein thrombosis: an unusual presentation of Lemierre syndrome. *Otolaryngol Open J.* 2016; 2(2): 70-72. doi: [10.17140/OTLOJ-2-115](https://doi.org/10.17140/OTLOJ-2-115)

Copyright

©2016 Saxena A. This is an open access article distributed under the Creative Commons Attribution 4.0 International License (CC BY 4.0), which permits unrestricted use, distribution, and reproduction in any medium, provided the original work is properly cited.

Bilateral Internal Jugular Vein Thrombosis: An Unusual Presentation of Lemierre Syndrome

Arpit Saxena, MS^{*}; A. V. Ramesh, MS; Poonam Raj Mehra, MS; E. Nikhilesh, MBBS

Department of ENT, Command Hospital, Lucknow, UP, India

ABSTRACT

Background: Lemierre syndrome is a rare disease characterized by internal jugular vein thrombosis and septic emboli. These symptoms typically develop after acute oropharyngeal infection by *Fusobacterium necrophorum*.

Case Report: We present an unusual case of 54 years old lady suffering from Lemierre syndrome with bilateral internal jugular vein and carotid artery thrombosis with fatal outcome.

Conclusion: Lemierre syndrome is a rare disease. Thrombosis of bilateral Internal Jugular Vein associated with Lemierre syndrome has never been reported.

KEYWORDS: Bilateral internal jugular vein thrombosis; *Fusobacterium necrophorum*; Lemierre Syndrome.

INTRODUCTION

Lemierre syndrome is acute anaerobic oropharyngeal infection with secondary septic emboli causing internal jugular vein thrombophlebitis and other metastatic infections. Septic emboli may also cause infections in other organs like lungs, bones, joints and brain. The most commonly isolated pathogen is *Fusobacterium necrophorum*.¹ Lemierre syndrome is often described as the “forgotten disease”.² An uncommon disease, its mortality rates are still high.

CASE REPORT

A 54 years old obese woman presented to Otolaryngology department with complaints of dysphagia and progressive swelling in neck since two months but had deteriorated in past 15 days. There was no known comorbidity. The patient had taken treatment at another hospital. On presentation, the patient was a febrile, oriented and vitals were stable. There was a diffuse swelling around neck. Video laryngoscopy revealed a swelling in posterior pharyngeal wall with normal larynx. Magnetic resonance imaging done in previous hospital revealed a retropharyngeal abscess (Figure 1) following which incision and drainage of posterior pharyngeal wall was done in emergency operation theatre. Drainage revealed no pus and patient was admitted in intensive care unit. Haematological profile revealed Total Leukocyte Count of 18400/mm³ with predominant polymorphs and serum creatinine of 2.4 mg%. Ultrasound abdomen showed bilateral hydronephrosis with small left uretric calculus. Radiograph chest showed bilateral pleural effusion, right more than left with mediastinal widening (Figure 2). Serum cortisol was 715 IU/L ruling out Cushing Syndrome. Contrast enhanced computed tomography neck showed soft tissue edema extending from scalp to neck with bilateral Internal Jugular Vein (IJV) thrombosis (Figure 3). Throat swab and blood culture did not reveal any pathogens. She was started on broad spectrum intravenous antibiotics consisting of Levofloxacin, Teicoplanin and Clindamycin. Low molecular weight heparin was added to prevent further thromboembolism. Cardiothoracic unit consultation denied for any surgical intervention as ligation of bilateral IJV will lead to cerebral edema. Next day she developed dyspnoea and had to be intubated. The swelling of the neck increased progressively and inspite of adequate anaerobic antibiotic cover patient succumbed to her illness after five days.

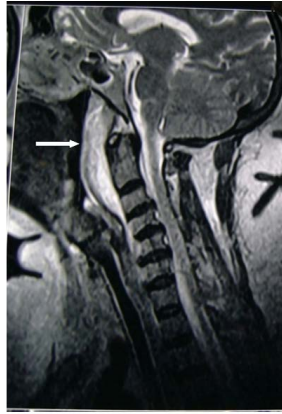

Figure 1: Retropharyngeal abscess in MRI neck (white arrow).

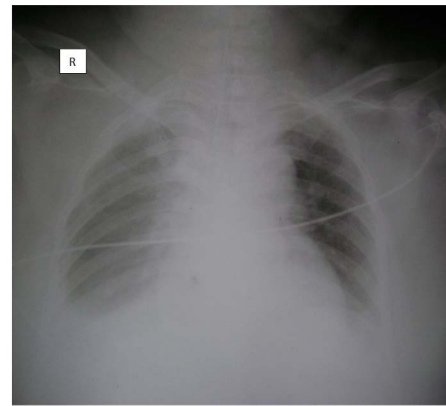


Figure 2: Radiograph showing bilateral pleural effusion.

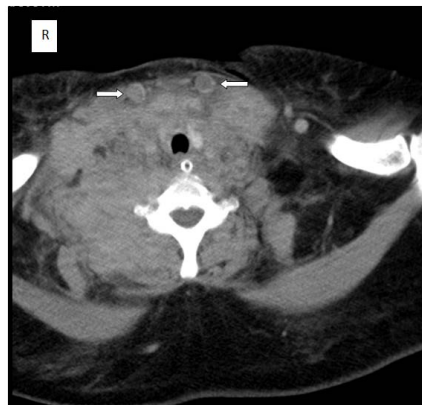


Figure 3: CECT neck showing bilateral internal jugular vein thrombosis (white arrow indicating bilateral IJV).

DISCUSSION

Courmant and Cade in 1900 were first to describe the correlation between oropharyngeal infection and sepsis.³ Lemierre in 1936 published a series of 20 cases, 18 of whom died.⁴ Karkos PD et al conducted a systematic review of 84 research articles. The median age of the patients was 22 years. Most of the patients were young non immune compromised individuals who presented with sore throat, neck mass or neck pain.⁵ The oropharyngeal infection ranged from mild to fulminant in severity. The septic emboli from oropharyngeal infection caused ipsilateral internal jugular vein thrombosis and infection of the lungs. *Fusobacterium* is unique among non spore forming anaerobes, first of its virulence and association with Lemierre's syndrome as a monomicrobial infection and second because it seems probable that it is an exogenously acquired infection.⁶ In addition to *Fusobacterium*, various anaerobes isolated from blood include *Streptococcus*, *Bacteroides* and *Peptostreptococcus*.⁷

The septic emboli could be thrown by infection from other extra pharyngeal sites like middle ear, female urogenital tract and gastrointestinal tract. The septic emboli have been identified in organs such as bone, meninges, abdominal viscera, peritoneum and soft tissue.⁸

X-Ray Chest was the first investigation asked in 92% of cases. IJV thrombosis has been diagnosed with Ultrasonography. PP Suthar et al have recommended Colour Doppler as the preferred modality to diagnose IJV thrombosis.⁹ Broad spectrum antibiotic therapy with potent anaerobic activity for e.g. either clindamycin or a combination of a beta-lactam and metronidazole is the cornerstone of management. Improvement with symptoms, resolution of leucocytosis and falling inflammatory indices are signs of response to treatment. The treatment is continued for 2-6 weeks. The intravenous antibiotics may be changed to oral based on response. Following regression of symptoms, patients can be kept over oral clindamycin therapy for 04 weeks.¹⁰ Availability of appropriate antibiotics has significantly reduced the mortality rate to 17 %.¹¹

The use of anticoagulants for septic emboli is debatable. Lustig et al reported similar outcome irrespective of whether anticoagulants were used or not.¹² Some have recommended anticoagulation cavernous sinus thrombosis only. While the use of anticoagulants seems logical, there are no randomised controlled trials to support their use.¹¹ In this case, patient had thrombosis of both internal jugular veins and the common carotid arteries. The patient was not responding to the antibiotics. Hence, low molecular weight heparin was used in standard doses.

CONCLUSION

Most cases of Lemierre syndrome have been described in young males with ipsilateral Internal Jugular Vein thrombosis. Present case was a middle aged woman who had retropharyngeal abscess followed by bilateral internal jugular vein thrombosis which has never been reported in literature. The prognosis in bilateral IJV thrombosis remains poor.

CONFLICTS OF INTEREST: None.

CONSENT

Authors obtain written informed consent from the patient for submission of this manuscript for publication

REFERENCES

1. Weesner C L, Cisek JE. Lemierre syndrome: the forgotten disease. *Ann Emerg Med.* 1993; 22(2): 256-258. doi: [10.1016/S0196-0644\(05\)80216-1](https://doi.org/10.1016/S0196-0644(05)80216-1)
2. Courmont P, Cade A. Sur uneseptico-pyohemie de l'homme simulant la pesteetcausee par un streptobacilleanaerobie. *Arch Med Exp Anat Patol.* 1900; 12: 393-418.
3. Lemierre A. On certain septicemias due to anaerobic organisms. *Lancet.* 1936; 227(5874): 701-703. doi: [10.1016/S0140-6736\(00\)57035-4](https://doi.org/10.1016/S0140-6736(00)57035-4)
4. Alston JM. Necrobacillosis in Great Britain. *Br Med J.* 1955; 2(4955): 1524-1528. Web site. http://www.js-tor.org/stable/20333911?seq=1#page_scan_tab_contents. Accessed May 8, 2016
5. Karkos PD, Asrani S, Karkos CD, et al. Lemierre's syndrome:

A systematic Review. *Laryngoscope.* 2009; 119(8): 1552-1559. doi: [10.1002/lary.20542](https://doi.org/10.1002/lary.20542)

6. Riordan T. Human infectionwith Fusobacterium necrophorum (Necrobacillosis), with a focus on Lemierre's Syndrome. *Clin Microbiol Rev.* 2007; 20(4): 622-659. doi: [10.1128/CMR.00011-07](https://doi.org/10.1128/CMR.00011-07)
7. Wong AP, Duggins ML, Neil T. Internal jugular vein septic thrombophlebitis (lemierre syndrome) as a complication of pharyngitis. *J Am Board Fam Med.* 2015; 28(3): 425-340. doi: [10.3122/jabfm.2015.03.140131](https://doi.org/10.3122/jabfm.2015.03.140131)
8. Sinave CP, Hardy GJ, Fardy PJ. The Lemierre syndrome: suppurative thrombophlebitis of the internal jugular vein secondary to oropharyngeal infection. *Medicine.* 1989; 68(2): 85-94. Web site. http://journals.lww.com/md-journal/Citation/1989/03000/The_Lemierre_Syndrome_Suppurative.2.aspx. Accessed May 8, 2016.
9. Suthar PP, PatelAKB, PatelK, Doshi RK, PatelNA. Grave complication of pharyngitis: lemierre syndrome. *J Clin Diagn Res.* 2015; 9(6): TD03-TD04. doi: [10.7860/JCDR/2015/11917.6060](https://doi.org/10.7860/JCDR/2015/11917.6060)
10. Sara Z et al. Insight into a forgotten disease: Lemierre's syndrome. *Eur J Clin Micriol Infect Dis.* 1998; 17: 561-565. Web site. http://www.hcplive.com/journals/Resident-and-Staff/2005/2005-03/2005-03_02/. Accessed May 8, 2016.
11. Hagelskjaer LH, Prag J. Human necrobacillosis, with emphasis on Lemierre's syndrome. *Clin Infect Dis.* 2000; 31(2): 524-532. doi: [10.1086/313970](https://doi.org/10.1086/313970)
12. Lustig LR, Cusick BC, Cheung SW, Lee KC. Lemierre's syndrome: two cases of postanginal sepsis. *Otolaryngol Head Neck Surg.* 1995; 112(6): 767-772. doi: [10.1016/S0194-5998\(95\)70192-3](https://doi.org/10.1016/S0194-5998(95)70192-3)