

Systematic Review

*Corresponding author

Arianna Di Stadio, MD, PhD
Department of Otolaryngology
University "La Sapienza"
00185 Rome, Italy
E-mail: ariannadistadio@hotmail.com

Volume 2 : Issue 5

Article Ref. #: 1000OTLOJ2128

Article History

Received: August 22nd, 2016

Accepted: September 27th, 2016

Published: September 27th, 2016

Citation

Di Stadio A. Arachnoid cyst of internal auditory canal: How the temporal bone findings explain ear symptoms and suggest the best treatment to do. *Otolaryngol Open J.* 2016; 2(5): 125-131. doi: [10.17140/OTLOJ-2-128](https://doi.org/10.17140/OTLOJ-2-128)

Copyright

©2016 Di Stadio A. This is an open access article distributed under the Creative Commons Attribution 4.0 International License (CC BY 4.0), which permits unrestricted use, distribution, and reproduction in any medium, provided the original work is properly cited.

Arachnoid Cyst of Internal Auditory Canal: how the Temporal Bone Findings Explain Ear Symptoms and Suggest the Best Treatment to do

Arianna Di Stadio, MD, PhD*

Department of Otolaryngology, University "La Sapienza", 00185 Rome, Italy

ABSTRACT

Objective: Aim of this short review is to identify relevant findings in clinical and surgical treatment studying arachnoid cyst of internal auditory canal.

Study design: Retrospective study of relevant papers in literature.

Methods: PubMed and Google Scholar searches using the following keywords: arachnoid cyst, internal auditory canal, temporal bones study, schwannoma of internal auditory canal, cystic schwannoma, MRI findings, surgery of internal auditory canal. Only the article where three keywords, included always arachnoid cyst, were considered. The study analyzed the etiopathogenesis of arachnoid cyst, hearing and vestibular symptoms and temporal bone findings.

Review and conclusion: The author identified and reviewed a total of 46 articles. The results showed high incidence of hearing loss that was the more common symptom than vestibular one. Arachnoid cyst carried out more compression on the vestibular nerves than on the cochlear one. The review allowed us to identify which mechanism of damage arachnoid cyst acting on the nerves. It is necessary to consider the arachnoids cyst in differential diagnosis with tumors and pathologies involving the internal auditory canal.

KEYWORDS: Arachnoid cyst; Internal auditory canal; Temporal bones study; Schwannoma of internal auditory canal; Cystic schwannoma; MRI findings; Surgery of internal auditory canal.

INTRODUCTION

Arachnoid Cyst (AC) of Internal Auditory Canal (IAC) is a very rare finding. Sumner and Thijssen described the first clinical case in the beginning of '70.^{1,2} Schucknecht, in 1993, identified this structure in the internal auditory canal of three temporal bones.³ Arachnoid cyst can be found in 50% of cases in the Sylvian fissure, in the posterior fossa in 20% and in the Ponto Cerebellum Angle (APC) in 10% of case. In children the higher incidence is in the middle cranial fossa.⁴ AC are discovered in the 0.5% of surgery to treat the tumor of internal auditory canal, sometimes as accidental findings or mistaken as Schwannoma.³ The author tries to define when and if, the Arachnoid cyst needs to be considered in differential diagnosis in presence of hearing loss, dizziness and facial palsy.

ARACHNOID CYST ETHIOPATHOGENESIS

The etiology of arachnoid cyst is poorly understood. Congenital/primary^{5,6} and inflammatory origin/secondary^{6,7} could explain its births and growths. Two mechanisms can determinate an arachnoid cyst. One, is the inflammation, that can explain the primary cyst too. The leptomeningeal infection can be acquired prenatally through placenta.⁸ This inflammation produces a localized scarring and adhesion involving the subarachnoid space, leading to a flocculation and closure of its communication with the adjacent subarachnoid compartment.^{9,10} The cyst usually contains a clear colorless fluid. Their wall consists of a vascular collagenous membrane lined by a flat single-layered arachnoid endothelium. The presence of fibrous thickening

and chronic inflammatory cells suggest a post infection or post traumatic origin.¹¹ The second mechanism involved in cyst formation is the splitting of arachnoid membrane. This is probably the most common between the two. Also in this second case, cyst contains clear colorless fluid but the wall is regular without thickening and similar to the normal arachnoid membrane. The clear fluid is similar to cerebrospinal fluid (CSF) but may have a higher concentration of protein than CSF.¹² The variation in cyst volume is widely discussed in literature. There are different theories to explain the mechanism: 1) The outer arachnoid cells liquid production; 2) The slit valve mechanism causing intermittent entrapment of CSF; 3) Osmotic gradient between the cysts. The slit valve mechanism seems to be the more probable cause of the growth, because liquid production is very rare by the cells, as the osmotic gradient.^{13,14}

SYMPTOMS

Arachnoid cyst can be asymptomatic or symptomatic in function of its volume and its position in the internal auditory canal (Figure 1). Sumner described as first a facial paralysis as sequel of an arachnoid cyst of internal auditory canal in a child. He reported a case of child 3 years old with facial paralysis; the arachnoid cyst compressed the nerve determining a facial palsy.¹ Thijssen as Sumner described a peripheral facial palsy in a 7 year old girl, in this case deafness in the same side of facial palsy was present.² In 1986 Hardenberg described an AC in the internal auditory canal pervasive to the region of the oval window with disturbance of ossicular chain function.¹⁵

Schucknecht reported three cases of arachnoid cyst of internal auditory canal, two of the three patients presented bilateral sensorineural hearing loss, the third case showed a mixed

hearing loss with speech discrimination at 68%.³ Francis reported a case of AC of right internal auditory canal in a 50 year woman that presented with progressive hearing loss and tinnitus and occasional loss of balance; neuro-otological examination showed a profound sensorineural hearing loss in the right ear and a paralysis of right lateral semicircular canal reflex.⁷ Takano described a 59 years old woman with facial spasm and tinnitus in the left side persistent since 3 years, also in this occasion TC and T2 MRI showed the presence of an arachnoids cyst.¹⁶ Aubry presented another case of symptomatic arachnoid cyst, in his case report the patient showed hearing loss, tinnitus and recurrent vertigo.¹⁷ Mastronardi identified an AC in a patient affected by left hemifacial spasm since 10 years.¹⁸ Fleck described one patient affected by unilateral sensorineural hearing loss associated with tinnitus.¹⁹ Zhang, in a multi case report, presented a patient with sensorineural hearing loss and tinnitus without ABR response in the ear and other two patients didn't present any symptoms.⁶ Tamarind presented a 10 years old boy with facial palsy and hearing loss.⁵

We can conclude that hearing loss is the most common symptoms in patients affected by arachnoid cyst of internal auditory canal followed by facial nerve disorders (Figure 2).

TEMPORAL BONE AND SURGERY FINDINGS

Few TBs studies are available in literature due to the low incidence of arachnoid cyst in human subject.^{3,6} Surgery case reports describe widely the findings of internal auditory canal in case of arachnoids cyst resection.^{2,5,7,16-19} Figure 3 shows the different findings in displacement and compression of the nerves between the TBs studies and surgery. Figures 4 and 5 summarized dif-

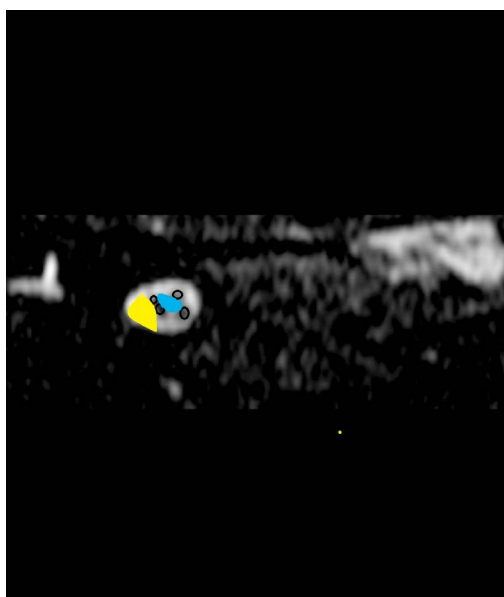


Figure 1: MRI Figure of IAC in T2: in blue Arachnoid Cyst in central position between the nerves, in yellow lateral to the structures.

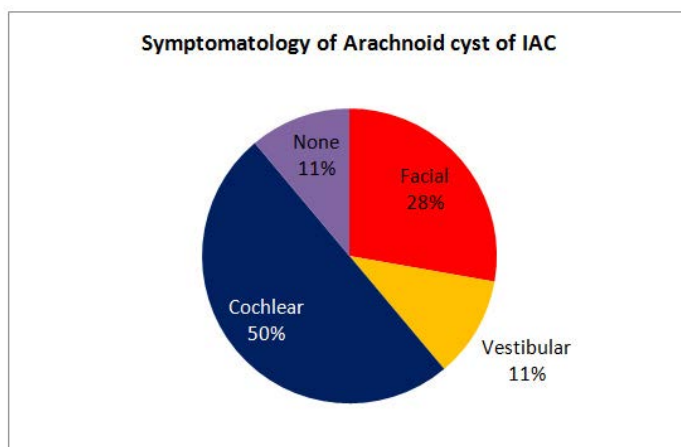


Figure 2: Symptomatology distribution in case of Arachnoid cyst of IAC.

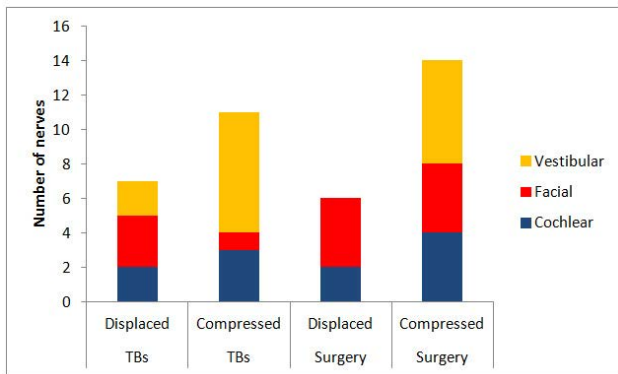


Figure 3: Nerve involvement in the different actions of Arachnoid cyst in Temporal bone findings and surgery reports.

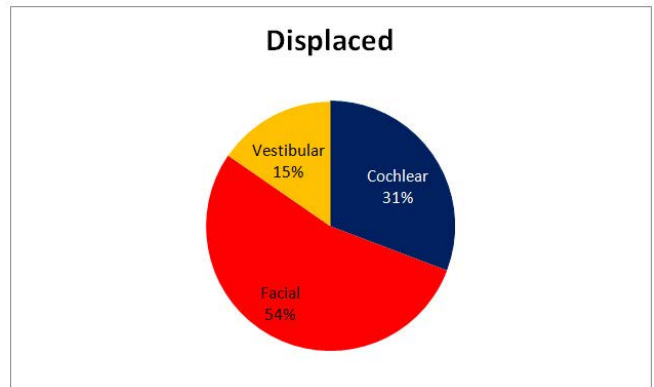


Figure 4: Incidence of nerves displaced by Arachnoid Cyst action.

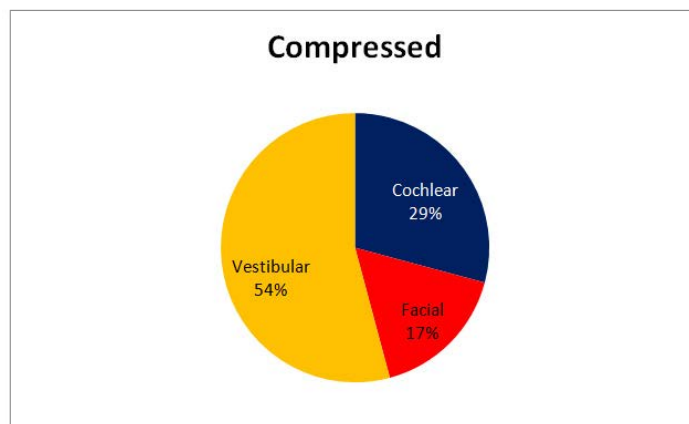


Figure 5: Incidence of compression acted by arachnoid cyst on the different structures.

ferent distribution between displacement and compression between the nerves. Vestibular nerves seem to be most frequently compressed (54%) than cochlear nerve (29%). The facial nerve is more frequently displaced (54%) but less compressed (17%). Figure 6 shows the otopathology aspects of the cyst in the IAC.

MECHANISM OF DAMAGE

Erick studied the average of diameter of internal auditory canal using MRI study on more 1230 patients and, he identified 5.93

mm as caliber of internal auditory canal. It's easy understand that in this small space, also a small structure (within 1 mm) can produce a nerves compression. The compression process starts when and if the cyst changes its volume. The first step is a nerve displacement in case of cyst under 1 mm. Figure 1 showed how cyst can arise in different areas of IAC and can displace one or more nerves. An AC in central position in the IAC (blue in Figure 1) with growth compresses the four nerves against the wall of IAC, probably a cyst in this position can be symptomatic also in volume <1 mm. A cyst in the lateral position (yellow in Figure

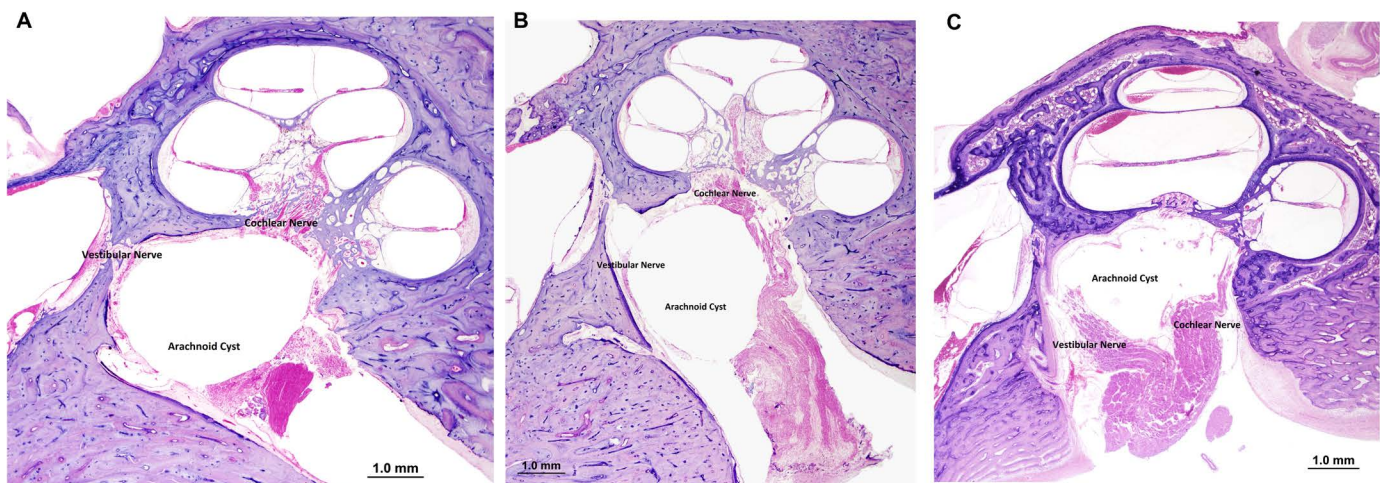


Figure 6: A) Temporal bone aspect of arachnoid cyst of IAC that compress cochlear and vestibular nerve. B) In this aspect the main pressure is on the vestibular nerve and the cochlear nerve is displaced. C) In this TB the cyst displaced both nerve without important compression.

Arachnoid Cyst versus	*Schwannoma	*Ganglioma	*Giant Cell Tumor
	*Meningioma	*Lipoma	*Teratoid/Raboid tumor
	*Gliosarcoma	*Cavernous Angioma	*Metastasis
	*Hemangiopericytoma	*Solitary Plasmacytoma	

Table 1: Differential diagnosis.

1), displaces the nerves too, but could be less aggressive than the one in central position and be asymptomatic for long time also if bigger than 1 mm. The compression mechanism demyelinates the nerve as first arriving to totally destroy the structures.

DISCUSSION

Literature supports the idea that arachnoid cyst of Internal Auditory canal can be symptomatic. Compression and displacement of vestibular nerves seem to be more common than cochlear nerve.

Vertigo and dizziness are less common than hearing loss because cyst normally has a slow growth and it allows an adaptive mechanism by the vestibular apparatus that involves somatosensory (proprioception) and vision other the ear.

We have to consider a cyst involvement, in case of recurrent facial palsy, without regression after several months.

Sensorineural Hearing Loss (SNHL) can be progressive and asymptomatic in the beginning, but can become “the pure” symptom of arachnoid cyst. The audiogram shows a unilateral sensorineural hearing loss with a sloping threshold involving all frequencies.

Word recognition test and ABR can help in diagnosis. WR recognition test is worse than expected from audiometric threshold. ABR results destructured presenting prolonged latencies of 1st, 3rd and 5th peak.

The progressive SNHL in AC, is a phenomenon due to neurodegeneration, so word recognition test and ABR can detect this event more quickly than Pure Tone Audiometry.

Arachnoid cyst can be discovered as accidental finding during a schwannoma surgery, because it is often confused as cystic Schwannoma.^{2,7,17} Arachnoid cyst and acoustic schwannoma can present same symptoms and onset.

Using imaging MRI today is possible figure out the correct diagnosis. Arachnoid Cyst appears as well demarcated area, hypo intense on T1 weighted imaging and hyper intense on T2 weighted imaging, without contrast enhancement with gadolinium.¹⁸ Acoustic schwannoma enhances gadolinium in homogenous way; it is intense to CSF and present different shapes: round (14%), oval (36%) and poliglobular in 14% of cases.²⁰⁻²³ The acoustic cystic schwannoma exhibits higher signal intensity than CSF in T1- and T2- weighted Figures,^{22,24} and the intramu-

ral cyst showed peripheral enhancement after gadolinium.

Schwannoma and Arachnoids Cyst have similar symptomatology analyzing audiometric and vestibular findings. A sudden onset of symptoms is rare in both pathologies even if, in case of rapid growth of cystic schwannoma the symptom becomes quickly disabling for patient. Arachnoid cyst has usually a slow growth, slight symptoms and these are usually not referred by the patients as disabling.

Differential diagnosis is very difficult in case of pathologies involving the IAC. Common symptoms are presented by different types of cancers/masses; nerves compression or involvement is always present due to the small caliber of IAC. Vestibular symptoms as dizziness, hearing loss and tinnitus and, in some case facial palsy, reveals the nerve involving and damage.²⁵⁻³⁴

Table 1 summarizes cancer and/or mass (common and rare) that can arise in the IAC.

A correct diagnosis is useful to figure out to the best treatment to do. Gliosarcoma, hemangiopericitoma and metastasis in the IAC are treated with surgical approach associated to radio/chemotherapy.^{25,26}

The conservative approach using gamma knife therapy can be useful if Schwannoma has a small volume.³⁵

The posterior fossa approach is the best option to treat meningioma.³⁶

Symptoms as manifestation of nerves involvement help us also to chose the treatment. Good hearing threshold and vestibular function preservation are findings often present in arachnoid cyst, this suggests that a middle temporal fosse approach³⁷ or a retrosigmoid one³⁸ can be the good option to preserve the nerve functions. The endoscopic approach^{19,39} would be the best choice but not all surgeons are comfortable with it.

The translabyrinthine approach is always the best option to treat big mass in patients with hearing loss.

It is possible to remove the arachnoid cyst in one block, or to fenestrate it, removing part of liquid content and, then to remove its capsule.¹⁹ The endoscopic surgery needs to fenestrate the cyst before whole removal especially in case of big mass. Using a middle fossa approach the whole mass removal is easy to do.

Audio-logic and vestibular evaluations are important before diagnosis, and after treatment also.

As before exposed, test results are able to address the specialist into the correct diagnosis. It is necessary to schedule one year follow-up also in patients after cyst removal, even if arachnoid cyst rarely recurrent.

Arachnoid cyst surgery can determinate some sequelae, that have to be treated correctly. Vestibular rehabilitation is the gold standard to achieve vestibular compensation.⁴⁰ Facial nerve palsy can be treated by physical rehabilitation,⁴¹ or using surgical procedure in inveterate case.⁴²⁻⁴⁵ Residual hearing loss is successfully treated using temporal bone anchorage device.⁴⁶

CONCLUSION

The author concluded even if AC is a very rare finding, it is always necessary to consider it as differential diagnosis of mass in the IAC. The SNHL is the most common symptom in the mass of IAC. Hearing test as pure audiometry, WR and ABR are helpful in diagnosis identification. MRI findings are fundamental to detect the pathologies origin and the recent improvement of this methodology helps us to understand the findings more easily. Undoubtedly, the most difficult differential diagnosis is the one with Cystic Schwannoma, but a strict follow-up can detect the correct findings. Further researches improving the quality of MRI will be necessary to identify the AC with accuracy.

ACKNOWLEDGEMENT

Special thanks to Professors Joseph Nadol and Micheal McKenna to allow the use of images from Otopathology collection of MEEI and to Mrs Garyphallia Patagonis for her help in the graphics and images production.

CONFLICTS OF INTEREST

The authors declare that they have no conflicts of interest.

REFERENCES

1. Sumner TE, Benton C, Marshak G. Arachnoid cyst of the internal auditory canal producing facial paralysis in a three-year-old child. *Radiology*. 1975; 114(2): 425-426. doi: [10.1148/114.2.425](https://doi.org/10.1148/114.2.425)
2. Thijssen HO, Marres EH, Slooff JL. Arachnoid cyst simulating intrameatal acoustic neuroma. *Neuroradiology*. 1976; 11(4): 205-207. doi: [10.1007/BF00346080](https://doi.org/10.1007/BF00346080)
3. Schuknecht HF, Gao YZ. Arachnoid cyst in the internal auditory canal. *Ann Otol Rhinol Laryngol*. 1983; 92(6 Pt 1): 535-541. doi: [10.1177/000348948309200601](https://doi.org/10.1177/000348948309200601)
4. Huang JH, Mei WZ, Chen Y, Chen JW, Lin ZX. Analysis on clinical characteristics of intracranial Arachnoid Cysts in 488 pediatric cases. *Int J Clin Exp Med*. 2015; 8(10): 18343-18350.

5. Thakar S, Furtado SV, Hegde AS. Arachnoid cyst in the internal auditory canal causing fluctuating facial paresis in a child. *Childs Nerv Syst*. 2011; 27(7): 1177-1179. doi: [10.1007/s00381-011-1458-1](https://doi.org/10.1007/s00381-011-1458-1)
6. Zhang Q, Kaga K, Sano M, Takegoshi H. Arachnoid cysts confined to the internal auditory canal or facial nerve canal. *J Laryngol Otol*. 2011; 125(10): 1053-1058. doi: [10.1017/S0022215111001745](https://doi.org/10.1017/S0022215111001745)
7. Francis HW, Nager GT, Holliday MJ, Long DM. Association of heterotopic neuroglial tissue with an arachnoid cyst in the internal auditory canal. *Skull Base Surg*. 1995; 5(1): 37-49. doi: [10.1055/s-2008-1058949](https://doi.org/10.1055/s-2008-1058949)
8. Zulch KJ. *Brain Tumors: Their Biology and Pathology*. 3rd ed Berlin, Germany: Springer Verlag; 1986
9. Burger PC, Scheithauer BW, Vogel FS. *Surgical Pathology of the Nervous System and its Coverings*. 3rd ed. New York, USA; Churchill Livingstone; 2002.
10. Horrax G. Generalized cisternal arachnoiditis simulating cerebellar tumor: Its surgical treatment and end results. *Arch surg*. 1924; 9(1): 95-112. doi: [10.1001/archsurg.1924.01120070098004](https://doi.org/10.1001/archsurg.1924.01120070098004)
11. Russel D, Rubinstein LJ. *Pathology of Tumors of the Nervous System*. 5th ed. Baltimore, MD, USA; William and Wilkins; 1989.
12. Matsuda M, Hirai O, Munemitsu H, Kawamura J, Matsubayashi K. Arachnoid cysts--report of two adult cases in the interhemispheric fissure and over the cerebral convexity. *Neurol Med Chir (Tokyo)*. 1982; 22(1): 71-76. doi: [10.2176/nmc.22.71](https://doi.org/10.2176/nmc.22.71)
13. Rengachary SS, Watanabe I. Ultrastructure and pathogenesis of intracranial arachnoid cysts. *J Neuropathol Exp Neurol*. 1981; 40(1): 61-83. doi: [10.1097/00005072-198140010-00007](https://doi.org/10.1097/00005072-198140010-00007)
14. Go KG, Houthoff HJ, Blaauw EH, Stokroos I, Blaauw G. Morphology and origin of arachnoid cysts. Scanning and transmission electron microscopy of three cases. *Acta Neuropathol*. 1978; 44(1): 57-62. doi: [10.1007/BF00691640](https://doi.org/10.1007/BF00691640)
15. Harenberg C, Helms J. Arachnoid cysts in the internal ear canal and facial canal (Fallopian). *Laryngol Rhinol Otol (Stuttg)*. 1986; 65(2): 83-85. Web site: <http://europepmc.org/abstract/med/3959691> Accessed August 21, 2016.
16. Takano S, Maruno T, Shirai S, Nose T. Facial spasm and paroxysmal tinnitus associated with an arachnoid cyst of the cerebellopontine angle--case report. *Neurol Med Chir (Tokyo)*. 1998; 38(2): 100-103. doi: [10.2176/nmc.38.100](https://doi.org/10.2176/nmc.38.100)
17. Aubry K, Wassef M, Guichard JP, Herman P, Tran Ba Huy P. Association of an arachnoid cyst with heterotopic neuroglial tis-

- sue in the internal auditory canal. *Ann Otolaryngol Chir Cervicofac.* 2009; 126(3): 133-137. doi: [10.1016/j.aorl.2009.03.001](https://doi.org/10.1016/j.aorl.2009.03.001)
18. Mastronardi L, Taniguchi R, Caroli M, Crispo F, Ferrante L, Fukushima T. Cerebellopontine angle arachnoid cyst: A case of hemifacial spasm caused by an organic lesion other than neurovascular compression: Case report. *Neurosurgery.* 2009; 65(6): E1205. doi: [10.1227/01.NEU.0000360155.18123.D1](https://doi.org/10.1227/01.NEU.0000360155.18123.D1)
19. Fleck SK, Baldauf J, Langner S, Vogelgesang S, Schroeder S, Werner H. Arachnoid cyst confined to the internal auditory canal-endoscope-assisted resection: Case report and review of the literature. *Neurosurgery.* 2011; 68(1): E267-E270. doi: [10.1227/NEU.0b013e3181ff1fb7](https://doi.org/10.1227/NEU.0b013e3181ff1fb7)
20. Erkok MF, Imamoglu H, Okur A, Gumus C, Dogan M. Normative size evaluation of internal auditory canal with magnetic resonance imaging: Review of 3786 patients. *Folia Morphol (Warsz).* 2012; 71(4): 217-220.
21. Dähnert W. *Radiology Review Manual.* Philadelphia, PA, USA: Lippincott Williams & Wilkins; 2003.
22. Morantz RA, Walsh JW. *Brain Tumors: A Comprehensive Text.* Zug, Switzerland: Informa HealthCare; 1994.
23. Mulkens TH, Parizel PM, Martin JJ, et al. Acoustic schwannoma: MR findings in 84 tumors. *AJR Am J Roentgenol.* 1993; 160(2): 395-398. doi: [10.2214/ajr.160.2.8424360](https://doi.org/10.2214/ajr.160.2.8424360)
24. Tali ET, Yuh WT, Nguyen HD, et al. Cystic acoustic schwannomas: MR characteristics. *AJNR Am J Neuroradiol.* 1993; 14(5): 1241-1247. Web site. <http://www.ajnr.org/content/14/5/1241.short>. Accessed August 21, 2016.
25. Duan H, Kitazawa K, Yako T, Ichinose S, Kobayashi S, Sudo M. Gliosarcoma in the cerebellopontine angle with rapid tumor growth and intratumoral hemorrhage. *World Neurosurg.* 2016; 92: e17-e21. doi: [10.1016/j.wneu.2016.06.053](https://doi.org/10.1016/j.wneu.2016.06.053)
26. Ben Nsir A, Badri M, Kassar AZ, Hammouda KB, Jemel H. Hemangiopericytoma of the cerebellopontine angle: A wolf in Sheep's clothing. *Brain Tumor Res Treat.* 2016; 4(1): 8-12. doi: [10.14791/btrt.2016.4.1.8](https://doi.org/10.14791/btrt.2016.4.1.8)
27. Hooten KG, Oliveria SF, Sadrameli SS, Gandhi S, Yachnis AT, Lewis SB. Bilateral internal auditory canal gangliogliomas mimicking neurofibromatosis Type II. *Surg Neurol Int.* 2016; 7: 39. doi: [10.4103/2152-7806.180300](https://doi.org/10.4103/2152-7806.180300)
28. Bigelow DC, Eisen MD, Smith PG, et al. Lipomas of the internal auditory canal and cerebellopontine angle. *Laryngoscope.* 1998; 108(10): 1459-1469. doi: [10.1097/00005537-199810000-00008](https://doi.org/10.1097/00005537-199810000-00008)
29. Reimann K, Arnold H, Bisdas S, et al. Cavernous angio-myoma of the internal auditory canal. *Otol Neurotol.* 2015. doi: [10.1097/MAO.0000000000000094](https://doi.org/10.1097/MAO.0000000000000094)
30. Lavinsky J, Aaron KA, Christian E, et al. Solitary Plasmacytoma in the Internal Auditory Canal and Cerebellopontine Angle Mimicking Meningioma. *Otol Neurotol.* 2015. doi: [10.1097/MAO.0000000000000859](https://doi.org/10.1097/MAO.0000000000000859)
31. Jada AS, Shrivastava RK, Mannan A, Kobets A, Manolidis S. Rare Presentation of Giant Cell Tumor in the Internal Auditory Canal: Case Report and Review of the Literature. *J Neurol Surg Rep.* 2015; 76(1): e65-e71. doi: [10.1055/s-0034-1396656](https://doi.org/10.1055/s-0034-1396656)
32. Yamaguchi T, Oka H, Kijima C, Sano H, Watanabe H, Okamoto M. A case of atypical teratoid/rhabdoid tumor in the internal auditory canal. *Auris Nasus Larynx.* 2015; 42(2): 163-166. doi: [10.1016/j.anl.2014.09.005](https://doi.org/10.1016/j.anl.2014.09.005)
33. Kitavi W, Hamberger U, Sudhoff H. Perineural spread of salivary duct carcinoma to the internal auditory canal. *Case Rep Otolaryngol.* 2014; 2014: 476317. doi: [10.1155/2014/476317](https://doi.org/10.1155/2014/476317)
34. Lalwani AK, Jackler RK. Preoperative differentiation between meningioma of the cerebellopontine angle and acoustic neuroma using MRI. *Otolaryngol Head Neck Surg.* 1993; 109(1): 88-95.
35. Spatola G, Carron R, Delsanti C, Thomassin JM, Roche PH, Régis J. Long-term results of Gamma-knife stereotactic radiosurgery for vestibular schwannomas in patients with type 2 neurofibromatosis. *Neurochirurgie.* 2016; pii: S0028-3770(16)30065-0. doi: [10.1016/j.neuchi.2016.03.005](https://doi.org/10.1016/j.neuchi.2016.03.005)
36. Gao K, Ma H, Cui Y, Chen X, Ma J, Dai J. Meningiomas of the cerebellopontine angle: Radiological differences in tumors with internal auditory canal involvement and their influence on surgical outcome. *PLoS One.* 2015; 10(4): e0122949. doi: [10.1371/journal.pone.0122949](https://doi.org/10.1371/journal.pone.0122949)
37. Aihara N, Murakami S. Enlargement of the Internal Auditory Canal and Hearing Preservation in the Middle Fossa Approach for Intracanalicular Vestibular Schwannomas. *World Neurosurg.* 2015; 84(6): 1950-1955. doi: [10.1016/j.wneu.2015.08.041](https://doi.org/10.1016/j.wneu.2015.08.041)
38. Leal AG, Silva EB Jr, Ramina R. Surgical exposure of the internal auditory canal through the retrosigmoid approach with semicircular canals anatomical preservation. *Arq Neuropsiquiatr.* 2015; 73(5): 425-430. doi: [10.1590/0004-282X20150020](https://doi.org/10.1590/0004-282X20150020)
39. Marchioni D, Carner M, Rubini A, et al. The fully endoscopic acoustic neuroma surgery. *Otolaryngol Clin North Am.* 2016; 49(5): 1227-1236. doi: [10.1016/j.otc.2016.05.014](https://doi.org/10.1016/j.otc.2016.05.014)
40. Herdman SJ, Clendaniel RA, Mattox DE, Holliday MJ,

- Niparko JK. Vestibular adaptation exercises and recovery: Acute stage after acoustic neuroma resection. *Otolaryngol Head Neck Surg.* 1995; 113(1):77-87. doi: [10.1016/S0194-5998\(95\)70148-6](https://doi.org/10.1016/S0194-5998(95)70148-6)
41. Barbara M, Monini S, Buffoni A, et al. Early rehabilitation of facial nerve deficit after acoustic neuroma surgery. *Acta Otolaryngol.* 2003; 123(8): 932-935. doi: [10.1080/00016480310000629](https://doi.org/10.1080/00016480310000629)
42. Di Stadio A. Eyelid lifting for ectropion and scleral show in facial palsy disease. *ORL J Otorhinolaryngol Relat Spec.* 2014; 76(6): 329-335. doi: [10.1159/000369623](https://doi.org/10.1159/000369623)
43. Biglioli F, Colombo V, Rabbiosi D, et al. Masseteric-facial nerve neurotomy: Results of a case series. *J Neurosurg.* 2016; 1: 1-7. doi: [10.3171/2015.12.JNS14601](https://doi.org/10.3171/2015.12.JNS14601)
44. Kochhar A, Albathi M, Sharon JD, Ishii LE, Byrne P, Boahene KD. Transposition of the Intratemporal Facial to Hypoglossal Nerve for Reanimation of the Paralyzed Face: The VII to XII Transposition Technique. *JAMA Facial Plast Surg.* 2016; 18(5): 370-378. doi: [10.1001/jamafacial.2016.0514](https://doi.org/10.1001/jamafacial.2016.0514)
45. Aljudaibi N, Bennis Y, Duquennoy-Martinot V, Labbé D, Guerreschi P. Lengthening temporalis myoplasty: Virtual animation-assisted technical video. *Plast Reconstr Surg.* 2016; 138(3): 506e-509e. doi: [10.1097/PRS.0000000000002512](https://doi.org/10.1097/PRS.0000000000002512)
46. Bouček J, Vokřál J, Černý L, et al. Baha implant as a hearing solution for single-sided deafness after retrosigmoid approach for the vestibular schwannoma: Audiological results. *Eur Arch Otorhinolaryngol.* 2016; 1-9. doi: [10.1007/s00405-016-4261-5](https://doi.org/10.1007/s00405-016-4261-5)