

Case Report

Corresponding author

Matteo Bertini, MD, PhD
Department of Cardiology
S. Anna Hospital
University of Ferrara
Via Aldo Moro 8
Cona-Ferrara 44124, Italy
Tel. +39 532 236269
Fax: +39 532 236593
E-mail: doc.matber@gmail.com

Volume 2 : Issue 5

Article Ref. #: 1000HROJ2123

Article History

Received: November 9th, 2015

Accepted: November 23rd, 2015

Published: November 25th, 2015

Citation

Leonetti E, Malagù M, Bertini M. An emergent echo-guided apical pericardiocentesis for cardiac tamponade in a patient with only the left lung. *Heart Res Open J.* 2015; 2(5): 131-133. doi: [10.17140/HROJ-2-123](https://doi.org/10.17140/HROJ-2-123)

Copyright

©2015 Bertini M. This is an open access article distributed under the Creative Commons Attribution 4.0 International License (CC BY 4.0), which permits unrestricted use, distribution, and reproduction in any medium, provided the original work is properly cited.

An Emergent Echo-Guided Apical Pericardiocentesis for Cardiac Tamponade in a Patient with only the Left Lung

Emanuela Leonetti, Michele Malagù and Matteo Bertini*

Department of Cardiology, S. Anna Hospital, University of Ferrara, Cona-Ferrara, Italy

ABSTRACT

A 74 years old man with previous right pneumonectomy was admitted with cardiac tamponade. Pericardiocentesis was attempted through sub-xiphoid approach but was not feasible. Therefore, second echo-guided pericardiocentesis was performed by apical approach with success. We present our experience of apical pericardiocentesis in a patient with only the left lung.

KEYWORDS: Cardiac tamponade; Pericardiocentesis; Apical approach.

INTRODUCTION

Pericardiocentesis is an emergent life-saving procedure in patients with cardiac tamponade. Pericardiocentesis is generally safe, but may lead to complications (perforation of the heart, artery, lung or liver). The failure of the procedure may evolve in patient death. Preferred approach for pericardiocentesis is sub-xiphoid but other approaches may be required.

CASE REPORT

A 74 years old man came to the emergency department complaining of severe dyspnea and reduced exercise tolerance. The patient reported no significant cardiovascular history but a history of lung cancer treated with right pneumonectomy, followed by local radiotherapy, which required an oesophagus endoprosthesis implantation due to post-radiation stenosis.

On physical examination, his blood pressure was 90/70 mm Hg, heart rate 130 beats per minute. There was elevated jugular venous pressure, peripheral oedema and pulsus paradoxus. The electrocardiogram showed sinus tachycardia with low voltage and a thoracic Computed Tomography (CT) revealed severe pericardial effusion (Figure 1). Because of this, the patient was immediately admitted to our Intensive Care Unit (ICU). A bedside echocardiogram confirmed the large pericardial effusion and a right atrium diastolic collapse. The poor quality sub-xiphoid pericardial window did not allow the visualization of a pericardial sack, which was detected by parasternal and apical views (Figure 1).

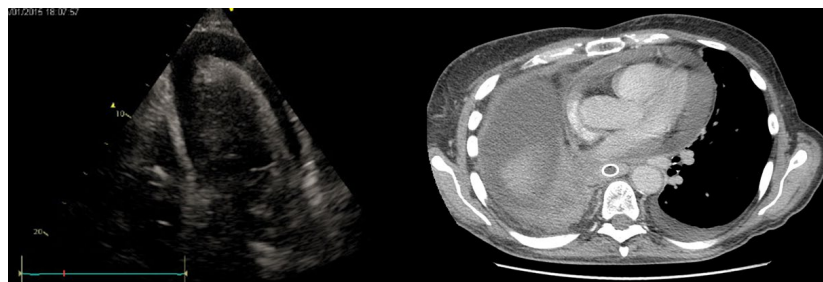


Figure 1: Echocardiogram and thoracic CT showing massive pericardial effusion.

A sub-xiphoid pericardiocentesis was attempted without success. In view of the severe clinical instability of the patient, a second echo-guided pericardiocentesis was performed, this time by the apical approach (Figure 2). Cardiac apex was identified with palpation and echocardiogram in fifth intercostal space between emiclavicular line and anterior axillary line. The needle tip was evident on echocardiographic images acquired through parasternal view through injection of agitated saline, and images were used to identify the optimal point to penetrate the pericardium and safely drainage the effusion. This maneuver was successful and 400 ml of blood-serum fluid were aspirated resulting in immediate improvement in symptoms, increase of blood pressure (110/80 mm Hg) and reduction of heart rate (90 bpm). The echocardiogram showed complete resolution of pericardial effusion (Figure 3). Finally, chest radiograph confirmed absence of pneumothorax or lung injury (Figure 2). Cytological examination of pericardial fluid showed reactive blood cells. The patient left the hospital 5 days later in good clinical condition and has been doing well since.

DISCUSSION

Cardiac tamponade is a life-threatening condition. Consequently, percutaneous pericardiocentesis is a life-saving

therapy. Echo-guided pericardiocentesis, performed *via* sub-xiphoid, apical or parasternal approach, has smaller risk of major complication than blind pericardiocentesis.¹⁻³ The sub-xiphoid approach is considered the safest.^{2,3} In our patient this approach was attempted but was not feasible, probably because of the anatomy and the fibrosis due to both previous radiation exposure and the recent surgery. In this particular case, the apical approach was a very high-risk procedure in view of the previous right pneumonectomy and the risk of left pneumothorax, which could be life-threatening in a patient with only the left lung. However, the instability of the patient and the distribution of pericardial effusion in the apical region encouraged us to take the risk to perform this maneuver by the apical approach through echocardiographic guidance. Luckily, the procedure was successful and we obtained a rapid improvement of the clinical condition without complications. We did not consider the parasternal approach because of the risk of pneumothorax and of puncturing the internal thoracic artery.

To our knowledge this is the first report of pericardiocentesis through apical approach in a patient with only the left lung. Our case suggests that in emergency condition pericardiocentesis *via* apical approach with ultrasound guidance may be considered despite its high intrinsic risk. In order to avoid pur-

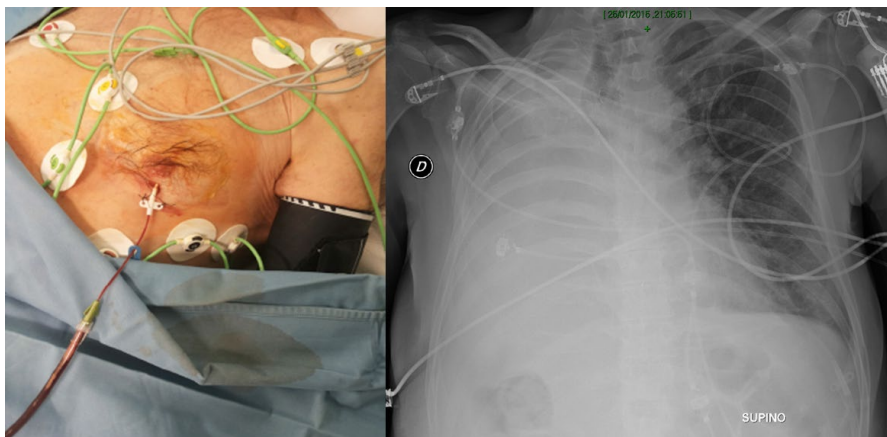


Figure 2: Pericardiocentesis apical approach.

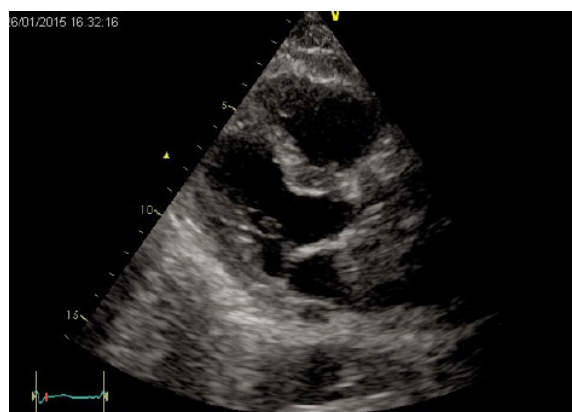


Figure 3: Repeat echocardiogram showing resolution of pericardial effusion.

suing the sub-xiphoid approach if this is not immediate, clinicians can consider the apical approach that may be successful in particular under ultrasound guidance. In absence of previous description of such cases in literature, this report may be useful to clinicians for the management of patients in similar situations.

CONFLICTS OF INTEREST

The authors declare that they have no conflicts of interest.

ACKNOWLEDGMENTS

This work was supported by a grant from Fondazione Anna Maria Sechi per il Cuore (FASC), Italy. The funders had no role in the study design, data collection and analysis, decision to publish or the preparation of the manuscript.

CONSENT

No consent is required for the publication of this case report.

REFERENCES

1. Callahan JA, Seward JB, Nishimura RA, et al. Two-dimensional echocardiographically guided pericardiocentesis: experience in 117 consecutive patients. *Am J Cardiol.* 1985; 55: 476-479. doi: [10.1016/0002-9149\(85\)90397-2](https://doi.org/10.1016/0002-9149(85)90397-2)
2. Spodick DH. Acute cardiac tamponade. *New Engl J Med.* 2003; 349: 684-690. doi: [10.1056/NEJMra022643](https://doi.org/10.1056/NEJMra022643)
3. Fitch MT, Nicks BA, Pariyadath M, et al. Emergency pericardiocentesis. *New Engl J Med.* 2012; 366: e17. doi: [10.1056/NEJMvc0907841](https://doi.org/10.1056/NEJMvc0907841)