

## Case Report

### \*Corresponding author

Justin Zelones, MD

Surgeon

Department of Surgery

University of California San Diego

200 West Arbor Drive, San Diego

CA 92103-0739, USA

E-mail: [zelones@AD.UCSD.EDU](mailto:zelones@AD.UCSD.EDU)

Volume 2 : Issue 1

Article Ref. #: 1000SROJ2106

### Article History

Received: January 28<sup>th</sup>, 2015

Accepted: February 27<sup>th</sup>, 2015

Published: February 27<sup>th</sup>, 2015

### Citation

Zelones J, Sood D, Ramamoorthy SL. Transverse colon perforation in a patient with primary systemic amyloidosis associated with multiple myeloma. *Surg Res Open J.* 2015; 2(1): 32-35. doi: [10.17140/SROJ-2-106](https://doi.org/10.17140/SROJ-2-106)

### Copyright

©2015 Zelones J. This is an open access article distributed under the Creative Commons Attribution 4.0 International License (CC BY 4.0), which permits unrestricted use, distribution, and reproduction in any medium, provided the original work is properly cited.

# Transverse Colon Perforation in a Patient with Primary Systemic Amyloidosis Associated with Multiple Myeloma

Justin Zelones\*, Divya Sood and Sonia L. Ramamoorthy

Department of Surgery, University of California San Diego, 200 West Arbor Drive, San Diego, CA 92103-0739, USA

### ABSTRACT

Amyloidosis is caused by extracellular deposits of amyloid by plasma cells, which can be idiopathic, occur with chronic inflammatory conditions, familial, or be associated with Multiple Myeloma. The Gastrointestinal tract can be affected by amyloidosis and can lead to colonic perforation, which is a rare cause of Gastrointestinal perforation as there are only nine cases documented in the literature. The aim of this case report is to describe a patient presenting with a colon perforation secondary to amyloidosis associated with Multiple Myeloma. A 66 year old male presented with diffuse abdominal pain, distention, and obstipation. Imaging demonstrated free air so he was taken to the operating room for a subtotal colectomy and end ileostomy for a transverse colon perforation. Pathology was consistent with amyloidosis in the colon. Further workup revealed that he had multiple organ systems affected by amyloid deposits along with Multiple Myeloma. Given his cardiac involvement by amyloidosis he succumbed to the disease four weeks after diagnosis. In the setting of bowel perforation and multi-organ failure of unknown etiology it is important to keep protein deposition diseases such as amyloidosis in the differential diagnosis.

**KEYWORDS:** Colonic perforation; Primary amyloidosis; Multiple myeloma; Infiltrative cardiomyopathy.

**ABBREVIATIONS:** Multiple Myeloma (MM); Gastrointestinal (GI); Pulseless Electrical Activity (PEA); Difference between involved and uninvolved Free Light Chains (FLC-diff); Troponin-T (TnT); Pro-B-type Natriuretic Peptide (ProBNP).

### INTRODUCTION

Amyloidosis involves extracellular deposits of amyloid produced by plasma cells and can be localized or systemic. It can be idiopathic (primary), occur with chronic inflammatory states (secondary), familial, or be associated with Multiple Myeloma (MM). The deposition of amyloid usually occurs in blood vessel walls and the mucosa/muscularis of the Gastrointestinal (GI) tract, which can lead to ischemia and ultimately perforation.<sup>1</sup> Primary Amyloidosis is a rare cause of intestinal perforation. A review of the literature documents approximately nine colonic perforations secondary to amyloidosis (Table 1), of which four were primary amyloidosis,<sup>2-5</sup> four were Secondary Amyloidosis associated with ankylosing spondylitis,<sup>6-9</sup> and one case was associated with Multiple Myeloma.<sup>10</sup> The purpose of this case report is to describe a patient presenting with a transverse colon perforation who was found to have primary systemic amyloidosis associated with Multiple Myeloma. His post-operative course was significant for complications of several organ systems and ultimately PEA arrest. There are no cases in the literature of a patient with a colonic perforation that is diagnosed with systemic amyloidosis associated with

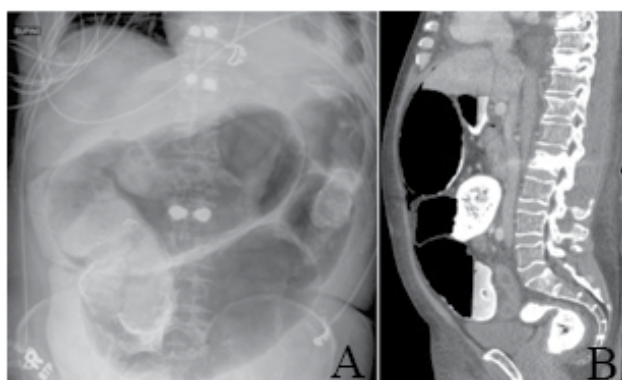
Case Report	Age Gender	Amyloidosis Type	Perforation Site
Deharo et al, 1988 <sup>2</sup>	Unknown	Primary	Colon
Shinozaki et al, 1989 <sup>3</sup>	Unknown	Primary	Sigmoid
Thaler et al, 1999 <sup>4</sup>	58 M	Primary	Sigmoid
Parks et al, 2002 <sup>5</sup>	88 M	Primary	Sigmoid
Gonzalaez-Sanchez et al, 1989 <sup>6</sup>	Unknown	Secondary (AS)	Colon
Gonzalez-Gay et al, 1994 <sup>7</sup>	Unknown	Secondary (AS)	Colon
Gonzalez-Gay et al, 2000 <sup>8</sup>	Unknown	Secondary (AS)	Colon
Kovacsovics-Bannkowski et al, 2000 <sup>9</sup>	Unknown	Secondary (AS)	Colon
Harada et al, 2014 <sup>10</sup>	75 F	Multiple Myeloma	Sigmoid

**Table 1:** Characteristics of 9 cases of colonic perforation secondary to amyloidosis identified on review of the literature. [Abbreviations: AS – Ankylosing Spondylitis].

Multiple Myeloma involving the heart, lungs, small/large bowel, liver, and bone marrow followed by death within four weeks of diagnosis. In a patient presenting with an intestinal perforation, protein deposition diseases such as amyloidosis should be kept in the differential diagnosis.

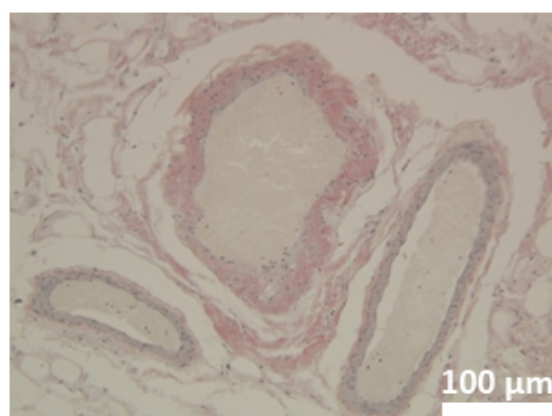
**CASE REPORT**

The patient is a 66 year old male with history of anaemia, atrial fibrillation, hypertension, and compression fractures status post kyphoplasty two weeks prior to admission. The patient presented to the emergency department with diffuse abdominal pain, distention, and obstipation. He was afebrile with normal vital signs. His physical exam was notable for diffuse tenderness to palpation and distention. Labs were significant for a normal white blood count, anaemia, coagulopathy, and malnutrition. An abdominal XR (Figure 1A) and CT abdomen/pelvis (Figure 1B) showed a distended cecum to transverse colon, free air, and bilateral pleural effusions.



**Figure 1:** (A) Abdominal XR and (B) CT abdomen/pelvis showing dilated cecum to transverse colon, moderate free air, bilateral pleural effusions, and T8/T10/L2 kyphoplasties.

from the cecum to the splenic flexure were dilated and ischemic with a perforation present in the transverse colon. During his hospitalization he had bradycardia with a junctional rhythm and a troponin of 0.06 ng/dL. Cardiac echo demonstrated thickened valves, atria and ventricles, right ventricular hypertrophy, and preserved diastolic function consistent with an infiltrative cardiomyopathy. The patient developed progressive oliguria and a diuretic was started to help maintain euolemia. He gradually improved and was discharged two weeks after his operation in stable condition. After discharge, the pathology revealed a 2 mm perforation in the transverse colon, ischemic colitis, and extensive amyloidosis present in the colon, ileum, omentum, and colonic perforation site. Amyloidosis was confirmed by Congo red staining (Figure 2).



**Figure 2:** Congo red staining (magnification × 20) showing amyloid deposition in blood vessel walls and around adipocytes within the colon. Bar scale represents 100 μm.

The patient underwent an exploratory laparotomy, subtotal colectomy, end ileostomy, and mucous fistula. The colon

Three days after discharge the patient was readmitted for conservative management of an ileus. His vital signs and labs were stable. The Hematology/Oncology team diagnosed the patient with primary amyloidosis associated with Multiple Myeloma after a bone marrow biopsy, which showed a kappa

expression plasma cell dyscrasia in a hypercellular marrow with focal amyloid deposit. Therapy was initiated in hospital with Cyclophosphamide, Bortezomib, and Dexamethasone (Cy-BorD). Despite aggressive treatment the patient was found to have a myriad of other amyloid related organ abnormalities. Coagulopathy with a heterogeneous liver on imaging, indicating hepatic amyloidosis. Nephrotic syndrome with progressive proteinuria, anasarca, hypoalbuminemia, and oliguria. Arrhythmias with congestive heart failure from infiltrative cardiomyopathy. Shortly after starting Chemotherapy the patient went into PEA, was made DNR, and expired four weeks post-operatively. The autopsy report reported amyloid deposition in the heart, lungs, small/large bowel, liver, and bone marrow along with concentric hypertrophy of the heart, cardiomegaly, bilateral pleural effusions, chronic passive congestion of the liver, hepatic steatosis, splenic congestion, acute tubular necrosis, bilateral adrenal necrosis, and testicular atrophy. The bone marrow revealed hyaline deposition, 40% plasma cells (lambda predominant), positive CD 19/20 in <1% of cells, and positive CD3 small T cells. The cause of death was heart failure secondary to primary amyloidosis, associated with Plasma cell dyscrasia.

## DISCUSSION

Perforation of the colon is rarely secondary to protein deposition diseases such as amyloidosis. There are approximately 20 known cases of GI perforation due to amyloidosis documented in the literature with only nine of these involving the large bowel. Most patients with primary amyloidosis are not diagnosed until after secondary organ injury has occurred, as was the case with our patient. Treatment of amyloidosis includes combinations of stem-cell transplant, dexamethasone, and chemotherapy depending on the risk stratification of the patient.<sup>1</sup> It is important to be able to predict the prognosis of a patient with systemic amyloidosis so that they can receive the appropriate therapy. Given that amyloidosis with cardiac involvement has a poorer prognosis than other organ involvement, a revised prognostic staging system for primary systemic amyloidosis was created based on the Difference between involved and uninvolved Free Light Chains (FLC-diff), Troponin-T (TnT), and Pro-B-type Natriuretic Peptide (ProBNP).<sup>1</sup> Patients were given one point for each if FLC-diff  $\geq$  180 mg/L, TnT  $\geq$  0.025 ng/dL, and ProBNP  $\geq$  1,800 pg/mL. The median overall survival for stages I through IV were 94, 40, 14, and 5.8 months respectively.<sup>1</sup> Our patient had a FLC-diff of 400 mg/L, TnT of 0.06 ng/dL, and ProBNP of 6064 pg/mL, thus classifying him as stage IV for primary systemic amyloidosis. Our patient presented with a transverse colon perforation, underwent a subtotal colectomy, and had a post-operative course that was complicated by cardiac, pulmonary, hepatic, and GI events secondary to amyloid deposits ultimately leading to death. It is important to consider protein deposition diseases such as primary amyloidosis in patients with bowel perforation and multi-organ failure of unknown etiology. Cardiac involvement portends a poor prognosis and treatment

strategies should be initiated as soon as possible.

## ACKNOWLEDGMENTS

The authors would like to thank the University of California, San Diego for allowing us the opportunity to take care of their patients. No financial support was obtained for this work.

**CONFLICT OF INTEREST:** None

## REFERENCES

1. Kumar S, Dispenzieri A, Lacy M, et al. Revised Prognostic Staging System for Light Chain Amyloidosis Incorporation Cardiac Biomarkers and Serum Free Light Chain Measurements. *J Clin Onc.* 2012; 30(9): 989-995. doi: [10.1200/JCO.2011.38.5724](https://doi.org/10.1200/JCO.2011.38.5724)
2. Deharo S, Petit J, Testart J, Lemoine F, Hannequin D, Oksenhendler G. Colonic perforation disclosing primary amyloidosis. *Ann Med Interne.* 1988; 139(4): 280-281.
3. Shinozaki S, Hongo M, Hirai K, et al. Perforation of sigmoid colon in primary amyloidosis: report of a case. *Nihon Naika Gakkai Zasshi.* 1989; 78(11): 1603-1604.
4. Thaler W, Schatzer G, Eder P, Fichtel G. Amyloidosis-an unusual case of recurrent intestinal bleeding and sigmoid perforation: case report with review of the literature. *Int J Colorectal Dis.* 1999; 14(6): 297-299.
5. Parks RW, O'Rourke D, Bharucha H, Wilson BG. Perforation of the sigmoid colon secondary to localized amyloidosis. *Ulster Med J.* 2002; 71(2): 144-146.
6. Gonzalaez-Sanchez JA, Martin Molinero R, Dominquez Sayans J, Jimenez Sanchez F. Colonic perforation by amyloidosis. Report of a case. *Dis Colon Rectum.* 1989; 32(5): 437-440. doi: [10.1007/BF02563700](https://doi.org/10.1007/BF02563700)
7. Gonzalez-Gay MR, Alonso MD, Bal M, et al. Colonic perforation in a patient with amyloidosis and ankylosing spondylitis. *J Rheumatol.* 1994; 21(2): 376-377. doi: [10.1007/BF02563700](https://doi.org/10.1007/BF02563700)
8. Gonzalez-Gay MA, Garcia-Porrua C, Rivas MJ, Ramos-Gudino B. Secondary amyloidosis and colonic perforation in ankylosing spondylitis. *Joint Bone Spine.* 2000; 67(5): 492.
9. Kovacsovics-Bankowski M, Zufferey P, So AK, Gerster JC. Secondary amyloidosis: a severe complication of ankylosing spondylitis. Two case-reports. *Joint Bone Spine.* 2000; 67(2): 129-133.
10. Harada K, Ichikawa D, Konishi H, et al. Perforation of the

sigmoid colon and massive ischemia of the small intestine caused by amyloidosis with multiple myeloma: a case report. *Int Surg.* 2014; 99(6): 685-690. doi: [10.9738/INTSURG-D-14-00058.1](https://doi.org/10.9738/INTSURG-D-14-00058.1)