Openventio PUBLISHERS

ISSN 2470-4059

OTOLARYNGOLOGY

Open Journal

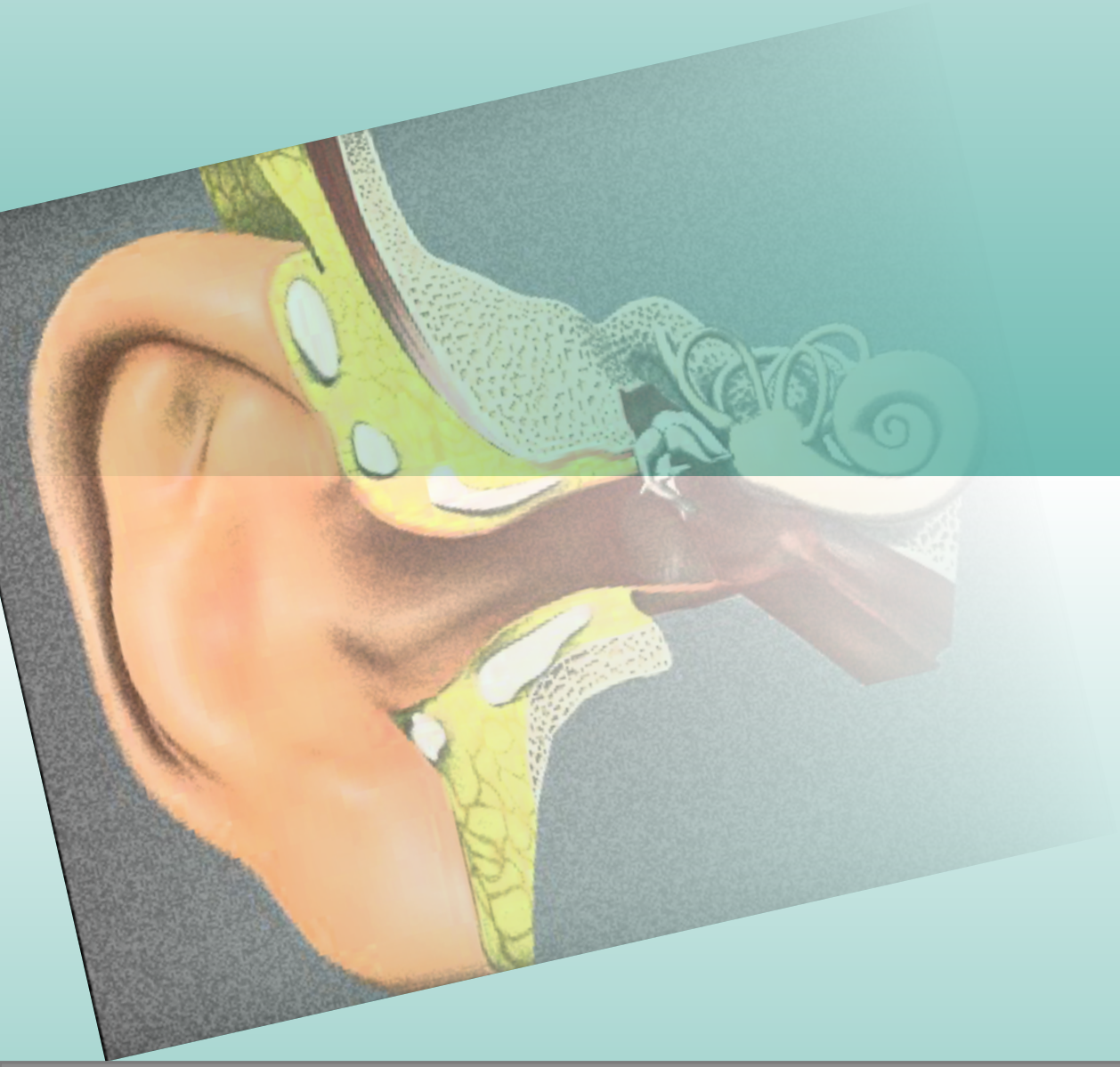

| October 2016 | Volume 2 | Issue 5 |

www.openventio.org

OTOLARYNGOLOGY

Openventio PUBLISHERS

ISSN 2470-4059

Open Journal

TABLE OF CONTENTS

OTOLARYNGOLOGY

Openventio PUBLISHERS

ISSN 2470-4059 Open Journal http://dx.doi.org/10.17140/OTLOJ-2-127

Research

*Corresponding author
Mustafa Çelik, MD
Department of Otorhinolaryngology Head and Neck Surgery
Bakırköy Dr. Sadi Konuk Eğitim ve Araştırma Hastane
Zuhuratbaba Mah. Tevfik Sağlam Cad. No: 11, Bakırköy, Istanbul, Türkey
Tel. 090 (212) 4147282
E-mail: dr.mcelik@yahoo.com

Volume 2 : Issue 5
Article Ref. #: 1000OTLOJ2127

Article History
Received: September 9th, 2016
Accepted: September 15th, 2016
Published: September 19th, 2016

Citation
Yegin Y, Çelik M, Şimşek BM, Olgun B, Kayhan FT. The relationship between tonsillar size and neutrophil-to-lymphocyte ratio in children with recurrent tonsillitis. *Otolaryngol Open J*. 2016; 2(5): 120-124. doi: 10.17140/OTLOJ-2-127

The Relationship Between Tonsillar Size and Neutrophil-to-Lymphocyte Ratio in Children With Recurrent Tonsillitis

Yakup Yegin, MD; Mustafa Çelik, MD*; Baver Maşallah Şimşek, MD; Burak Olgun, MD; Fatma Tülin Kayhan, MD

Department of Otorhinolaryngology-Head and Neck Surgery, Bakırköy Dr. Sadi Konuk Training and Research Hospital, Istanbul, Turkey

ABSTRACT

Objectives: To explore the relationships between tonsillar sizes and neutrophil-to-lymphocyte ratio (NLR) values in children with recurrent tonsillitis.
Subjects and Methods: In total, 236 children (128 males, 108 females; average age 11.80±9.16 years; range, 4-18 years) who underwent tonsillectomy with a diagnosis of recurrent tonsillitis were included. The patients were divided into four groups according to the tonsillar sizes. Group A was consist of 56 children with grade 1 tonsil size, while group B, C and D was consist of 58, 70 and 52 children with grade 2, 3 and 4 tonsil size, respectively. Pre-operative NLR values of all groups were compared with measurements in the post-operative third month.
Results: In group A, pre-operative NLR levels were 1.76±0.92, while post-operative NLR were 1.74±1.53. No statistically significant difference in NLR values was observed between pre- and post-operatively in group A (p=0.864). In group B, pre-operative NLR levels were 1.56±1.14, while post-operative NLR were 1.29±0.65. In group C, pre-operative NLR levels were 1.48±1.47, while post-operative NLR were 1.22±0.79. In group D, pre-operative NLR levels were 1.44±1.52, while post-operative NLR were 1.19±0.96. Post-operative NLR values were significantly lower than pre-operative NLR values in both groups B, C, D (p=0.012, p=0.036, p=0.043, respectively).
Conclusion: The larger tonsils affect the NLR levels and larger tonsils are strongly suspected to contribute to higher systemic inflammations. However, higher systemic inflammations can be prevented by tonsillectomy.

KEYWORDS: Tonsillar sizes; Neutrophil-to-lymphocyte; Recurrent tonsillitis.

ABBREVIATIONS: NLR: Neutrophil-to-lymphocyte ratio; OSAS: Obstructive Sleep Apnea Syndrome; IEC: Institutional Ethics Committee; EDTA: Ethylene-diamine-tetracetic acid.

INTRODUCTION

Acute tonsillitis is usually diagnosed by clinical acute inflammatory manifestations such as hyperemic tonsils, exudation, and ulceration.[1,2] Approximately 5 to 17% of cases are bacteriological which is mostly group A beta-hemolytic streptococci, although the most common etiological agent is viral.[3] As previously described by Paradise, recurrent tonsillitis is defined as seven episodes within one year or five episodes in the preceding two years and more or three episodes in the preceding three years and more.[4] Many factors are blamed for the development of recurrent tonsillitis. These include patient incompliance, premature cessation of antibiotherapy, inadequate antibiotic absorbance, bacterial tolerance, bacterial load, bacterial biofilms, and immune system deficiencies.[2,3]

The most common indications of tonsillectomy or adenotonsillectomy are obstructive sleep apnea syndrome (OSAS) due to adenotonsillar hypertrophy, followed by recurrent

ISSN 2470-4059 Open Journal http://dx.doi.org/10.17140/OTLOJ-2-127

tonsillitis.[5-10] Large tonsils obstruct the upper airway and it is associated with symptoms of upper airway obstruction including mouth breathing, snoring, sleep apnea, coughing at night, and production of hyponasal sounds as well as sinusitis and recurrent otitis media.[8-11] Poor quality sleep and sleep-related hypoxia have been previously described in children with recurrent tonsillitis. Capper and Canter[9] reported that children awaiting tonsillectomy have poorer sleep quality than their normal peers. However, there is no dose-response effect between deteriorating sleep quality and increasing frequency of tonsillitis.[9] Recurrent infections lead to some changes in hematological parameters. Recently, neutrophil-to-lymphocyte ratio (NLR) was explored in some diseases such as vestibular neuronitis, Bell's palsy, sudden hearing loss, OSAS in the field of otorhinolaryngology.[12-18] Neutrophils are essential for cytokine production in acute process in inflammatory disorders while lymphocyte is important for cytokine production in chronic process in inflammatory disorders.[19] Also, higher neutrophils demonstrate an acute inflammation and lower lymphocytes demonstrate deficiency of some elements in body and chronic inflammatory status. NLR is propounded as a parameter of systemic inflammation.[5-7] NLR can be easily determined by a simple complete blood count analysis and is a valuable parameter in diseases such as sudden hearing loss, certain some cancers, autoimmune and cardiovascular diseases.[6-14] Only a few studies have explored the relationship between NLR levels and recurrent tonsillitis. To the best of our knowledge, no study has yet focused on associations between tonsillar sizes and NLR values. We address this topic in the present study. In the present study, the relationships between tonsillar sizes and NLR values in children with recurrent tonsillitis were explored.

MATERIALS AND METHODS

We retrospectively reviewed data collected from January 2009 to September 2012 on patients treated in the Department of Otolaryngology, Head-and-Neck Surgery, of our hospital. In total, 236 children who underwent tonsillectomy with a diagnosis of recurrent tonsillitis were included in the study. Patients with previous history of adenotonsillectomy, genetic syndromes, congenital malformations, cleft palate, nasal septal deviation, sinonasal infection, chronic diseases, hematological diseases were excluded from the study. All parents of the patients were informed about the study and a written consent was obtained from each parents of the patients. The study protocol was approved by the Institutional Ethics Committee (IEC). The study was conducted in accordance with the principles of Helsinki declaration. All patients were followed for at least 1 year and the total number of acute tonsillitis episodes was recorded. Recurrent tonsillitis that previously described by Paradise,[4] is defined as seven episodes within 1 year or 5 episodes in the preceding 2 years and more or 3 episodes in the preceding 3 years and more. Recurrent tonsillitis was considered as an indication for tonsillectomy and these patients were recommended for tonsillectomy. All tonsillar sizes were evaluated by the same otorhinolaryngologist using Brodsky[20] grading scale as follows:

- +1: Tonsils obstruct less than 25% of the upper airway.
- +2: Tonsils obstruct 25-50% of the upper airway.
- +3:Tonsils obstruct 50-75% of the upper airway.
- +4: Tonsils obstruct more than 75% of the upper airway.

The patients included in the study were divided into 4 groups according to the tonsillar sizes. Group A was consist of 56 children with grade 1 tonsil size, while group B, C and D was consist of 58, 70 and 52 children with grade 2, 3 and 4 tonsil size, respectively. All operations risks and complications were explained to children's parents. Tonsillectomy was performed *via* cold-steel dissection approach. All the operations were performed by the same otorhinolaryngologist in our department. All chidren were clinically no symptoms of infection at the time of tonsillectomy. Routine pre-operative blood samples were taken from the antecubital vein into tubes with ethylene-diamine-tetracetic acid (EDTA) by a nurse. Neutrophil and lymphocyte were measured by hematology analyzer machine. NLR was calculated from the differential count by dividing the neutrophil measurement by the lymphocyte measurement. All of the patients were invited for control examinations at post-operative first week and third month. Blood samples were taken again in the post-operative third month, and the measurements were compared with pre-operative measurements.

Statistical Analysis

Number Cruncher Statistical System (NCSS) 2007 software (Kaysville, UT, USA) was used for all statistical analyses. Descriptive statistics (means and standard deviation, medians with interquartile range) were derived. The significance of intergroup differences was analyzed using Student's *t*-test, and the significance of the medians was analyzed with the Mann-Whitney U-test. A paired *t*-test was performed to test differences between pre-operative and post-operative values of NLR. A p-value<0.05 was considered to reflect statistical significance.

RESULTS

We included 236 patients: 108 (45.8%) females and 128 (54.2%) males. Their average age was 11.80±9.16 years (range: 4-18 years). The age and gender were not significantly different between the groups (all p>0.05). In group A, mean pre-operative NLR levels were 1.76±0.92, while post-operative NLR values were 1.74±1.53. No statistically significant difference in mean NLR values was observed between pre- and post-operatively in group A (p=0.864, Figure 1). In group B, mean pre-operative NLR levels were 1.56±1.14, while post-operative NLR values were 1.29±0.65. Post-operative NLR values were significantly lower than pre-operative NLR values in group B ($p=0.012$, p<0.05). In group C, mean pre-operative NLR levels were 1.48±1.47, while post-operative NLR values were 1.22±0.79. Post-operative NLR values were significantly lower than pre-operative NLR values in group C (p=0.036, p<0.05). In group D, mean pre-operative NLR levels were 1.44±1.52, while post-

ISSN 2470-4059 Open Journal http://dx.doi.org/10.17140/OTLOJ-2-127

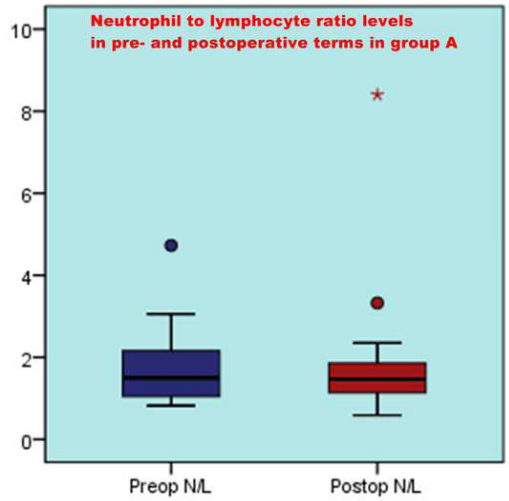

Figure 1: Neutrophil to lymphocyte ratio levels in pre- and post-operative terms in group A.

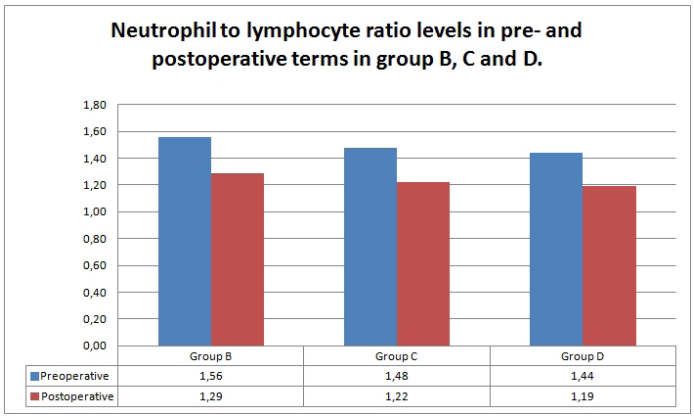

Figure 2: Neutrophil to lymphocyte ratio levels in pre- and post-operative terms in group B, C and D.

NLR	Group A (n:56)	Group B (n:58)	Group C (n:70)	Group D (n:52)
pre-operative	1.76±0.92	1.56±1.14	1.48±1.47	1.44±1.52
post-operative	1.74±1.53	1.29±0.65	1.22±0.79	1.19±0.96
*p	0.864	0.012	0.036	0.043

NLR: Neutrophil-to-lymphocyte ratio; *p: Mann–Whitney U-test; *p<0.05

Table 1: Comparison of Neutrophil-to-Lymphocyte ratio between groups.

operative NLR values were 1.19±0.96. Post-operative NLR values were significantly lower than pre-operative NLR values in group D (p=0.043, p<0.05) (Table 1) (Figure 2).

DISCUSSION

Identification of etiological factors of recurrent tonsillitis remains a current issue in otorhinolaryngology. Although many factors are blamed for the development of recurrent tonsillitis, there is no consensus on the certain etiological factors of recurrent tonsillitis. Knowledge of such factors would reduce the cost of surgery, increase the quality of life, and allow child development to be optimized.[1,2] Indications of tonsillectomy are well defined previously in literature, however, it depends entirely on surgeons approach and definitions. Also, child age, number of acute tonsillitis episodes, environmental conditions, the level of country development, parents attention affect the decision of timing of surgery.[2,4] No consensus has yet emerged regarding the optimal age at surgery, the surgical procedure to be used, or optimal post-operative care. Lack of data hinders the resolution of several controversial issues. Recently, NLR was used for determining the disease-specific survival of cancer subjects.[21] Also, systemic inflammation is strongly suspected to contribute to the decreased the overall survival of cancer subjects.[21-23] Similarly, the study of Gibson et al[23] have reported that survival rates after coronary artery bypass grafting were decreased due to higher NLR values. Some authors subscribe to that NLR is a valuable predictive marker for disease-specific survival and the overall of cancer subjects.[21,22] However, the exact reason of systemic inflammation in cancer subjects remains unclear. The study of Köseoğlu et al[5] have reported that mean NLR values of the OSAS group was 1.88±0.85 and NLR values of control group was 2.01±0.85 and they found no significant differences between OSAS group and normal group in terms of NLR values. Also, they assert that NLR may be used as a marker that indicates chronic intermittent hypoxia in patients with OSAS.[5] In another study, Chung et al[14] reported that NLR was higher in patients with vestibular neuronitis. NLR levels increased with nystagmus lasting up more than five days and drug treatment required for such patients. The study of Baglam et al[13] have reported that NLR was higher in patients who developed deep neck infection while compared to those who did not develop among children with acute bacterial tonsillitis. The study of Yenigun[24] have reported that the NLR could be used in chronic tonsillitis subjects as a potential helpful method for defined the necessity and timing of tonsillectomy and post-operative follow-up. To our knowledge, the present study provides the first report of explored the relationships between NLR and tonsillar sizes in children with recurrent tonsillitis. In the present study, the patients included were divided into four groups according to the tonsillar sizes. No statistically significant difference in mean NLR values was observed between pre- and post-operatively in group A, in contrast to other groups. We could assert that tonsillar sizes affect the NLR values and larger tonsils are strongly suspected to contribute to higher systemic inflammations. Also, surgeon do not decide tonsillectomy due to tonsillar size, but our data suggest that tonsillar sizes affect the systemic inflammation and may be contribute to increase numbers of acute tonsillitis episode. However, tonsils have an endophytic growth pattern. Moreover, it is not yet known the reason why some patients develop tonsil-

lar hypertrophy and some do not. Recurrent tonsillitis decrease the quality of children's life, therefore, timing of surgery is very important.[2,3] Also, without timely and appropriate treatment of recurrent tonsillitis, complications could be occurred.[4] Its complications are serious and life-threatening including such as peritonsillar, parapharyngeal and retropharyngeal abscesses.[11] Also, Yenigun[24] suggested that NLR levels could be used to prevent complications due to delayed or inadequate treatment in children with chronic tonsillitis. Therefore, several studies in the literature have led to the emergence of a new controversy. On the other hand, there are some limitations to this study. The limitations of this study included a retrospective study design, the sample size, and the lack of randomization. Again, NLR levels were not correlated with recurrent tonsillitis severity evaluations such as number of acute tonsillitis episode, symptom scores or the quality of life. However, a determination of severity of recurrent tonsillitis is objectively difficult because the diagnostic criteria is not determined. Future randomized studies should assess the relationship between number of acute tonsillitis episodes and NLR values in larger numbers of patients.

CONCLUSION

In conclusion, the larger tonsils affect the NLR levels and larger tonsils are strongly suspected to contribute to higher systemic inflammations. However, higher systemic inflammations can be prevented by tonsillectomy. Future randomized studies should assess the relationship between number of acute tonsillitis episodes and NLR values in larger numbers of patients.

AUTHORS CONTRIBUTIONS

YY and MÇ conceived, designed and did statistical analysis & editing of manuscript. BO, BMŞ, FTK did data collection and manuscript writing. FTK performed operations and did review and final approval of manuscript.

CONFLICTS OF INTEREST

No conflicts of interest was declared by the authors.

FINANCIAL DISCLOSURE

The authors declare that this study has received no financial support.

REFERENCES

1. Flanary VA. Long-term effect of adenotonsillectomy on quality of life in pediatric patients. *Laryngoscope.* 2003; 113(10): 1639-1644. doi: 10.1097/00005537-200310000-00003

2. Gigante J. Tonsillectomy and adenoidectomy. *Pediatr Rev.* 2005; 26(6): 199-202. Web site. http://www.thaipediatrics.org/attchfile/adenoidec2005.pdf. Accessed September 8, 2016

3. Nseir W, Mograbi J, Abu-Rahmeh Z, Mahamid M, Abu-Elheja O, Shalata A. The association between vitamin D levels and recurrent group A streptococcal tonsillopharyngitis in adults. *Int J Infect Dis.* 2012; 16(10): e735-e738. doi: 10.1016/j.ijid.2012.05.1036

4. Paradise JL, Bluestone CD, Colborn DK, Bernard BS, Rockette HE, Kurs-Lasky M. Tonsillectomy and adenotonsillectomy for recurrent throat infection in moderately affected children. *Pediatrics.* 2002; 110(1): 7-15. Web site. http://pediatrics.aappublications.org/content/110/1/7. Accessed September 8, 2016

5. Köseoğlu S, Özcan KM, Ikincioğlu A, Çetin MA, Yıldırım E, Dere H. Relationship between neutrophil to lymphocyte ratio, platelet to lymphocyte ratio and obstructive sleep apnea syndrome. *Adv Clin Exp Med.* 2015; 24(4): 623-627. doi: 10.17219/acem/47735

6. Patel HH, Straight CE, Lehman EB, Tanner M, Carr MM. Indications for tonsillectomy: A 10 year retrospective review. *Int J Pediatr Otorhinolaryngol.* 2014; 78(12): 2151-2155. doi: 10.1016/j.ijporl.2014.09.030

7. Achar P, Sharma RK, De S, Donne AJ. Does primary indication for tonsillectomy influence post-tonsillectomy haemorrhage rates in children? *Int J Pediatr Otorhinolaryngol.* 2015; 79(2): 246-250. doi: 10.1016/j.ijporl.2014.12.022

8. Werle AH, Nicklaus PJ, Kirse DJ, Bruegger DE. A retrospective study of tonsillectomy in the under 2-year-old child: indications, perioperative management, and complications. *Int J Pediatr Otorhinolaryngol.* 2003; 67(5): 453-460. doi: 10.1016/S0165-5876(02)00387-7

9. Capper R, Canter RJ. A comparison of sleep quality in normal children and children awaiting (adeno)tonsillectomy for recurrent tonsillitis. *Clin Otolaryngol Allied Sci.* 2001; 26(1): 43-46. doi: 10.1046/j.1365-2273.2001.00426.x

10. Gysin C. Indications of pediatric tonsillectomy. *ORL J Otorhinolaryngol Relat Spec.* 2013; 75(3): 193-202. doi: 10.1159/000342329

11. Lescanne E, Chiron B, Constant I, et al. Pediatric tonsillectomy: Clinical practice guidelines. *Eur Ann Otorhinolaryngol Head Neck Dis.* 2012; 129(5): 264-271.

12. Atan D, Ikinciogulları A, Koseoglu S, et al. New predictive parameters of Bell's palsy: Neutrophil to lymphocyte ratio and platelet to lymphocyte ratio. *Balk Med J.* 2015; 32: 167-170. doi: 10.5152/balkanmedj.2015.15456

13. Baglam T, Binnetoglu A, Yumusakhuylu AC, Gerin F, Demir B, Sari M. Predictive value of the neutrophil-to-lymphocyte ratio in patients with deep neck space infection secondary to acute bacterial tonsillitis. *Int J Pediatr Otorhinolaryngol.* 2015; 79:

1421-1424. doi: 10.1016/j.ijporl.2015.06.016

14. Chung JH, Lim J, Jeong JH, Kim KR, Park CW, Lee SH. The significance of neutrophil to lymphocyte ratio and platelet to lymphocyte ratio in vestibular neuritis. *Laryngoscope*. 2015; 125: E257-E261. doi: 10.1002/lary.25204

15. Kum RO, Yurtsever Kum N, Ozcan M, et al. Elevated neutrophil-to-lymphocyte ratio in Bell's palsy and its correlation with facial nerve enhancement on MRI. *Otolaryngol Head Neck Surg*. 2015; 152(1): 130-135. doi: 10.1177/0194599814555841

16. Seo YJ, Park YA, Bong JP, Park DJ, Park SY. Predictive value of neutrophil to lymphocyte ratio in first-time and recurrent idiopathic sudden sensorineural hearing loss. *Auris Nasus Larynx*. 2015; 42(6): 438-442. doi: 10.1016/j.anl.2015.04.011

17. Seo YJ, Jeong JH, Choi JY, Moon IS. Neutrophil-to-lymphocyte ratio and platelet-to-lymphocyte ratio: Novel markers for diagnosis and prognosis in patients with idiopathic sudden sensorineural hearing loss. *Dis Markers*. 2014; 2014: 702807. doi: 10.1155/2014/702807

18. Durmuş K, Terzi H, Karataş TD, et al. Assessment of hematological factors involved in development and prognosis of idiopathic sudden sensorineural hearing loss. *J Craniofac Surg*. 2016; 27(1): e85-e91. doi: 10.1097/SCS.0000000000002241

19. Wang J, Arase H. Regulation of immune responses by neutrophils. *Ann N Y Acad Sci*. 2014; 1319: 66-81. doi: 10.1111/nyas.12445

20. Brodsky L, Moore L, Stanievich JF. A comparison of tonsillar size and oropharyngeal dimensions in children with obstructive adenotonsillar hypertrophy. *Int J Pediatr Otorhinolaryngol*. 1987; 13(2): 149-156. doi: 10.1016/0165-5876(87)90091-7

21. Walsh SR, Cook EJ, Goulder F, Justin TA, Keeling NJ. Neutrophil-lymphocyte ratio as a prognostic factor in colorectal cancer. *J Surg Oncol*. 2005; 91: 181-184. doi: 10.1002/jso.20329

22. Sarraf KM, Belcher E, Raevsky E, Nicholson AG, Goldstraw P, Lim E. Neutrophil/lymphocyte ratio and its association with survival after complete resection in non-small cell lung cancer. *J Thorac Cardiovasc Surg*. 2009; 137: 425-428. doi: 10.1016/j.jtcvs.2008.05.046

23. Gibson PH, Croal BL, Cuthbertson BH, et al. Preoperative neutrophil-lymphocyte ratio and outcome from coronary artery bypass grafting. *Am Heart J*. 2007; 154: 995-1002. doi: 10.1016/j.ahj.2007.06.043

24. Yenigun A. The efficacy of tonsillectomy in chronic tonsillitis patients as demonstrated by the neutrophil-to-lymphocyte ratio. *J Laryngol Otol*. 2015; 129(4): 386-391. doi: 10.1017/S0022215115000559

OTOLARYNGOLOGY

Openventio PUBLISHERS

ISSN 2470-4059 Open Journal http://dx.doi.org/10.17140/OTLOJ-2-128

Systematic Review

***Corresponding author**
Arianna Di Stadio, MD, PhD
Department of Otolaryngology
University "La Sapienza"
00185 Rome, Italy
E-mail: ariannadistadio@hotmail.com

Volume 2 : Issue 5
Article Ref. #: 1000OTLOJ2128

Article History
Received: August 22nd, 2016
Accepted: September 27th, 2016
Published: September 27th, 2016

Citation
Di Stadio A. Arachnoid cyst of internal auditory canal: How the temporal bone findings explain ear symptoms and suggest the best treatment to do. *Otolaryngol Open J*. 2016; 2(5): 125-131. doi: 10.17140/OTLOJ-2-128

Arachnoid Cyst of Internal Auditory Canal: How the Temporal Bone Findings Explain Ear Symptoms and Suggest the Best Treatment To Do

Arianna Di Stadio, MD, PhD*

Department of Otolaryngology, University "La Sapienza", 00185 Rome, Italy

ABSTRACT

Objective: Aim of this short review is to identify relevant findings in clinical and surgical treatment studying arachnoid cyst of internal auditory canal.
Study design: Retrospective study of relevant papers in literature.
Methods: PubMed and Google Scholar searches using the following keywords: arachnoid cyst, internal auditory canal, temporal bones study, schwannoma of internal auditory canal, cystic schwannoma, MRI findings, surgery of internal auditory canal. Only the article where three keywords, included always arachnoid cyst, were considered. The study analyzed the etiopathogenesis of arachnoid cyst, hearing and vestibular symptoms and temporal bone findings.
Review and conclusion: The author identified and reviewed a total of 46 articles. The results showed high incidence of hearing loss that was the more common symptom than vestibular one. Arachnoid cyst carried out more compression on the vestibular nerves than on the cochlear one. The review allowed us to identify which mechanism of damage arachnoid cyst acting on the nerves. It is necessary to consider the arachnoids cyst in differential diagnosis with tumors and pathologies involving the internal auditory canal.

KEYWORDS: Arachnoid cyst; Internal auditory canal; Temporal bones study; Schwannoma of internal auditory canal; Cystic schwannoma; MRI findings; Surgery of internal auditory canal.

INTRODUCTION

Arachnoid Cyst (AC) of Internal Auditory Canal (IAC) is a very rare finding. Sumner and Thijssen described the first clinical case in the beginning of '70.[1,2] Schucknecht, in 1993, identified this structure in the internal auditory canal of three temporal bones.[3] Arachnoid cyst can be found in 50% of cases in the Sylvian fissure, in the posterior fossa in 20% and in the Ponto Cerebellum Angle (APC) in 10% of case. In children the higher incidence is in the middle cranial fossa.[4] AC are discovered in the 0.5% of surgery to treat the tumor of internal auditory canal, sometimes as accidental findings or mistaken as Schwannoma.[3] The author tries to define when and if, the Arachnoid cyst needs to be considered in differential diagnosis in presence of hearing loss, dizziness and facial palsy.

ARACHNOID CYST ETHIOPATHOGENESIS

The etiology of arachnoid cyst is poorly understood. Congenital/primary[5,6] and inflammatory origin/secondary[6,7] could explain its births and growths.Two mechanisms can determinate an arachnoid cyst. One, is the inflammation, that can explain the primary cyst too. The leptomeningeal infection can be acquired prenatally through placenta.[8] This inflammation produces a localized scarring and adhesion involving the subarachnoid space, leading to a flocculation and closure of its communication with the adjacent subarachnoid compartment.[9,10] The cyst usually contains a clear colorless fluid. Their wall consists of a vascular collagenous membrane lined by a flat single-layered arachnoid endothelium. The presence of fibrous thickening

ISSN 2470-4059 Open Journal http://dx.doi.org/10.17140/OTLOJ-2-128

and chronic inflammatory cells suggest a post infection or post traumatic origin.[11] The second mechanism involved in cyst formation is the splitting of arachnoid membrane. This is probably the most common between the two. Also in this second case, cyst contains clear colorless fluid but the wall is regular without thickening and similar to the normal arachnoid membrane. The clear fluid is similar to cerebrospinal fluid (CSF) but may have a higher concentration of protein than CSF.12 The variation in cyst volume is widely discussed in literature. There are different theories to explain the mechanism: 1) The outer arachnoid cells liquid production; 2) The slit valve mechanism causing intermittent entrapment of CSF; 3) Osmotic gradient between the cysts. The slit valve mechanism seems to be the more probable cause of the growth, because liquid production is very rare by the cells, as the osmotic gradient.[13,14]

SYMPTOMS

Arachnoid cyst can be asymptomatic or symptomatic in function of its volume and its position in the internal auditory canal (Figure 1). Sumner described as first a facial paralysis as sequel of an arachnoid cyst of internal auditory canal in a child. He reported a case of child 3 years old with facial paralysis; the arachnoid cyst compressed the nerve determining a facial palsy.[1] Thijssen as Sumner described a peripheral facial palsy in a 7 year old girl, in this case deafness in the same side of facial palsy was present.[2] In 1986 Hardenberg described an AC in the internal auditory canal pervasive to the region of the oval window with disturbance of ossicular chain function.[15]

Schucknecht reported three cases of arachnoid cyst of internal auditory canal, two of the three patients presented bilateral sensorineural hearing loss, the third case showed a mixed hearing loss with speech discrimination at 68%.[3] Francis reported a case of AC of right internal auditory canal in a 50 year woman that presented with progressive hearing loss and tinnitus and occasional loss of balance; neuro-otological examination showed a profound sensorineural hearing loss in the right ear and a paralysis of right lateral semicircular canal reflex.[7] Takano described a 59 years old woman with facial spasm and tinnitus in the left side persistent since 3 years, also in this occasion TC and T2 MRI showed the presence of an arachnoids cyst.[16] Aubry presented another case of symptomatic arachnoid cyst, in his case report the patient showed hearing loss, tinnitus and recurrent vertigo.[17] Mastronardi identified an AC in a patient affected by left hemifacial spasm since 10 years.[18] Fleck described one patient affected by unilateral sensorineural hearing loss associated with tinnitus.[19] Zhang, in a multi case report, presented a patient with sensorineural hearing loss and tinnitus without ABR response in the ear and other two patients didn't present any symptoms.[6] Tamarind presented a 10 years old boy with facial palsy and hearing loss.[5]

We can conclude that hearing loss is the most common symptoms in patients affected by arachnoid cyst of internal auditory canal followed by facial nerve disorders (Figure 2).

TEMPORAL BONE AND SURGERY FINDINGS

Few TBs studies are available in literature due to the low incidence of arachnoid cyst in human subject.[3,6] Surgery case reports describe widely the findings of internal auditory canal in case of arachnoids cyst resection.[2,5,7,16-19] Figure 3 shows the different findings in displacement and compression of the nerves between the TBs studies and surgery. Figures 4 and 5 summarized dif-

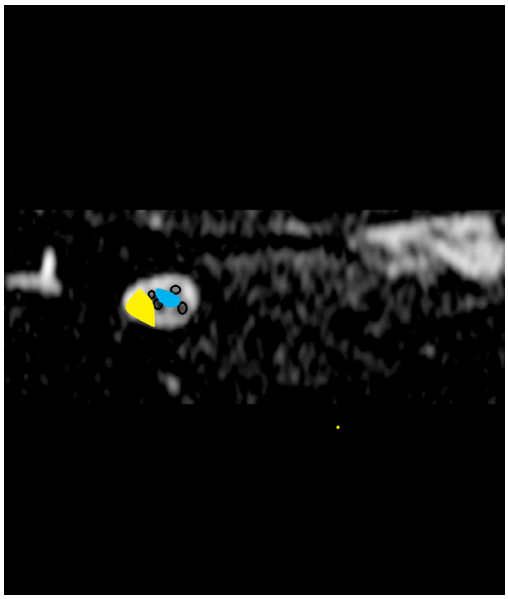

Figure 1: MRI Figure of IAC in T2: in blue Arachnoid Cyst in central position between the nerves, in yellow lateral to the structures.

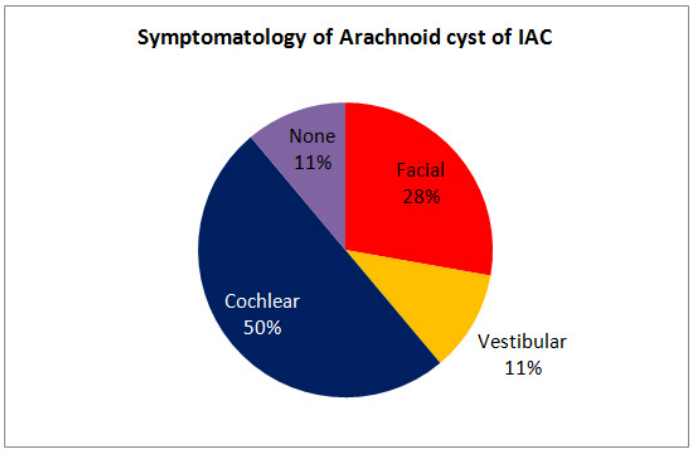

Figure 2: Symptomatology distribution in case of Arachnoid cyst of IAC.

ISSN 2470-4059 Open Journal http://dx.doi.org/10.17140/OTLOJ-2-128

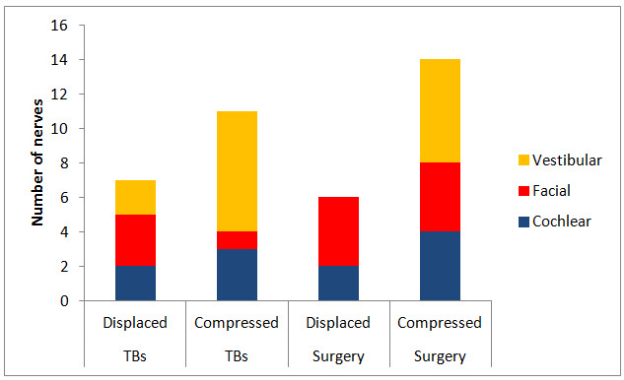

Figure 3: Nerve involvement in the different actions of Arachnoid cyst in Temporal bone findings and surgery reports.

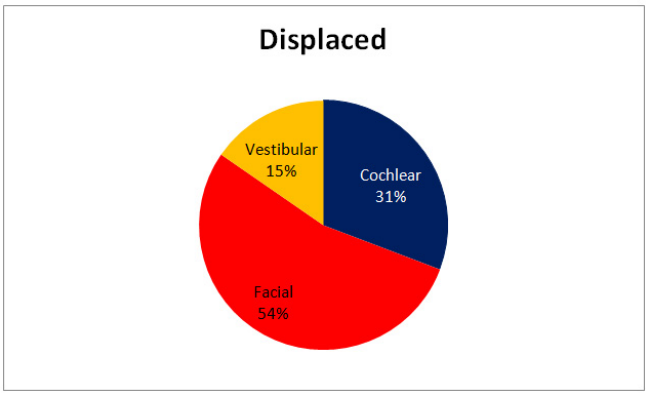

Figure 4: Incidence of nerves displaced by Arachnoid Cyst action.

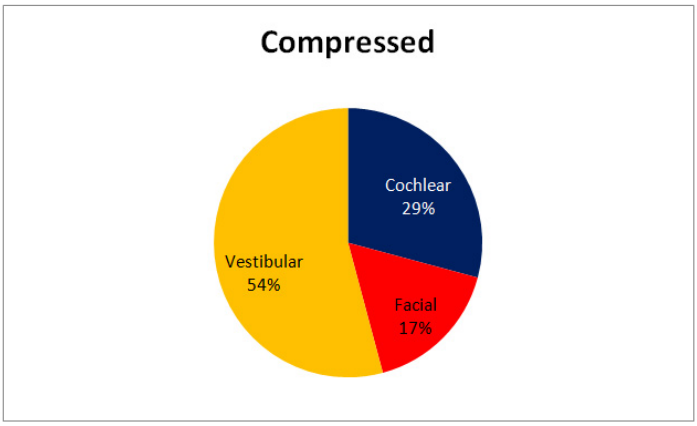

Figure 5: Incidence of compression acted by arachnoid cyst on the different structures.

ferent distribution between displacement and compression between the nerves. Vestibular nerves seem to be most frequently compressed (54%) than cochlear nerve (29%). The facial nerve is more frequently displaced (54%) but less compressed (17%). Figure 6 shows the otopathology aspects of the cyst in the IAC.

MECHANISM OF DAMAGE

Erick studied the average of diameter of internal auditory canal using MRI study on more 1230 patients and, he identified 5.93 mm as caliber of internal auditory canal. It's easy understand that in this small space, also a small structure (within 1 mm) can produce a nerves compression. The compression process starts when and if the cyst changes its volume. The first step is a nerve displacement in case of cyst under 1 mm. Figure 1 showed how cyst can arise in different areas of IAC and can displace one or more nerves. An AC in central position in the IAC (blue in Figure 1) with growth compresses the four nerves against the wall of IAC, probably a cyst in this position can be symptomatic also in volume <1 mm. A cyst in the lateral position (yellow in Figure

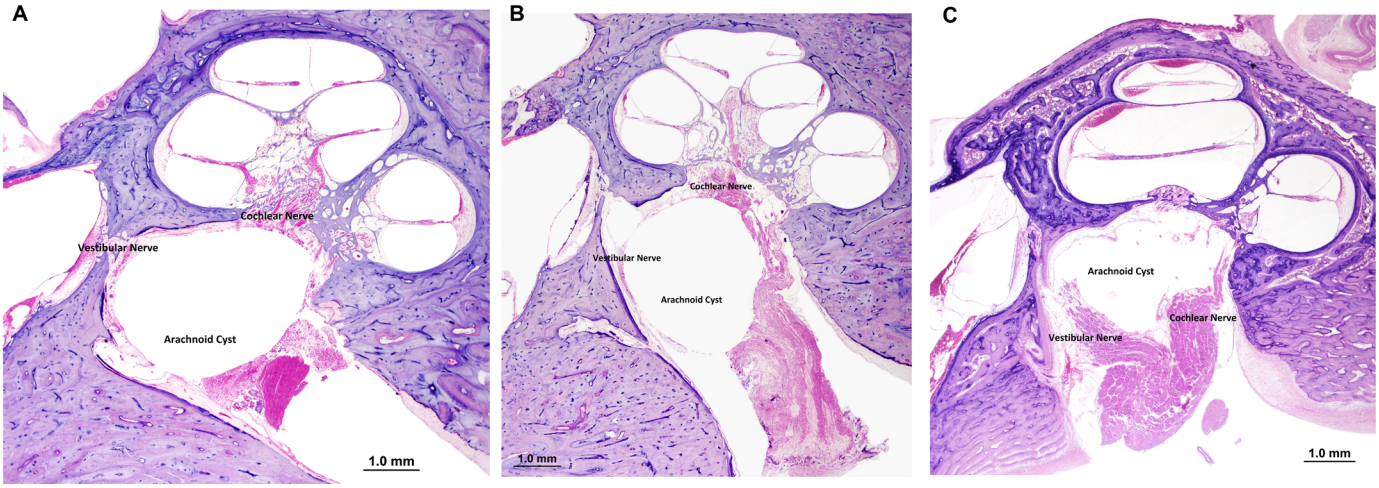

Figure 6: A) Temporal bone aspect of arachnoid cyst of IAC that compress cochlear and vestibular nerve. B) In this aspect the main pressure is on the vestibular nerve and the cochlear nerve is displaced. C) In this TB the cyst displaced both nerve without important compression.

ISSN 2470-4059 Open Journal http://dx.doi.org/10.17140/OTLOJ-2-128

Arachnoid Cyst versus	*Schwannoma	*Ganglioma	*Giant Cell Tumor
	*Meningioma	*Lipoma	*Teratoid/Rabhoid tumor
	*Gliosarcoma	*Cavernous Angioma	*Metastasis
	*Hemangiopericytoma	*Solitary Plasmacytoma	

Table 1: Differential diagnosis.

1), displaces the nerves too, but could be less aggressive than the one in central position and be asymptomatic for long time also if bigger than 1 mm. The compression mechanism demyelinates the nerve as first arriving to totally destroy the structures.

DISCUSSION

Literature supports the idea that arachnoid cyst of Internal Auditory canal can be symptomatic. Compression and displacement of vestibular nerves seem to be more common than cochlear nerve.

Vertigo and dizziness are less common than hearing loss because cyst normally has a slow growth and it allows an adaptive mechanism by the vestibular apparatus that involves somatosensory (proprioception) and vision other the ear.

We have to consider a cyst involvement, in case of recurrent facial palsy, without regression after several months.

Sensorineural Hearing Loss (SNHL) can be progressive and asymptomatic in the beginning, but can become "the pure" symptom of arachnoid cyst. The audiogram shows a unilateral sensorineural hearing loss with a sloping threshold involving all frequencies.

Word recognition test and ABR can help in diagnosis. WR recognition test is worse than expected from audiometric threshold. ABR results destructured presenting prolonged latencies of 1st, 3rd and 5th peak.

The progressive SNHL in AC, is a phenomenon due to neurodegeration, so word recognition test and ABR can detect this event more quickly than Pure Tone Audiometry.

Arachnoid cyst can be discovered as accidental finding during a schwannoma surgery, because it is often confused as cystic Schwannoma.[2,7,17] Arachnoid cyst and acoustic schwannoma can present same symptoms and onset.

Using imaging MRI today is possible figure out the correct diagnosis. Arachnoid Cyst appears as well demarcated area, hypo intense on T1 weighted imaging and hyper intense on T2 weighted imaging, without contrast enhancement with gadolinium.[18] Acoustic schwannoma enhances gadolinium in homogenous way; it is intense to CSF and present different shapes: round (14%), oval (36%) and poliglobular in 14% of cases.[20-23] The acoustic cystic schwanoma exhibits higher signal intensity than CSF in T1- and T2- weighted Figures,[22,24] and the intramural cyst showed peripheral enhancement after gadolinium.

Schwannoma and Arachnoids Cyst have similar symptomatology analyzing audiometric and vestibular findings. A sudden onset of symptoms is rare in both pathologies even if, in case of rapid growth of cystic schwannoma the symptom becomes quickly disabling for patient. Arachnoid cyst has usually a slow growth, slight symptoms and these are usually not referred by the patients as disabling.

Differential diagnosis is very difficult in case of pathologies involving the IAC. Common symptoms are presented by different types of cancers/masses; nerves compression or involvement is always present due to the small caliber of IAC. Vestibular symptoms as dizziness, hearing loss and tinnitus and, in some case facial palsy, reveals the nerve involving and damage.[25-34]

Table 1 summarizes cancer and/or mass (common and rare) that can arise in the IAC.

A correct diagnosis is useful to figure out to the best treatment to do. Gliosarcoma, hemangiopericitoma and metastasis in the IAC are treated with surgical approach associated to radio/chemotherapy.[25,26]

The conservative approach using gamma knife therapy can be useful if Schwannoma has a small volume.[35]

The posterior fossa approach is the best option to treat meningioma.[36]

Symptoms as manifestation of nerves involvement help us also to chose the treatment. Good hearing threshold and vestibular function preservation are findings often present in arachnoid cyst, this suggests that a middle temporal fosse approach[37] or a retrosigmoid one[38] can be the good option to preserve the nerve functions. The endoscopic approach[19,39] would be the best choice but not all surgeons are comfortable with it.

The translabyrinthine approach is always the best option to treat big mass in patients with hearing loss.

It is possible to remove the arachnoid cyst in one block, or to fenestrate it, removing part of liquid content and, then to remove its capsule.[19] The endoscopic surgery needs to fenestrate the cyst before whole removal especially in case of big mass. Using a middle fossa approach the whole mass removal is easy to do.

Audio-logic and vestibular evaluations are important before diagnosis, and after treatment also.

As before exposed, test results are able to address the specialist into the correct diagnosis. It is necessary to schedule one year follow-up also in patients after cyst removal, even if arachnoid cyst rarely recurrent.

Arachnoid cyst surgery can determinate some sequelae, that have to be treated correctly. Vestibular rehabilitation is the gold standard to achieve vestibular compensation.[40] Facial nerve palsy can be treated by physical rehabilitation,[41] or using surgical procedure in inveterate case.[42-45] Residual hearing loss is successfully treated using temporal bone anchorage device.[46]

CONCLUSION

The author concluded even if AC is a very rare finding, it is always necessary to consider it as differential diagnosis of mass in the IAC. The SNHL is the most common symptom in the mass of IAC. Hearing test as pure audiometry, WR and ABR are helpful in diagnosis identification. MRI findings are fundamental to detect the pathologies origin and the recent improvement of this methodology helps us to understand the findings more easily. Undoubtedly, the most difficult differential diagnosis is the one with Cystic Schwannoma, but a strict follow-up can detect the correct findings. Further researches improving the quality of MRI will be necessary to identify the AC with accuracy.

ACKNOWLEDGEMENT

Special thanks to Professors Joseph Nadol and Micheal McKenna to allow the use of images from Otopathology collection of MEEI and to Mrs Garyphallia Patagonis for her help in the graphics and images production.

CONFLICTS OF INTEREST

The authors declare that they have no conflicts of interest.

REFERENCES

1. Sumner TE, Benton C, Marshak G. Arachnoid cyst of the internal auditory canal producing facial paralysis in a three-year-old child. *Radiology*. 1975; 114(2): 425-426. doi: 10.1148/114.2.425

2. Thijssen HO, Marres EH, Slooff JL. Arachnoid cyst simulating intrameatal acoustic neuroma. *Neuroradiology*. 1976; 11(4): 205-207. doi: 10.1007/BF00346080

3. Schuknecht HF, Gao YZ. Arachnoid cyst in the internal auditory canal. *Ann Otol Rhinol Laryngol*. 1983; 92(6 Pt 1): 535-541. doi: 10.1177/000348948309200601

4. Huang JH, Mei WZ, Chen Y, Chen JW, Lin ZX. Analysis on clinical characteristics of intracranial Arachnoid Cysts in 488 pediatric cases. *Int J Clin Exp Med*. 2015; 8(10): 18343-18350.

5. Thakar S, Furtado SV, Hegde AS. Arachnoid cyst in the internal auditory canal causing fluctuating facial paresis in a child. *Childs Nerv Syst*. 2011; 27(7): 1177-1179. doi: 10.1007/s00381-011-1458-1

6. Zhang Q, Kaga K, Sano M, Takegoshi H. Arachnoid cysts confined to the internal auditory canal or facial nerve canal. *J Laryngol Otol*. 2011; 125(10): 1053-1058. doi: 10.1017/S0022215111001745

7. Francis HW, Nager GT, Holliday MJ, Long DM. Association of heterotopic neuroglial tissue with an arachnoid cyst in the internal auditory canal. *Skull Base Surg*. 1995; 5(1): 37-49. doi: 10.1055/s-2008-1058949

8. Zulch KJ. *Brain Tumors: Their Biology and Pathology*. 3rd ed Berlin, Germany: Springer Verlag; 1986

9. Burger PC, Scheithauer BW, Vogel FS. *Surgical Pathology of the Nervous System and its Coverings*. 3rd ed. New York, USA; Churchill Livingstone; 2002.

10. Horrax G. Generalized cisternalarachnoiditis simulating cerebellar tumor: Its surgical treatment and end results. *Arch surg*. 1924; 9(1): 95-112. doi: 10.1001/archsurg.1924.01120070098004

11. Russel D, Rubinstein LJ. *Pathology of Tumors of the Nervous System*. 5th ed. Baltimore, MD, USA; William and Wilkins; 1989.

12. Matsuda M, Hirai O, Munemitsu H, Kawamura J, Matsubayashi K. Arachnoid cysts--report of two adult cases in the interhemispheric fissure and over the cerebral convexity. *Neurol Med Chir (Tokyo)*. 1982; 22(1): 71-76. doi: 10.2176/nmc.22.71

13. Rengachary SS, Watanabe I. Ultrastructure and pathogenesis of intracranial arachnoid cysts. *J Neuropathol Exp Neurol*. 1981; 40(1): 61-83. doi: 10.1097/00005072-198140010-00007

14. Go KG, Houthoff HJ, Blaauw EH, Stokroos I, Blaauw G. Morphology and origin of arachnoid cysts. Scanning and transmission electron microscopy of three cases. *Acta Neuropathol*. 1978; 44(1): 57-62. doi: 10.1007/BF00691640

15. Harenberg C, Helms J. Arachnoid cysts in the internal ear canal and facial canal (Fallopius). *Laryngol Rhinol Otol (Stuttg)*. 1986; 65(2): 83-85. Web site. http://europepmc.org/abstract/med/3959691 Accessed August 21, 2016.

16. Takano S, Maruno T, Shirai S, Nose T. Facial spasm and paroxysmal tinnitus associated with an arachnoid cyst of the cerebellopontine angle--case report. *Neurol Med Chir (Tokyo)*. 1998; 38(2): 100-103. doi: 10.2176/nmc.38.100

17. Aubry K, Wassef M, Guichard JP, Herman P, Tran Ba Huy P. Association of an arachnoid cyst with heterotopic neuroglial tis-

sue in the internal auditory canal. *Ann Otolaryngol Chir Cervicofac*. 2009; 126(3): 133-137. doi: 10.1016/j.aorl.2009.03.001

18. Mastronardi L, Taniguchi R, Caroli M, Crispo F, Ferrante L, Fukushima T. Cerebellopontine angle arachnoid cyst: A case of hemifacial spasm caused by an organic lesion other than neurovascular compression: Case report. *Neurosurgery*. 2009; 65(6): E1205. doi: 10.1227/01.NEU.0000360155.18123.D1

19. Fleck SK, Baldauf J, Langner S, Vogelgesang S, Schroeder S, Werner H. Arachnoid cyst confined to the internal auditory canal-endoscope-assisted resection: Case report and review of the literature. *Neurosurgery*. 2011; 68(1): E267-E270. doi: 10.1227/NEU.0b013e3181ff1fb7

20. Erkoc MF, Imamoglu H, Okur A, Gumus C, Dogan M. Normative size evaluation of internal auditory canal with magnetic resonance imaging: Review of 3786 patients. *Folia Morphol (Warsz)*. 2012; 71(4): 217-220.

21. Dähnert W. *Radiology Review Manual*. Philadelphia, PA, USA: Lippincott Williams & Wilkins; 2003.

22. Morantz RA, Walsh JW. *Brain Tumors: A Comprehensive Text*. Zug, Switzerland: Informa HealthCare; 1994.

23. Mulkens TH, Parizel PM, Martin JJ, et al. Acoustic schwannoma: MR findings in 84 tumors. *AJR Am J Roentgenol*. 1993; 160(2): 395-398. doi: 10.2214/ajr.160.2.8424360

24. Tali ET, Yuh WT, Nguyen HD, et al. Cystic acoustic schwannomas: MR characteristics. *AJNR Am J Neuroradiol*. 1993; 14(5): 1241-1247. Web site. http://www.ajnr.org/content/14/5/1241.short. Accessed August 21, 2016.

25. Duan H, Kitazawa K, Yako T, Ichinose S, Kobayashi S, Sudo M. Gliosarcoma in the cerebellopontine angle with rapid tumor growth and intratumoral hemorrhage. *World Neurosurg*. 2016; 92: e17-e21. doi: 10.1016/j.wneu.2016.06.053

26. Ben Nsir A, Badri M, Kassar AZ, Hammouda KB, Jemel H. Hemangiopericytoma of the cerebellopontine angle: A wolf in Sheep's clothing. *Brain Tumor Res Treat*. 2016; 4(1): 8-12. doi: 10.14791/btrt.2016.4.1.8

27. Hooten KG, Oliveria SF, Sadrameli SS, Gandhi S, Yachnis AT, Lewis SB. Bilateral internal auditory canal gangliogliomas mimicking neurofibromatosis Type II. *Surg Neurol Int*. 2016; 7: 39. doi: 10.4103/2152-7806.180300

28. Bigelow DC, Eisen MD, Smith PG, et al. Lipomas of the internal auditory canal and cerebellopontine angle. *Laryngoscope*. 1998; 108(10): 1459-1469. doi: 10.1097/00005537-199810000-00008

29. Reimann K, Arnold H, Bisdas S, et al. Cavernous angiomyoma of the internal auditory canal. *Otol Neurotol*. 2015. doi: 10.1097/MAO.000000000000094

30. Lavinsky J, Aaron KA, Christian E, et al. Solitary Plasmacytoma in the Internal Auditory Canal and Cerebellopontine Angle Mimicking Meningioma. *Otol Neurotol*. 2015. doi: 10.1097/MAO.0000000000000859

31. Jada AS, Shrivastava RK, Mannan A, Kobets A, Manolidis S. Rare Presentation of Giant Cell Tumor in the Internal Auditory Canal: Case Report and Review of the Literature. *J Neurol Surg Rep*. 2015; 76(1): e65-e71. doi: 10.1055/s-0034-1396656

32. Yamaguchi T, Oka H, Kijima C, Sano H, Watanabe H, Okamoto M. A case of atypical teratoid/rhabdoid tumor in the internal auditory canal. *Auris Nasus Larynx*. 2015; 42(2): 163-166. doi: 10.1016/j.anl.2014.09.005

33. Kitavi W, Hamberger U, Sudhoff H. Perineural spread of salivary duct carcinoma to the internal auditory canal. *Case Rep Otolaryngol*. 2014; 2014: 476317. doi: 10.1155/2014/476317

34. Lalwani AK, Jackler RK. Preoperative differentiation between meningioma of the cerebellopontine angle and acoustic neuroma using MRI. *Otolaryngol Head Neck Surg*. 1993; 109(1): 88-95.

35. Spatola G, Carron R, Delsanti C, Thomassin JM, Roche PH, Régis J. Long-term results of Gamma-knife stereotactic radiosurgery for vestibular schwannomas in patients with type 2 neurofibromatosis. *Neurochirurgie*. 2016; pii: S0028-3770(16)30065-0. doi: 10.1016/j.neuchi.2016.03.005

36. Gao K, Ma H, Cui Y, Chen X, Ma J, Dai J. Meningiomas of the cerebellopontine angle: Radiological differences in tumors with internal auditory canal involvement and their influence on surgical outcome. *PLoS One*. 2015; 10(4): e0122949. doi: 10.1371/journal.pone.0122949

37. Aihara N, Murakami S. Enlargement of the Internal Auditory Canal and Hearing Preservation in the Middle Fossa Approach for Intracanalicular Vestibular Schwannomas. *World Neurosurg*. 2015; 84(6): 1950-1955. doi: 10.1016/j.wneu.2015.08.041

38. Leal AG, Silva EB Jr, Ramina R. Surgical exposure of the internal auditory canal through the retrosigmoid approach with semicircular canals anatomical preservation. *Arq Neuropsiquiatr*. 2015; 73(5): 425-430. doi: 10.1590/0004-282X20150020

39. Marchioni D, Carner M, Rubini A, et al. The fully endoscopic acoustic neuroma surgery. *Otolaryngol Clin North Am*. 2016; 49(5): 1227-1236. doi: 10.1016/j.otc.2016.05.014

40. Herdman SJ, Clendaniel RA, Mattox DE, Holliday MJ,

ISSN 2470-4059 Open Journal http://dx.doi.org/10.17140/OTLOJ-2-128

Niparko JK. Vestibular adaptation exercises and recovery: Acute stage after acoustic neuroma resection. *Otolaryngol Head Neck Surg*. 1995; 113(1):77-87. doi: 10.1016/S0194-5998(95)70148-6

41. Barbara M, Monini S, Buffoni A, et al. Early rehabilitation of facial nerve deficit after acoustic neuroma surgery. *Acta Otolaryngol*. 2003; 123(8): 932-935. doi: 10.1080/00016480310000629

42. Di Stadio A. Eyelid lifting for ectropion and scleral show in facial palsy disease. *ORL J Otorhinolaryngol Relat Spec*. 2014; 76(6): 329-335. doi: 10.1159/000369623

43. Biglioli F, Colombo V, Rabbiosi D, et al. Masseteric-facial nerve neurorrhaphy: results of a case series. *J Neurosurg*. 2016; 1: 1-7. doi: 10.3171/2015.12.JNS14601

44. Kochhar A, Albathi M, Sharon JD, Ishii LE, Byrne P, Boahene KD. Transposition of the Intratemporal Facial to Hypoglossal Nerve for Reanimation of the Paralyzed Face: The VII to XII TranspositionTechnique. *JAMA Facial Plast Surg*. 2016; 18(5): 370-378. doi: 10.1001/jamafacial.2016.0514

45. Aljudaibi N, Bennis Y, Duquennoy-Martinot V, Labbé D, Guerreschi P. Lengthening temporalis myoplasty: Virtual animation-assisted technical video. *Plast Reconstr Surg*. 2016; 138(3): 506e-509e. doi: 10.1097/PRS.0000000000002512

46. Bouček J, Vokřál J, Černý L, et al. Baha implant as a hearing solution for single-sided deafness after retrosigmoid approach for the vestibularschwannoma: Audiological results. *Eur Arch Otorhinolaryngol*. 2016; 1-9. doi: 10.1007/s00405-016-4261-5

OTOLARYNGOLOGY

Openventio PUBLISHERS

ISSN 2470-4059 Open Journal http://dx.doi.org/10.17140/OTLOJ-2-129

Review

*Corresponding author
Omar Ramadan, PhD
ENT Registrar
Independent Researcher
Paterson, NJ 07533, USA
Tel. +1 973 563 9283
E-mail: omarram982@hotmail.com

Volume 2 : Issue 5
Article Ref. #: 1000OTLOJ2129

Article History
Received: September 29th, 2016
Accepted: October 6th, 2016
Published: October 6th, 2016

Citation
Ramadan O. Adult supraglottic stenosis: Etiology and management. *Otolaryngol Open J*. 2016; 2(5): 132-140. doi: 10.17140/OTLOJ-2-129

Adult Supraglottic Stenosis: Etiology and Management

Omar Ramadan, PhD*

Independent Researcher, Paterson, NJ 07533, USA

ABSTRACT

Supraglottic stenosis is a rare entity, which is more common in females, and trauma is the most common cause for it. Dysphagia, dysphonia, dyspnea and stridor are the common symptoms of supraglottic stenosis. Non-symptomatic cases can be managed by observation, and symptomatic cases with sever airway obstruction may need a tracheostomy; some cases may need nasogastric tube to relieve dysphagia. Endoscopic approach using carbon dioxide (CO_2) laser is the most common procedure used to treat supraglottic stenosis, supraglottic laryngectomy is only indicated for severe supraglottic stenosis. Supraglottic stenosis has high rate of recurrence and may need multiple surgical procedures. Supraglottic stenosis has a better prognosis than glottis and subglottic stenosis with successful treatment rate up to 83%. This is a short discussion about supraglottic stenosis found in literatures; the objective of this study is to present a brief review about this disease.

INTRODUCTION

The supraglottic stenosis is a rare disease; it is usually difficult to be managed. The most common causes are iatrogenic injury from supraglottic surgery, prolonged intubation, trauma, radiation therapy, caustic ingestion, and autoimmune diseases. Presenting symptoms may include dysphagia, dysphonia, shortness of breath (SOB), stridor and potentially life-threatening airway obstruction. There is a controversy about the optimal treatment of supraglottic stenosis. Historically, open supraglottic laryngectomy was the treatment of choice; however, this was associated by high morbidity connected to chronic aspiration and poor wound healing. Recently, endoscopic approach is more favorable because it is more conservative and associated with less morbidity.[1]

MATERIAL AND METHODS

Literature review was conducted using PubMed (MEDLINE) and Google Scholar for English articles, the following keywords were used: suraglottic and stenosis; laryngeal and stenosis.

Inclusion Criteria

All adult patients diagnosed with supraglottic stenosis following any cause were included in the study.

Exclusion Criteria

Neck malignancies, pediatric cases less than 12 years and burns of the neck.

RESULTS

Thirty-six studies about surpraglottic stenosis have been reported in PubMed (MEDLINE) in English literatures (Table 1).

ISSN 2470-4059 Open Journal http://dx.doi.org/10.17140/OTLOJ-2-129

Case	M/F	Age	Etiology	Site	Trachestomy	Treatment	Surgery Number	Outcome
Yilmaz et al[1]	3 M 3 F		Latrogenic Autoimmune (SLE) Infection (Rhinosclerma) Irradiation Caustic ingestion Trauma	4 patients had Supraglottic 2 patients had Supraglottic Glottic Subglottic	Yes all had Trachestomy	4 Patients had: Microlaryngoscopy CO_2 Laser Scar excision Dilation Mitomicin application 2 Patients had: Laryngeal construction surgery with stent	One Multiple	4 patients were decanulated One was decanulated One stayed dependent
Zoghbi et al[2]	F	51	Radiation	Supraglottic glotic	Yes	Microlaryngoscopy KTP Laser Scar excision	Multiple	Decanulated
Freitas et al[3]	F	78	Pemphigoid	Supraglottic	Yes	Medical treatment	NO	Dependent
Gilad et al[4]	F	64	Systemic Amyloidosis	Diffuse Amyloidosis suragloticpharynex trachea	Yes	No	NO	Dependent
Assanasen et al[5]	F M	24 39	Caustic agent Trauma	Supraglotic Glotic Sub glotic Supraglotic Glotic Sub glotic	Yes Yes	Laryngeal reconstruction surgery Laryngeal reconstruction surgery	One One	Dependent Dependent
Kim et al[6]	M	65	Radiation	Supraglotic Glotic Subglotic	Yes	Laryngeal reconstruction surgery	One	Dependent
Nair et al[7]	M F M		Radiation Caustic agent External trauma	Supraglotic Supraglotic Supraglottic Glottic Subglottic	Yes Yes Yes	Microlaryngoscopy CO_2 Laser Scar excision Microlaryngoscopy CO_2 Laser Scar excision Laryngeal reconstruction surgery	Multiple Multiple Multiple	Decanulated Decanulated Dependent
Pegg et al[8]	M	83	Idiopathic	Supraglotic	No	Microlaryngoscopy CO_2 Laser Dilation Scar excision	Multiple	Improved
Lasisi et al[9]	M M		Trauma Trauma	Supraglotic Supraglotic	Yes Yes	Microlaryngoscopy Scar excision with cold instruments Steroid injection Microlaryngoscopy Scar excision with cold instruments Steroid injection	Multiple Multiple	Decanulated Decanulated
Krishna et al[10]	F	61	GERD	Supraglotic	Yes	Transoral supraglottic laryngectomy	One	Decanulated
Saad et al[11]	F	70	TB	Supraglottic	Yes	Microlaryngoscopy CO_2 Laser Scar excision	Multiple	Decanulated
Oosthuizen et al[12]	F	13	Trauma	Supraglottic	No	Microlaryngoscopy Scar excision Dilation Mitomicin application	Multiple	Improved
Rubino et al[13]	F	70	Radiation	Supraglottic Posterior golttic	No	Microlaryngoscopy Scar excision with CO_2 Keel using	One	Improved

ISSN 2470-4059 Open Journal http://dx.doi.org/10.17140/OTLOJ-2-129

Sinacori et al[14]	1 M 1 F		Trauma Caustic agent		Yes	Microlaryngoscopy Scar excision with CO_2 ballon dilation Microlaryngoscopy Scar excision with CO_2 ballon dilation	Multiple Multiple	Decanulated
Kiniwa et al[15]	F	37	Epidermolysis Bullosa Acquisita	Supraglottic	Yes	Medical treatment	No	Decanulated
Lyons et al[16]	f	47	Caustic agent	Supraglottic Glottic	yes	Microlaryngoscopy Scar excision with CO_2 microdebrider	Multiple	Decanulated
Davis et al[17]	F	48	Iatrogenic	Supraglottic	Yes	Microlaryngoscopy Scar excision with CO_2	Mutiple	Decanulated
Duncav Age et al[18]	2F 1M		1 Trauma 2 Caustic agent	Supraglottic	Yes	All three patients had: Microlaryngoscopy Scar excision with CO_2	Mutiple	Decanulated
Doyle et al[19]	F		Caustic	Supraglottic	Yes	Open surgery laryngofissure Remove scar tissue	One	Decanulated
Minni et al[20]	F M M	62 58 35	Iatrogenic Iatrogenic Trauma	Supraglotic Supraglotic Supraglottic	No Yes Yes	Suprglottic laryngectomy Supraglottic Laryngectomy Supraglottic laryngectomy	One Multiple Multiple	Improved Decanulated Decanulated
Canis et al[21]	M		Iatrogenic	Supraglottic	Yes	Microlaryngoscopy Scar excision with CO_2	Multiple	Decanulated
Grant et al[22]	3 M 1 F		4 cases of Iatrogenic cause	All four cases Supra-glottic	Yes	All four patients had: Microlaryngoscopy Scar excision with CO_2	All four patients had: Multiple	4 Decanulated
Alon et al[23]	1 F		Iatrogenic	Supraglotic	Yes	No treatment	No	Dead before treatment
F. Izadi et al[24]	F	12	Fraser syndrome	Supraglottic Glotic	yes	Microlaryngoscopy CO_2 Laser Scar excision	Multiple	Dependent
Moore et al2[5]	M	48	Trauma	Supraglottic	Yes	Microlaryngoscopy KTP Laser Scar excision	One	Decanulated
Kacker et al[26]	3 M 2 F		3 Trauma 2 Caustic agent	Supraglotic	Yes	open surgical procedure (excision of the stenosis with repair of the supra glottis area *via* laryngofissure)	Multiple	All 5 Decanulated
Sunderr Ajan et Al[27]	M		Intubation	Supraglottic	Yes	Microlaryngoscopy Scar excision with CO_2	Multiple	Decanulated
Stevens et al[28]	4 M 4 F		5 Radiation 3 Autoimmune (2 wager, 1 Sarcoidosis)	Supraglotic	Yes	Microlaryngoscopy CO_2 laser Scar excision 6 patient had additional KTP laser in clinic	All patients have Multiple procedures	8 Decanulated
Mistry et al[29]	M	54	Plasmacytosis	Supraglotic	Yes	Dilatation to relieve supraglottic stenosis	One	Decanulated
Rubinstein et al[30]	F	18	TB	Supraglottic	Yes	Microlaryngoscopy CO_2 Laser Scar excision Stent topical mitomicin	Multiple	Decanulated

ISSN 2470-4059 Open Journal http://dx.doi.org/10.17140/OTLOJ-2-129

Belloso et al[31]	M	64	Wagner	Supraglottic	Yes	Medical treatment Microlaryngoscopy CO_2 Laser	One	Decanulated
Bahamonde et al[32]	F	69	Pemphigoid	Supraglottic	No	Medical treatment		Improved
Sims et al[33]	M	50	Sarcoidosis	Supraglottic	Yes	Microlaryngoscopy Scar excision with CO_2 Steroid	One	Decanulated
	F	50	Sarcoidosis	Supraglottic	Yes	Microlaryngoscopy Scar excision with CO_2 Steroid	Multiple	Decanulated
	F	48	Sarcoidosis	Supraglottic	Yes	Microlaryngoscopy Scar excision with CO_2 Steroid	Multiple	Dependent
	M	43	Sarcoidosis	Supraglottic	Yes	Microlaryngoscopy Scar excision with CO_2 Steroid	One	Dependent
Ma et al[34]	M	36	Amyloidosis	Supraglottis anterior commissure	Yes	Microlaryngoscopy Scar excision with CO_2 microdebrider	Multiple	Decanulated
Kaneko et al[35]	F	76	Wagner	Supraglotic	Yes	Medical treatment	No	Dependent
	F	72	Wagner	Supraglottic	No	Medical Treatment Microlaryngoscopy KTP Laser	One	Improved
	F	77	Idiopathic	Supraglottic	Yes	Medical treatment Palliative	No	Dependent
Vira et al[36]	F	50	Radiation	Supraglottic	Yes	Microlaryngoscopy CO_2 Laser Multiple dilation Scar excision Mitomycin application	Multiple	Decanulated
	M	58	Radiation	Supraglottic	Yes	Microlaryngoscopy CO_2 Laser Multiple dilation Scar excision Mitomycin application	Mutiple	Decanulated
	F	60	Sarcoidosis	Supraglottic	Yes	Microlaryngoscopy CO_2 Laser Multiple dilation Scar excision Mitomycin application	Multiple	Decanulated
	F	66	Idiopathic	Supraglottic	Yes	Microlaryngoscopy CO_2 Laser Multiple dilation Scar excision Mitomycin application	Multiple	Decanulated

Table 1: Supraglottic stenosis reported cases.

DEMOGRAPHIC AND ETIOLOGY

There were 72 patients of age ranged from 12 to 83 with majority of the patients over 50 year old. There were 33 males and 39 females in the study. Forty-six patients had stenosis secondary to trauma, 15 patients had supraglottic stenosis secondary to autoimmune diseases, 4 patients had supraglottic stenosis secondary to infection, 7 patients had stenosis secondary to other diseases (Table 2 Chart 1).

Sixty patients out of them had isolated supraglottic stenosis, while the other 12 patients had multiple sites laryngeal stenosis. Sixty-five patients of them had a tracheostomy, while the other 7 patients did not have tracheostomy.

TREATMENT

One was dead before the treatment, 2 patients had only medical treatment (pemphigoid), 1 patient had only a tracheostomy as a palliative therapy (systemic amyloidosis), 3 patients had tracheastomy and medical treatment (2 patients of them had wagener disease, the other patient had pemphigoid), 52 patients had endoscopic laryngeal surgery (one patient of them had endoscopic supralaryngectomy, 3 patients of them had endoscopic approach using cold instruments, while the other 48 patients had endoscopic approach using Laser), 9 patients had external laryngeal

ISSN 2470-4059 Open Journal http://dx.doi.org/10.17140/OTLOJ-2-129

Trauma	46	63.3%	External trauma	13	• Three patients without tracheostomy had a surgery and all of them improved • Forty-three patients had a surgery for decanulation, thirty eight patients of them were decanulated after surgery, while the other 5 patients stayed dependent on tracheostomy. **Successful management rate (41/46) 89%**
			Radiation	12	
			Caustic agent	10	
			Iatrogenic	10	
			Post intubation	1	
Autoimmune	15	20.8%	Ssarcoidosis	6	• Two patients improved after medical treatment • One patient without tracheostomy had surgery and his situation improved. • Eight patients weredecanulated after surgery. • Four patients stayed dependent on tracheostomy. **Successful management rate (11/15) 73%**
			Wagener	5	
			Pemphigoid	3	
			SLE	1	
Infection	4	5.5%	TB	2	• 4 patients weredecanulated after surgery. **Successful management rate 100%**
			Sclerma	1	
			Plasmacytosis	1	
Others	7	9.7%	Congenital	1	• One patient without tracheostomy had surgery and improved after it. • Two patients had tracheostomy as palliative therapy • Three patients had a surgery for decanultion, • Two patients of them were decanulated while the other patient stayed dependent on tracheostomy. **Successful management rate (3/7) 42%**
			Amyloidosis	2	
			GERD	1	
			Idiopathic	3	

Table 2: Etiology, successful rate whatever treatment (59/70) 84%.

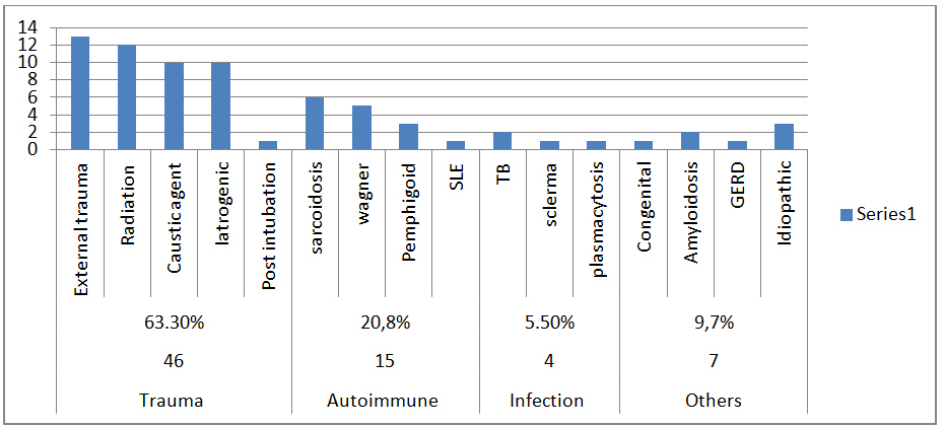

Chart 1

approach (3 patients of them had supraglottic laryngectomy, while the other 6 patients had open surgery using laryngofissure approach), 4 patients had staged laryngeal reconstruction surgery (Table 3 Chart 2).

DECANULATION

Sixty patients had a surgery for decanulation, 49 patients of them had only isolated supraglottic stenosis (47 patients of them were decanulated, 2 patients stayed dependent on tracheostomy), the other 11 patients with multiple sites laryngeal stenosis including supraglottic stenosis had surgery for decanulation (4 patients of them were decanulated, while the other 7 patients of them stayed dependent on tracheostomy. Most patients need multiple surgeries for decanulation. (Table 4 Chart 3).

DISCUSSION

Surgery for supraglottic stenosis is usually approached as same as stenosis elsewhere in the larynx.

Non-symptomatic cases may be managed by observation. Surgery is advised for symptomatic cases.

Endoscopic approaches are more favorable than open approaches, but open procedures is usually recommend for difficult and complex cases. For open procedures, a laryngofissure is used to approach and to respect the scar tissue. Partial supraglottic laryngectomy which can be done endoscopically or by open approach is used for severe cases in which the stenosis extends to the glottis. Endoscopic approaches to supraglottic stenois are

ISSN 2470-4059 Open Journal http://dx.doi.org/10.17140/OTLOJ-2-129

Management	Patients	Patients improved	Successful rate
Medical treatment	2	2	100%
Tracheastomy	1	0	0%
Medical treatment and Tracheastomy	3	0	0%
Endoscopic Laryngeal Surgery (laser, dilation or cold instruments)	52	47	90%
External approach (open supraglottic laryngectomy or open surgery using laryngofissure) for sever supraglottic stenosis	9	9	100%
Staged laryngeal construction Surgery (for severe cases associated with stenosis in another laryngeal areas).	4	1	25%

Table 3: Treatment modalities.

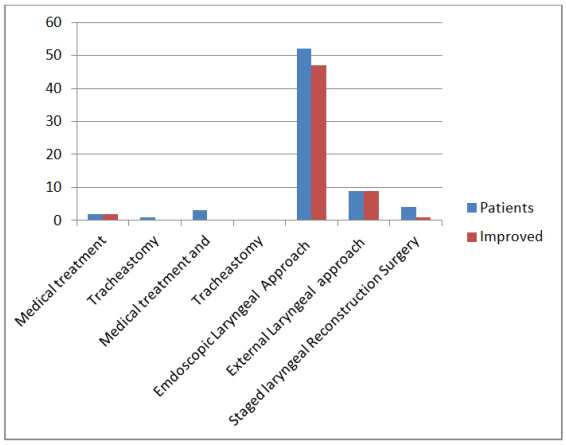

Chart 2

	Isolated Suprglottic stenosis	Multiple sites laryngeal stenosis including Supraglottic stenosis
Patients had a Surgery for decanulation	49	11
Decanulated patients	47	4
Decanulation rate	95%	36%

Table 4: Supraglottic stenosisdecanulation.

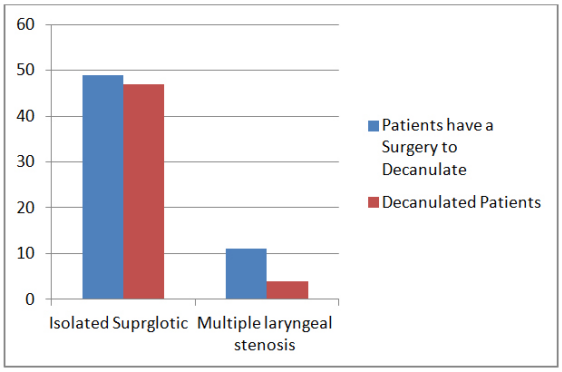

Chart 3

less invasive and often give good results same as open approach. CO_2 laser excision is commonly used because of its ability to resect scar and give good hemostasis at the same time. If the scar tissue extends to the glottis, then cold resection may be good option to protect vocal folds from thermal injury.[25]

Laryngeal caustic injury is associated with oral, pharyngeal and esophagus injury, sopanendoscopy consisting of laryngo-tracheo-bronchoscopy and pharyngo-esophago-gastroscopy is considered to be mandatory. Up to 3rd of patients with caustic ingestion may complain of long-term complications such as oral, pharyngeal, laryngeal, and esophageal strictures. The typical clinical course starts 2 weeks after caustic ingestion. The clinical symptoms include upper airway obstruction, dysphagia, and dysphonia/aphonia. The larynx scar is often located at supraglottic area without involvement of the vocal folds. The surgical treatments of caustic pharyngolaryngeal stenosis include open neck surgery or transoral procedures. The 1st approach con-

ISSN 2470-4059 Open Journal http://dx.doi.org/10.17140/OTLOJ-2-129

sists of laryngofissure, permanent tracheostomy, and/or laryngectomy. In selected cases, a complete resection of the stenosis is performed and followed by optimal reconstruction. The 2nd approach includes using of cold instrumentations or laser.[26]

Intubation usually cause stenosis in subglottic and posterior glottis area, it is uncommon to induce stenosis insupraglottic area.[27]

Laryngeal edema, chondronecrosis, necrosis of soft tissue, necrosis of skin, stricture of pharynx and larynx, and carotid stenosis occur infrequently during head and neck radiotherapy. Treatment of laryngeal stricture caused by radiation is a tracheostomy for respiratory distressed patients, dilation and CO_2 laser to remove scar tissue.[28]

Balloon dilation for supraglottic stenosis is reported in the literature to treat suraglottic stenosis caused by fungal infection.[29]

Laryngeal tuberculosis is rarely reported; it is more common in middle-aged males, and appears with a negative chest x-ray; hoarseness is the most common symptom. Sometimes tracheostomy is necessary to relieve severe laryngeal obstruction. Endoscopic CO_2 laser to remove scar tissue and to insert a laryngeal stent is the treatment of choice for supraglottic stenosis. We can also apply mitomycin-C locally.[30]

The therapy of laryngeal involvement of Wagner disease is based on two components; the 1st is the treatment of systemic disease with steroid and immunosuppressant medications, the second is the treatment of local symptoms with tracheostomy, dilation, CO_2 laser vaporization and finally resection of the stenosis segment followed by reconstruction.[31]

Pemphogoid is treated with steroid, immunosuppressant medications and dapsone. Tracheostomy is kept for necessary cases, remission is essential so we avoid needing for surgical intervention as well as regular assessment to prevent recurrence.[32]

Laryngeal sarcoidosis more commonly involves supraglottic area. Laryngeal sarcoidosis usually presents with hoarseness, dry cough and dysphagia.

Treatment ranging from closes observing in stable asymptomatic patients to emergent tracheostomy in patients with acute respiratory distress. Systemic steroid therapy is the basic therapy for a systemic disease. Localized laryngeal disease is treated with resection using CO_2 laser with local steroids or mitomycin-C. Open surgical excision and external radiation therapy may be also used.[33]

Amyloidosis is usually localized in the head and neck area, treatment with surgical excision is usually successful for symptomatic cases. In the larynx, a conservative resection using microlaryngeal surgical approach is recommended with preservation of the surrounding tissue. Recent articles has advocated CO_2 laser as the treatment of choice, recurrence is usually rare and can be treated with further conservative excision.[34]

No history of recent intubation, trauma, or autoimmune diseases should be existed to diagnosis idiopathic supraglottic stenosis which is more common in female.[35]

There are multiple articles reported that the application of local mitomycin-C or corticosteroid during the surgery may decrease the recurrence of the laryngeal stenosis.[36]

CONCLUSION

Suraglottic stenosis is more common in female, trauma is the most common cause of supraglottic stenosis, suraglottic stenosis caused by infection has a better prognosis, while supraglottic stenosis caused by autoimmune diseases has a lower rate of decanulation (may be because there is no definite treatment for autoimmune diseases and disease usually recur). Isolated supraglottic stenosis has a good prognosis with 95% successful treatment rate. Endoscopic approach using laser was the most common procedure used to treat supraglottic stenosis with 90% successful rate.

REFERENCES

1. Yılmaz T, Jafarov S, Kuşçu O, Sözen T, Süslü AE. Endoscopic Z-plasty for Treatment of supraglottic stenosis: A new technique. *Otolaryngol Head Neck Surg*. 2015; 153(6): 1064-1066. doi: 10.1177/0194599815607201

2. Zoghbi Y, Hachem RA, Wood JW, Rosow DE. Technical nuances for endoscopic management of complete supraglottic stenosis. *Ann Otolaryngol Rhinol.* 2016; 3(1): 1083. Web site. https://www.jscimedcentral.com/Otolaryngology/otolaryngology-3-1083.pdf. Accessed September 28, 2016.

3. Freitas VA, Becker HM, Guimarães RE, et al. Cicatricial pemphygoid in the upper aerodigestive tract: Report of two cases. *Braz J Otorhinolaryngol.* 2008; 74(6): 941-944. doi: 10.1590/S0034-72992008000600020

4. Gilad R, Milillo P, Som PM. Severe diffuse systemic amyloidosis with involvement of the pharynx, larynx, and trachea: CT and MR findings. *AJNR Am J Neuroradiol.* 2007; 28(8): 1557-1578. Web site. http://www.ajnr.org/content/28/8/1557.long. Accessed September 28, 2016.

5. Tantinikorn W, Sinrachtanant C, Assanasen P. How to overcome laryngotracheal stenosis. *J Med Assoc Thai.* 2004; 87(7): 800-809.

6. Kim IA, Long J. Laryngotracheal stenosis as a complication of photodynamic therapy. *Ann Otol Rhinol Laryngol.* 2015;

124(6): 495-498. doi: 10.1177/0003489415570930

7. Nair S, Nilakantan A, Sood A, Gupta A, Gupta A. Challenges in the management of laryngeal stenosis. *Indian J Otolaryngol Head Neck Surg*. 2016; 68(3): 294-299. doi: 10.1007/s12070-015-0936-2

8. Pegg D, Kanatas A, Makura Z. Idiopathic acquired supraglottic web: A case report. *Ear Nose Throat J.* 2011; 90(10): 486-488. Web site. http://search.proquest.com/openview/af5c1231ebc6497363d3cf5b72938c7e/1.pdf?pq-origsite=gscholar&cbl=47886. Accessed September 28, 2016.

9. Lasisi AO, Adeyemo A. Improvized laryngeal cautery forcep in microsurgical treatment of laryngotracheal stenosis--experience in Nigeria, sub-Saharan Africa. *Afr J Med Med Sci.* 2007; 36(2): 163-167. Web site. http://europepmc.org/abstract/med/19205580. Accessed September 28, 2016.

10. Krishna PD, Malone JP. Isolated adult supraglottic stenosis: Surgical treatment and possible etiologies. *Am J Otolaryngol*. 2006; 27(5): 355-357. doi: 10.1016/j.amjoto.2005.11.021

11. Saad C, Mehta A. Case report: Supraglottic stenosis. *J Bronchology.* 2003; 10(2):142-143.

12. Oosthuizen JC, Burns P, Russell JD. Endoscopic management of posttraumatic supraglottic stenosis in the pediatric population. *Am J Otolaryngol.* 2011; 32(5): 426-429. doi: 10.1016/j.amjoto.2010.07.024

13. Rubino SM, Pitman MJ. Endoscopic management of severe supraglottic and posterior glottic stenosis due to chemotherapy and radiation. *International Journal of Otolaryngology and Head & Neck Surgery*. 2014; 3: 133-136. doi: 10.4236/ijohns.2014.33024

14. Sinacori JT, Taliercio SJ, Duong E, Benson C. Modalities of treatment for laryngotracheal stenosis: The EVMS experience. *Laryngoscope.* 2013; 123(12): 3131-3136. doi: 10.1002/lary.24237

15. Kiniwa Y, Ashida A, Ohashi A, et al. A case of epidermolysis bullosa acquisita associated with laryngeal stenosis. *Acta Derm Venereol.* 2012; 92(1): 93-94. doi: 10.2340/00015555-1163

16. Lyons GD, Owens R, Lousteau RJ, Trail ML. Carbon dioxide laser treatment of laryngeal stenosis. *Arch Otolaryngol*. 1980; 106(5): 255-256. doi: 10.1001/archotol.1980.00790290007003

17. Davis RK, Kriskovich MD, Galloway EB 3rd, Buntin CS, Jepsen MC. Endoscopic supraglottic laryngectomy with postoperative irradiation. *Ann Otol Rhinol Laryngol.* 2004; 113(2): 132-138. doi: 10.1177/000348940411300210

18. Duncavage JA, Ossoff RH, Toohill RJ. Carbon dioxide laser management of laryngeal stenosis. *Ann Otol Rhinol Laryngol.* 1985; 94(6 Pt 1): 565-569. Web site. http://europepmc.org/abstract/med/4073733. Accessed September 28, 2016.

19. Doyle PJ. Repair of supraglottic laryngeal stenosis with postcricoid Involvement: A case report. *Ann Otol Rhinol Laryngol*. 1980; 89(6 Pt 1): 576-577. doi: 10.1177/000348948008900620

20. Minni A, Gallo A, Croce A, Moretti A, Vincentiis MD. Leroux-Robert-Huet'slaryngectomy for supraglottic stenosis. *Laryngotracheal Reconstruction*. 1992; 3(3): 194-198. doi: 10.1016/S1043-1810(10)80179-4

21. Canis M, Martin A, Ihler F, et al. Results of transoral laser microsurgery for supraglottic carcinoma in 277 patients. *Eur Arch Otorhinolaryngol.* 2013; 270(8): 2315-2326. doi: 10.1007/s00405-012-2327-6

22. Grant DG, Salassa JR, Hinni ML, Pearson BW, Hayden RE, Perry WC. Transoral laser microsurgery for carcinoma of the supraglottic larynx. *Otolaryngol Head Neck Surg.* 2007; 136(6): 900-906. doi: 10.1016/j.otohns.2006.12.015

23. Alon EE, Kasperbauer JL, Olsen KD, Moore EJ. Feasibility of transoral robotic-assisted supraglottic laryngectomy. *Head Neck.* 2012; 34(2): 225-229. doi: 10.1002/hed.21719

24. Izadi F, Ahmadi A, Zobairy H, Bakhti S, Hirbod H, Safdarian M. Fraser syndrome with laryngeal webs: Report of two cases and a review of the literature. *Int J Pediatr Otorhinolaryngol.* 2015; 79(11): 1959-1962. doi: 10.1016/j.ijporl.2015.08.043

25. Moore JE, Capo J, Hu A, Sataloff RT. Management of supraglottic stenosis using a novel stent design. *J Voice.* 2014; 28(4): 515-517. doi: 10.1016/j.jvoice.2013.12.018

26. Kacker A, Deka RC, Chatterjee TK. Surgical management of supraglottic stenosis. *Indian J Otolaryngol Head Neck Surg.* 1993; 45: 128. doi: 10.1007/BF03054712

27. Sunderrajan EV, Davenport J. The Guillain-Barré syndrome: Pulmonary-neurologic correlations. *Medicine (Baltimore).* 1985; 64(5): 333-341. Web site. http://journals.lww.com/md-journal/Citation/1985/09000/The_Guillain_Barre_Syndrome__Pulmonary_Neurologic.5.aspx. Accessed September 28, 2016.

28. Stevens MS, Chang A, Simpson CB. Supraglottic stenosis: Etiology and treatment of a rare condition. *Ann Otol Rhinol Laryngol.* 2013; 122(3): 205-209. doi: 10.1177/000348941312200310

29. Mistry SG, Watson GJ, Rothera MP. Balloon dilatation to treat plasmacytosis of the supraglottic larynx. *J Laryngol Otol.* 2012; 126(10): 1077-1080. doi: 10.1017/S0022215112001922

30. Rubinstein M, Boyd JW, Wu EC, Fine EL, Wong, BJF, Crum-

ISSN 2470-4059 Open Journal http://dx.doi.org/10.17140/OTLOJ-2-129

ley RL. Supraglottic stenosis caused by tuberculosis: A case report. *Laryngoscope.* 2011; 121: S178. doi: 10.1002/lary.22060

31. Belloso A, Estrach C, Keith AO. Supraglottic stenosis in localized Wegener granulomatosis. *Ear Nose Throat J.* 2008; 87(7): E11-E14. Web site. http://web.a.ebscohost.com/abstract?direct=true&profile=ehost&scope=site&authtype=crawler&jrnl=01455613&AN=48872765&h=pw5%2fb5nISuDsScisabYEqPit%2f%2fqAg5PkIeKRMNVb9MCAkUn1ZzpXXNrvJKfv%2fle%2fE1QNySZmfYu5hu1DMhB%2fkQ%3d%3d&crl=c&resultNs=AdminWebAuth&resultLocal=ErrCrlNotAuth&crlhashurl=login.aspx%3fdirect%3dtrue%26profile%3dehost%26scope%3dsite%26authtype%3dcrawler%26jrnl%3d01455613%26AN%3d48872765. Accessed September 28, 2016.

32. Héctor BS, Delano RPH, Nicolás AA, Valdes PC. Constanza. Penfigoidecicatricial, causapococomún de estenosissupraglótica [In Spanish]. *Rev Otorrinolaringo Cir Cabeza Cuello.* 2008; 68(3): 288-294. doi: 10.4067/S0718-48162008000400010

33. Sims HS, Thakkar KH. Airway involvement and obstruction from granulomas in African-American patients with sarcoidosis. *Respir Med.* 2007; 101(11): 2279-2283.

34. Ma L, Bandarchi B, Sasaki C, Levine S, Choi Y. Primary localized laryngeal amyloidosis: Report of 3 cases with long-term follow-up and review of the literature. *Arch Pathol Lab Med.* 2005; 129(2): 215-218. Web site. http://www.archivesofpathology.org/doi/10.1043/1543-2165(2005)129%3C215:PLLARO%3E2.0.CO;2?url_ver=Z39.88-2003&rfr_id=ori:rid:crossref.org&rfr_dat=cr_pub%3dpubmed. Accessed September 28, 2016.

35. Kaneko K, Komazawa O, Takahashi H. Idiopathic supraglotticstenosis: A report of three cases. *jibi to rinsho-J-Stage.* 2015; 61(5): 194-199. doi: 10.11334/jibi.61.5_194

36. Vira D, DeConde A, Chhetri DK. Endoscopic management of supraglottic laryngopharyngeal stenosis. *Otolaryngol Head Neck Surg.* 2012; 146(4): 611-613. doi: 10.1177/0194599811431684

OTOLARYNGOLOGY

Openventio PUBLISHERS

ISSN 2470-4059 Open Journal http://dx.doi.org/10.17140/OTLOJ-2-130

Systematic Review

*Corresponding author
Omar Ramadan, PhD
ENT Registrar
Independent Researcher
Paterson, NJ 07533, USA
Tel. +1 973 563 9283
E-mail: omarram982@hotmail.com

Volume 2 : Issue 5
Article Ref. #: 1000OTLOJ2130

Article History
Received: October 8th, 2016
Accepted: October 19th, 2016
Published: October 20th, 2016

Citation
Ramadan O. Laryngeal histoplamosis overview. *Otolaryngol Open J.* 2016; 2(5): 141-149. doi: 10.17140/OTLOJ-2-130

Laryngeal Histoplamosis Overview

Omar Ramadan, PhD*

Independent Researcher, Paterson, NJ 07533, USA

ABSTRACT

Objective: The objective of this study was to present a review article about laryngeal histoplasmosis.
Data Sources: Published English-language literatures in PubMed and Google scholar.
Review Methods: PubMed and Google scholar were systematically searched using search terms: laryngeal and histoplasmosia.
Study Selection: We included studies about laryngeal histoplasmosis.
Results: Forty studies were included in this study. The results showed that most patients are male over 40 years old, and most cases were reported from endemic areas. Hoarseness dysphagia and general symptoms were the common symptoms of laryngeal histoplasmosis. Laryngeal mass was the most common finding during laryngeal exam. Itracanzole was the most common medication used to treat this disease. Laryngeal histoplasmosis had a good prognosis, but some cases may need long-term treatment up to 1 year.
Conclusion: Histoplasmosis is a rare fungal granulomatous disease that may mimic laryngeal malignancy or tuberculosis.

INTRODUCTION

Primary laryngeal histoplasmosis is a rare disease. Less than 100 cases of laryngeal histoplasmosis have been reported in English literatures since it was first described in 1940 by Brown and colleagues. The clinical symptoms and signs may mimic tuberculosis or laryngeal malignancy.[1]

MATERIAL AND METHODS

Literature review was conducted using PubMed (MEDLINE) and Google Scholar for English articles. The following keywords were used: laryngeal and histoplasmosis.

INCLUSION CRITERIA

All laryngeal histoplasmosis articles published after 1984 were included in the study.

RESULTS

Forty studies about laryngeal histoplasmosis were available in PubMed (MEDLINE) and Google scholar in English literature (Table 1).

Demographs

There were 51 patients of age ranged from 7 to 73 with majority of the patients over 40 years old. There were 43 males and 8 females in the study Chart 1 and 2.

Symptoms

Forty-two patients had hoarseness (82%), 33 patients had difficulty swallowing (64%) (odynophagia, dysphagia, sore throat or globus), 9 patients had difficulty in breathing (17%) (stridor or

ISSN 2470-4059 Open Journal http://dx.doi.org/10.17140/OTLOJ-2-130

Articles	Sex	Age	History	Clinical exam	Associated diseases	Treatment	Risk factor
Subramaniam et al[1]	M	52	Hoarseness, Cough, Weight loss, Fatigue, Sore throat	Irregular left vocal cord mass extending to the anterior commissure	None	Amphotericin then ketoconazole for 1 month	DM Smoker
Ghosh et al[2]	M	50	Dysphonia, Dysphagia, General, Symptom	General laryngeal inflammation, Right vocal cord ulcerated nodules	Disseminated	Amphotericin then itra-conazole for 8 weeks	Smoker
Robayo et al[3]	M	7	Diarrhea, Sore throat, Fever, Headache, Stridor	Granulomatous supraglottic mucosa which deforms the epiglottis and partially obstructs the airway	None	Amphotericin then changed to Itraconazole for 12 months	Immunosuppressant medication
Pervez Katoch et al[4]	M	20	Dysphagia	Friable growth in the cricoid region subglottic	Pharyngeal	Fluconazole with complete remession	Endemic
John et al[5]	M	53	Fever, Cough, Weakness, Hoarseness	Multiple ulcers on the laryngeal surface of the epiglottis and the vocal cords	Pulmonary Adrenal gland	Voriconazole treatment for 1 year	Smoker Endemic
Carter et al[6]	F	73	Weight loss, Hoarseness, Dysphagia, Stridor	Multiple exophytic ulcer nodular lesions across the laryngeal epiglottis and vocal folds	None	Gastrostomy, Tracheostomy, Itraconzole for 2 months	Seropositive RA
Giménez et al[7]	M	55	Fever	Erythematous keratinizing mass In both vocal cord	None	itraconzole	Smoker Cirrhosis
O'Hara et al[8]	M	78	Weightloss, Dysphagia, Night sweats	The superior right free edge of the epiglottis showed an irregular mass with focal ulceration	Pulmonary	Itraconazole for 9 months	Travel
Bist et al[9]	M	62	Mouth swelling, Hoarseness	Multiple exophytic nodular lesions across the oropharynx, endolarynx and hypopharynx	Oral lesions Pharyngeal	Amphotericin then oral itraconazolefor 3 weeks	Endemic Smoker
Teoh et al[10]	M	70	Weightloss, Hoarseness, Dysphagia	Showed that the mucosae at the posterior one-third of both vocal folds were irregular	Pulmomary	Amphotericin then oral itraconazole for 5 months	DM Smoker
Masoud et al[11]	M	60	Hoarseness	Ulcerative growth in the left vocal cord	None	Amphotericin then oral itraconazole for 12 weeks	TB Endemic
Solari et al[12]	M	48	Weightloss, Hoarseness, Dysphagia, Stridor, Dyspnea Cough, Weightloss,	Epiglotitis, enlargement and mobile vocal cords with granulomatous lesions deforming and infiltrating the glottis and subglottis	Disseminated histoplasmosis	Amphotericin then oral itraconazole with clinical improvement in 1 month	AIDS
Ahumadau et al[13]	M	70	Dyspnea, Hoarseness, Dysphagia, Odynophagia, Fatigue, Anorexia, Weight loss	Vegetative lesion on the lingual surface of the epiglottis	Pharyngeal	amphotericin B then itraconazole for 12 months	Smoking Immunosuppressant drugs Travel
Smeets et al[14]	M	58	Weightloss, Hoarseness, Dysphagia	The vocal process was thickened. granulation tissue on right ventricular area	None	Itraconazole for 4 week	Travel
Bouldouyre et al[15]	M	65	Hoarseness	Non-specific inflammatory changes in right vocal cord, edema and hypertrophic vocal cord	Pulmonary	Itraconazole for 6 months	Travel TB smoking

ISSN 2470-4059 Open Journal http://dx.doi.org/10.17140/OTLOJ-2-130

Mackowiak et al[16]	M	55	Weight loss Hoarseness Dysphagia	Yellowish, edematous mucosal changes in the inter-arytenoid region involving the posterior part of the vocal cords	Disseminated histoplasmosis	itraconazole for 2 months	Addison's disease DM
Fechner et al[17]	M	44	Sore throat Hoarseness, Dysphagia	The vocal cords were swollen and covered with a thin white exudate.	None	Amphotericin	-
Donegan et al[18]	M	69	Weight loss, Hoarseness, Dysphagia	Left large epiglottic and glottis mass	None	Amphotericin for 6 weeks	-
Sonkhya et al[19]	8 M 2 F	2 (30) 4 (40) 4 (50)	Weightloss, Hoarseness, Dysphagia	Endophytic growth in 6 cases, exophytic growth in 2 cases and ulcer-ative lesion in 2 cases. False cord and aryepiglottic fold was the common site of involvement (6 cases). Epiglottis involvement was seen in 3 cases and only 1 case was with postcricoid and subglottic lesion.	One case pharyngeal	There were no signs of pulmonary or systemic involvement Amphotericin in 3 cases. Itraconazole in 7 cases. for 6 months	10 patients from endemic area
Cairoli et al[20]	F	35	Hoarseness and sore throat	Whitish nodular lesions in the arytenoid cartilage and vocal cords	Paranasalsinus pulmonary	amphotericin followed by itraconazole for 8 months.	SLE
Larbcharoensub et al[21]	F	39	Hoarseness for eleven months	Glottic mass	Pharyngeal oral cavity	Amphotericin B dead	SLE
Gulati, et al[22]	M	47	Hoarseness Painful ulcer tongue	Exophytic lesion (epiglottis and glottis)	Oral lesion	Itraconazole for 6 weeks	Endemic
	M	45	Hoarseness	Exophytic lesion was noted on the anterior aspect of both vocal cords	Oral cavity	Itraconazole for 6 week	Endemic
Troncoso et al[23]	M	30	Dysphagia, Dyspnea, Stridor, Fever	Indurated Glottis, supraglottic And Subglottic mass	Heptospleno-megaly	Amphotericin followed by Itraconzale for 12 months	AIDS
Le et al[24]	M	58	Hoarseness, Dysphagia, Weightloss	Ulcerated mass that involved the left pyriform sinus and supraglottic space	Pharyngeal	Amphotericin then itraconzale	Smoking Diabetes
Sane et al[25]	M	55	Weight loss, Anorexia, Fever	Vocal cord paresis and edema with small irregular nodule on the right vocal cord	Disseminated	Amphotericin B for 1 year	Endemic
Larsen et al[26]	M	63	SOB Sore throat Fever weight loss stridor Hoarseness	Ulcerative mass supraglottic edema glottic	Pulmonary	Tracheostomy gastrostomy tube amphotericin patients was decanulated	Smoking Rheumatoid arthritis
Sataloff et al[27]	F	44	Hoarseness	Laryngitis. non-specific changes in all larynx	None	Treatment with oral ketoconazole was instituted	-
Ragah et al[28]	M	55	Hoarseness, Dysphagia, General symptom	Supraglottic glottis ulcer	Oral cavity Pharyngeal	Treatment with amphotericin B resulted in a rapid recovery	Endemic TB
Klein et al[29]	M	37	Hoarseness, Vague throat pain, Weightloss, SOB stridor	Destructive supraglottic lesion. The lesion was exophytic, extending down to the true vocal folds	Oral cavity	Tracheotomy, Itraconazle for 13 week	Smoking
Fernández Liesa et al[30]	M	-	Hoarseness	Edema, erythema and leukoplakia of the right vocal cord	None	Itraconazole treatment was successful	Smoker Travel
Yen et al[31]	F	46	Dysphonia	Epiglottic mass	Disseminated	Amphotericin then Itraconazole death	-

ISSN 2470-4059 Open Journal http://dx.doi.org/10.17140/OTLOJ-2-130

Coiffier et al[32]	M	10	General symptoms	Ulcerated pharyngo-laryngeal lesions	Disseminated	Amphotericin B then oral itraconazole	Endemic
Postma et al[33]	M	54	SOB, Globus, Hoarsness	Verrcous mass anterior third left vocal cord	Esophagus Pharyngeal	Itraconazole 1 year	-
Alcurra et al[34]	M	61	Oral ulcer Weightloss Fever	Multiple laryngeal, glottis ulcer	Oral cavity Esophagus	Itraconazole 2 months	Smoker
Samuel et al[35]	M	60	Sore throat	Supraglottic ulcer	Pharyngeal Pulmonary	Micronazole for 1 month oral cavity	-
Rajagobal et al[36]	M	72	Dysphagia, Dysphonia, Weightloss	Supraglottic, glottic and subglottic mass	Pharyngeal	Intubated, 1 year itraconazole	Smoker
Zain et al[37]	M	63	Hoarseness, Dysphagia, General, Symptoms	Glottis and Supraglottic mass	Oral cavity	Amphotericin	Addison Disease
Wolf et al[38]	M	60	Hoarseness, Dyspnea	Glottic mass	Pulmonary	Amphotericin	-
César Garcia de Alencar et al[39]	F	25	Fever, Nausea, Weightloss, Hoarseness	Ulcerated mass in the glottis space	None	Amphotericin B patient died of cardiovascular complications	Larynx tuberculosis
Pochini Sobrinho et al[40]	M	44	Dysphonia, Dysphagia, Sore throat, Weightloss	White necrotic lesion spread throughout his larynx, exophytic lesion in the upper right border of the epiglottis	None	Amphotericin B then fluconazole	AIDS

Table 1: Articles included in the study.

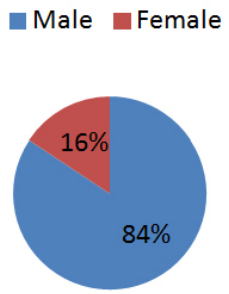

Chart 1: M/F rate.

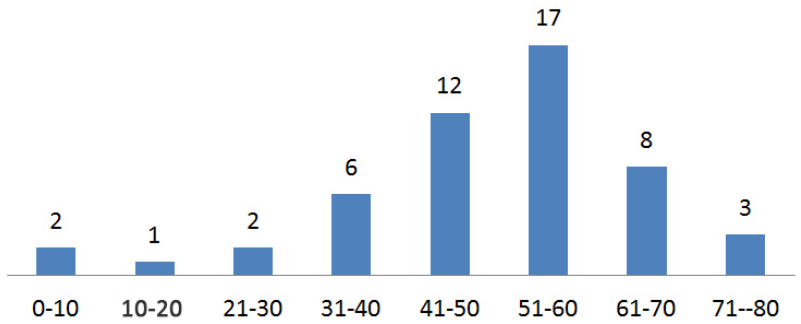

Chart 2: Age distribution.

dyspnea) and 36 patients had general symptoms (70%) (fever, night sweat and weight loss) Chart 3A.

Laryngeal Exam

Seventeen patients had laryngeal histoplasmosis in glottic area, 17 patients had laryngeal histoplasmosis in supraglottic area, and 2 patients had laryngeal histoplasmosis in subglottic area, while the other 15 patients had laryngeal histoplasmosis in multiple laryngeal areas Chart 3B.

Clinical laryngeal exam revealed the presence of a mass in 22 patients, ulcerated mass in 8 patients, nodule in 4 patients, granuloma in 4 patients, ulcer in 7 patients, ulcerated mass in 8 patients and other forms (keratosis, thickness and irregularity of vocal cord, leukoplakia and inflammation) in 6 patients (Chart 4).

RISK FACTORS

Twenty patients were living in endemic area, 6 patients had history of travelling to endemic area, 12 patients were smokers, 3 patients had AIDS, 5 patients had a history of Tuberculosis, 3 patients had endocrinology diseases (DM, Addison disease), 4 patients had rheumatology diseases, 2 patients were on immunosuppressant medications and one patient had hepatic cirrhosis (Table 2).

Associated Another Area Involvement

Eleven patients had histoplasmosis in pharynex (23%), 8 patients had histoplasmosis in pulmonary tract, 7 patients hadhistoplasmosis in oral caviy (17%), 4 patients had hsitoplasmosis in other organs (9%) (esophagus, nose, liver) and, 6 patients had

ISSN 2470-4059 Open Journal http://dx.doi.org/10.17140/OTLOJ-2-130

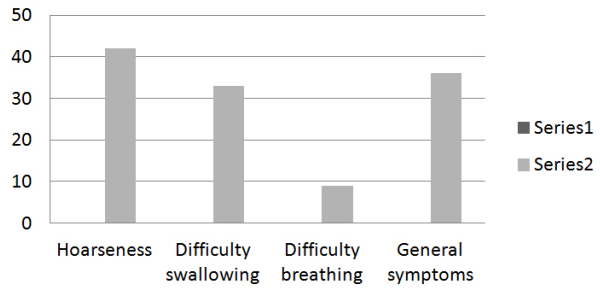

Chart 3A: Histoplasmosis laryngeal symptoms.

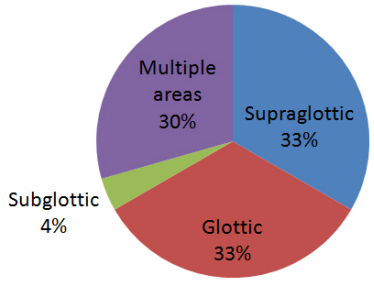

Chart 3B: Histoplasmosis laryngeal locations.

disseminated histoplasmosis disease (13%) Chart 5.

Treatment

Nine patients received only IV amphotericin, 15 patients received IV amphotericin followed by itraconazole, and 22 patients received only azole medications Table 3.

Only 36 articles reported treatment period that vary from 1 month to 12 months, the treatment should be continued until the symptoms improve and the physical exam did not reveal the presence of laryngeal histoplasmosis (Chart 6).

Prognosis

3 patients were dead, while the other 48 patients improved, no recurrence were reported.

DISCUSSION

Histoplasmosis is a worldwide distribution granulomatous disease that is caused *Histoplasma capsulatum* which is a dimor-

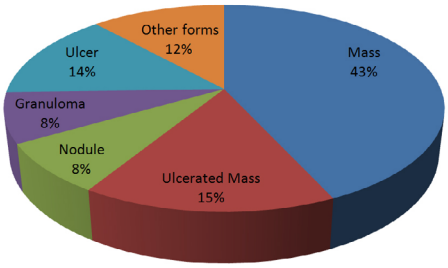

Chart 4: Clinical exam presentation.

Endemic	Travel	Smoking	AIDS	TB	Endocrinology diseases	Rheumatology diseases	Medications	Cirrhosis
20	5	12	3	5	3	4	2	1

Some patients had multiple risk factors

Table 2: Number of patients having risk factors.

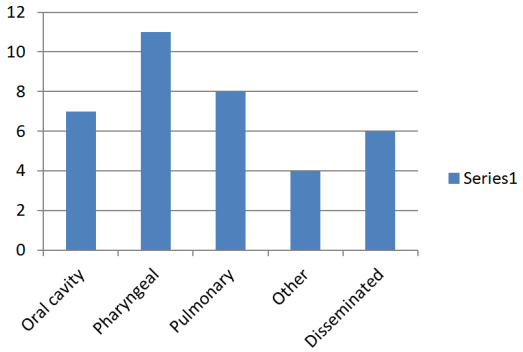

Chart 5: Histoplasmosis associated with other areas.

ISSN 2470-4059 Open Journal http://dx.doi.org/10.17140/OTLOJ-2-130

Amphotericin	Azole medications	Amphotericin+itraconazole	Dead
9/51	24/51	15/51	3/51

3 patients had a temporary tracheostomy, 2 patients had temporary gastrostomy tube.3 patients were dead

Table 3: Treatment modalities.

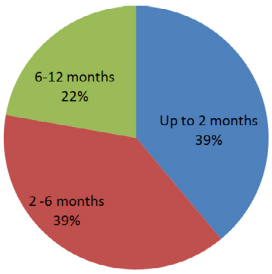

Chart 6: Treatment period.

phic intracellular fungus.[1]

The fungus usually exists in the mycelial phase at room temperature. However once the spores are inhaled, the spores transform to the yeast phase which is responsible for the human infection and which leads to pulmonary infection that may be complicated by haematogenous spread to other organs. Primary pulmonary histoplasmosis is usually asymptomatic but chronic pulmonary histoplasmosis is clinically similar to pulmonary tuberculosis.[1]

The clinical scenario of ranges from a mild infection localized to the gastrointestinal tract, skin, larynx or other extra pulmonary sites to severe disseminated multisystem disease that involve the bone marrow, liver, spleen and lungs.

The most common clinical presentation of laryngeal histoplasmosis is secondary to chronic disseminated histoplasmosis as a result of haematogenous spread. There are a few reports of sporadic primary laryngeal histoplasmosis cases.

The degree of infection is determined by the size of the inoculum and prior immune status of the host. It is often associated with general symptoms such low grade fever, weight loss and fatigue. Other symptoms of laryngeal histoplasmosis may include hoarseness, dysphagia, sore throat, cough and occasionally stridor.[1]

It is known that macrophages are the major targets of *H. capsulatum*. The fungal surface heat shock protein 60 (hsp60) binds to alpha 2 integrins on macrophages surface. So macrophages are induced by this binding to secrete Tumor Necrosis Factor (TNF) which stimulates and recruits other macrophages to kill the histoplasma.[41]

Laryngeal involvement is usually observed in disseminated histoplasmosis. Goodwin et al[42] observed that 66% of patients with chronic pulmonary histoplasmosis and 31% with subacute pulmonary histoplasmosis developed laryngeal disease. Involvement of the larynx was observed in only 19% of patients with acute disseminated histoplasmosis.[43]

Chest radiography, sputum and urine cultures and bone marrow aspiration biopsy should be done in any laryngeal histoplasmosis case to look for disseminated disease.[39]

Clinical presentations of the laryngeal histoplasmosis include granulomas, ulceration, nodular ulcerative lesions, and verrucous and plaque-like lesions.[39]

Histoplasmosis affects 4% to 5% of patients with AIDS, on whom it generally causes acute or subacute clinical disease with disseminated illness. These presentations of the infection takes place in patients with CD4 T-cell counts lower than 200 cells/µl.[39]

In the biopsy, it can be observed with hematoxylin-eosin granulomatous tissue, necrosis, and infiltration of giant cells, lymphocytes, plasma cells and many macrophages. By using special stains such as coloring Gomorimethenamine-silver, coloring periodic acid-schiff (PAS) staining or Gridley technique[40] to identify macrophages and these cell containing hyphae.

Macroscopically, histoplasmosisshouldbe differentiated from syphilis, tuberculosis, carcinoma, mid-line granuloma, mucormycosis, lymphoma,and other granulomatous diseases.[40]

Anti-histoplasma serological tests using complement fixation and immune-diffusion methods are positive in about 90% of immune-competent patients and 70% of immune-compromised patients. Antibody tests may be false negative in immune-compromised patients. The antibodies usually start to appear during the second month after exposure in acute phase, and they may remain positive for several years.[44]

The treatment of laryngeal histoplasmosis is similar to

ISSN 2470-4059 Open Journal http://dx.doi.org/10.17140/OTLOJ-2-130

the other forms of the disease. Although it is usually benign, histoplasmosis can be disseminated and cause severe fatal disease. Treatment of choice is IV amphotericin B, 0.3-0.6 mg/kg of body weight per day, with a maximum dose of 2-4 mg. Mucosal laryngeal lesions respond within 6-8 weeks, recurrences may occur. Itraconazole is an alternative treatment for laryngeal histoplasmosis. It is given orally 100 mg daily until clinical cures is achieved and then change the treatment regimen to 50 mg/day for 6 more months.[44]

CONCLUSION

Laryngeal histoplasmosis is more common in male, most patients are over 40 year old and native or have a history of traveling to endemic area. It is usually associated with pharyngeal or pulmonary involvement. There is no specific laryngeal location for it, hoarseness is the most common symptom and mass (non-ulcerated or ulcerated) is the most common clinical finding during laryngeal exam. Treatment is by amphotericin, itraconzale or both. Some patients may need tracheostomy to relieve acute respiratory obstruction or gastrostomy tube for feeding. Prognosis is usually good with a few fatal cases in disseminated disease.

ACKNOWLEDGEMENTS

The authors wish to acknowledge John Cotton Dana Library, NJ, USA, for their kind help to get the reference papers.

CONFLICTS OF INTEREST

The author declare that he have no conflicts of interest.

REFERENCES

1. Subramaniam S, Abdullah AH, Hairuzah I. Histoplasmosis of the larynx. *Med J Malaysia*. 2005; 60(3): 386-388. Web site. http://www.e-mjm.org/2005/v60n3/Histoplasmosis.pdf. Accessed October 7, 2016.

2. Ghosh R, Mishra P, Sen S, Maiti PK, Chatterjee G. Experience of varied presentation of chronic progressive disseminated histoplasmosis in immunocompetent patients: A diagnostic conundrum. *Indian J Dermatol*. 2016; 61(5): 580. doi: 10.4103/0019-5154.190128

3. Oriones Robayo CA, Guerra Ortiz CP. Histoplasmosis laryngeal: Report first case in Colombia. *Colomb Med (Cali)*. 2014; 45(4): 186-189.

4. Pervez K, Subash B. Primary laryngeal histoplasmosis. *JK Science Journal of Medical Education and Research*. 2009; 11(2): 89-90.

5. John M, Koshy JM, Mohan S, Paul P. Histoplasmosis presenting as a laryngeal ulcer in an immunocompetent host. *J Assoc Physicians India*. 2015; 63(6): 69-71. Web site. http://japi.org/june_2015/13_cr_histoplasmosis.pdf. Accessed October 7, 2016.

6. Carter JM, Williams K, Moore BA. Histoplasmosis of the larynx. *J Laryngol Voice*. 2013; 3: 64-66. doi: 10.4103/2230-9748.132059

7. Giménez A, Zijlstra P, Ivars AE, Irastorza C. Histoplasmosis laryngeal. *Casuistry*. Web site. www.hpc.org.ar/images/revista/722-R18_59-60.pdf. Accessed October 7, 2016.

8. O'Hara CD, Allegretto MW, Taylor GD, Isotalo PA. Epiglottichistoplasmosis presenting in a nonendemic region: A clinical mimic of laryngeal carcinoma. *Arch Pathol Lab Med*. 2004; 128(5): 574-577.

9. Bist SS, Agrawal V, Shirazi N, Luthra M. Primary oropharyngeal and laryngeal histoplasmosis - A diagnostic challenge. *Online J Health Allied Scs*. 2015; 14(3): 12. Web site. http://www.ojhas.org/issue55/2015-3-12.html. Accessed October 7, 2016.

10. Teoh JW, Hassan F, Mohamad Yunus MR. Laryngeal histoplasmosis: An occupational hazard. *Singapore Med J*. 2013; 54(10): e208-e210. doi: 10.11622/smedj.2013184

11. Masud MK, Ahmad SM, Ferdouse F, et al. Laryngeal histoplasmosis. *Mymensingh Med J*. 2014; 23(3): 566-571. Web site. http://europepmc.org/abstract/med/25178612. Accessed October 7, 2016.

12. Solari R, Corti M, Cangelosi D, et al. Disseminated histoplasmosis with lesions restricted to the larynx in a patient with AIDS. Report of a case and review of the literature. *Rev Iberoam Micol*. 2007; 24(2): 164-166. Web site. http://www.pubpdf.com/pub/17604440/Disseminated-histoplasmosis-with-lesions-restricted-to-the-larynx-in-a-patient-with-AIDS-Report-of-a. Accessed October 7, 2016.

13. Ahumada F, Pérez D, de Górgolas M, et al. Subacutehistoplasmosis with focal involvement of the epiglottis: Importance of differential diagnosis. *Case Rep Otolaryngol*. 2014; 2014: 235975. doi: 10.1155/2014/235975

14. Smeets LC, Lestrade PJ, de Visscher AV, Schneeberger PM. Hoarseness in a recent visitor to the tropics through infection of the larynx by Histoplasmacapsulatum. *Ned Tijdschr Geneeskd*. 2005; 149(12): 657-659.

15. Bouldouyre MA, Roux D, Lacroix C, Meignin V, Molina JM. Histoplasmacapsulatum granulomatous laryngitidis. *Med Mal Infect*. 2010; 40(10): 602-604. doi: 10.1016/j.medmal.2010.03.004

16. Mackowiak PA. Photo quiz: A well-preserved culprit. *Clin Infect Dis*. 2013; 56(5): 704, 747-748. doi: 10.1093/cid/cis907

17. Fechner RE. Pathologic quiz case 1: Histoplasmosis. *Arch Otolaryngol*. 1981; 107(12): 776-778.

18. Donegan JO, Wood MD. Histoplasmosis of the larynx. *Laryngoscope*. 1984; 94(2 Pt 1): 206-209. doi: 10.1288/00005537-198402000-00011

19. Sonkhy A, Mehta R, Sonkhya D, Gupta S, Faujda M. Primary histoplasmosis of larynx: A case series and review of literature nishi. *International Journal of Otolaryngology and Head & Neck Surgery*. 2013; 2: 47-51. doi: 10.4236/ijohns.2013.22012

20. Cairoli E, Tafuri J, Olivari D. Laryngeal histoplasmosis in systemic lupus erythematosus: first reported case. *Lupus*. 2010; 19(11): 1354-1355. doi: 10.1177/0961203310375267

21. Larbcharoensub N, Kanoksilp W, Wirojtananugoon C, et al. Oropharyngolaryngeal sarcocystosis and histoplasmosis co-infection in a patient with systemic lupus erythematosus. *Diagn Pathol Open*. 2016; 1: 117.

22. Gulati SP, Gupta A, Wadhera R, Deep A, Kalra R. Histoplasmosis of larynx in immunocompetent patients mimicking carcinoma report of two cases. *J Infect Dis Antimicrob Agents*. 2008; 25: 145-149.

23. Troncosoa A, Gulottaa H, Olenchucka A, Bavab J. Histoplasmosis laríngea como manifestación de SIDA [In Portuguese]. *Enferm Infecc Microbiol Clin*. 2003; 21(5): 273-278. doi: 10.1016/S0213-005X(03)72935-8

24. Le K, Daroca PJ Jr, Palacios E. Laryngeal histoplasmosis as a mimicker of squamous cell carcinoma: Imaging and histologic findings. *Ear Nose Throat J*. 2007; 86(11): 662, 664.

25. Sane SY, Patel MG, Patel BM, Kokal KK. Disseminated histoplasmosis (a case report). *J Postgrad Med.* 1983; 29(4): 270-273. Web site. http://www.jpgmonline.com/article.asp?issn=0022-3859;year=1983;volume=29;issue=4;spage=270;epage=3;aulast=Sane. Accessed October 7, 2016.

26. Larsen CG, Militsakh O, Fang F, Tawfik O, Wallace DI. Histoplasmosis presenting as upper airway obstruction. *Otolaryngol Head Neck Surg*. 2005; 132(3): 514-516. doi: 10.1016/j.otohns.2004.04.034

27. Sataloff RT, Wilborn A, Prestipino A, Hawkshaw M, Heuer RJ, Cohn J. Histoplasmosis of the larynx. *Am J Otolaryngol*. 1993; 14(3): 199-205. doi: 10.1016/0196-0709(93)90030-B

28. Rajah V, Essa A. Histoplasmosis of the oral cavity, oropharynx and larynx. *J Laryngol Otol*. 1993; 107(1): 58-61. doi: 10.1017/S0022215100122169

29. Klein AM, Tiu C, Lafreniere D. Malignant mimickers: Chronic bacterial and fungal infections of the larynx. *J Voice*. 2005; 19(1): 151-157. doi: 10.1016/j.jvoice.2004.10.004

30. Fernández Liesa R, Pérez Obón J, Ramírez Gasca T, Marín-García J, Ortiz García A, Calvo Alvarez A. Laryngeal histoplasmosis. *Acta Otorrinolaringol Esp*. 1995; 46(6): 453-456.

31. Tai YF, Kullmann DM, Howard RS, et al. Central nervous system histoplasmosis in an immunocompetent patient. *J Neurol*. 2010; 257(11): 1931-1933. doi: 10.1007/s00415-010-5629-x

32. Coiffier T, Roger G, Beust L, et al. Pharyngo-laryngeal histoplasmosis: One case in an immunocompetent child. *Int J Pediatr Otorhinolaryngol*. 1998; 45(2): 177-181. doi: 10.1016/S0165-5876(98)00099-8

33. Postma GN, Belafsky PC, Koufman JA. Laryngeal and esophageal histoplasmosis. *Ear Nose Throat J*. 2001; 80(10): 702.

34. Alcure ML, Di HipólitoJúnior O, Almeida OP, Bonilha H, Lopes MA. Oral histoplasmosis in an HIV-negative patient. *Oral Surg Oral Med Oral Pathol Oral Radiol Endod*. 2006; 101(2): e33-e36. doi: 10.1016/j.tripleo.2005.06.028

35. Samuel J, Wolff L. Oto-laryngeal histoplasmosis. *J Laryngol Otol*. 1986; 100(5): 587-593. doi: 10.1017/S0022215100099709

36. Rajagopal A, Khosravi M. D43. Critical Care Case Reports: Infections Leading to Critical Illness. Laryngeal histoplasmosis mimicking laryngeal cancer with acute life-threatening upper-airway obstruction. *ATS Journals (American Thoracic Society International Conference Abstracts)*. 2016; A6984. doi: 10.1164/ajrccm-conference.2016.193.1_MeetingAbstracts.A6984

37. Zain RB, Ling KC. Oral and laryngeal histoplasmosis in a patient with Addison's disease. *Ann Dent*. 1988; 47(2): 31-33. Web site. http://europepmc.org/abstract/med/3218944. Accessed October 7, 2016.

38. Wolf J, Blumberg HM, Leonard MK. Laryngeal histoplasmosis. *Am J Med Sci*. 2004; 327(3): 160-162.

39. de Alencar JCG, de Souza SB, de Araujo RMO, Martins RR. Laryngeal histoplasmosis–Description of two cases autochthonous in brazil and review of literature. *J Neuroinfect Dis.* 2014; 5: 158. doi: 10.4172/2314-7326.1000158

40. Pochini Sobrinho F, Della Negra M, Queiroz W, Ribeiro UJ, Bittencourt S, Klautau GB. Histoplasmosis of the larynx. *Braz J Otorhinolaryngol*. 2007; 73(6): 857-861.

41. Kumar V, Husain AN. The lung. In: Kumar V, Abbas AK, Fausto N, eds. *Robbins and Cotran Pathological Basis of Dis-*

ISSN 2470-4059 Open Journal http://dx.doi.org/10.17140/OTLOJ-2-130

ease. 7th ed. Philadelphia, PA, USA: WB Saunders Company; 2004: 711-772.

42. Goodwin RA, Shapiro JL, Thurman GH, Thurman SS, Des Prez RM. Disseminated histoplasmosis: Clinical and pathologic correlations. *Medicine*. 1980; 59: 1-33.

43. Bennett DE. Histoplasmosis of the oral cavity and larynx: A clinicopathologic study. *Arch Intern Med*. 1967; 120: 417-427.

44. Hage CA, Ribes JA, Wengenack NL, et al. A multicenter evaluation of tests for diagnosis of histoplasmosis. *Clin Infect Dis*. 2011; 53(5): 448-454. doi: 10.1093/cid/cir435

OTOLARYNGOLOGY

Openventio PUBLISHERS

ISSN 2470-4059 Open Journal http://dx.doi.org/10.17140/OTLOJ-2-131

Research

*Corresponding author
Himanshu Kumar Sanju
Research Officer
Department of Audiology
All India Institute of Speech and Hearing, Mysuru-6, Karnataka, India
Tel. +91-740-609-3279
E-mail: himanshusanjuaiish@gmail.com

Volume 2 : Issue 5
Article Ref. #: 1000OTLOJ2131

Article History
Received: September 12th, 2016
Accepted: October 19th, 2016
Published: October 21st, 2016

Citation
Sanju HK, Mishra R, Kumar P. Temporal modulation transfer function (TMTF) in individuals with diabetes mellitus type 2. *Otolaryngol Open J*. 2016; 2(5): 150-155. doi: 10.17140/OTLOJ-2-131

Temporal Modulation Transfer Function (TMTF) in Individuals With Diabetes Mellitus Type 2

Himanshu Kumar Sanju[1*]; Rajkishor Mishra[2]; Prawin Kumar, PhD[1]

[1]*Department of Audiology, All India Institute of Speech and Hearing, Mysuru-6, Karnataka, India*
[2]*Consultant Audiologist, Bloom Senso Hearing Centre, Kolkata, West Bengal, India*

ABSTRACT

Introduction: Diabetes mellitus is a collection of metabolic disorders characterized by elevated blood sugar and abnormalities in insulin secretion and action. Previous studies have shown the link between hearing impairment and diabetes. But, there is a lack of literature on patients with diabetes mellitus type 2 for auditory temporal resolution skills.
Aim and Objective: The aim of the current research is to assess auditory temporal resolution skills using Temporal Modulation Transfer Function (TMTF) in persons with diabetes mellitus type 2 (elevated blood sugar level) having high frequency hearing loss.
Methods: Fifteen individuals between the age of 30 to 40 years having diabetes mellitus type 2 with high frequency hearing loss recruited for the study as a clinical group. Fifteen age matched normal hearing subjects with no diabetes were taken as control group. To assess the temporal resolution ability, TMTF tests were administered. Research design used in this study was between group design.
Result: The 2 groups were compared using independent *t*-test. It showed that in TMTF task the diabetic group with high frequency hearing loss (clinical) performed significantly poorer when compared to non-diabetic group having normal hearing (control).
Overall Conclusion: It can be concluded that the reasons for having poorer performance in temporal resolution task in subjects with diabetes mellitus type 2 may be the changes in the central auditory nervous system and widening of auditory filter. The finding of the current study revealed that the processing at the level of central auditory system there is a deterioration due to impact of diabetes mellitus type 2.

KEYWORDS: Auditory temporal resolution; Auditory processing disorder; Diabetes complication.

ABBREVIATIONS: TMTF: Temporal Modulation Transfer Function; GDT: Gap Detection Threshold.

INTRODUCTION

Diabetes mellitus is a carbohydrate metabolism disorder which happens due to relative or absolute deficiency in insulin, including metabolic disturbance and various pathological changes in our body. It is characterized by increased sugar level in the blood, abnormalities in insulin action and secretion. Because of these abnormalities there is an alteration in carbohydrate, protein and fat metabolism. These nutrients acts as structural components and nourishes the cell. When these nutrients remain in the bloodstream, eventually damages micro and macrovascular system. Previous researchers have reported that in individuals with diabetes mellitus, a progressive sensory neural hearing loss bilaterally with gradual onset in which high frequencies are mainly affected as it is seen in presbycusis.[1] It was also observed that there can be sudden and unilateral hearing loss with and without vestibular disorder. Researchers

ISSN 2470-4059 Open Journal http://dx.doi.org/10.17140/OTLOJ-2-131

have shown that the vasculature of endolymphatic sac has a significant role in pathogenesis of sensorineural hearing loss.[2,3] The vascular insufficiency of cochlea in diabetic patient is the main reason for hearing loss. Uncontrolled diabetes may be caused due to vasculopathy in stria vascularis of the cochlea. Previous studies have showed that, in the vascular endothelium there is a diffused thickening of basilar membrane which is known as microangiopathy.[4,5] Literatures have also shown that microangiopathy is the main cause for hearing loss in subjects with diabetes mellitus[6,7] and involvement of minute vessels in the inner ear causes hypoxia which in turn leads to hearing loss.[7,8] Maia et al[9] concluded that high frequency hearing loss can be caused by diabetic neuropathy and microangiopathy. It was also found that in diabetic patients hearing loss was present at frequencies from 250 Hz to 8000 Hz.[8] Studies have shown mild to moderate high frequency hearing loss and higher thresholds at all the frequencies in individuals with diabetes mellitus.[9,10] Studies have observed no changes in speech discrimination outcome among normal population and subjects with diabetes mellitus.[11] Previous study by Bajaj et al[12] in 2014 showed that in diabetic patients there is poor perception of speech in noise. Researchers have also reported that, individuals with high frequency hearing loss have poor speech perception in noise.[13,14] In patients with hearing loss at higher frequencies, there is loss of audibility and poor frequency selectivity because of which there is a poor auditory processing at a given signal and poor perception of speech in noise.[15] Various researchers have investigated the effect of cochlear lesion on frequency and intensity coding.[16,17] Earlier studies have been done to check hearing and speech perception ability in diabetes mellitus individuals but there is a shortage of studies on evaluating their temporal resolution skill with high frequency hearing loss. Temporal resolution is the capability of the human hearing and listening system to track fast changes in the envelop of a stimulus over a period of time.[18] The Temporal Modulation Transfer Function (TMTF) is a worthy test and cost effective measure to investigate auditory temporal resolution skill. TMTF is psychophysical method which is defined as the depth of modulation required to just allow discrimination between a modulated and an unmodulated waveform. The identfication of amplitude modulation (fluctuations) over time is a measure of temporal acuity i.e. temporal resolution ability. The modulation of the signal depends on the modulation rate or frequency (number of modulations per second). Whereas, modulation depth gives information about the amplitude modulation. This gives the information on listening sensitivity of a person to detect the amplitude modulation. Modulation depth can be expressed in terms of decibels or percent i.e., 0 dB corresponds to 100%. The Gap Detection Threshold (GDT) is another test for temporal resolution. GDT is the ability of an individual to detect the shortest duration of gap in the given signal.[19] Previous researchers have used GDT to study cortical lesion.[20] Musiek et al[21] showed that GDT is an important measure in the evaluation of temporal resolution deficit in cortical as well as brainstem lesions. Therefore, current study is aimed at comparing auditory temporal resolution skill in subjects with diabetes mellitus with high frequency hearing loss and age matched normal hearing subjects. The foremost objective of the current study is to investigate TMTF in individuals with diabetes with high frequency hearing loss (experimental group) and age matched normal hearing individual (control group).

MATERIALS AND METHODS

Participants

Totally there were 30 participants participated in this study. Prior to the test administration all the participants were informed orally and written consent was taken. The participants were divided into 2 groups (experimental and control). There were 15 participants (10 males and 5 females) with diabetic mellitus in the experimental group with the age range of 30 to 40 years (mean age of 36.2 years). Research design used in this study was between group design. All the subjects of experimental group were having diabetic mellitus type 2 for minimum of 5 years (mean duration of 6.92 years). The subjects those who had a complaint of hearing loss after diabetes mellitus type 2 were taken as an experimental group. The subjects in experimental group were having decreased hearing sensitivity (mild to moderate degree) in both ears and the pure tone thresholds were higher than 15 dBHL at 2 kHz, 4 kHz and 8 kHz with normal hearing sensitivity at 250 Hz, 500 Hz and 1000 Hz. Normal middle ear functioning was indicated by 'A' type of tympanogram with no of acoustic reflexes at 2000 Hz and 4000 Hz for both the stimulation (ipsilateral and contralateral).

The diagnosis of diabetes mellitus was confirmed by a physician based on the blood glucose measurements including average blood sugar level over the previous three months (HbA1C testing), along with fasting plasma glucose and oral glucose tolerance test of all subjects as shown in Table 1.

Whereas control group consists age matched 15 non-diabetic individuals (10 males and 5 females) in the age range of 30 to 40 years (mean age of 35.3 years). The reason for taking participants in the age range of 30 to 40 years was to avoid the effect of age related hearing loss on outcomes. Control group consists the subjects with normal hearing sensitivity at all octaves in both air conduction (250 to 8000 Hz) and bone conduc-

	HbA1C (%)	Fasting Plasma Glucose (mg/dL)	Oral Glucose Tolerance (mg/dL)
Diabetes Mellitus Type 2	7.3	156.4	219.7
Non-Diabetic	4.2	80.2	103.7

*HbA1C-Hemoglobin A1c

Table 1: Average blood sugar level over the previous three months (HbA1C testing), fasting plasma glucose and oral glucose tolerance test of all subjects.

ISSN 2470-4059 Open Journal http://dx.doi.org/10.17140/OTLOJ-2-131

tion (250 to 4000 Hz) mode. All the participants in this group should must have normal middle ear functioning with A type tympanogram with presence of acoustic reflex at 500 Hz, 1000 Hz, 2000 Hz and 4000 Hz. Both the groups exhibited absence of other otological, neurological and neuromuscular symptoms. The data collection was done at All India Institute of Speech and Hearing, Mysuru, Karnataka within a period of 6 months. All procedures performed in studies involving human participants were in accordance with the ethical standards of the All India Institute of Speech and Hearing ethical committee and with the 1964 Helsinki declaration and its later amendments or comparable ethical standards.

Environment

All the psychophysical tests were carried out in a sound treated room, as per the standards of ANSI S3.1 (1991).

INSTRUMENTATION

Pure tone audiometry was done using a calibrated double channel clinical audiometer (Madsen MA-53). Calibrated GSI-TympStar Immittance meter was used for tympanometry and reflexometry. A personal laptop with Matlab software was used for TMTF.

Procedure

Pure tone thresholds air conduction (250 Hz to 8000 Hz) and bone conduction (250 Hz to 4000 Hz) were obtained using modified Hughson and Westlake procedure given by Carhart and Jerger in 1959.[22] Using a calibrated middle ear analyzer (GSI-Tympstar), tympanometry at 226 Hz probe frequency and acoustic reflexes thresholds (ipsilateral and contralateral) at 500 Hz to 4000 Hz were obtained.

In TMTF, 2 types of stimuli were used in the study i.e. sinusoidal amplitude modulated and unmodulated white noise bursts of 500 ms duration with 20 ms ramp. Stimuli were prepared using a 32 bit digital to analog converter having a sampling frequency of 44.1 KHz and cut off frequency of 220 Hz. The stimuli were then filtered using low pass filter. Variation in the amplitude of modulating sine wave was used to control the depth of modulation. The range of modulation depth was varied from 0 to -30 dB (-30 dB represent 0% modulation and 0 dB represent 100% modulation) with different modulation frequencies (4 Hz, 8 Hz, 16 Hz, 32 Hz, 64 Hz, and 128 Hz). Test stimuli were presented through a calibrated headphone routed from double channel audiometer which was connected with personal laptop having Matlab 2011 software. The stimuli was presented at 40 dBSL (comfortable level) for all participants. The subject task was to identify the modulated stimuli from a group of 3 stimuli which includes 2 unmodulated and one modulated noise bursts. Three interval forced choice method was used. In each trial, unmodulated and modulated stimuli were presented with an interstimulus interval of 500 ms. Feedback was given after every correct or wrong response on the computer screen. Modulation depth was changed into decibels 20 log 10(m), where 'm' refers to modulation depth. Initially 4 db step size was used and later it was decreased to 2 db steps after first two reversals. This method gives an estimate value of amplitude modulation necessary for 70.7% estimate of correct responses. The mean of eight reversals in a block of 14 was taken as threshold.

STATISTICAL ANALYSIS

Descriptive statistics was done to find mean and standard deviation for TMTF for both the groups. The 2 groups (experimental and control) were compared using independent *t*-test for TMTF.

RESULTS

In the present study, all the participants underwent Temporal Modulation Transfer Function test. The data was analyzed using SPSS software (Version 18).

Temporal Modulation Transfer Function (TMTF) Test

TMTF test was done for both the groups. Mean and standard deviation (SD) of TMTF threshold is shown in Table 2. Descriptive statistical analysis revealed that TMTF threshold was better (lower) for group-2 when compared to groups-1. Figure 1 represent graphical presentation of the outcome.

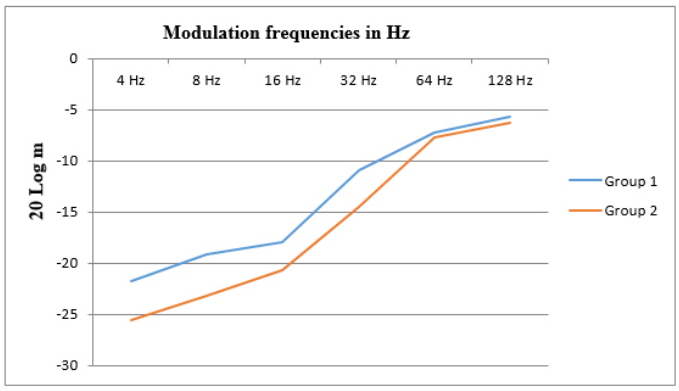

Figure 1: Graphical representation of mean values of temporal modulation transfer function (TMTF) for group 1 (Experimental) and groups 2 (Control).

ISSN 2470-4059 Open Journal http://dx.doi.org/10.17140/OTLOJ-2-131

Modulation frequencies	Groups			
	Group 1 (Experimental)		Group 2 (Control)	
	Mean	SD	Mean	SD
4 Hz	-21.81	1.23	-25.54	1.33
8 Hz	-19.15	1.03	-23.14	1.59
16 Hz	-17.96	1.18	-20.66	1.34
32 Hz	-10.97	1.04	-14.42	1.04
64 Hz	-7.01	0.45	-7.54	0.95
128 Hz	-6.02	0.51	-6.65	0.38

Table 2: Mean and SD of temporal modulation transfer function (TMTF) for group 1 (Experimental) and group 2 (Control).

To compare TMTF thresholds between these 2 groups independent *t*-test was administered. The statistical analysis revealed significant difference between the 2 groups (t=-7.82; df=28; $p<0.05$).

TMTF was assessed for 6 different modulation frequencies (4 Hz, 8Hz, 16 Hz, 32 Hz, 64 Hz, and 128 Hz), for both the groups i.e. experimental and control. Table 2 showed the descriptive statistics (mean & SD) of the TMTF for all the six modulation frequencies across the two groups. The same are graphically depicted in Figure 1. It was observed from the graph that the experimental group performed poorer in TMTF task compared to control group. Both the groups modulation detection thresholds were worsened as the modulation frequency increased.

Independent *t*-test was administered to compare the parameters across two groups. It revealed statistically significant difference for 4 Hz (t=-4.70; df=28; $p<0.05$), 8 Hz (t=-3.55; df=28; $p<0.05$), 16 Hz (t=-4.59; df=28; $p<0.05$), 32 Hz (t= -3.63; df=28; $p<0.05$), 64 Hz ((t=-7.15; df=28; $p<0.05$) and 128 Hz(t=-5.22; df=28; $p<0.05$).

The results showed that there is statistically significant difference between the scores of the 2 group at all modulation frequencies i.e.4 Hz, 8 Hz, 16 Hz, 32 Hz, 64 Hz and 128 Hz. Group-1 (experimental) showed poorer performance compare group-2 (control) at 5% level of significance.

DISCUSSION

The result of the current study showed poor auditory temporal resolution ability in individuals with diabetes mellitus type 2 having high frequency hearing loss when compared to their age-matched non-diabetic subjects having normal hearing. The results of sent TMTF threshold across the 2 groups showed statistically significant difference for the modulation frequencies like 4 Hz, 8Hz, 16 Hz, 32 Hz, 64 Hz and 128 Hz. However, present study showed an increased magnitude of deterioration in temporal resolution as modulation frequency increased. In the present study, it was also observed that as the modulation frequencies increase it requires more modulation depth to complete the task in both Group-1 and Group-2. But overall threshold on the TMTF was elevated for the diabetic individual with high frequencies sensorineural hearing loss compared to age matched non-diabetic subjects having normal hearing. Elevated threshold on TMTF at higher modulation frequencies could be because the task is more challenging at high frequencies and as band pass filter at high frequencies region uses requires more depth in the signal spectrum to detect.

Current study showed that, in temporal resolution task the patients with diabetes mellitus performed poor which revealed certain degeneration in the central auditory processing system. Earlier literature on rats and diabetic patients showed hearing disorder mainly because of edema in stria vascularis, decrease in number of outer hair cells and spiral ganglion.[23-25] Increased thresholds at high frequencies revealed that the cochlear regions may have been damaged due to angiopathy in the stria vascularis and spiral ligament, edema of stria vascularis which in turn leads to reduced intensity and frequency coding.[16,26,27] A study on auditory brainstem response in individuals with diabetes revealed poor response with prolonged latencies of wave III, V and also prolonged latencies of inter-peak III-V, I-III and I-V at 90 dB presentation level[28] which showed that there is a participation of the relay station of different order neuron in the central auditory nervous system. The current study results are in support with the study done by McCrimmon et al[29] in 1997 in which they have also found poor temporal resolution skill in diabetes mellitus patients. Sommerfield in 2003 also revealed significantly poor results in the tests of immediate visual and verbal memory at the time of hypoglycemia.[30] The impact of hypoglycemia was found to be more profound on working and delayed memory. Present study also supported by Strachan et al[31] 2003 reported adverse effects of acute hypoglycaemia on sensory information processing in adults with diabetes. McAulay in 2006 investigated attention functioning in individuals with diabetes mellitus type 1. The result showed hypoglycemia caused a significant damage in tests sensitive to visual and auditory selective attention.[32] An experiment done by Gold et al[33] reported significant reduction in cognitive function in individuals with hypoglycemia. It was also observed that hypoglycemic seizures had reduce in scores on tests assessing memory skills including short term memory and memory for words.[33] The finding of current study revealed poor temporal resolution ability in individuals with diabetes mellitus may due to broadening of auditory filter and changes in the central auditory nervous system. Sanju and Kumar[34] also suggested annual audiological evaluation in indi-

ISSN 2470-4059 Open Journal http://dx.doi.org/10.17140/OTLOJ-2-131

vidual with diabetes mellitus. Recently, Mishra et al[35] in 2015 also reported poor temporal resolution skill in individual with diabetes mellitus. Less number of participants is the limitation of the present study. Lack of a group of diabetes mellitus without hearing loss is another limitation of the current study. In future, researchers can compare temporal resolution ability in individuals with diabetes mellitus with and without hearing loss.

CONCLUSION

Current study outcome revealed poor temporal resolution ability in subjects with diabetes mellitus type 2. Because of poor temporal resolution skill, there may be poor speech perception in quiet as well as noise in these individuals. It is not the work of an audiologist or otolaryngologist to diagnose and treat diabetes. But, audiologist and otolaryngologist should give time to take detail case history of diabetic patient and medication they are taking. Annual evaluation by other professionals like podiatrist, cardiologist, ophthalmologist and others are considered to be a standard care for individuals with diabetes mellitus. To add on to this list an audio logical evaluation should be done annually. The findings of the current study reveal that there is an adverse effect of diabetes mellitus type 2 on the central auditory processing, especially on temporal processing. So, it can be recommended to screen all the individuals with diabetes mellitus for temporal resolution test to understand the underlying mechanism of speech perception in noise. In future further research should be conducted by researchers to study the effect of other central auditory processing abilities on diabetes mellitus as auditory discrimination in background noise, speech perception in noise, binaural integration, binaural separation, auditory attention and memory.

CONFLICTS OF INTEREST

The authors declare that they have no conflicts of interest.

REFERENCE

1. Jorgensen MB, Buch NH. Studies on the sense of smell and taste in diabetics. *Acta Otolaryngol*. 1961; 53(2): 539-545. doi: 10.3109/00016486109126521

2. Leone CA, Feghali JG, Linthicum FH. Endolymphatic sac: Possible role in autoimmune sensorineural hearing loss. *Ann Otol Rhinol Laryngol*. 1984; 93(5): 208-209. doi: 10.1177/000348948409300303

3. Gussen R. Vascular mechanisms in Meniere's disease. Theoretical considerations. *Arch Otolaryngol*. 1982; 108(9): 544-549. doi: 10.1001/archotol.1982.00790570010003

4. Malpas S, Blake P, Bishop R, Robinson B, Johnson R. Does autonomic neuropathy in diabetes cause hearing deficits? *N Z Med J*. 1989; 102(874): 434-435.

5. Konrad-Martin D, Austin DF, Griest S, Mcmillan GP, Mcdermott D, Fausti S. Diabetes-related changes in auditory brainstem responses. *Laryngoscope*. 2010; 120(1): 150-158. doi: 10.1002/lary.20636

6. Makishima K, Tanaka K. Pathological changes of the inner ear and central auditory pathway in diabetics. *Ann Otol Rhinol Laryngol*. 1971; 80(2): 218-228.

7. Costa OA. Inner ear pathology in experimental diabetes. *Laryngoscope*. 1967; 77(1): 68-75. doi: 10.1288/00005537-196701000-00005

8. Wackym PA, Linthicum FH. Diabetes mellitus and hearing loss: Clinical and histopathologic relationships. *Am J Otol*. 1986; 7(3): 176-182.

9. Maia CA, Campos CA. Diabetes mellitus as etiological factor of hearing loss. *Braz J Otorhinolaryngol*. 2005; 71(2): 208-214.

10. Celik O, Yalçin S, Celebi H, Oztürk A. Hearing loss in insulin-dependent diabetes mellitus. *Auris Nasus Larynx*. 1996; 23(8): 127-132. doi: 10.1016/S0385-8146(96)80019-8

11. Cullen JR, Cinnamond MJ. Hearing loss in diabetics. *J Laryngol Otol*. 1993; 107(3): 179-182. doi: 10.1017/S0022215100122571

12. Bajaj G, Puthuchery S, Bhat J, Ranjan R. Effect of type 2 diabetes on speech perception in noise. *Int Journ Innov Res Dev*. 2014; 3 (4): 50-54.

13. Dubno JR, Dirks DD, Morgan DE. Effects of age and mild hearing loss on speech recognition in noise. *J Acoust Soc Am*. 1984; 76(1): 87-96. doi: 10.1121/1.391011

14. Stuart A, Phillips DP. Word recognition in continuous and interrupted broadband noise by young normal-hearing, older normal-hearing, and presbyacusic listeners. *Ear Hear.* 1996; 17(6): 478-489. doi: 10.1097/00003446-199612000-00004

15. Moore BC. Perceptual consequences of cochlear hearing loss and their implications for the design of hearing aids. *Ear Hear.* 1996; 17(2): 133-161. Web site. https://www.ncbi.nlm.nih.gov/pubmed/8698160. Accessed September 11, 2016.

16. Florentine M, Reed CM, Rabinowitz WM, Braida LD, Durlach NI, Buus S. Intensity perception. XIV. Intensity discrimination in listeners with sensorineural hearing loss. *J Acoust Soc Am.* 1993; 94(5): 2575-2586. doi: 10.1121/1.407369

17. Simon HJ, Yund EW. Frequency discrimination in listeners with sensorineural hearing loss. *Ear Hear.* 1993; 14(3): 190-201. Web site. http://journals.lww.com/ear-hearing/Abstract/1993/06000/Frequency_Discrimination_in_Listeners_with.6.aspx. Accessed September 11, 2016.

ISSN 2470-4059 Open Journal http://dx.doi.org/10.17140/OTLOJ-2-131

18. Plack CJ, Viemeister NF. Suppression and the dynamic range of hearing. *J Acoust Soc Am.* 1993; 93(2): 976-982. doi: 10.1121/1.405403

19. Lister J, Besing J, Koehnke J. Effects of age and frequency disparity on gap discrimination. *J Acoust Soc Am*. 2002; 111(6): 2793-2800. doi: 10.1121/1.1476685

20. Efron R, Yund EW, Nichols D, Crandall PH. An ear asymmetry for gap detection following anterior temporal lobectomy. *Neuropsychologia*. 1985; 23(1): 43-50. Web site. http://www.ebire.org/hcnlab/papers/1985aEfron.pdf. Accessed September 11, 2016.

21. Musiek FE, Shinn JB, Jirsa R, Bamiou DE, Baran JA, Zaida E. GIN (Gaps-In-Noise) test performance in subjects with confirmed central auditory nervous system involvement. *Ear Hear.* 2005; 26(6): 608-618. Web site. http://journals.lww.com/ear-hearing/Abstract/2005/12000/GIN__Gaps_In_Noise__Test_Performance_in_Subjects.7.aspx. Accessed September 11, 2016.

22. Carhart R, Jerger J. Preferred method for clinical determination of pure-tone thresholds. *J Speech Hearing Disord.* 1959; 24(4): 330-335. doi: 10.1044/jshd.2404.330

23. Raynor EM, Carrasco VN, Prazma J, Pillsbury HC. An assessment of cochlear hair-cell loss in insulin-dependent diabetes mellitus diabetic and noise-exposed rats. *Arch Otolaryngol Head Neck Surg.* 1995; 121(4): 452-456.

24. Fukushima H, Cureoglu S, Schachern PA, et al. Cochlear changes in patients with type 1 diabetes mellitus. *Otolaryngol Head Neck Surg*. 2005; 133(1): 100-106.

25. Lee HS, Kim KR, Chung WH, Cho YS, Hong SH. Early sensorineural hearing loss in ob/ob mouse, an animal model of type 2 diabetes. *Clin Exp Otorhinolaryngol.* 2008; 1(4): 211-216. doi: 10.3342/ceo.2008.1.4.211

26. Nelson DA, Freyman RL. Psychometric functions for frequency discrimination from listeners with sensorineural hearing loss. *J Acoust Soc Am*. 1986; 79(3): 799-805. doi: 10.1121/1.393470

27. Schroder AC, Viemeister NF, Nelson DA. Intensity discrimination in normal-hearing and hearing-impaired listeners. *J Acoust Soc Am.* 1994; 96(5): 2683-2693.

28. Gupta R, Aslam M, Hasan S, Siddiqi S. Type-2 diabetes mellitus and auditory brainstem responses-a hospital based study. *Indian J Endocrinol Metab*. 2010; 14(1): 9-11. Web site. http://www.ijem.in/article.asp?issn=2230-8210;year=2010;volume=14;issue=1;spage=9;epage=11;aulast=Gupta. Accessed September 11, 2016.

29. Mccrimmon RJ, Deary IJ, Frier BM. Auditory information processing during acute insulin-induced hypoglycaemia in non-diabetic human subjects. *Neuropsychologia*. 1997; 35(12): 1547-1553.

30. Sommerfield AJ, Ewing FM, Strachan MW, Deary IJ, Aitken G, Frier BM. Self-treatment of mild symptomatic hypoglycaemia by people with insulin-treated diabetes. *Diabet Med.* 2003; 20(8): 686-687. doi: 10.1046/j.1464-5491.2003.09281.x

31. Strachan MW, Ewing FM, Frier BM, Mccrimmon RJ, Deary IJ. Effects of acute hypoglycaemia on auditory information processing in adults with type I diabetes. *Diabetologia*. 2003; 46(1): 97-105. doi: 10.1007/s00125-002-0950-2

32. Kaufman FR, Epport K, Engilman R, Halvorson M. Neurocognitive functioning in children diagnosed with diabetes before age 10 years. *J Diabetes Complicat.* 1999; 13(1): 31-38. doi: 10.1016/S1056-8727(98)00029-4

33. Gold AE, Deary IJ, Macleod KM, Thomson KJ, Frier BM. Cognitive function during insulin-induced hypoglycemia in humans: Short-term cerebral adaptation does not occur. *Psychopharmacology (Berl).* 1995; 119(3): 325-333. doi: 10.1007/BF02246299

34. Sanju HK, Kumar P. Annual audiological evaluations should be mandatory for patients with diabetes. *Hearing Review*. 2016; 23(1): 14. Web site. http://www.hearingreview.com/2015/12/annual-audiological-evaluations-mandatory-patients-diabetes/. Accessed September 11, 2016.

35. Mishra R, Sanju HK, Kumar P. Auditory temporal resolution in individuals with diabetes mellitus type 2. *Int Arch Otorhinolaryngol.* 2016; 20(4): 327-330. doi: 10.1055/s-0035-1571207

OTOLARYNGOLOGY

Openventio PUBLISHERS

ISSN 2470-4059 Open Journal http://dx.doi.org/10.17140/OTLOJ-2-132

Brief Research

***Corresponding author**
Ziya Salturk, MD
Specialist
Okmeydanı Training and Research Hospital, ENT Clinic
Istanbul, Turkey
E-mail: ziyasalturk@gmail.com

Volume 2 : Issue 5
Article Ref. #: 1000OTLOJ2132

Article History
Received: August 27th, 2016
Accepted: October 26th, 2016
Published: October 27th, 2016

Citation
Aydoğdu İ, Aydoğdu Z, Salturk Z, Uyar Y. The asessment of gastroesophageal and gastropharyngeal reflux prevelance after total laryngectomy. *Otolaryngol Open J*. 2016; 2(5): 156-157. doi: 10.17140/OTLOJ-2-132

The Asessment of Gastroesophageal and Gastropharyngeal Reflux Prevelance after Total Laryngectomy

İmran Aydoğdu, MD; Zeynep Aydoğdu, MD; Ziya Salturk, MD*; Yavuz Uyar, MD

Okmeydanı Training and Research Hospital, ENT Clinic, Istanbul, Turkey

ABSTRACT

Objective: The aim of this study is to detect prevalence of glomerular filtration rate (GFR) in total laryngectomy patients.
Method: Thirty-eight healthy patients who underwent total laryngectomy and followed at least 6 months paticipated to study. Patients were asked to complete gastroesophageal reflux disease questionnaire (GerdQ) and examined with flexible laryngoscopy.
Result: Twenty-seven of 38 (71%) patients had scores over 8 and diagnosed as gastroesophageal reflux (GER). Eleven patients had scores lower than 8.
Conclusion: Our study revealed that GER and GFR incidence are higher in total laryngectomy patients.

KEYWORDS: Laryngectomy; Gastropharyngeal reflux (GFR); Gastroesophageal reflux (GER).

ABBREVIATIONS: GFR: Glomerular Filtration Rate; GerdQ: Gastroesophageal reflux disease questionnaire; GER: Gastroesophageal reflux.

INTRODUCTION

Gastroesophageal reflux (GER) is a condition in which gastrointestinal content passes through upper esophageal sphincter and reaches esophagus. This situation is called GER disease when casues signs and symptoms.[1] Gastropharyngeal reflux (GFR) is an advanced situation that gastrointestinal content reaches pharyngeal mucosa passing through upper esophageal sphincter.[2] It has been proved that GFR is associated with numerous otorhinolaryngological diseases including otitis media with effusion, laryngeal granuloma and subglottic stenosis. It is accused of being one of the etiological factors in esophageal carcinoma.[3,4] GFR usually exhibits itself without gastrointestinal symptoms.[5] It should be considered in chronic otorhinolaryngological problems.[6]

Although its importance has been accepted in otorhinolaryngological problems it was not studied in detail at laryngectomized patients. GFR may cause pharyngocutanous fistula and voice problems in laryngectomized patients.[7] We aimed to study prevalence of GFR in total laryngectomy patients.

METHODS

We evaluated 38 healthy patients who underwent total laryngectomy and followed at least 6 months. All participants were informed of the study procedures and signed a consent form. Patients were asked to complete Gastroesophageal reflux disease questionnaire (GerdQ) and examined with flexible laryngoscopy. Statistical analysis of the data was conducted using SPSS version 17.0. After analysis, data were presented using descriptive statistical methods (mean±standard deviation). Student *t*-tests were used for comparison data of pre-operation and data of post-operation.

ISSN 2470-4059 Open Journal http://dx.doi.org/10.17140/OTLOJ-2-132

RESULTS

GerdQ has high sensitivity and specifity in GER patients and scores over 8 was accepted as GER.[9] Thirty-four males and 4 females were included in the study. Mean age of the patients were 59.8±73.27 of 38 (71%) patients had scores over 8 and diagnosed as GER. Eleven patients had scores lower than 8. There was a statistically significant difference between patients with higher scores and lower scores than 8 (p=0.024).

CONCLUSION

Our study revealed that GER and GFR incidence are higher in total laryngectomy patients. This can be related to physiological changes which were caused by surgery. Diagnosis and treatment of these patients are important because it negatively affects quality-of-life (QoL). Due to above reported facts we recommend prophylactic proton pump inhibitor use after total laryngectomy.

CONFLICTS OF INTEREST

The authors declare that they have no conflicts of interest.

REFERENCES

1. El-Serag HB, Graham DY, Satia JA, Rabeneck L. Obesity is an independent risk factor for GERD symptoms and erosive esophagitis. *Am J Gastroenterol.* 2005; 100: 1243-1250. doi: 10.1111/j.1572-0241.2005.41703.x

2. Ulualp SO, Toohill RJ. Larngopharyngeal reflux: State of the art diagnosis and treatment. *Otolaryngol Clin North Am.* 2000; 33: 785-801.

3. Koufman J, Sataloff RT, Toohill R. Laryngopharyngeal reflux: Consensus conference report. *J Voice.* 1996; 10: 215-216. doi: 10.1016/S0892-1997(96)80001-4

4. Freije JE, Beatty TW, Campbell BH, Woodson BT, Schultz CJ, Toohill RJ. Carcinoma of the larynx in patients with gastroesophageal reflux. *Am J Otolaryngol.* 1996; 17: 386-390. doi: 10.1016/S0196-0709(96)90071-X

5. Burton DM, Pransky SM, Kearns DB, Katz RM, Seid AB. Pediatric airway manifestations of gastroesophageal reflux. *Ann Otol Rhinol Laryngol.* 1992; 101: 742-749. doi: 10.1177/000348949210100905

6. Rival R, Wong R, Mendelsohn M, Rosgen S, Goldberg M, Freeman J. Role of gastroesophageal reflux disease in patients with cervical symptoms. *Otolaryngol Head Neck Surg.* 1995; 113: 364-369. doi: 10.1016/S0194-5998(95)70069-2

7. Seikaly H, Park P. Gastroesophageal reflux prophylaxis decreases the incidence of pharyngocutaneous fistula after total laryngectomy. *Laryngoscope.* 1995; 105: 1220-1222. doı: 10.1288/00005537-199511000-00015

8. Dent J, Vakil N, Jones R, et al. Accuracy of the diagnosis of GORD by questionnaire, physicians and a trial of proton pump inhibitor treatment: The Diamond Study. *Gut.* 2010; 59: 714-721. doi: 10.1136/gut.2009.200063

9. Jonasson C, Wernersson B, Hoff DA, Hatlebakk JG. Validation of the GerdQ questionnaire for the diagnosis of gastro-oesophageal reflux disease. *Aliment Pharmacol Ther*. 2013; 37: 564-572. doi: 10.1111/apt.12204