

## Research

### Corresponding author

**Jihene Marrakchi, MD**  
Clinical Chief  
ENT Department  
La Rabta University Hospital  
Tunis, Tunisia  
Tel. 0021698260676  
E-mail: [jihenemarrakchi@yahoo.fr](mailto:jihenemarrakchi@yahoo.fr)

Volume 2 : Issue 3

Article Ref. #: 1000OTLOJ2121

### Article History

Received: May 5<sup>th</sup>, 2016

Accepted: June 22<sup>nd</sup>, 2016

Published: June 23<sup>rd</sup>, 2016

### Citation

Marrakchi J, Nefzaoui S, Chiboub D, et al. Imaging of paranasal sinus mucocoeles. *Otolaryngol Open J.* 2016; 2(3): 94-100. doi: [10.17140/OTLOJ-2-121](https://doi.org/10.17140/OTLOJ-2-121)

### Copyright

©2016 Marrakchi J. This is an open access article distributed under the Creative Commons Attribution 4.0 International License (CC BY 4.0), which permits unrestricted use, distribution, and reproduction in any medium, provided the original work is properly cited.

# Imaging of Paranasal Sinus Mucocoeles

**Jihene Marrakchi, MD<sup>1\*</sup>; Safa Nefzaoui, MD<sup>1</sup>, Dorra Chiboub, MD<sup>1</sup>, Mariem Jrad, MD<sup>2</sup>; Mohamed Ben Amor, MD<sup>1</sup>; Najeh Beltaief, MD<sup>1</sup>; Habiba Mizouni, MD<sup>2</sup>; Besbes Ghazi, MD<sup>1</sup>**

<sup>1</sup>Department of ENT, La Rabta University Hospital, Tunis, Tunisia

<sup>2</sup>Department of Imaging, La Rabta University Hospital, Tunis, Tunisia

## ABSTRACT

**Introduction:** Mucocoeles are cystic masses developing after obstruction of the sinus ostium. The symptoms are not specific. Computed Tomography scan (CT scan) and Magnetic Resonance Imaging (MRI) confirm the diagnosis.

**Objectives:** We herein review the radiologic characteristics of mucocoeles in CT scan and MRI. **Materials and Methods:** We report a retrospective study of 43 patients diagnosed with paranasal sinuses mucocoeles. CT scans were performed for all patients, but MRI was carried out only in selected cases.

**Results:** Our study was constituted of 27 males and 16 females with a mean age of 47 years. The CT scan appearance of mucocoeles were in all cases as a well circumscribed expansile sinus mass with an effect on the neighbor bone structure. This mass was hypodense in 26 cases, isodense in 14 cases and hyperdense in 3 patients. The paranasal sinuses most frequently affected in our series were the fronto-ethmoidal sinuses. The most affected bone eroded was the lamina papiracea. Intracranial extension was seen in four cases. CT scan allowed to predict the cause of mucocoeles in some cases and to provide information about anatomic variants. MRI was realized for 15 patients in addition to the CT scan. It allowed to study the extension of mucocoeles to the neighboring organs especially orbital and endocranial ones.

**Conclusion:** The presentations of mucocoeles on imaging are quite variable. CT scan provides precious information about the location, bone erosion and extension of the mucocoeles. MRI is indicated in some cases especially in cases of orbital or cranial extension.

**KEYWORDS:** Mucocoeles; Paranasal sinuses; Computed Tomography scan (CT scan); Magnetic Resonance Imaging (MRI).

**ABBREVIATIONS:** CT scan: Computed Tomography scan; MRI: Magnetic Resonance Imaging.

## INTRODUCTION

Mucocoeles are benign, slow-growing paranasal sinus lesions that develop after obstructions of the sinus ostium.<sup>1</sup> Symptoms are variable. The diagnosis is based on imaging. CT scan of the sinuses is the method of the choice. MRI is indicated in some cases and provides much information of mucocoele extensions to adjacent compartments.<sup>2</sup>

The purpose of this study was to review the role of pre-operative imaging and to illustrate the main characteristics imaging findings of paranasal sinuses mucocoeles.

## MATERIALS AND METHODS

We conducted a retrospective review of the charts of 43 patients diagnosed with paranasal sinus mucocoeles who were admitted to our Department of Otolaryngology, between January 1990 and December 2012.

Review of the patients' medical records including out-patient clinical records and reports of imaging were performed.

CT scans of the head were performed for all patients. Axial, sagittal, coronal and contrast CT scan with 3 mm slice thickness were reviewed in all cases.

MRI was carried out only in selected cases for the evaluation of the extension of sinonasal mucocoeles. MRI findings on coronal and axial views in T1, T2 weighted and contrast enhanced images were studied.

**RESULTS**

**Clinical Features**

Our study was constituted of 27 males and 16 females (sex ratio=1.68) with a mean age of 47 years (from 14 to 77 years).

Rhinosinusitis past history was present in six patients, a facial traumatism in seven patient and eleven patients have undergone prior sinus surgery.

The most commonly reported symptoms were ophthalmologic one (n=24, 56%), including proptosis (n=16), chronic lachrimation (n=7), diplopia (n=3), visual acuity reduced (n=2) and ptosis (n=1).

Headache was present in twenty three patients. Rhinologic symptoms were reported in 20 patients and were dominated by chronic discharge (17 cases).

On examination, we noted a face swelling in 17 cases, a proptosis in 16 patients and opthalmoplegia in two cases.

Endoscopic nasal examination revealed an obstructive deviation of nasal septum in 10 cases, a filling of middle meatus in six patients and adhesions between the middle turbinate and the nasal septum in three cases.

**Radiologic Findings**

**CT scan:** The CT scan appearance of mucocoeles were in all cases as a well circumscribed expansile sinus mass with an effect on the neighbor bone structure. This mass was hypodense in 26 cases, isodense in 14 cases and hyperdense in 3 patients. After injection of contrast agents, we saw a poor enhancement in three cases and a peripherally enhanced image in all others cases.

The paranasal sinuses most frequently affected in our series were the fronto-ethmoidal sinuses (Figure 1). Mucocoeles involved both the frontal and ethmoidal sinus in fourteen cases, ten mucocoeles were located in the ethmoid sinus, and five were located in the frontal sinus (Figures 2, 3 and 4).

Bone erosion was noted (Figures 5 and 6). The most affected was the lamina papiracea which was eroded in 27 cases (Table 1).

Intracranial extension was seen in four cases and was

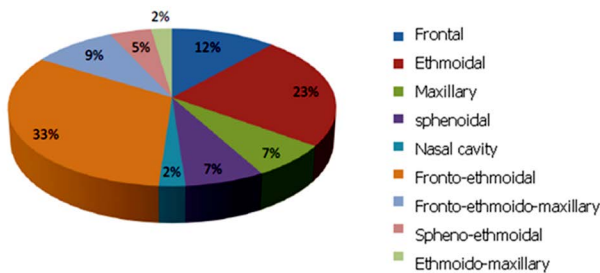


Figure 1: The location of the mucocoeles in our patients.

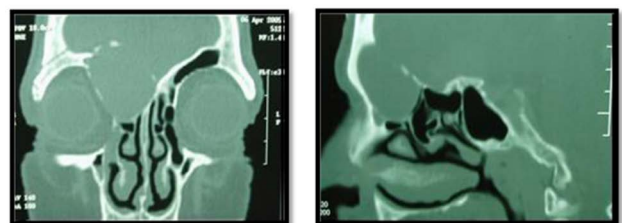


Figure 2: CT scan imaging (coronal and sagittal sections) showing an expansile mass in the fronto-ethmoidal sinuses with orbital involvement.

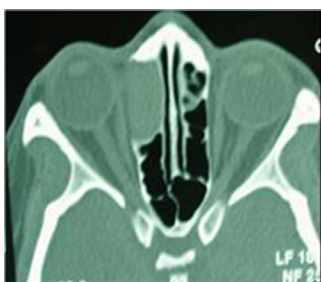

Figure 3: Axial CT scan of a mucocoele involving the right ethmoid.

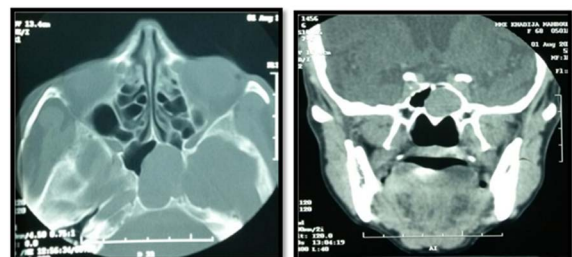


Figure 4: Axial and coronal CT scan imaging demonstrating a mucocoele of the sphenoid sinus.

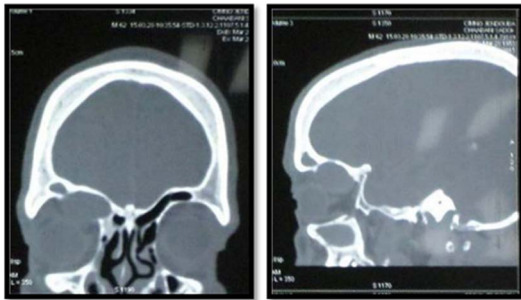


Figure 5: CT scan with coronal and sagittal reconstruction: Mucocoele with in the left frontal sinus with erosion of the roof of the orbite and extension into the orbital cavity.

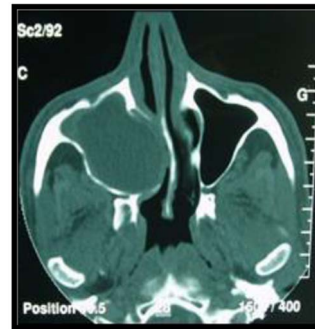

Figure 6: Axial computed tomographic image of the paranasal sinuses showing a completely opacified right maxillary sinus with a medial bulge of the wall of sinus and the septum.

Bone erosion	Number of cases	Mucocoele location							
		F	E	M	S	FE	FEM	SE	EM
Lamina papiracea	27	2	7	—	—	12	4	2	—
Orbital roof	9	2	—	—	—	5	2	—	—
Ethmoidal roof	6	—	—	—	—	4	2	—	—
Anterior wall of frontal sinus	5	2	—	—	—	2	1	—	—
Posterior wall of frontal sinus	5	2	—	—	—	2	1	—	—
Postero-superior wall of sphenoidal sinus	3	—	—	—	1	—	—	2	—
Medial wall of maxillary sinus	2	—	—	2	—	—	—	—	—
External wall of maxillary sinus	1	—	—	1	—	—	—	—	—

F: Frontal sinus; E: Ethmoidal sinus; M: Maxillary sinus; S: Sphenoidal sinus.

Table 1: Bone erosion in our study.

consequently to a frontal mucocoele in one case, fronto-ethmoidal mucocoele in two cases, speno-ethmoidal mucocoele in one other case (Figure 7).

Extension into the orbite was observed in 27 cases and concerned predominately the medial wall of the orbite. Optic nerve was repulsed in two cases of fronto-ethmoidal mucocoeles and one case of fronto-ethmoido-maxillary mucocoele. It was compressed in others three cases of: Ethmoidal, Sphenoidal and Spheno-ethmoidal mucocoeles. We noted one case of atrophic optic nerve in a sphenoidal mucocoele (Figures 8, 9 and 10).

CT scan allowed to note a proptosis in 17 cases (grade 2 in

16 patients and grade 3 in one patient with a fronto-ethmoidal mucocoele associated with an important orbital extension) Others lesions were observed some predicted of the cause of mucocoeles:

\*Adhesions between the middle turbinate and lateral nasal wall were observed in three patients who had prior sinus surgery and were seen respectively in an ethmoidal, fronto-ethmoidal and fronto-ethmoidal maxillary mucocoeles.

\*Calcifications of the frontal recess in one patient having a frontal mucocoele and history of craniofacial traumatism.

\*Sinus retention were noted in three cases of maxillary mucocoele-

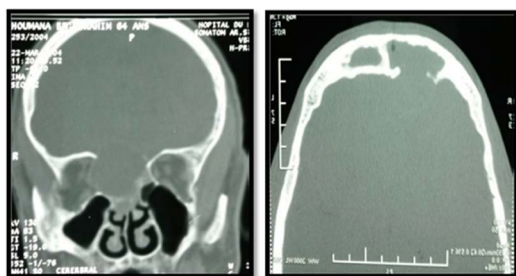


Figure 7: Axial and coronal CT scan imaging of the sinuses demonstrating a mucocoele of the frontal sinus and the ethmoid with important endocranial extension.

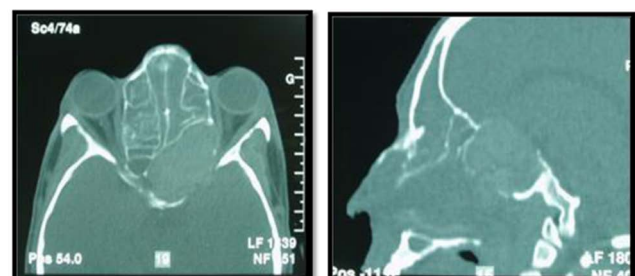
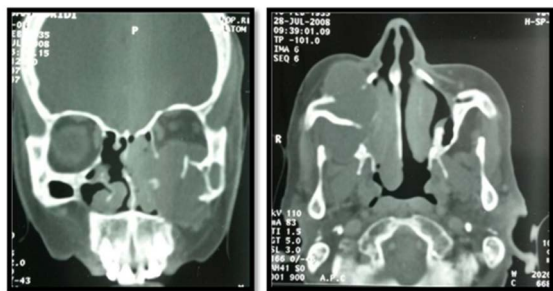
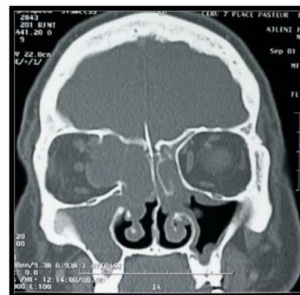


Figure 8: Axial and sagittal images of CT scan demonstrating a mass consistent with a left spheno-ethmoid mucocoele. The medial orbital wall is expanded and we note a mass effect on the medial rectus and optic nerve with endocranial extension.



**Figure 9:** Axial and coronal CT scan imaging demonstrating a mucocele of the right maxillary sinus with important erosion of the adjacent walls and extension to the orbit and infratemporal fossa.



**Figure 10:** Coronal CT scan imaging showing a mass of the ethmoid with large erosion of the lamina papyracea and compressing of the orbit contents.

le, fronto-ethmoidal and fronto-ethmoido-maxillary mucocele.

\*Concha bullosa was present in four patients presenting: Ethmoidal mucocele, Fronto-ethmoidal mucocele, Maxillary mucocele and Nasal cavity mucocele. (Figure 11)

\*Hypoplastic frontal sinuses was noted in one case of ethmoidal mucocele.

\*Agenesis of the frontal sinus in one case of ethmoidal mucocele. (Figure 12)

\*Presence of a frontal cell (kuhn's cell) in a frontal mucocele. (Figure 13)

\*Paradoxical middle turbinate in one patient having a fronto-ethmoidal mucocele.

\*Septum deviation was observed in 17 patients and were obstructive in 10 cases.

CT scan provided also information about anatomic variants. We noted:

\*Providence of the canal of the carotid artery in four cases. It was bilateral in three cases (frontal, maxillary and sphenoi-

dal mucocele) and unilateral in one case of fronto-ethmoidal mucocele associated with the presence of a sphenoid sinus septa attached to the artery canal.

\*Providence of the optic nerve canal in one case of a frontal mucocele.

\*Asymmetry in the height of the ethmoid roof in two cases of a fronto-ethmoidal mucoceles.

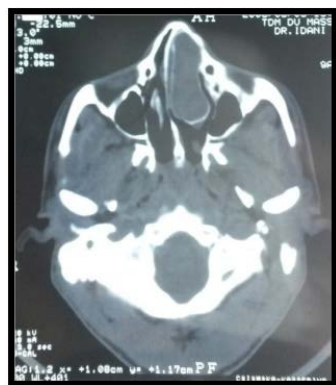**MRI:** MRI was realized for 15 patients in addition to the CT scan. It was indicated in four cases of sphenoid mucoceles (Figure 14) and in 11 cases presenting orbital or endocranial extension on CT scan.

Mucoceles appeared as a homogenous round mass who was in:

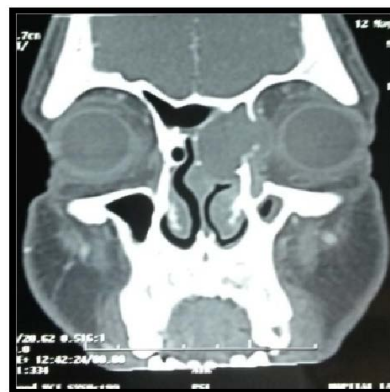-Hypointense signal on T1-weighted images, hyperintense signal on T2-weighted images in nine cases.

-Hyperintense signal on T1-weighted and T2-weighted images in two cases.

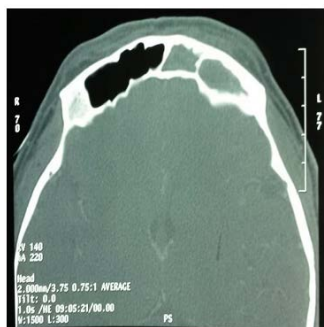-Hypointense signal on T1-weighted images, isointense signal on T2-weighted images in two cases.



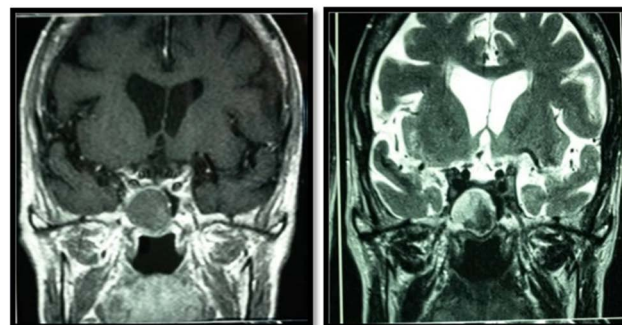
**Figure 11:** Axial CT scan imaging showing a mucocele developing from a concha bullosa of the left middle turbinate.



**Figure 12:** Coronal CT scan shows ethmoidal mucocele associated with an agenesis of the left frontal sinus and a pneumatization of the right frontal sinus and the crista galli.



**Figure 13:** Axial CT scan imaging showing a left frontal mucocoele associated with a left frontal cell (Kuhn's cell).



**Figure 14:** Coronal MRI imaging demonstrating a sphenoidal mucocoele (isointense T1 weighted images and hyperintense T2 weighted images).

-Isointense signal on T1-weighted images, hyperintense signal on T2-weighted images in one case.

-Isointense signal on T1-weighted and T2-weighted images in one case.

In all cases, we have noted no enhancement after injection of gadolinium.

MRI allowed to study the extension of mucocoeles to the neighboring organs especially orbital and endocranial ones. We observed that:

-The orbite contents was repulsed in two cases of fronto-ethmoido-maxillary mucocoeles and one case of fronto-ethmoidal mucocoele. (Figure 15)

-Optic nerve was pushed in three patients who had respectively sphenoid mucocoele, sphenoid-ethmoidal mucocoele, fronto-ethmoido-maxillary mucocoele.

It was stretched in one case of fronto-ethmoidal mucocoele with important orbital extension.

-Endocranial extension was noted in three cases: Sphenoid-ethmoido mucocoele, fronto-ethmoidal mucocoele and fronto-ethmoido-maxillary mucocoele. (Figure 16)

**DISCUSSION**

Paranasal sinus mucocoeles are cystic masses filled with mucous and lined by respiratory epithelium which are capable of expansion by bone resorption and new bone formation.<sup>1</sup>

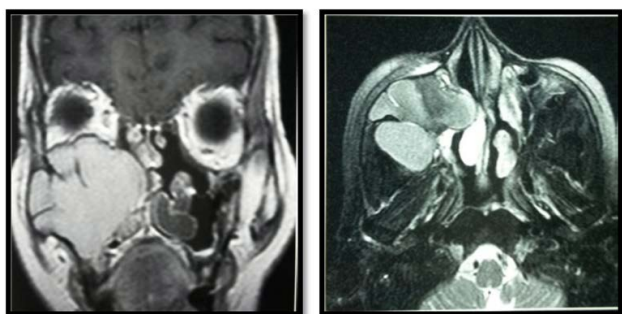
They occur principally in the third or fourth decades of life with a male predilection.<sup>1</sup>

Mucocoeles result from the blockage of the sinus drainage secondary to inflammation, trauma, anatomical aberrations, tumours, chronic rhinosinusitis, allergic disease and craniofacial disease are the most common cause of mucocoele formation.<sup>2,3</sup>

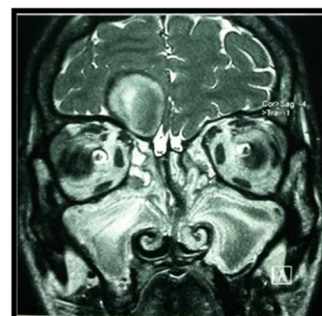
Symptoms depend on the location of the mucocoele and may vary from rhinological, neurologic, or ophthalmologic ones.<sup>1-3</sup>

CT scan is considered to be the complementary method of choice in the investigation of mucocoeles. It allows to evoke the diagnosis of the mucocoele and determine its location, to study the neighboring structure (bone erosion, extension), to presume an aetiology of the sinus ostium obstruction and to research the anatomic variants of the sinuses.<sup>3,4</sup>

Mucocoele appears on CT as a homogenous well circumscribed expansible cyst involving one or much sinuses and



**Figure 15:** Axial and coronal MRI imaging showing a maxillary mucocoele with extension toward the orbite and the infra temporal fossa.



**Figure 16:** Coronal T2-weighted MRI showing a fronto-ethmoidal sinus mucocoele with endocranial extension.

may expand to neighboring structure. they may appear either hypo- or hyperdense.<sup>4</sup> This variable densities depend on their protein content and possible infection. Mucoceles do not show contrast enhancement centrally but a thin peripheral enhancement, can be seen and is suggestive of encapsulation.<sup>5</sup>

The differential diagnosis for mucocele is made with inflammatory, congenital cystic and neoplastic lesions of skull base, facial sinuses and nasopharynx.<sup>4-6</sup>

Mucocele location depends on anatomic conditions that favorise its formation. The frontal sinus is most commonly affected followed by the ethmoid sinuses, mucoceles occur in these locations in 70 to 90%. Sphenoid mucoceles are rare. The maxillary antrum is a relatively unfrequent site for mucocele formation, accounting for 10 percent or less of mucoceles.<sup>7,8</sup>

In our study, mucoceles were seen frequently in fronto-ethmoidal sinus followed by ethmoidal location then frontal sinus.

The neighboring bone structure is remodeled with areas of thickening and erosion.<sup>2,4,5</sup> In some areas of greater fragility, we may observe herniation into adjacent structures such as the orbite and the endocrine.<sup>4,9</sup>

CT scan provides also information about existence of factors favorising mucoceles formation as: Osteoma, Fibrous displasia, Facial traumatism, Sinonasal polyposis. It can visualizes anatomic abnormalities that may cause a blockage of sinus drainage.<sup>10-12</sup> For our patients, CT scan has allowed to evoke the cause of mucoceles in some cases as adhesions, concha bullosa, septum deviation, paradoxical middle turbinate.

Furthermore, this exam is essentially to define anatomic variants prior to surgery.<sup>13</sup>

MRI is an excellent exam in mucocles. It allows to differentiate and to assess any extension into the orbit or intracranial compartment, but, unfortunately it can't study bone detail.<sup>14,15</sup>

Its indications are in complement of the CT scan in case of diagnosis doubt in CT scan between mucocele and other tumors or inflammatory lesions, in case of sphenoid location and in endocranial or orbital extension.<sup>14</sup>

The MRI appearance of paranasal sinus mucoceles is quite variable, depending on the composition of the mucocele.<sup>16</sup> The usual signal characteristics are a low intense T1 and a high intense T2 but any combination of signal intensity may be seen depending on the presence of blood products or the degree of hydration of the contents.<sup>5,14,17,18</sup> The appearance consisted of hyperintense signal on both T1 and T2 type images, corresponding to more hydrated secretions, which are also high in protein content.<sup>17-20</sup>

We have noted variable presentation of mucocele in MRI from hypo to hyperintensity T1 and T2 but in all cases, we have noted no enhancement after injection of gadolinium.

#### CONCLUSION

The presentations of mucoceles on imaging are quite variable depending on its contents. Practicians should know the typical as well as atypical findings. Special care should be taken with regard to differential diagnosis and associated cases.<sup>16</sup>

#### CONFLICTS OF INTEREST

The authors declare that they have no conflicts of interest.

#### CONSENT

As our article is a retrospective study and did not publish any personal photo or information regarding any of the patient in our manuscript thus the consent is not required for the article publication.

#### REFERENCES

1. Capra GG, Carbone PN, Mullin DP. Paranasal sinus mucocele. *Head Neck Pathol.* 2012; 6: 369-372. doi: [10.1007/s12105-012-0359-2](https://doi.org/10.1007/s12105-012-0359-2)
2. Cannon DE, Wells T, Poetker DM. Two late complications of craniofacial trauma: Case report and review of the literature. *American Journal of Otolaryngology-Head and Neck Medicine and Surgery.* 2012; 33 : 615-618. doi: [10.1016/j.amjoto.2011.12.003](https://doi.org/10.1016/j.amjoto.2011.12.003)
3. Obeso S, Liorente JL, Rodrigo JP, Sanchez R, Mancebo G, Suarez C. Paranasal sinus mucoceles. Our experience in 72 patients. *Acta Otorrinolaringol Esp.* 2009; 60(5): 332-339. doi: [10.1016/S2173-5735\(09\)70153-X](https://doi.org/10.1016/S2173-5735(09)70153-X)
4. De Carvalho BV, De Campos Carvalho LI, De Brito Corrêa J, Ramos LFM, Motta EGPC, Diniz RLFC. Typical and atypical presentations of paranasal sinus mucocele at computed tomography. *Radiol Bras.* 2013; 46(6): 372-375. doi: [10.1590/S0100-39842013000600010](https://doi.org/10.1590/S0100-39842013000600010)
5. Hee Han M, Hyun Chang K, Hee Lee C, Gyu Na D, Mo Yeon K, Chung Han M. Cystic expansile masses of the maxilla: Differential diagnosis with CT and MR. *AJNR Am J Neuroradiol.* 1995; 16: 333-338. Web site. <http://www.ajnr.org/content/16/2/333.long>. Accessed May 4, 2016.
6. Chmielewski R, Paprocki A, Morawski K, Niemczyk K. Sphenoid sinus mucocele penetrating to the orbit, anterior and middle cranial fossae and parapharyngeal space: A case report. *Otolaryngol Pol.* 2010; 64(1): 47-50. doi: [10.1016/S0030-6657\(10\)70035-4](https://doi.org/10.1016/S0030-6657(10)70035-4)

7. Lloyd G, Lund VJ, Savy L, Howard D. Optimum imaging for mucoceles. *J Laryngol Otol.* 2000; 114(3): 233-236. doi: [10.1258/0022215001905238](https://doi.org/10.1258/0022215001905238)
8. Pratiksha Y. Mucocele of the sphenoid, ethmoid and frontal sinuses presenting with proptosis, visual impairment and diplopia. *Br J Med Med Res.* 2014; 4(12): 2383-2387. doi: [10.9734/BJMMR/2014/8074](https://doi.org/10.9734/BJMMR/2014/8074)
9. Bahadir O, Imamoglu M, Bektas D. Massive concha bullosa pyocele with orbital extention. *Auris Nasus Larynx.* 2006; 33: 195-198. doi: [10.1016/j.anl.2005.11.007](https://doi.org/10.1016/j.anl.2005.11.007)
10. Atasoy C, Stuner E, Erden I, Akyar S. Frontal sinus mucocele: A rare complication of craniofacial fibrous dysplasia. *Journal of Clinical Imaging.* 2001; 25: 388-391. doi: [10.1016/S0899-7071\(01\)00320-5](https://doi.org/10.1016/S0899-7071(01)00320-5)
11. Mourouzis C, Evans BT, Shenouda E. Late presentation of a mucocele of the frontal sinus: 50 years postinjury. *J Oral Maxillofac Surg.* 2008; 66: 1510-1513. doi: [10.1016/j.joms.2007.12.031](https://doi.org/10.1016/j.joms.2007.12.031)
12. Derham C, Bucur S, Russell J, Liddington M, Chumas P. Frontal sinus mucocele in association with fibrous dysplasia: Review and report of two cases. *Childs Nerv Syst.* 2011; 27: 327-331. doi: [10.1007/s00381-010-1266-z](https://doi.org/10.1007/s00381-010-1266-z)
13. Reddy UM, Dev B. Pictorial essay: Anatomical variations of paranasal sinuses on multidetector computed tomography-How does it help FESS surgeons? *Indian J Radiol Imaging.* 2012; 22: 317-324. doi: [10.4103/0971-3026.111486](https://doi.org/10.4103/0971-3026.111486)
14. Lee TJ, Li SP, Fu C-H, et al. Extensive paranasal sinus mucoceles: A 15-year review of 82 cases. *Am J Otolaryngol.* 2009; 30: 234-238. doi: [10.1016/j.amjoto.2008.06.006](https://doi.org/10.1016/j.amjoto.2008.06.006)
15. Kim YS, Kim K, Lee JG, Yoon JH, Kim CH. Paranasal sinus mucoceles with ophthalmologic manifestations: A 17-year review of 96 cases. *Am J Rhinol Allergy.* 2011; 25: 272-275. doi: [10.2500/ajra.2011.25.3624](https://doi.org/10.2500/ajra.2011.25.3624)
16. Haloi AK, Ditchfield M, Maixner W. Mucocele of the sphenoid sinus. *Pediatr Radiol.* 2006; 36: 987-990. doi: [10.1007/s00247-006-0243-x](https://doi.org/10.1007/s00247-006-0243-x)
17. Lanzieri CF, Shah M, Krauss D, et al. Use of gadolinium-enhanced MR imaging for differentiating mucoceles from neoplasms in the paranasal sinuses. *Radiology.* 1991; 178: 425-428. doi: [10.1148/radiology.178.2.1987603](https://doi.org/10.1148/radiology.178.2.1987603)
18. Van Tassel P, Lee YY, Jing BS, De Pena C. Mucoceles of the paranasal sinuses: MR imaging with CT correlation. *AJNR.* 1989; 10: 607-612. Web site. <http://www.ajnr.org/content/10/3/607.full.pdf>. Accessed May 4, 2016.
19. Campbell PD, Zinreich SJ, Aygun N. Imaging of the paranasal sinuses and in office CT. *Otolaryngol Clin N Am.* 2009; 42: 753-764.
20. Topdag M, Iseri M, Sari F, Erdogan S, Keskin IG. Paranasal sinus mucoceles: Our clinical experiments. *Int J Clin Exp Med.* 2015; 8(10): 18518-18522. Website. <http://www.ncbi.nlm.nih.gov/pubmed/26770462>. Accessed May 4, 2016.