

Research

***Corresponding author**
Katarzyna Amernik, MD, PhD
 Departments of Otolaryngology and
 Oncologic Laryngology
 Pomeranian Medical University
 Ul. Unii Lubelskiej 1
 71-252 Szczecin, Poland
 Tel. +48-91-425-32-89
 Fax: +48-91-425-32-77
 E-mail: kamernik@yahoo.com

Volume 2 : Issue 4

Article Ref. #: 1000OTLOJ2123

Article History

Received: June 24th, 2016

Accepted: July 19th, 2016

Published: July 20th, 2016

Citation

Amernik K, Sindrewicz K, Jaworowska E. Hot or immediate tonsillectomy: A safe and effective method for treatment of acute tonsillitis' complications. *Otolaryngol Open J.* 2016; 2(4): 105-108. doi: [10.17140/OTLOJ-2-123](https://doi.org/10.17140/OTLOJ-2-123)

Copyright

©2016 Amernik K. This is an open access article distributed under the Creative Commons Attribution 4.0 International License (CC BY 4.0), which permits unrestricted use, distribution, and reproduction in any medium, provided the original work is properly cited.

Hot or Immediate Tonsillectomy: A Safe and Effective Method for Treatment of Acute Tonsillitis' Complications

Katarzyna Amernik, MD, PhD*; **Krzysztof Sindrewicz, MD**; **Ewa Jaworowska, MD, PhD**

Departments of Otolaryngology and Oncologic Laryngology, Pomeranian Medical University, Ul. Unii Lubelskiej 1, 71-252 Szczecin, Poland

ABSTRACT

Aim: The aim of this study was retrospective analysis of indications to hot tonsillectomy, its effectiveness and safety. Peritonsillar abscess (PTA) is one of the most common complications of acute tonsillitis and the cause of emergency laryngological counselling. In some cases, it is necessary to perform hot tonsillectomy.

Material and Methods: In between 2009-2015, 21 patients (aged between 4 to 43 years old) with an initial diagnosis of peritonsillar abscess were admitted. Among them, 11 were women and 10 were men. All underwent hot tonsillectomy.

Results: Most of the patients were between 20-40 years old. The most common symptoms were pain in the throat, trismus and dysphagia. In all cases incision of an abscess was made, in 9 patients purulent discharge was present. In all patients there was no relief of symptoms after incision and antibiotic therapy. In 12 cases without drainage after initial incision, pus was drained after tonsillectomy. In the remaining 9 cases there were additional reservoirs of pus, which were drained after surgery in 6 patients. In 8 patients there was more than one localization of an abscess. There were no problems with intubation and no complications in the early and late post-operative periods occurred. The average time of stay in hospital was 8 days (5-12 days).

Conclusion: Lack of improvement after initial treatment of PTA is an indication to hot tonsillectomy. This procedure is not connected with an increased risk of complications. Evacuation of purulent content does not exclude presence of another abscess, unusual localization or parapharyngeal space abscess.

KEYWORDS: Peritonsillar abscess (PTA); Tonsillectomy; Hot tonsillectomy; Acute tonsillitis; Complication; Parapharyngeal space abscess.

ABBREVIATIONS: PTA: Peritonsillar abscess; CRP: C-reactive protein.

INTRODUCTION

Peritonsillar abscess (PTA) is one of the most common complications of acute tonsillitis and cause of emergency laryngological counselling. It is also the most common deep neck infection. The incidence is estimated to be 30 out of 100,000 people per year.^{1,2} Factors predisposing to the development of peritonsillar abscess described in the literature are bad periodontal status and smoking.^{2,3} Treatment is always connected with an abscess incision, drainage of purulent content, re-hydration⁴⁻¹⁰ with subsequent antibiotic therapy. In some cases, it is necessary to perform immediate tonsillectomy.^{5,9,11} Otherwise infection may spread into surrounding tissues such as parapharyngeal space. This procedure is potentially connected with an increased risk of complications, such as problems with intubation,⁸ intra- and post-operative haemorrhage and spread of the infection to surrounding tissues especially to the parapharyngeal space.^{4,10} Immediate tonsillectomy has also been reported in pediatric cases for airway obturation.¹²

MATERIALS AND METHODS

Between 2009-2015 in The Clinic of Otolaryngology and Oncological Laryngology of Pomeranian Medical University 21 patients with an initial diagnosis of peritonsillar abscess were admitted, who underwent hot tonsillectomy. The ages of the patients ranged from 4 to 43 years old (middle 26 years), 11 women and 10 men.

Retrospective analysis of data from medical history, according to age, symptoms, signs and methods of treatment was made. Inclusion criteria were peritonsillar abscess recognized in clinical examination requiring tonsillectomy within 48 hours after admission to the hospital. Symptoms were asymmetry of oral pharynx and palatoglossal arch, dislocation of the tonsil.¹³ Age, stay in the hospital, history of recurrent tonsillitis and peritonsillar abscesses, C-reactive protein (CRP) level and type of treatment were analyzed. The day of discharge from hospital was assumed as the end of treatment. Patients left hospital after healing of tonsillar niche and relief of local and general symptoms.

RESULTS

The age range of the patients is shown in Figure 1. The largest group of patients in this study were aged between 21 and 40 years.

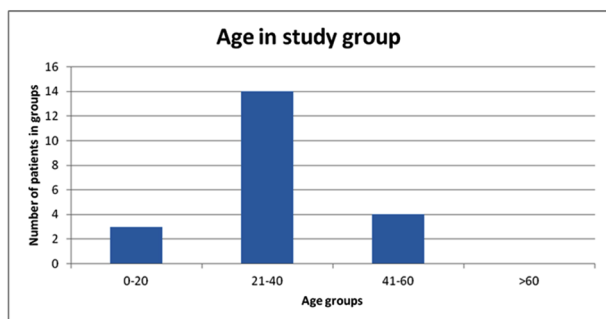


Figure 1: Age groups of patients.

The number of men and women in the study were similar (M:W 57%/43%).

Symptoms reported by patients are shown in Table 1, the most common symptom was pain in the throat and problems with swallowing.

Symptom	Number of patients	Percentage
Fever	9	43%
Trismus	19	90%
Pain in the throat	21	100%
Dysphagia	13	62%
Ear pain	2	9,5%
≥3 acute tonsillitis in the previous 1 year	10/21	48%
1-2 acute tonsillitis in the previous 1 year	2/21	10%
Peritonsillar abscess (previous year)	13(10)	62% (47%)

Table 1: Symptoms reported by patients.

In the history of previous upper respiratory tract infections more than half of the patients had at least 3 episodes of acute tonsillitis in the previous year and 13 had peritonsillar abscess in the past.

Upon admission to the hospital the patients were in good general condition. Following laryngological examination, swelling in the peritonsillar area and pain with enlargement of lymph nodes on the affected side were stated together with signs of acute tonsillitis.

Blood tests was performed in all patients on the days of admitting and discharges from the hospital. Results of the blood tests are shown in Table 2. In all patients, levels of inflammatory parameters decreased at the day of discharge.

	Min	Max	Average	Standard deviation
CRP (C reactive protein)	82	241	123	67.7
WBC	10.34	21.03	15.7	3.63
RBC	3.99	5.48	5.01	0.38
CRP controls	5	69	35	20.03
WBC controls	7.05	11.34	9.56	1.24
RBC controls	3.75	5.15	4.57	0.34

Table 2: Blood tests results.

All patients at the day of admission had undergone incision of PTA. In 9 there was purulent drainage (43%). The algorithm of treatment is show in Figure 2.

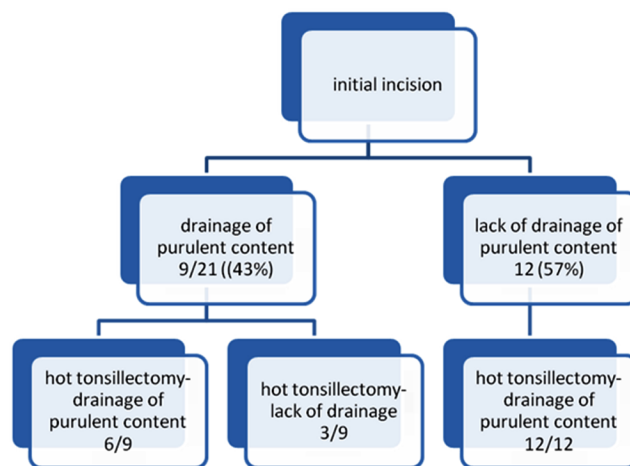


Figure 2: Algorithm of treatment for patients with PTA.

In all patients indication for surgery, hot tonsillectomy, was lack of improvement within the following 48 hours, independent of purulent drainage after initial incision.

All 21 patients had immediate/hot tonsillectomy. In 11 it was on one side and in 10 bilateral. Indications for bilateral tonsillectomy were recurrent acute tonsillitis and history of PTA in the previous year (7 cases) and signs of chronic tonsillitis (3 cases). During surgery in 86% of patients purulent content was drained and among those cases half of them were parapharyngeal space abscesses. Table 3 gives detailed information about

recognized abscesses during surgery.

	Number	Percentage
antero-superior PTA	14	66%
Posterior PTA	6	29%
Parapharyngeal space abscess	9	43%

Table 3: Postoperative diagnosis.

Among all patients with parapharyngeal space abscess only in 2 cases on initial incision drainage of pus was present. In 8 patients there was more than one localization of an abscess. In 4 patients PTA in antero-superior area and parapharyngeal space abscess were found and in 4 posterior PTA and parapharyngeal space were found simultaneously.

Loss of blood was on average 150 ml. The average time of surgery was 100 minutes.

There were no problems with intubation, no complications in the early and late post-operative period occurred.

Patients were treated with antibiotics and it was usually intravenous amoxycylin with clavulanic acid (3 times daily, 1,2 g in 19 out of 21 patients), in one case cefurixime with metronidazole was used and in another case cefotaxim with clindamycin was used.

The average time of stay in hospital was 8 days (5-12 days). None of the described patients required treatment on our clinic again.

DISCUSSION

PTA is a purulent reservoir localized between the superior pharyngeal sphincter and a tonsil which is a complication of acute tonsillitis.^{3,12,14} This diagnosis requires immediate treatment because of the possibility of infection spread to the parapharyngeal space, retropharyngeal space and floor of the mouth.¹⁵ Continuation of disease leads to the involvement of deep neck spaces and mediastinum, which is a life threatening condition.^{14,15} According to the literature progression of infection from throat to deep neck space occurs in 1.8% patients and from those spaces to mediastinum in 10%.¹⁶ Mortality in acute mediastinitis is still high and ranges from 30% to 40%.^{14,16}

In the group of patients analyzed in the study, most patients were young adults aged from 21 to 40 years old who are professionally active people. These data are consistent with those from the literature^{2,3,5-7,12} and that makes problem of PTA treatment economically important. The symptoms reported by patients were typical for throat infections.

Out of the whole group in 8, patients abscesses were present in more than one localization, for example PTA with abscess of parapharyngeal space. This means that even initial incision with drainage of pus from the peritonsillar area requires subsequent controls, especially in situations when there is no ex-

pected improvement in patient's clinical status or recurrence of symptoms after initial improvement. There are data in the literature concerning the spread of infection from peritonsillar area to deep neck spaces in similar cases.¹⁴⁻¹⁷

Fine needle aspiration of PTA or incision with drainage of pus with subsequent antibiotic therapy is the treatment of choice.² Although, when there is a lack of expected improvement the next step that should be considered is hot tonsillectomy. This procedure is also called tonsillectomy "a chaud" or urgent tonsillectomy and was described at the beginning of 20th century as typical treatment of PTA.⁵ Potentially increased risk of the procedure and intra-operative and post-operative complications led to the abandonment of this procedure by surgeons. However, on the basis of the results presented here, along with data from the literature we can suggest that this procedure is not connected with increased risk of complications such as haemorrhage during surgery or delayed haemorrhage.^{5-7,9-11,18} Albertz et al¹³ reported that describing their 10 years experience. The authors had cases of bleeding (3.6%) and single cases of edema, diarrhea, persisted odynophagia, panic attack, cutaneous rash.¹² No problems with intubation or complications such as haemorrhaging occurred in any of our patients. These results confirm information from the literature according to Berry et al⁵ who estimated hot tonsillectomy to be easier than delayed tonsillectomy, especially on the side of PTA. Johnson⁶ suggested that if there is delayed tonsillectomy following abscess, this may be connected with higher costs of treatment as it may require another hospitalization and absence at work. The same author recommends hot tonsillectomy in all patients with recurrent PTA,^{6,7} as it may prevent recurrences.^{2,12} It is still controversial if this tonsillectomy should be performed on one side only or if it should be performed bilaterally. In our material bilateral tonsillectomy was made in all patients who had indications for tonsillectomy, independent from PTA. According to the literature it seems to be the most common practice in another centres.¹¹ However, Albertz et al¹³ recommend bilateral tonsillectomy in all cases as a prevention of recurrences, on the basis of their study. Immediate tonsillectomy is especially effective in cases of intratonsillar and posterior abscess,¹² which was confirmed in our study.

It is recommended to administer antibiotics intravenously before hot tonsillectomy and to avoid analgesic drugs which inhibit aggregation of blood platelets and may influence blood coagulation.^{5,19}

In all of our patients improvement was achieved after surgery and antibiotic therapy with amoxicillin with clavulanic acid. Diagnostic imaging may include computer tomography^{11,17,20} but it seems that the main indication for hot tonsillectomy is lack of expected clinical improvement in spite of proper treatment. Diagnostic imaging may be useful in case of doubts.

CONCLUSION

Lack of improvement after initial treatment of PTA should make a consideration of performing hot tonsillectomy as an emer-

gency. This procedure is not connected with increased risk of complications and postponing the decision may lead to infection spread into surrounding tissues. Evacuation of purulent content does not exclude the presence of another abscess in close, unusual localization or parapharyngeal space abscess.

ACKNOWLEDGEMENTS

The author wishes to thank Ms. Ruth Danielski for help in preparation of the manuscript and editorial assistance.

CONFLICTS OF INTEREST

The authors declare that they have no conflicts of interest.

CONSENT

As the article is a retrospective study and did not publish any personal photo or information regarding any of the patients in the manuscript. Thus, the consent is not required for the article publication.

REFERENCES

1. Zagólski O, Gajda M. The role of anaerobic flora in formation of peritonsillar abscess. *Pol Merk Lek.* 2008; 24: 140-146.
2. Shaul C, Koslowsky B, Rodriguez M, et al. Is needle aspiration for peritonsillar abscess still as good as we think? A long-term follow-up. *Ann Otol Rhinol Laryngol.* 2015; 124(4): 299-304. doi: [10.1177/0003489414556083](https://doi.org/10.1177/0003489414556083)
3. Lepelletier D, Pinaud V, Le Conte P, et al. Peritonsillar abscess (PTA): Clinical characteristics, microbiology, drug exposures and outcomes of a large multicenter cohort survey of 412 patients hospitalized in 13 French university hospitals. *Eur J Clin Microbiol Infect Dis.* 2016; 35(5): 867-873. doi: [10.1007/s10096-016-2609-9](https://doi.org/10.1007/s10096-016-2609-9)
4. Herzon FS, Martin AD. Medical and surgical treatment of peritonsillar, retropharyngeal, and parapharyngeal abscesses. *Curr Infect Dis Rep.* 2006; 8: 196-202. doi: [10.1007/s11908-006-0059-8](https://doi.org/10.1007/s11908-006-0059-8)
5. Berry S, Pascal I, Whittet HB. Tonsillectomy à chaud for quinsy: Revisited. *Eur Arch Otorhinolaryngol.* 2008; 265: 31-33. doi: [10.1007/s00405-007-0498-3](https://doi.org/10.1007/s00405-007-0498-3)
6. Johnson RF, Stewart MG, Wright CC. An evidence based review of the treatment of peritonsillar abscess. *Otolaryngol Head Neck Surg.* 2003; 128: 332-343. doi: [10.1067/mhn.2003.93](https://doi.org/10.1067/mhn.2003.93)
7. Page C, Chassery G, Boute P, Obongo R, Strunski V. Immediate tonsillectomy: Indications for use as first-line surgical management of peritonsillar abscess (quinsy) and parapharyngeal abscess. *J Laryngol Otol.* 2010; 124: 1085-1090. doi: [10.1017/S0022215110000903](https://doi.org/10.1017/S0022215110000903)

8. Steyer TE. Peritonsillar abscess: Diagnosis and treatment. *Am Fam Physician.* 2002; 65: 93-96. Web site. <http://www.aafp.org/afp/2002/0101/p93.html>. Accessed June 23, 2016
9. Suzuki M, Ueyama T, Mogi G. Immediate tonsillectomy for peritonsillar abscess. *Auris Nasus Larynx.* 1999; 26: 299-304. doi: [10.1016/S0385-8146\(98\)00070-4](https://doi.org/10.1016/S0385-8146(98)00070-4)
10. Windfuhr JP, Chen YS. Immediate abscess tonsillectomy--a safe procedure? *Auris Nasus Larynx.* 2001; 28: 323-327. doi: [10.1016/S0385-8146\(01\)00098-0](https://doi.org/10.1016/S0385-8146(01)00098-0)
11. Page C, Biet A, Zaatar R, Strunski V. Parapharyngeal abscess: Diagnosis and treatment. *Eur Arch Otorhinolaryngol.* 2008; 265: 681-686. doi: [10.1007/s00405-007-0524-5](https://doi.org/10.1007/s00405-007-0524-5)
12. Coyle P, Marzouk SD, Gerolympou M, Marais J. Hot tonsillectomy for pediatric obstructive sleep apnoea. *BMJ Case Rep.* 2014. doi: [10.1136/bcr-2013-203378](https://doi.org/10.1136/bcr-2013-203378)
13. Albertz N, Nazar G. Peritonsillar abscess: Treatment with immediate tonsillectomy - 10 years of experience. *Acta Otolaryngol.* 2012; 132(10): 1102-1107. doi: [10.3109/00016489.2012.684399](https://doi.org/10.3109/00016489.2012.684399)
14. Machała W, Śmiechowicz K, Gaszyński T. Sepsis caused by descending mediastinitis as peritonsillar abscess complication. Case report. *Otolaryngol Pol.* 2006; 60: 211-215. Web site. <http://www.ncbi.nlm.nih.gov/pubmed/16903340>. Accessed June 23, 2016
15. Nowak K, Błaszcyk M, Szyfter W. Fatal necrotic mediastinitis as a complication of peritonsillar abscess. *Otolaryngol Pol.* 2005; 59: 751-754. Web site. <http://www.ncbi.nlm.nih.gov/pubmed/16471196>. Accessed June 23, 2016
16. Collin J, Beasley N. Tonsillitis to mediastinitis. *J Laryngol Otol.* 2006; 120: 963-966. doi: [10.1017/S0022215106001940](https://doi.org/10.1017/S0022215106001940)
17. Thapar A, Tassone P, Bhat N, Pfeleiderer A. Parapharyngeal abscess. A life threatening complication of quinsy. *Clin Anat.* 2008; 21: 23-26. doi: [10.1002/ca.20569](https://doi.org/10.1002/ca.20569)
18. Watanabe T, Arita M, Suzuki M, Mogi G. Immediate tonsillectomy for peritonsillar abscess. *Int Congress Series.* 2003; 1257: 199-203.
19. Giger R, Landis BN, Dulguerov P. Hemorrhage risk after quinsy tonsillectomy. *Otolaryngol Head Neck Surg.* 2005; 133(5): 729-734. doi: [10.1016/j.otohns.2005.07.013](https://doi.org/10.1016/j.otohns.2005.07.013)
20. Kawabata M, Umakoshi M, Makise T, et al. Clinical classification of peritonsillar abscess based on CT and indications for immediate abscess tonsillectomy. *Auris Nasus Larynx.* 2016; 43(2): 182-186. doi: [10.1016/j.anl.2015.09.014](https://doi.org/10.1016/j.anl.2015.09.014)