

Short Communication

Corresponding author

James Wei Tatt Toh, BSc, MBBS, FRACS

Conjoint lecturer

University of Western Sydney

University of New South Wales

James Ruse Dr, Parramatta NSW

2150, Sydney NSW 2052, Australia

Colorectal Fellow

Bankstown Hospital

68 Eldridge Road

Bankstown NSW 2200, Australia

E-mail: james.toh@unsw.edu.au

Volume 1 : Issue 2

Article Ref. #: 1000GOJ1109

Article History

Received: April 15th, 2015

Accepted: April 23rd, 2015

Published: April 23rd, 2015

Citation

Toh JWT, Rahman K, Kozman D. Mucinous tumour in ileal pouch post restorative proctocolectomy and ileal pouch anal anastomosis for Familial Adenomatous Polyposis. *Gastro Open J.* 2015; 1(2): 59-60. doi: [10.17140/GOJ-1-109](https://doi.org/10.17140/GOJ-1-109)

Copyright

©2015 Toh JWT. This is an open access article distributed under the Creative Commons Attribution 4.0 International License (CC BY 4.0), which permits unrestricted use, distribution, and reproduction in any medium, provided the original work is properly cited.

Mucinous Tumour in Ileal Pouch Post Restorative Proctocolectomy and Ileal Pouch Anal Anastomosis for Familial Adenomatous Polyposis

James Wei Tatt Toh^{1,2*}, Kasim Rahman² and Daniel Kozman²

¹Conjoint lecturer, University of Western Sydney, University of New South Wales, James Ruse Dr, Parramatta NSW 2150, Sydney NSW 2052, Australia

²Bankstown Hospital, 68 Eldridge Road, Bankstown NSW 2200, Australia

CLINICAL CONTEXT

We present a fifty-six years old female having surveillance gastroscopy and colonoscopy ten years after a restorative proctocolectomy and Ileal-pouch anal anastomosis (IPAA). This was performed for Familial Adenomatous Polyposis (FAP). The patient was found to have unusual patchy nodular areas of abnormal mucosa in the ileal pouch and at the level of the anastomosis.

Magnetic Resonance Imaging (MRI) was performed which showed a large fluid collection (12x10x13 cm) within the pelvis. Histopathology from biopsy was reported as a low grade mucinous tumour with abundant mucoid material containing scattered degenerate cellular material and histiocytes. Computed Tomography (CT) of chest and pelvis did not reveal any evidence of metastatic disease.

A pelvic exenteration was performed and patient underwent adjuvant radiotherapy. Histopathology showed cystic mass 50 mm × 50 mm × 30 mm in size containing mucin of intermediate nuclear grade with 0/18 nodes involved (Figure 1).

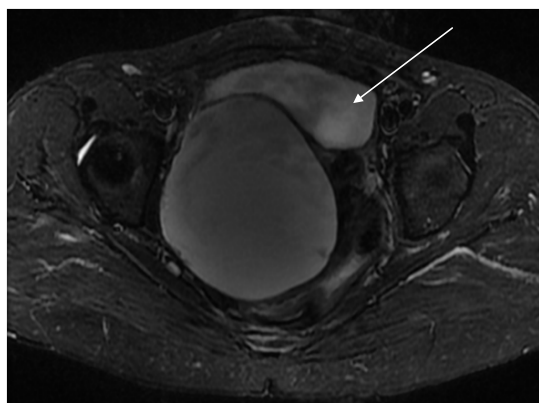


Figure 1: Magnetic Resonance Imaging (MRI) of ileal pouch demonstrating mucinous tumour (see arrow).

DISCUSSION

There have been only a few case reports of adenocarcinoma within ileal pouches after restorative proctocolectomy and IPAA in FAP.¹ In a recent literature review, only 21 cases were identified.² While malignancy is rare, risk of pouch adenomas is common and ranged between 6 to 75%²⁻⁵ Risk factors for development of pouch adenomas include >1000 colonic polyps and

age >50 years old 5, age of pouch, with pouches >10 years old at high risk of adenoma² and those who have previously developed pouch adenomas.³

It is unclear why the risk of malignant transformation in these patients is low, but most cohort studies have shown adenomas to be tubular or tubulovillous with only a small percentage demonstrating dysplasia. To the best of our knowledge, there have been no reports of mucinous tumours within an ileal pouch in the literature.

While the incidence of malignancy within an ileal pouch is low, this case illustrates the importance of surveillance for patients who have had restorative proctocolectomy and IPAA for FAP. Apart from ileal pouch malignancy, patients may also develop anastomotic site tumours and anal transitional zone tumours, although this is also a rare entity.⁶ Older pouches are more at risk of malignancy. In this case, the mucinous tumour was found thirteen years after restorative proctocolectomy and IPAA.

The Australian Clinical Practice Guidelines and European guidelines recommend annual pouch surveillance post restorative proctocolectomy and IPAA for FAP.^{7,8} As the risk of pouch adenoma and adenocarcinoma, anal transitional zone and anastomotic tumours increases with time, FAP patients post restorative proctocolectomy and IPAA should have lifelong surveillance.

CONFLICTS OF INTEREST

The authors have no conflicts of interest to declare.

REFERENCES

1. Friederich P, de Jong AE, Mathus-Vliegen LM, et al. Risk of developing adenomas and carcinomas in the ileal pouch in patients with familial adenomatous polyposis. *Clin Gastroenterol Hepatol*. 2008; 6(11): 1237-1242. doi: [10.1016/j.cgh.2008.06.011](https://doi.org/10.1016/j.cgh.2008.06.011)
2. Tajika M, Niwa Y, Bhatia V, Tanaka T, Ishihara M, Yamao K. Risk of ileal pouch neoplasms in patients with familial adenomatous polyposis. *World J Gastroenterol*. 2013; 19(40): 6774-6783. doi: [10.3748/wjg.v19.i40.6774](https://doi.org/10.3748/wjg.v19.i40.6774)
3. Zahid A, Kumar S, Koorey D, Young CJ. Pouch adenomas in Familial Adenomatous Polyposis after restorative proctocolectomy. *Int J Surg*. 2015; 13: 133-136. doi: [10.1016/j.ijso.2014.11.048](https://doi.org/10.1016/j.ijso.2014.11.048)
4. Pommaret E, Vienne A, Lefevre JH, et al. Prevalence and risk factors for adenomas in the ileal pouch and the afferent loop after restorative proctocolectomy for patients with familial adenomatous polyposis. *Surg Endosc*. 2013; 27(10): 3816-3822. doi: [10.1007/s00464-013-2980-x](https://doi.org/10.1007/s00464-013-2980-x)
5. Tonelli F, Ficari F, Bargellini T, Valanzano R. Ileal pouch adenomas and carcinomas after restorative proctocolectomy for familial adenomatous polyposis. *Dis Colon Rectum*. 2012; 55(3): 322-329. doi: [10.1097/DCR.0b013e318241e6f2](https://doi.org/10.1097/DCR.0b013e318241e6f2)
6. Ooi BS, Remzi FH, Gramlich T, Church JM, Preen M, Fazio VW. Anal transitional zone cancer after restorative proctocolectomy and ileoanal anastomosis in familial adenomatous polyposis: report of two cases. *Dis Colon Rectum*. 2003; 46(10): 1418-1423; discussion 1422-1423. doi: [10.1097/01.DCR.0000089057.20288.C9](https://doi.org/10.1097/01.DCR.0000089057.20288.C9)
7. Vasen HF, Möslein G, Alonso A, et al. Guidelines for the clinical management of familial adenomatous polyposis (FAP). *Gut*. 2008; 57(5): 704-713. doi: [10.1136/gut.2007.136127](https://doi.org/10.1136/gut.2007.136127)
8. NHMRC. NHMRC Clinical Practice Guidelines for the Prevention, Early Detection and Management of Colorectal Cancer. In: Chapter 7. High Risk Familial Colorectal Cancer Syndromes. 2005.