Openventio PUBLISHERS

ISSN 2377-164X

HEART RESEARCH

Open Journal

| May 2016 | Volume 2 | Issue 5 |

www.openventio.org

HEART RESEARCH

Openventio PUBLISHERS

ISSN 2377-164X

Open Journal

TABLE OF CONTENTS

HEART RESEARCH

Openventio PUBLISHERS

ISSN 2377-164X

Open Journal

http://dx.doi.org/10.17140/HROJ-2-e005

Editorial

*Corresponding author
Zhonghua Sun, PhD
Professor
Department of Medical Radiation Sciences
School of Science
Curtin University
GPO Box, U1987, Perth
WA 6845, Australia
Tel. +61-8-9266 7509
Fax: +61-8-9266 2377
E-mail: z.sun@curtin.edu.au

Volume 2 : Issue 5
Article Ref. #: 1000HROJ2e005

Article History
Received: November 20th, 2015
Accepted: November 20th, 2015
Published: November 20th, 2015

Citation
Sun Z. The PLATFORM trial: an insight into the improved value of using FFR_{CT} for reduction of invasive angiographic procedures. *Heart Res Open J.* 2015; 2(5): e13-e17. doi: 10.17140/HROJ-2-e005

The PLATFORM Trial: An Insight into the Improved Value of Using FFR_{CT} for Reduction of Invasive Angiographic Procedures

Zhonghua Sun*

Department of Medical Radiation Sciences, Curtin University, GPO Box U1987 Perth, WA 6845, Australia

Coronary CT Angiography (CCTA) has been widely used as a reliable non-invasive modality for the diagnosis of Coronary Artery Disease (CAD) due to its improved spatial and temporal resolution.[1-5] For patients with low to intermediate pre-test probability of CAD, CCTA is used as an effective gatekeeper for determination of downstream testing, such as invasive coronary angiography or functional imaging.[6] However, CCTA is mainly an anatomic test with excellent visualization of coronary anatomical structures and detection of coronary lumen stenosis, while providing little functional information of the coronary lesions. Despite high sensitivity and negative predictive value, CCTA has been reported to have moderate specificity and positive predictive value due to the high percentage of false positive rates, and this is especially apparent in the assessment of coronary arteries with heavy calcification. Studies have shown the limited diagnostic value of CCTA in diagnosing highly calcified coronary plaques.[7-11] Thus, an imaging technique able to detect ischemia-producing lesions is of paramount importance since coronary stenosis does not always translate to functional significance. Clinical decision making of whether patients should proceed to a revascularization procedure is based on the predictive functional effect of coronary stenosis, because no prognostic benefit of revascularization has been reported in the coronary lesions without functional significance.[12,13]

In recent years, a great interest has been shown in the investigation of diagnostic performance of non-invasive Fractional Flow Reserve derived from coronary CT angiography (FFR_{CT}). The scientific basis for non-invasive quantification of FFR_{CT} has been well described in the literature.[14] FFR_{CT} is computed by performing computational fluid dynamics modelling after image segmentation of coronary arteries and ascending aorta. The invasive FFR technique is conducted by using a pressure catheter to assess the rate of maximal myocardial blood flow through a coronary stenotic lesion in relation to the flow through the normal aorta in a hyperemic state.[15-17] The FFR is a lesion-specific technique and is widely used as the reference test for assessment of the functional significance of a coronary stenosis. According to the Fractional Flow reserve *versus* angiography for multivessel evaluation (FAME) trials, FFR-guided percutaneous coronary intervention has been shown to result in lower rate of major adverse cardiac events when compared to visual estimation from invasive coronary angiography or best available medical therapy alone.[18,19] However, invasive FFR is rarely performed in clinical practice, thus, a non-invasive method combining both anatomic and functional data to determine the hemodynamic significance of coronary lesions could serve as an alternative to invasive FFR for improvement of patient care and clinical outcomes.

In the PLATFORM prospective multicentre trial, Douglas, et al. compared the clinical outcomes of symptomatic patients with an intermediate likelihood of obstructive CAD, who were assigned to undergo either the planned usual care testing or CCTA/FFR_{CT} testing.[20] A total of 584 patients were recruited from 11 clinical sites with 287 receiving usual testing and 297 receiving CCTA/FFR_{CT} testing. The 90-day follow-up visits were reported in this study to

ISSN 2377-164X Open Journal http://dx.doi.org/10.17140/HROJ-2-e005

determine the cardiac event rates. The authors reported that non-obstructive CAD was found at Invasive Coronary Angiography (ICA) in 73% of the patients in the usual care group with intended ICA. In contrast, non-obstructive CAD was found at ICA in 12% of the patients in the CCTA/FFR_{CT} group, which is significantly lower than that observed in the usual care group (p<0.0001) (Figure 1). Among those with planned non-invasive testing, no significant difference was found in the rates of non-obstructive CAD at ICA between the two groups (6.0 usual care *vs.* 12.5% CCTA/FFR_{CT}, p=0.95) (Figure 1). There were no significant differences in cardiac events between these two groups. The authors concluded that use of CCTA/FFR_{CT} can be more effectively triage patients than the use care approach for invasive procedures since ICA was cancelled in 61% patients based on the results of CCTA/FFR_{CT}.

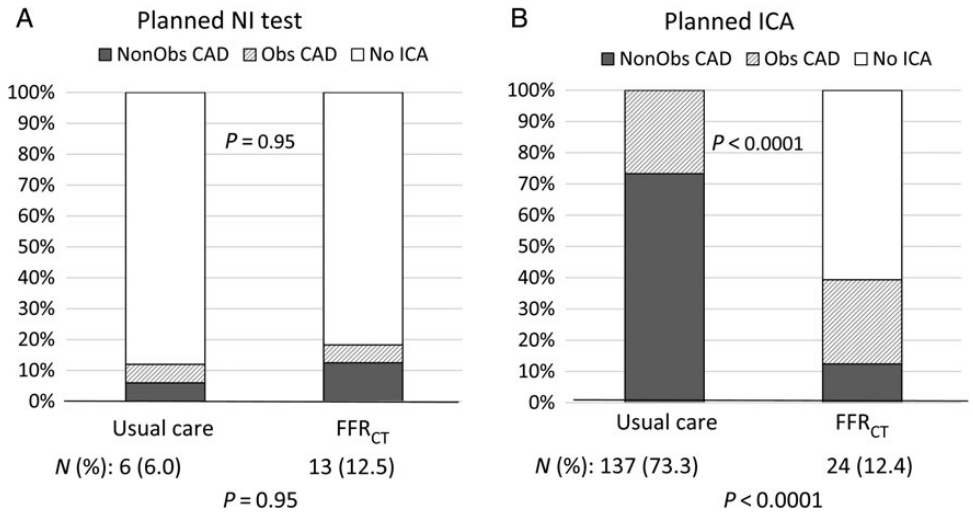

Figure 1: Determination of the rate of invasive catheterization without obstructive coronary artery disease. NI: Non-invasive; ICA: Invasive Coronary Angiography; Obs CAD: Obstructive Coronary Artery Disease; FFR_{CT}: Computation of fractional flow reserve from coronary computed tomographic angiography data.[20]

There are 2 observations from Douglas's study that bear discussion. First, improved diagnostic strategy has been achieved in patient managements based on analysis of CCTA/FFR_{CT}, with a significantly low rate of ICA showing non-obstructive CAD. This further verifies the advantage of FFR_{CT} over CCTA in the diagnostic assessment of coronary stenosis. According to a recently published randomized controlled PROMISE trial, coronary CTA was found to increase the rate of invasive catheterization by 50% compared with functional testing.[21] Clinical value of FFR_{CT} in comparison with CCTA has been reported in three multicenter trials, Diagnosis of Ischemia-Causing Coronary Stenoses by Non-invasive FFR Computed from Coronary Computed Tomographic Angiograms (DISCOVER-FLOW), Determination of Fractional Flow Reserve by Anatomic Computed Tomographic Angiography (DeFACTO), and NeXtsTeps (NXT) trials.[22-24] Findings of these trials confirm that FFR_{CT} is superior to CCTA for the diagnosis of ischemia-causing lesions on both per-patient and per-vessel analysis as determined by an invasive FFR the reference standard. Table 1 shows the diagnostic value of FFR_{CT} *versus* CCTA in stable patients with suspected CAD based on the analysis of these three trials.

Diagnostic value CCTA/FFR_{CT}	DISCOVER-FLOW[22]		NXT[24]		DeFACTO[23]
	Per-patient assessment	Per-vessel assessment	Per-patient assessment	Per-vessel assessment	Per-patient assessment
CCTA≥ 50%					
Sensitivity	94	91	94	83	84
Specificity	25	40	34	60	42
PPV	58	47	40	33	61
NPV	80	89	92	92	72
FFR_{CT} ≤ 0.80					
Sensitivity	93	88	86	84	90
Specificity	82	82	79	86	54
PPV	85	74	65	61	67
NPV	91	92	93	95	84

PPV: Positive Predictive Value, NPV: Negative Predictive Value.

Table 1: Three multicenter trials comparing FFR_{CT} with CCTA with invasive FFR as the gold standard.

ISSN 2377-164X Open Journal http://dx.doi.org/10.17140/HROJ-2-e005

Second, ICA examination is associated with high rate of non-obstructive CAD as shown in Figure 1. Although physicians' angiographic interpretation of coronary stenosis has been reported to have substantial disagreement from quantitative coronary angiographic images,[25,26] the visual readings in Douglas's study were low (57%) as the findings of determining non-obstructive CAD in ICA patients were determined by quantitative coronary angiography. This further highlights the limitation of ICA as an anatomic test or a luminogram. The role of ICA is gradually diminishing as compared to other imaging modalities such as CCTA or intravascular ultrasound,[27,28] which are able to look beyond the lumen and characterize plaque morphology or vessel wall, thus, enabling detection of vulnerable coronary plaques responsible for development of adverse cardiac events. ICA remains the gold standard for the detection of coronary stenosis, however, according to the PROSPECT, the largest prospective study to investigate the natural history of CAD,[29] the majority of non-culprit lesions responsible for acute coronary syndrome at a median follow-up of 3.4 years were mild lesions with diameter stenosis of 32% at baseline angiographic examination. Therefore, combining anatomic with functional imaging modalities represents a future direction for determination of functional significance of coronary lesions.

In summary, the PLATFORM trial adds additional value to other two recently published randomized controlled trials involving diagnostic performance of CCTA in CAD, the PROMISE and SCOT-HEART trials.[21,30] Like all large multicenter trials, PLATFORM has limitations. It is not a randomized controlled trial. Further, the sample size and short follow-up period (90 days) make it difficult to detect the impact on clinical outcomes. Further studies with inclusion of a large cohort at longer follow-up periods are warranted.

REFERENCES

1. Sun Z, Cao Y, Li HF. Multislice computed tomography angiography in the diagnosis of coronary artery disease. *J Geriatr Cardiol*. 2011; 8: 104-113. doi: 10.3724/SP.J.1263.2011.00104

2. Sun Z. Cardiac CT imaging in coronary artery disease: current status and future directions. *Quant Imaging Med Surg*. 2012; 2: 98-105. doi: 10.3978/j.issn.2223-4292.2012.05.02

3. Sun Z, Choo GH, Ng KH. Coronary CT angiography: current status and continuing challenges. *Br J Radiol*. 2012; 85: 495-510. doi: 10.1259/bjr/15296170

4. Pelliccia F, Pasceri V, Evangelista A, et al. Diagnostic accuracy of 320-row computed tomography as compared with invasive coronary angiography in unselected, consecutive patients with suspected coronary artery disease. *Int J Cardiovasc Imaging*. 2013; 29: 443-452. doi: 10.1007/s10554-012-0095-4

5. Sun Z, Lin C. Diagnostic value of 320-slice coronary CT angiography in coronary artery disease: a systematic review and meta-analysis. *Curr Med Imaging Rev*. 2014; 10: 272-280. doi: 10.2174/1573405610041501211408 36

6. Sun Z, Abdul Aziz Y, Ng KH. Coronary CT angiography: how should physicians use it wisely and when do physicians request it appropriately? *Eur J Radiol*. 2012; 81: e684-e687. doi: 10.1016/j.ejrad.2011.06.040

7. Sun Z, Xu L, Fan Z. Coronary CT angiography in calcified coronary plaques: comparison of diagnostic accuracy between bifurcation angle measurement and coronary lumen assessment for diagnostic significant coronary stenosis. *Int J Cardiol*. 2016; 203: 78-86. doi: 10.1016/j.ijcard.2015.10.079

8. Xu L, Sun Z. Coronary CT angiography evaluation of calcified coronary plaques by measurement of left coronary bifurcation angle. *Int J Cardiol*. 2015; 182: 229-231. doi: 10.1016/j.ijcard.2014.12.114

9. Chen CC, Chen CC, Hsieh IC, et al. The effect of calcium score on the diagnostic accuracy of coronary computed tomography angiography. *Int J Cardiovasc Imaging*. 2011; 27 (Suppl 1): 37-42. doi: 10.1007/s10554-011-9955-6

10. Palumbo A, Maffei E, Martini C, et al. Coronary calcium score as gatekeeper for 64-slice computed tomography coronary angiography in patients with chest pain: per-segment and per-patient analysis. *EurRadiol*. 2009; 19: 2127-2135. doi: 10.1007/s00330-009-1398-2

11. Park MJ, Jung JI, Choi YS, et al. Coronary CT angiography in patients with high calcium score: evaluation of plaque characteristics and diagnostic accuracy. *Int J Cardiovasc Imaging*. 2011; 27: 43-51. doi: 10.1007/s10554-011-9970-7

12. Pijls NH, van Schaardenburgh P, Manoharan G, et al. Percutaneous coronary intervention of functionally nonsignificant stenosis: 5-year follow-up of the DEFER study. *J Am Coll Cardiol*. 2007; 49: 2105-2111. doi: 10.1016/j.jacc.2007.01.087

13. Tonino PA, De Bruyne B, Pijls NH, et al. Fractional flow reserve versus angiography for guiding percutaneous coronary intervention. *N Engl J Med*. 2009; 360: 213-224. doi: 10.1056/NEJMoa0807611

14. Taylor CA, Fonte TA, Min JK. Computational fluid dynamics applied to cardiac computed tomography for noninvasive quantification of fractional flow reserve: scientific basis. *J Am Coll Cardio*l. 2013; 61: 2233-2241. doi: 10.1016/j.jacc.2012.11.083

15. De Bryune B, Baudhuin T, Melin JA, et al. Coronary flow reserve calculated from pressure measurements in humans. Validation with positron emission tomography. *Circulation*. 1994; 89: 1013-1022. doi: 10.1161/01.CIR.89.3.1013

16. Berger A, Botman KJ, MacCarthy PA, et al. Long-term clinical outcome after fractional flow reserve-guided percutaneous coronary intervention in patients with multivessel disease. *J Am Coll Cardiol*. 2005; 46: 438-442. doi: 10.1016/j.jacc.2005.04.041

17. Pijls NH, van Son JA, Kirkeeide RL, De Bruyne B, Gould KL. Experimental basis of determining maximum coronary, myocardial, and collateral blood flow by pressure measurements for assessing functional stenosis severity before and after percutaneous transluminal coronary angioplasty. *Circulation*. 1993; 87: 1354-1367. doi: 10.1161/01.CIR.87.4.1354

18. Fearon WF, Bornschein B, Tonino PA, et al. Fractional flow reserve versus angiography for multivessel evaluation (FAME) study investigators. Economic evaluation of fractional flow reserve-guided percutaneous coronary intervention in patients with multivessel disease. *Circulation*. 2010; 122: 2545-1250. doi: 10.1136/heartjnl-2014-306578

19. De Bruyne B, Pijls NH, Kalesan B, et al. FAME 2 Trial Investigators. Fractional flow reserve-guided PCI versus medical therapy in stable coronary disease. *N Engl J Med*. 2012; 367: 991-1001. doi: 10.1056/NEJMoa1205361

20. Douglas PS, Pontone G, Hlatky MA, et al. Clinical outcomes of fractional flow reserve by computed tomographic angiography-guided diagnostic strategies vs. usual care in patients with suspected coronary artery disease: the prospective longitudinal trial of FFR_{CT}: outcome and resource impacts study. *Eur Heart J*. 2015. doi: 10.1093/eurheartj/ehv444

21. Douglas PS, Hoffmann U, Patel MR, et al. PROMISE Investigators. Outcomes of anatomical versus functional testing for coronary artery disease. *N Engl J Med*. 2015; 372: 1291-1300. doi: 10.1056/NEJMoa1415516

22. Koo BK, Erglis A, Doh JH, et al. Diagnosis of ischemia-causing coronary stenoses by noninvasive fractional flow reserve computed from coronary computed tomographic angiograms. Results from the prospective multicenter discover-flow (diagnosis of ischemia-causing stenoses obtained via noninvasive fractional flow reserve) study. *J Am Coll Cardiol*. 2011; 58: 1989-1997. doi: 10.1016/j.jacc.2011.06.066

23. Min JK, Leipsic J, Pencina MJ, et al. Diagnostic accuracy of fractional flow reserve from anatomic CT angiography. *JAMA*. 2012; 308: 1237-1245. doi: 10.1001/2012.jama.11274

24. Norgaard BL, Leipsic J, Gaur S, et al. Diagnostic performance of non-invasive fractional flow reserve derived from coronary CT angiography in suspected coronary artery disease: the NXT trial. *J Am Coll Cardiol.* 2014; 63: 1145-1155. doi: 10.1016/j.jacc.2013.11.043

25. Nallamothu BK, Spertus JA, Lansky AJ, et al. Comparison of clinical interpretation with visual assessment and quantitative coronary angiography in patients undergoing percutaneous coronary intervention in contemporary practice: the assessing angiography (A2) project. *Circulation*. 2013; 127: 1793-1800. doi: 10.1161/CIRCULATIONAHA.113.001952

26. Patel MR, Peterson ED, Dai D, et al. Low diagnostic yield of elective coronary angiography. *N Engl J Med*. 2010; 362: 886-895. doi: 10.1056/NEJMoa0907272

27. Chan KH, Ng MKC. Is there a role for coronary angiography in the early detection of the vulnerable plaque? *Int J Cardiol*. 2013; 164: 262-266. doi: 10.1016/j.ijcard.2012.01.027

ISSN 2377-164X Open Journal http://dx.doi.org/10.17140/HROJ-2-e005

28. Colombo A, Panoulas VF. Diagnostic coronary angiography is getting old. *JACC Cardiovasc Imaging*. 2015; 8: 11-13. doi: 10.1016/j.jcmg.2014.11.003

29. Stone G, Maehara A, Lansky A, et al. A prospective natural-history study of coronary atherosclerosis. *N Engl J Med*. 2011; 364: 226-235. doi: 10.1056/NEJMoa1002358

30. Newby DE on behalf of the SCOT-HEART Investigators. CT coronary angiography in patients with suspected angina due to coronary heart disease (SCOT-HEART): an open-label, parallel-group, multicentre trial. *Lancet*. 2015; 385: 2383-2391. doi: 10.1016/S0140-6736(15)60291-4

HEART RESEARCH

Openventio PUBLISHERS

ISSN 2377-164X

Open Journal

http://dx.doi.org/10.17140/HROJ-2-123

Case Report

*Corresponding author
Matteo Bertini, MD, PhD
Department of Cardiology
S. Anna Hospital
University of Ferrara
Via Aldo Moro 8
Cona-Ferrara 44124, Italy
Tel. +39 532 236269
Fax: +39 532 236593
E-mail: doc.matber@gmail.com

Volume 2 : Issue 5
Article Ref. #: 1000HROJ2123

Article History
Received: November 9th, 2015
Accepted: November 23rd, 2015
Published: November 25th, 2015

Citation
Leonetti E, Malagù M, Bertini M. An emergent echo-guided apical pericardiocentesis for cardiac tamponade in a patient with only the left lung. *Heart Res Open J*. 2015; 2(5): 131-133. doi: 10.17140/HROJ-2-123

An Emergent Echo-Guided Apical Pericardiocentesis for Cardiac Tamponade in a Patient with only the Left Lung

Emanuela Leonetti, Michele Malagù and Matteo Bertini*

Department of Cardiology, S. Anna Hospital, University of Ferrara, Cona-Ferrara, Italy

ABSTRACT

A 74 years old man with previous right pneumonectomy was admitted with cardiac tamponade. Pericardiocentesis was attempted through sub-xiphoid approach but was not feasible. Therefore, second echo-guided pericardiocentesis was performed by apical approach with success. We present our experience of apical pericardiocentesis in a patient with only the left lung.

KEYWORDS: Cardiac tamponade; Pericardiocentesis; Apical approach.

INTRODUCTION

Pericardiocentesis is an emergent life-saving procedure in patients with cardiac tamponade. Pericardiocentesis is generally safe, but may lead to complications (perforation of the heart, artery, lung or liver). The failure of the procedure may evolve in patient death. Preferred approach for pericardiocentesis is sub-xifoid but other approaches may be required.

CASE REPORT

A 74 years old man came to the emergency department complaining of severe dyspnea and reduced exercise tolerance. The patient reported no significant cardiovascular history but a history of lung cancer treated with right pneumonectomy, followed by local radiotherapy, which required an oesophagus endoprosthesis implantation due to post-radiation stenosis.

On physical examination, his blood pressure was 90/70 mm Hg, heart rate 130 beats per minute. There was elevated jugular venous pressure, peripheral oedema and pulsus paradoxus. The electrocardiogram showed sinus tachycardia with low voltage and a thoracic Computed Tomography (CT) revealed severe pericardial effusion (Figure 1). Because of this, the patient was immediately admitted to our Intensive Care Unit (ICU). A bedside echocardiogram confirmed the large pericardial effusion and a right atrium diastolic collapse. The poor quality sub-xiphoid pericardial window did not allow the visualization of a pericardial sack, which was detected by parasternal and apical views (Figure 1).

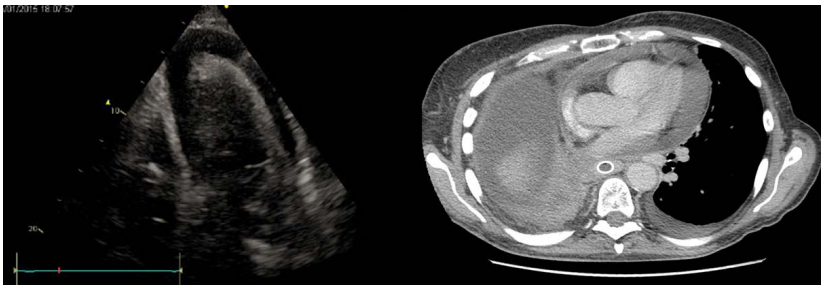

Figure 1: Echocardiogram and thoracic CT showing massive pericardial effusion.

ISSN 2377-164X Open Journal http://dx.doi.org/10.17140/HROJ-2-123

A sub-xiphoid pericardiocentesis was attempted without success. In view of the severe clinical instability of the patient, a second echo-guided pericardiocentesis was performed, this time by the apical approach (Figure 2). Cardiac apex was identified with palpation and echocardiogram in fifth intercostal space between emiclavear line and anterior axillary line. The needle tip was evident on echocardiographic images acquired through parasternal view through injection of agitated saline, and images were used to identify the optimal point to penetrate the pericardium and safely drainage the effusion. This maneuver was successful and 400 ml of blood-serum fluid were aspirated resulting in immediate improvement in symptoms, increase of blood pressure (110/80 mm Hg) and reduction of heart rate (90 bpm). The echocardiogram showed complete resolution of pericardial effusion (Figure 3). Finally, chest radiograph confirmed absence of pneumothorax or lung injury (Figure 2). Cytological examination of pericardial fluid showed reactive blood cells. The patient left the hospital 5 days later in good clinical condition and has been doing well since.

DISCUSSION

Cardiac tamponade is a life-threatening condition. Consequently, percutaneous pericardiocentesis is a life-saving therapy. Echo-guided pericardiocentesis, performed *via* sub-xiphoid, apical or parasternal approach, has smaller risk of major complication than blind pericardiocentesis.[1-3] The sub-xiphoid approach is considered the safest.[2,3] In our patient this approach was attempted but was not feasible, probably because of the anatomy and the fibrosis due to both previous radiation exposure and the recent surgery. In this particular case, the apical approach was a very high-risk procedure in view of the previous right pneumonectomy and the risk of left pneumothorax, which could be life-threating in a patient with only the left lung. However, the instability of the patient and the distribution of pericardial effusion in the apical region encouraged us to take the risk to perform this maneuver by the apical approach through echocardiographic guidance. Luckily, the procedure was successful and we obtained a rapid improvement of the clinical condition without complications. We did not consider the parasternal approach because of the risk of pneumothorax and of puncturing the internal thoracic artery.

To our knowledge this is the first report of pericardiocentesis through apical approach in a patient with only the left lung. Our case suggests that in emergency condition pericardiocentesis *via* apical approach with ultrasound guidance may be considered despite its high intrinsic risk. In order to avoid pur-

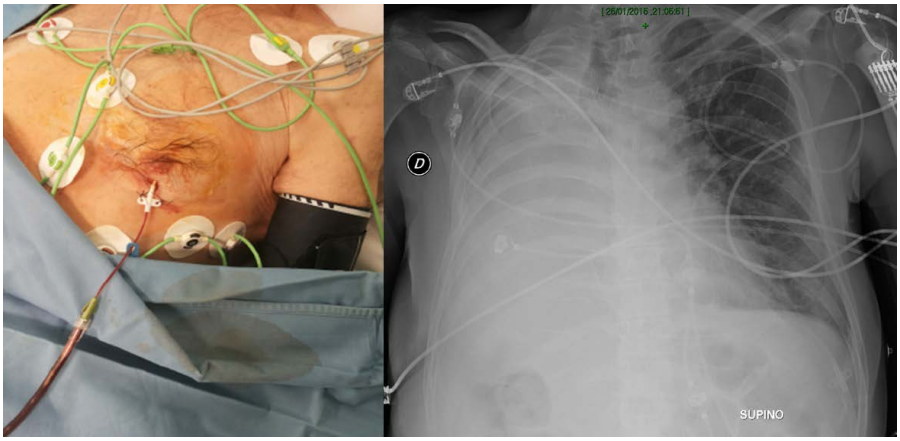

Figure 2: Pericardiocentesis apical approach.

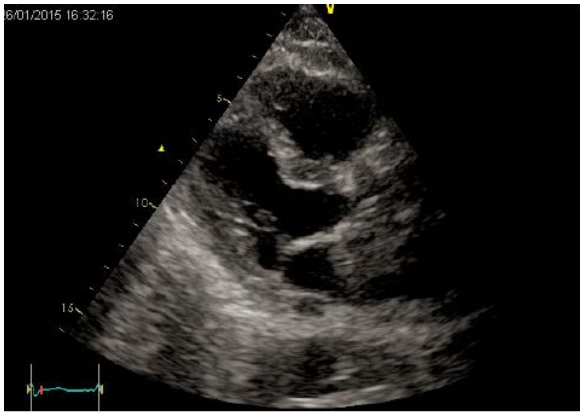

Figure 3: Repeat echocardiogram showing resolution of pericardial effusion.

ISSN 2377-164X Open Journal http://dx.doi.org/10.17140/HROJ-2-123

suing the sub-xiphoid approach if this is not immediate, clinicians can consider the apical approach that may be successful in particular under ultrasound guidance. In absence of previous description of such cases in literature, this report may be useful to clinicians for the management of patients in similar situations.

CONFLICTS OF INTEREST

The authors declare that they have no conflicts of interest.

ACKNOWLEDGMENTS

This work was supported by a grant from Fondazione Anna Maria Sechi per il Cuore (FASC), Italy. The funders had no role in the study design, data collection and analysis, decision to publish or the preparation of the manuscript.

CONSENT

No consent is required for the publication of this case report.

REFERENCES

1. Callahan JA, Seward JB, Nishimura RA, et al. Two-dimensional echocardiographically guided pericardiocentesis: experience in 117 consecutive patients. *Am J Cardiol.* 1985; 55: 476-479. doi: 10.1016/0002-9149(85)90397-2

2. Spodick DH. Acute cardiac tamponade. *New Engl J Med*. 2003; 349: 684-690. doi: 10.1056/NEJMra022643

3. Fitch MT, Nicks BA, Pariyadath M, et al. Emergency pericardiocentesis. *New Engl J Med.* 2012; 366: e17. doi: 10.1056/NEJMvcm0907841

HEART RESEARCH

Openventio PUBLISHERS

ISSN 2377-164X

Open Journal

http://dx.doi.org/10.17140/HROJ-2-124

Brief Report

***Corresponding author**
Vineet Bhatia, MD
Senior Consultant Cardiologist
Department of Cardiology
A 601, Prateek fedora
Sector 61, Noida
Uttar pradesh, India
Tel. +91-9818168874
E-mail: vinmonica@yahoo.co.in

Volume 2 : Issue 5
Article Ref. #: 1000HROJ2124

Article History
Received: March 22nd, 2016
Accepted: April 1st, 2016
Published: April 4th, 2016

Citation
Bhatia V, Minocha A, Arora P, Kaul U. Carcinoid heart disease: classical echocardiographic features. *Heart Res Open J.* 2016; 2(5): 134-136. doi: 10.17140/HROJ-2-124

Carcinoid Heart Disease: Classical Echocardiographic Features

Vineet Bhatia, MD[1*]; Anil Minocha, MD[2]; Parneesh Arora, MD[3]; Upendra Kaul, MD[4]

[1]Senior Consultant, Department of Cardiology, Fortis Hospital, Noida, UP, India
[2]Consultant, Department of Cardiology, Fortis Hospital, Noida, UP, India
[3]Principal Consultant, Department of Cardiology, Fortis Hospital, Noida, UP, India
[4]Executive Director and Dean, Fortis Escorts and Fortis Hospital, Vasant Kunj, New Delhi, India

ABSTRACT

Carcinoid Heart Disease (CHD) is an important and rare cause of acquired valvular heart disease. Clinical examination supplemented with Echocardiographic evaluation may give the first clue towards an under lying carcinoid tumor. We report a case with classical Echocardiographic features of carcinoid heart disease.

INTRODUCTION

Carcinoid tumors are rare neuro endocrine tumors arising in 1.2 to 2.1% per 1000,000 people in the general population per year.[1] They most commonly originate from the gastrointestinal tract (foregut) or the bronchus (midgut) and usually clinically asymptomatic until metastases are present. The foregut carcinoids metastasize to the liver or abdominal lymph nodes and may present with bowel obstruction. In 20-30% cases they may present with manifestations secondary to the release of vasoactiveamines (serotonin, bradykinin and histamine) which are referred to as Carcinoid Syndrome (CS). The classical triad of CS is flushing, diarrhea and bronchospasm. 50% cases of CS develop Carcinoid Heart Disease (CHD) a major cause of morbidity and mortality in such patients especially when hepatic metastases is present.[2] Cardiac involvement is also thought to be secondary to the actions of these vasoactive amines.[3] We recently came across a patient with a fore gut carcinoid with hepatic metastases and CHD who had classical echocardiographic findings of this rare disease. CHD may be the initial presentation in 20% cases of CS. Hence one should be aware of these echocardiographic findings as they may be the first clue of this intriguing disease.

CASE REPORT

A 62-year old male, known case of foregut carcinoid (arising from the first part of duodenum) with hepatic metastases was referred to us with progressive breathlessness. On examination he had features of right sided heart failure. Transthoracic Echocardiography revealed dilated right atrium (RA) and right ventricle (RV). The anterior and septal leaflets of the tricuspid valve (TV) were thickened, shortened, retracted and fixed in open position giving rise to severe low pressure tricuspid regurgitation (TR) (Figures 1, 2 and 3). On continuous wave doppler, severe TR was characterized by a dagger shaped profile with an early peaked velocity and a rapid decline suggestive of rapid pressure equalization between the right sided cardiac chambers (Figure 4). These features are classical of carcinoid heart disease. The pulmonary and mitral valves were morphologically normal. The RV contractility was reduced how ever the examination of the left side of the heart was un-remarkable. There was mild pericardial effusion. The inferior vena cava was dilated with loss of respiratory collapsibility. Management was initiated with fluid restriction, decongestive therapy with intravenous diuretics with resolution of symptoms. He was also on octreotide which has led to disease stabilization.

ISSN 2377-164X Open Journal http://dx.doi.org/10.17140/HROJ-2-124

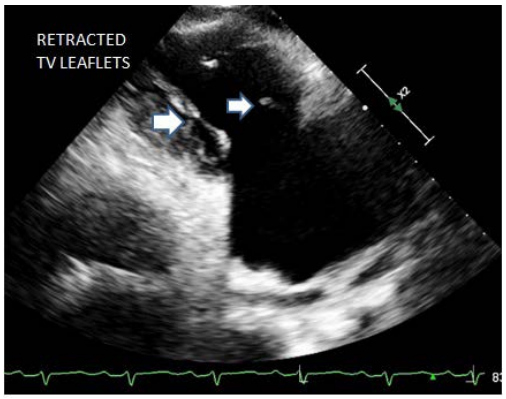

Figure 1: Retracted and shortened leaflets of the Tricuspid valve (TV).

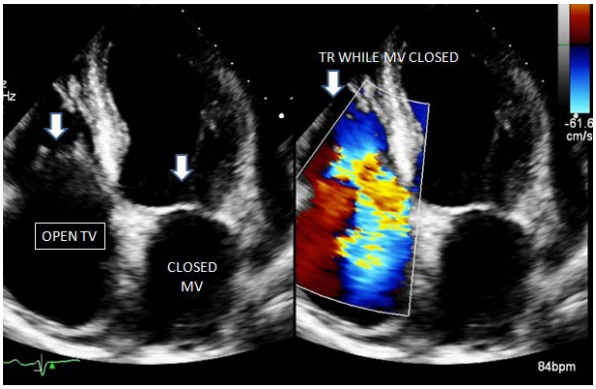

Figure 2: Simultaneous visualization of the Tricuspid valve (TV) and mitral valve (MV) in systole shows an open TV with severe tricuspid regurgitation while the MV is closed.

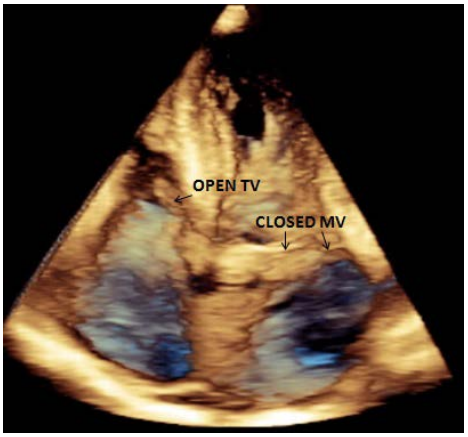

Figure 3: 3D image showing the same features as mentioned in figure 2.

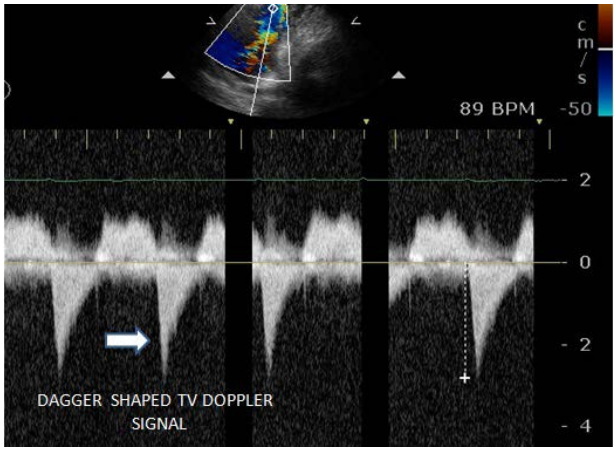

Figure 4: Continuous wave Doppler signal from TV shows dagger shaped profile with early peaked velocity.

DISCUSSION

In patients with CHD vasoactive substances such as serotonin have been implicated to cause endo-cardial damage and plaque formation which in turn leads to valvular damage. Right heart involvement is more common than left sided because these structures are directly exposed to the vasoactive substances which otherwise undergo protective first pass metabolism in the lungs as in the present case. Though right sided valvular lesions are commonest the cardiac chambers may also be involved.[4] The tricuspid and pulmonary valves are commonly regurgitant and less commonly stenotic. Pulmonic stenosis is commoner than tricuspid stenosis as the pulmonary valve orifice is smaller and the plaques on the valves, in the annulus and sinuses lead to a narrowed pulmonic root.[2,4] Left sided lesions occur in <10% cases and may present with mitral or aortic regurgitation.[2] Myocardial metastasis are rare and may occur in 4% cases[5] while pericardial effusion occurs in 14% cases and patient for a men ovale (PFO) in 7% cases. PFOs are common in patients with left sided involvement (87%) and may be mechanism by which the vasoactive substances reach the left side of the heart by passing the lung.

Without treatment, the median duration of survival with malignant carcinoid syndrome ranges from 12 to 38 months from the onset of systemic symptoms.[6] The major therapeutic modality in such patients consists of symptom control, usually with a somatostatin analog (octreotide or lanoreotide). Tumor removal is of limited value since patients with carcinoid syndrome typically have metastatic disease and chemotherapy has not had much success. As a result, more aggressive approaches, such as surgical debulking of the liver and hepatic artery embolization, are often used.

The stenotic right sided valves may be subject to balloon valvuloplasty in selected cases but symptom recurrence rates are high. In some cases with extensive structural defects valve surgery may be the only definitive treatment. Patients with carcinoid heart disease usually die as a result of severe tricuspid regurgitation rather than carcinomatosis.[7] An aggressive approach with surgery soon after the onset of cardiac symptoms may be the answer, as delay can result in worsening right ventricular failure and increase the risk of surgery. Peri-operative management may involve the use of an intravenous bolus or infusion of octreotide to reduce the risk of intra operative hypotension. Anti-histamines are also used before surgery to prevent flushing and bronchospasm; corticosteroids can be used to reduce bradykinin production.

ISSN 2377-164X Open Journal http://dx.doi.org/10.17140/HROJ-2-124

In the tricuspid position, mechanical prostheses are believed to be adequately durable and relatively unaffected by the vasoactive substances causing the original valve pathology.[8] However, long-term oral anti-coagulation may pose serious bleeding issues as these patients invariably have extensive hepatic metastases. Bio-prosthetic valve have an edge as anti-coagulation is not needed how ever may undergo early degeneration. Tricuspid valve repair is usually not an option due to severe valvular destruction. There is some debate regarding the optimal surgical management of the pulmonary valve; the two options include valvectomy or valve replacement. Although the data are sparse, a recent small study of 22 patients suggested that pulmonary valve replacement reduced the risk of right heart dilatation post-operatively.[9] CHD is an important cause of acquired valular heart disease in patients with neuroendocrine tumors. CHD warrants aggressive treatment as this condition carries high degree of morbidity and mortality.

CONFLICTS OF INTEREST: None.

REFERENCES

1. Modlin IM, Sandor A. An Analysis of 8305 cases of carcinoid tumors. *Cancer*. 1997; 79(4): 813-829. doi: 10.1002/(SICI)1097-0142(19970215)79:4<813::AID-CNCR19>3.0.CO;2-2

2. Pellikka PA, Tajik AJ, Khandheria BK, et al. Carcinoid heart disease. Clinical and Echocardiographic spectrum in 74 patients. *Circulation*. 1993; 87(4): 1188-1196. doi: 10.1161/01.CIR.87.4.1188

3. Spatz M. Pathogenetic studies of experimentally induced heart lesions and their relation to carcinoid syndrome. *Laboratory Investigation*. 1964; 13: 288-300.

4. Lundin L, Norheim I, Landelius J, et al. Carcinoid heart disease: relationship of circulating vasoactive substances to ultrasound-detectable cardiac abnormalities. *Circulation*. 1988; 77(2): 264-269. doi: 10.1161/01.CIR.77.2.264

5. Pandya U , Pellikka P, Enriquez-Sarano M, et al. Metastatic carcinoid tumor to the heart: Echocardiographic-pathologic study of 11 patients. *J Am Coll Cardiol*. 2002; 40(7): 1328-1332. doi: 10.1016/S0735-1097(02)02109-5

6. Hajdu SI, Winawer SJ, Myers WP. Carcinoid tumors: A study of 204 cases. *Am J Clin Pathol*. 1974; 61(4): 521-528. doi: 10.1093/ajcp/61.4.521

7. Connolly HM, Nishimura RA, Smith HC, et al. Outcome of cardiac surgery for carcinoid heart disease. *J Am Coll Cardiol*. 1995; 25: 410-416. doi: 10.1016/0735-1097(94)00374-Y

8. Fox DJ, Khattar RS. Carcinoid Heart Disease: presentation, diagnosis and management. *Heart.* 2004; 90(10): 1224-1228. doi: 10.1136/hrt.2004.040329

9. Defraigne JO, Jerusalem O, Soyeur D, et al. Successful tricuspid valve replacement and pulmonary valvotomy for carcinoid heart disease. *Acta Chiurge Belg*. 1996; 96: 170-176.

HEART RESEARCH

Openventio PUBLISHERS

ISSN 2377-164X

Open Journal

http://dx.doi.org/10.17140/HROJ-2-125

Review

*Corresponding author
Zhonghua Sun, PhD, FSCCT
Professor
Department of Medical Radiation Sciences
School of Science, Curtin University
GPO Box, U1987, Perth
Western Australia 6845
Australia
Tel. +61-8-9266 7509
Fax: +61-8-9266 2377
E-mail: z.sun@curtin.edu.au

Volume 2 : Issue 5
Article Ref. #: 1000HROJ2125

Article History
Received: March 31st, 2016
Accepted: April 20th, 2016
Published: April 25th, 2016

Citation
Sun Z. Effects of iterative reconstruction on the diagnostic assessment of coronary calcium scores. *Heart Res Open J*. 2016; 2(5): 137-143. doi: 10.17140/HROJ-2-125

Effects of Iterative Reconstruction on the Diagnostic Assessment of Coronary Calcium Scores

Zhonghua Sun, PhD, FSCCT*

Department of Medical Radiation Sciences, Curtin University, GPO Box U1987 Perth, Western Australia 6845, Australia

ABSTRACT

Coronary Artery Calcium (CAC) score is a widely used indicator to determine disease severity and predict the risk of severe cardiac events. However, radiation dose associated with coronary CT scanning for CAC scoring raises concerns, especially for asymptomatic patients. Iterative Reconstruction (IR) technique represents a recently developed image processing approach for reduction of image noise and radiation dose, while improving diagnostic image quality. Despite these advantages over conventional filtered back projection technique, effects of IR techniques on CAC scores remain unclear. This review article aims to provide an overview of clinical applications of IR techniques in coronary CT angiography with a focus on the effects of different IR techniques on CAC score assessment.

KEYWORDS: Coronary calcium score; Coronary artery disease; Diagnosis; Calcified plaque; Image processing; Iterative reconstruction.

INTRODUCTION

Coronary Artery Calcium (CAC) scoring is considered a reliable, noninvasive technique for determining coronary plaque burden, risk stratification and reclassification of risk of coronary artery disease.[1] CAC scoring used to be performed by electron beam CT (EBCT), but has now been replaced by coronary CT angiography (CTA) due to rapid technical developments of multi slice CT scanners over the last 15 years.[2-4] The rationale behind CAC scoring is that coronary calcification represents atherosclerotic changes in the coronary arterial wall, thus, measurement of the amount of calcium is usually performed to estimate the amount of coronary atherosclerosis and consequently, the risk of coronary artery disease (CAD).[5] Although different calcium scoring techniques have been proposed and used in clinical practice, such as Agatston score, volume score and mass score, with each of them having strengths and limitations,[6] the Agatston score is the most widely used method for quantification of CAC in routine clinical practice during coronary CT imaging.

The extent of coronary calcification has been shown to be closely related to the risk of major adverse cardiac events; therefore, quantitative assessment of coronary calcifications by coronary CTA has become a risk stratification scheme for patients with suspected CAD. However, image quality of coronary CTA depends on image reconstruction process. In recent years, iterative reconstruction (IR) an alternative to conventional filtered back projection (FBP) has been increasingly used in coronary CTA due to the following advantages: reduce image noise and radiation dose, in particular, significant dose reduction by up to 80% compared to FBP, while still preserving diagnostic image quality.[7] A recent systematic review has shown that IR serves as a feasible alternative to the standard FBP in coronary CTA with significant lower radiation dose, improved image quality and high diagnostic value in the diagnosis of CAD.[8]

ISSN 2377-164X Open Journal http://dx.doi.org/10.17140/HROJ-2-125

Despite these promising results of using IR in coronary CTA for dose reduction and image quality improvement, the effect of IR on image appearance change compared to FBP reconstructions should not be ignored. There is concern that this effect may generate negative impact of coronary CTA on coronary plaque characterization, in particular, quantification of high CAC, or severely calcified plaques. While beneficial effects of IR in coronary CTA have been reported to reduce blooming artifacts in highly calcified plaques and coronary stents,[9-11] effects of IR on CAC scoring are contradictory and debatable. This review provides an overview of the clinical applications of IR in coronary CTA with regard to its effects on CAC score, with a focus on how IR techniques affect CAC scoring and patient stratification.

DIAGNOSTIC VALUE OF CORONARY CTA IN HEAVILY CALCIFIED PLAQUES

Coronary CTA has been widely accepted as a less invasive imaging modality with high diagnostic value in coronary artery disease. The very high negative predictive value (>95%) of coronary CTA allows it to serve as a gatekeeper for excluding patients with suspected CAD.[12-17] However, diagnostic value of coronary CTA is affected by presence of high calcification in the coronary artery disease, and this is manifested by the limited specificity and positive predictive value (PPV) due to high percentage of false positive rates.[18-21] These studies have shown that diagnostic performance of coronary CTA decreases significantly with the increase of CAC score. This is mainly because of the blooming artifacts from heavy calcification in coronary plaques which result in overestimation of coronary lumen stenosis; thus, leading to low specificity and PPV. Figure 1 is an example of coronary CTA in a patient with heavily calcified plaques in left coronary artery showing significant lumen stenosis but invasive coronary angiography confirms stenosis of less than 50%.

The limited diagnostic value of coronary CTA in the assessment of severely calcified plaques can be addressed by two methods: use of image post-processing to minimize or suppress the effect of heave calcification for improvement of coronary lumen visualization, and use of IR techniques in either raw data or image space for reduction of image noise. Although only a few studies are available in the literature, use of image post-processing algorithms in calcified coronary arteries has been shown to be effective with promising results reported. Tanaka et al studied 11 patients with inclusion of 55 calcified coronary segments by comparing subtracted images with coronary CTA images, with invasive coronary angiography as the standard method.[22] At per-segment level, specificity of subtracted coronary CTA was improved from 48.7% (from standard CTA) to 59%. The area under curve (AUC) by receiver-operating characteristic (ROC) was also increased from 0.741 to 0.905. We reported our early experience of using different image post processing methods for assessment of calcified coronary plaques with resultant improved visualization of coronary lumen when the image post-processing "sharpen" algorithm was used compared to other algorithms.[23] This technique has been further verified by our recent report in 50 patients with calcified coronary plaques.[24] All coronary CTA data were post processed with "sharpen" and smooth reconstruction algorithms in comparison with the original coronary CTA data with the aim of determining the effects of image post processing on reduction of blooming artifacts. Diagnostic value of coronary CTA in CAD was compared at per-vessel assessment with invasive coronary angiography as the reference method. While the sensitivity and negative predictive value of coronary CTA remain unchanged among these coronary CTA data, the specificity and PPV were 66% and 57% with application of "sharpen" algorithm to coronary CTA data, which were significantly higher than 33% and 41%, 44% and 44%, corresponding to the original and coronary CTA data with use of smooth algorithm, respectively (Figure 2). The AUC by ROC analysis also showed significant improvement for >50% coronary stenosis is assessment in the left anterior descending artery when compared to the other two approaches (Figure 3).

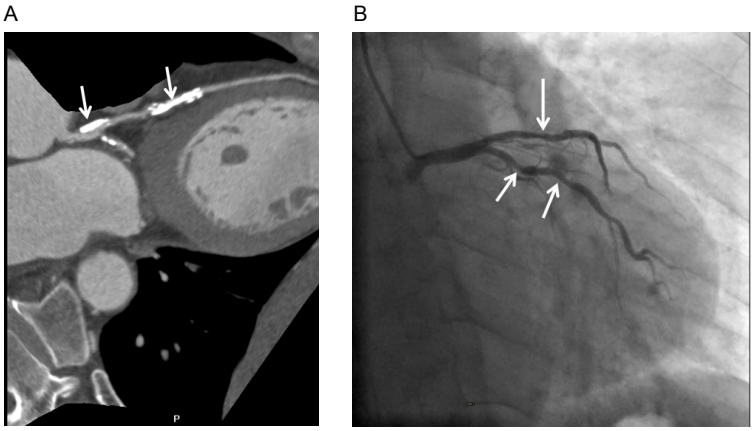

Figure 1: (A). Curved planar reformatted coronary CT angiography (CCTA) shows extensively calcified plaques (arrows) at the left anterior descending (LAD) coronary artery in a 55-year-old man. More than 50% and 90% stenosis was noticed at the proximal and mid-segments of LAD and about 50% stenosis at left circumflex (LCx) on CCTA. (B). Less than 50% stenosis was confirmed in LAD (short arrows) and LCx (long arrow) in invasive coronary angiography.

ISSN 2377-164X Open Journal http://dx.doi.org/10.17140/HROJ-2-125

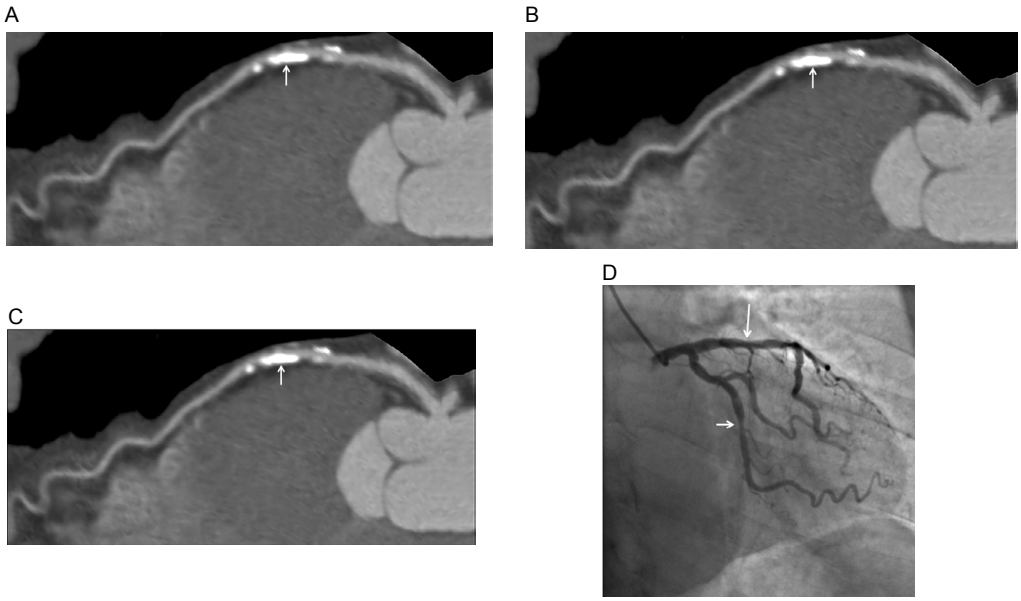

Figure 2: Curved planar reformatted coronary CT angiography (CCTA) shows multiple calcified plaques at the left anterior descending coronary artery (LAD) in a 59-year-old man. CCTA original data (CCTA_O) shows 69% stenosis in LAD due to the heavily calcified plaque, while CCTA with "sharpen" algorithm (CCTA_S) demonstrates 45% stenosis, and 68% stenosis as shown with CCTA with original data integrated with outcome of smoothed image subtracted from the original (CCTA_OS) (A-C). Invasive coronary angiography confirms mild stenosis of 28% at LAD and 44% stenosis at LCx (D). Long and short arrows refer to the stenosis at LAD and LCx, respectively. Reprinted under terms of Open Access article from reference.[24]

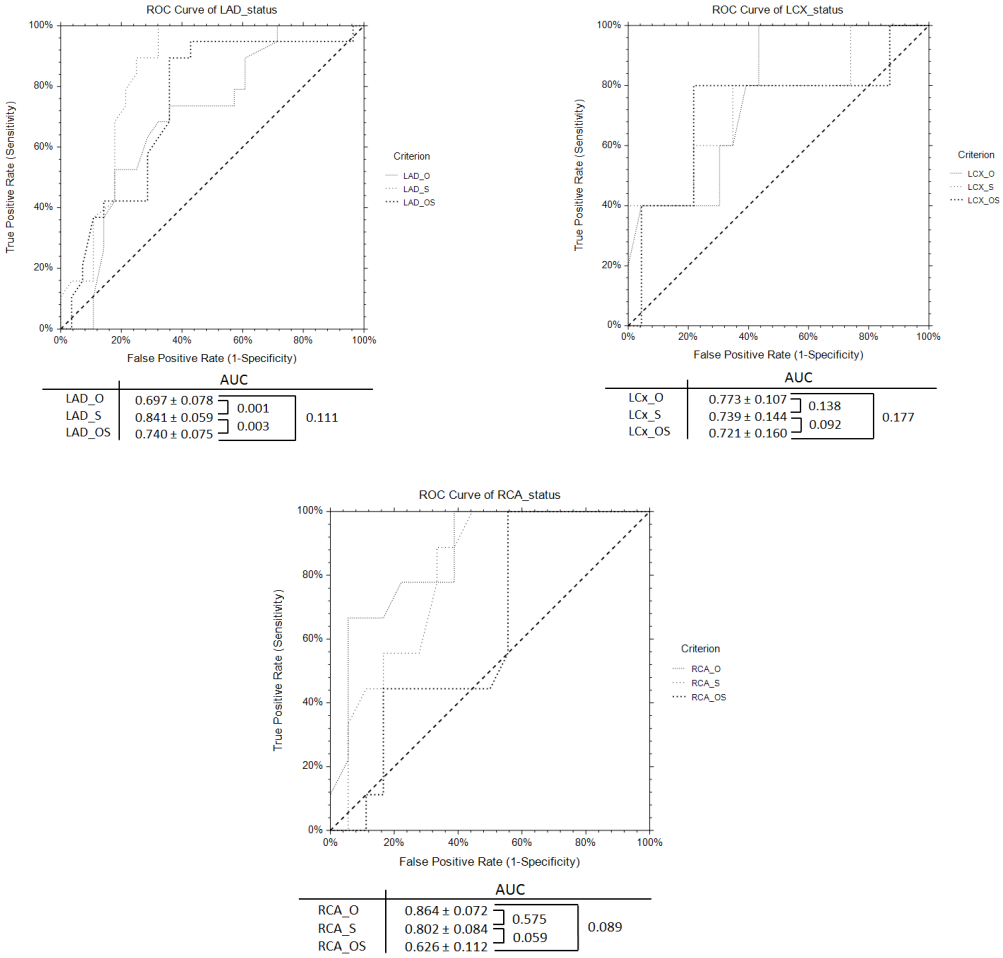

Figure 3: Areas under the curve by receiver-operating characteristic curve analysis demonstrate the diagnostic performance of coronary CT angiography (CCTA) original (CCTA_O), with use of image sharpen (CCTA_S) and smooth algorithms (CCTA_OS) in the detection of significant coronary stenosis when compared to invasive coronary angiography at left anterior descending (LAD), left circumflex (LCx) and right coronary artery (RCA) (A-C). Reprinted under terms of Open Access article from reference.[24]

ISSN 2377-164X Open Journal http://dx.doi.org/10.17140/HROJ-2-125

While image post-processing methods need to be confirmed by more studies, the current literature seems to favour the use of IR techniques in coronary CTA. The use of IR has become a common practice in latest multi slice CT scanners mainly because of significant dose reduction when compared to the conventional FBP. By the end of 2011, IR techniques are available in all four major CT vendors.[7] Although IR is widely accepted as an effective alternative to FBP for radiation dose reduction and image quality improvement, mixed results are reported in the literature with regard to its effect on the assessment of extensively calcified plaques in the coronary arteries. The following section will focus on detailed discussion of these studies in relation to the use of IR in coronary artery calcium assessment.

EFFECTS OF IR ON CORONARY CALCIUM SCORES

Extensive calcifications cause blooming artifacts which lead to over estimation of coronary stenosis, and this often results in unnecessary examinations such as invasive coronary angiography or myocardial perfusion imaging studies.[25,26] This inherent limitation in FBP image reconstruction can be overcome with use of IR techniques.

Renker et al in their prospective study compared IR with FBP reconstructions in 55 patients with an Agatston score of more than 400 (indicating severe calcification in the coronary arteries).[9] Specificity and PPV were significantly improved by using IR on a per-segment (91.2% and 61.1% for FBP, 95.8% and 76.9% for IR, $p<0.001$) and per-patient level (66.7% and 78.9% for FBP, 79.2% and 85.7% for IR, $p<0.05$) for diagnosis of significant coronary stenosis with invasive coronary angiography as the reference method. Their results also showed that IR enabled reclassification from false positive to true negative findings in 4% of coronary segments and 5.5% of patients, respectively. When compared with FBP, IR resulted in significantly lower calcium volumes.

The effects of IR on CAC scores are inconclusive according to the current literature, since some studies reported no effect, while others demonstrated significant impact which could change patient reclassification.[27-37] IR techniques include either image-based such as iterative reconstruction in image space (IRIS), or raw-data based such as Adaptive Statistical Iterative Reconstruction (ASIR) or sonogram-affirmed iterative reconstruction (SAFIRE), or hybrid approaches such as I-Dose.[7] While results of an *in vitro* phantom study showed mixed findings of using IR in relation to the corresponding effects on calcium measurements,[28,29] results of some *in vivo* studies showed no significantly reduced calcium score measurements.

Matsuura and colleagues compared hybrid IR with FBP in 77 patients with suspected CAD, and their results showed no significant effect of using IR on assessing the calcium score, with percentage difference between FBP and hybrid IR being 20.7%, 20.7% and 27.1%, respectively corresponding to the Agatston, volume and mass scores.[30] Hecht et al tested standard CAC scoring protocol using I-Dose level 3 and low-dose protocol of using I Dose level 7 in 102 consecutive patients. Agatston, volume and mass scores were measured and compared between these two protocols. There was excellent correlation in Agatston, volume and mass scores between the standard and low-dose protocols ($p<0.001$), with the mean differences in Agatston scores between these two protocols being 17.4±25.8. There were no significant differences in Agatston scores, except for the right coronary artery, or for aortic calcification.[31] These findings are further confirmed by a recent *in vitro* and *in vivo* study.[32] Schindler et al evaluated IRIS and SAFIRE techniques in a cardiac phantom and 110 patients for calcium scoring. Both IR techniques had excellent agreement with FBP for Agatston scores, while the patient's risk reclassification was less than 3%, indicating no significant effect on Agatston assessment.

Contrary to the above-mentioned studies, most of the recent reports support the statement that IR has significantly affected the CAC scores which could change patient's risk stratification.[33-39] These studies can be summarized into three groups based on the use of IR techniques: use of ASIR or SAFIRE for image reconstruction, use of I-Dose with different levels and use of iterative model reconstruction (IMR). A number of studies have reported the effects of using ASIR or SAFIRE on calcium score measurements with results showing significant reduction in Agatston score and volume scores.[33-36] These findings generally indicate that the mean calcium scores decreased with the use of IR or increased SAFIRE degrees, with up to one third of patients being reclassified to a lower risk category with IR in comparison with FBP. Furthermore, increased IR level such as high-grade SAFIRE has been shown to result in a negative calcium score as reported by Kurata et al.[34] Similarly, use of I-Dose levels leads to reduction in Agatston, volume and mass scores, with reclassification of patient risk up to 15%.[37,38] Szilveszter et al in their recent study applied IMR and hybrid IR techniques in 63 symptomatic patients and 504 asymptomatic individuals. Use of IR techniques resulted in significantly lower CAC score with the median values of CAC score being 147.7, 107 and 115.1 for FBP, hybrid IR and IMR, respectively. No significant difference in CAC score was found between these two IR techniques; however, the main difference was noticed between FBP and IMR reconstructions with difference of 7.3%. Authors found that the IMR led to 2.4% of individuals reclassified with modest effect on the actual risk classification.[39] These findings raised concerns about use of IR techniques in CAC scoring, although further larger prospective studies are needed to confirm these results.

SUMMARY AND CONCLUDING REMARKS

There is no doubt that IR techniques are replacing the conventional filtered back projection in coronary CT angiography due to significant image noise and radiation dose reduction and improvement of image quality. However, the effects of IR techniques on coronary calcium scores remain to be further clarified since these reported findings should be interpreted with caution. It should also be noted that CAC scoring not only depends on

ISSN 2377-164X Open Journal http://dx.doi.org/10.17140/HROJ-2-125

the use of imaging reconstruction techniques, but also relies on different vendors. Significantly different CAC scores were reported among different CT scanner types with resultant reclassification of patients in up to 6.5% of cases.[40] Further studies are warranted to assess the effects of different IR reconstruction techniques with use of different types of CT scanners in larger population groups.

REFERENCES

1. Greenland P, Bonow RO, Brundage BH, et al. ACCF/AHA 2007 clinical expert consensus document on coronary artery calcium scoring by computed tomography in global cardiovascular risk assessment and in evaluation of patients with chest pain: a report of the American College of Cardiology Foundation Clinical Expert Consensus Task Force (ACCF/AHA Writing Committee to Update the 2000 Expert Consensus Document on Electron Beam Computed Tomography) developed in collaboration with the Society of Atherosclerosis Imaging and Prevention and the Society of Cardiovascular Computed Tomography. *J Am Coll Cardiol*. 2007; 49(3): 378-402. doi: 10.1016/j.jacc.2006.10.001

2. Arad Y, Spadaro LA, Goodman K, Newstein D, Guerci AD. Prediction of coronary events with electron beam computed tomography. *J Am Coll Cardiol*. 2000; 36(4): 1253-1260. doi: 10.1016/S0735-1097(00)00872-X

3. Greenland P, LaBree L, Azen SP, Doherty TM, Detrano RC. Coronary artery calcium score combined with Framingham score forrisk prediction in asymptomatic individuals. *JAMA*. 2004; 291(2): 210-215. doi: 10.1001/jama.291.2.210

4. Taylor AJ, Bindeman J, Feuerstein I, Cao F, Brazaitis M, O'Malley PG. Coronary calcium independently predicts incident premature coronary heart disease over measured cardiovascular risk factors: mean three-year outcomes in the Prospective Army Coronary Calcium (PACC) project. *J Am Coll Cardiol*. 2005; 46(5): 807-814. doi: 10.1016/j.jacc.2005.05.049

5. Sun Z, Ng KH. Multislice CT angiography in cardiac imaging. Part II: clinical applications in coronary artery disease. *Singapore Med J*. 2010; 51(4): 282-289. Web site. http://smj.sma.org.sg/5104/5104ra2.pdf. Accessed March 30, 2016.

6. Alluri K, Joshi PH, Henry TS, Blumenthal RS, Nasir K, Blaha MJ. Scoring of coronary artery calcium scans: history, assumptions, current limitations, and future directions. *Atherosclerosis*. 2015; 239(1): 109-117. doi: 10.1016/j.atherosclerosis.2014.12.040

7. Beister M, Kolditz D, Kalender WA. Iterative reconstruction methods in x-ray CT. *Phys Med*. 2012; 28(2): 94-108. doi: 10.1016/j.ejmp.2012.01.003

8. Al Shammakhi A, Sun Z. A systematic review of image quality, diagnostic value and radiation dose of coronary CT angiography using iterative reconstruction compared to filtered back projection in the diagnosis of coronary artery disease. *J Med Imaging Health Inf*. 2015; 5(1): 96-102. doi: 10.1166/jmihi.2015.1364

9. Renker M, Nance JW, Schoepf UJ. Evaluation of heavily scalcified vessels with coronary CT angiography: comparison of iterative and filtered back projection image reconstruction. *Radiology*. 2011; 260(2): 390-399. doi: 10.1148/radiol.11103574

10. Leipsic J, Heilbron BG, Hague C. Iterative reconstruction for coronary CT angiography: finding its way. *Int J Cardiovasc Imaging*. 2012; 28(3): 613-620. doi: 10.1007/s10554-011-9832-3

11. Ebersberger U, Tricarico F, Schoepf UJ et al. CT evaluation of coronary artery stents with iterative image reconstruction: improvements in image quality and potential for radiation dose reduction. *Eur Radiol*. 2013; 23(1): 125-132. doi: 10.1007/s00330-012-2580-5

12. Sun Z, Cao Y, Li HF. Multislice computed tomography angiography in the diagnosis of coronary artery disease. *J Geriatr Cardiol*. 2011; 8(2): 104-113. doi: 10.3724/SP.J.1263.2011.00104

13. Sun Z, Choo GH, Ng KH. Coronary CT angiography: current status and continuing challenges. *Br J Radiol*. 2012; 85(1013): 495-510. doi: 10.1259/bjr/15296170

14. Sun Z, Lin C. Diagnostic value of 320-slice coronary CT angiography in coronary artery disease: A systematic review and meta-analysis. *Curr Med Imaging Rev*. 2014; 10(4): 272-280. Web site. http://www.ingentaconnect.com/content/ben/cmir/2014/00000010/00000004/art00008. Accessed March 30, 2016

15. Sun Z. Cardiac CT. Imaging in coronary artery disease: current status and future directions. *Quant Imaging Med Surg*. 2012; 2(2): 98-105. doi: 10.3978/j.issn.2223-4292.2012.05.02

16. Pelliccia F, Pasceri V, Evangelista A, et al. Diagnostic accuracy of 320-row computed tomography as compared with invasive coronary angiography in unselected, consecutive patients with suspected coronary artery disease. *Int J Cardiovasc Imaging*. 2013; 29(2): 443-452. doi: 10.1007/s10554-012-0095-4

17. Sun Z, Lin CH, Davidson R, Dong C, Liao Y. Diagnostic value of 64-slice CT angiography in coronary artery disease: A systematic review. *Eur J Radiol*. 2008; 67(1): 78-84. doi: 10.1016/j.ejrad.2007.07.014

18. Meijs MFL, Meijboom WB, Prokop M, et al. Is there a role for CT coronary angiography in patients with symptomatic angina? Effect of coronary calcium score on identification of stenosis. *Int J Cardiovasc Imaging*. 2008; 25(8): 847-854. doi: 10.1007/s10554-009-9485-7

19. Meng L, Cui L, Cheng Y, et al. Effect of heart rate and coro-

nary calcification on the diagnostic accuracy of the dual-source CT coronary angiography in patients with suspected coronary artery disease. *Korean J Radiol*. 2009; 10(4): 347-354. doi: 10.3348/kjr.2009.10.4.347

20. Park MJ, Jung JI, Choi YS, et al. Coronary CT angiography in patients with high calcium score: evaluation of plaque characteristics and diagnostic accuracy. *Int J Cardiovasc Imaging*. 2011; 27(2): 43-51. doi: 10.1007/s10554-011-9970-7

21. Vavere AL, Arbab-Zadeh A, Rochitte CE, et al. Coronary artery stenoses: accuracy of 64-detector row CT angiography in segments with mild, moderate, or severe calcification–a sub analysis of the CORE-64 trial. *Radiology*. 2011; 261(1): 100-108. doi: 10.1148/radiol.11110537

22. Tanaka R, Yoshioka K, Muranaka K, et al. Improved evaluation of calcified segments on coronary CT angiography: a feasibility study of coronary calcium subtraction. *Int J Cardiovasc Imaging*. 2013; 29(2): 75-81. doi: 10.1007/s10554-013-0316-5

23. Sun Z, Ng C. High calcium scores in coronary CT angiography: effects of image post-processing on visualization and measurement of coronary lumen diameter. *J Med Imaging Health Inf*. 2015; 5(1): 110-116. doi: 10.1166/jmihi.2015.1366

24. Sun Z, Ng KC, Xu L, Fan Z, Lei J. Coronary CT angiography in heavily calcified coronary arteries: Improvement of coronary lumen visualization and coronary stenosis assessment with image post processing methods. *Medicine*. 2015; 94(48): e2148. doi: 10.1097/MD.0000000000002148

25. Raff GL, Gallagher MJ, O'Neill WW, Goldstein JA. Diagnostic accuracy of noninvasive coronary angiography using 64-slice spiral computed tomography. *J Am Coll Cardiol*. 2005; 46(3): 552-557. doi: 10.1016/j.jacc.2005.05.056

26. Zhang LJ, Wu SY, Wang J, et al. Diagnostic accuracy of dual-source CT coronary angiography: the effect of average heart rate, heart rate variability, and calcium score in a clinical perspective. *Acta Radiol*. 2010; 51(7): 727-740. doi: 10.3109/02841851.2010.492792

27. Naoum C, Blanke P, Leipsic J. Iterative reconstruction in cardiac CT. *J Cardiovasc Comput Tomogr*. 2015; 9(4): 255-263. doi: 10.1016/j.jcct.2015.04.004

28. Funabashi N, Irie R, Aiba M et al. Adaptive-iterative-dose reduction 3D with multi sector-reconstruction method in 320-slice CT may maintain accurate-measurement of the Agatston-calcium-score of severe-calcification even at higher pulsating-beats and low tube-current in vitro. *Int J Cardiol*. 2013; 168(1): 601-603. doi: 10.1016/j.ijcard.2013.01.230

29. Blobel J, Mews J, Schuijf JD et al. Determining the radiation dose reduction potential for coronary calcium scanning with computed tomography: an anthropomorphic phantom study comparing filtered back projection and the adaptive iterative dose reduction algorithm for image reconstruction. *Invest Radiol*. 2013; 48(12): 857-862. doi: 10.1097/RLI.0b013e31829e3932

30. Matsuura N, Urashima M, Fukumoto W, et al. Radiation dose reduction at coronary artery calcium scoring by using a low tube current technique and hybrid iterative reconstruction. *J Comput Assist Tomogr*. 2015; 39(1): 119-124. doi: 10.1097/RCT.0000000000000168

31. Hecht HS, de Siqueira MEM, Cham M, et al. Low- vs. standard coronary artery calcium scanning. *Eur Heart J Cardiovasc Imaging*. 2015; 16(4): 358-363. doi: 10.1093/ehjci/jeu218

32. Schindler A, Vliegenthart R, Schoepf UJ, et al. Iterative image reconstruction techniques for CT coronary artery calcium quantification: comparison with traditional filtered back projection in vitro and in vivo. *Radiology*. 2014; 270(2): 387-393. doi: 10.1148/radiol.1313023

33. vanOsch JAC, Mouden M, van Dalen JA, et al. Influence of iterative image reconstruction on CT-based calcium score measurements. *Int J Cardiovasc Imaging*. 2014; 30(5): 961-967. doi: 10.1007/s10554-014-0409-9

34. Kurata A, Dharampal A, DedicA et al. Impact of iterative reconstruction on CT coronary calcium quantification. *Eur Radiol*. 2013; 23(12): 3246-3252. doi: 10.1007/s00330-013-3022-8

35. Gebhard C, Fiechter M, Fuchs TA. Coronary artery calcium score influence of adaptive statistical iterative reconstruction using 64 MDCT. *Int J Cardiol*. 2013; 167(6): 2932-2937. doi: 10.1016/j.ijcard.2012.08.003

36. Takahashi M, Kimura F, Umezawa T, Watanabe Y, Ogawa H. Comparison of adaptive statistical iterative and filtered back projection reconstruction techniques in quantifying coronary calcium. *J Cardiovasc Comput Tomogr*. 2016; 10(1): 61-68. doi: 10.1016/j.jcct.2015.07.012

37. Obmann VC, Klink T, Heverhagen JT, et al. Impact of hybrid iterative reconstruction on Agatston coronary artery calcium scores in comparison to filtered back projection in native cardiac CT. *Rofo*. 2015; 187(5): 372-379. doi: 10.1055/s-0034-1398850

38. Willemink MJ, den Harder AM, Foppen W, et al. Finding the optimal dose reduction and iterative reconstruction level for coronary calcium scoring. *J Cardiovasc Comput Tomogr*. 2016; 10(1): 69-75. doi: 10.1016/j.jcct.2015.08.004

39. Szilveszter B, Elzomor H, Karolyi M, et al. The effect of iterative model reconstruction on coronary calcium quantification. *Int J Cardiovasc Imaging*. 2016; 32(1): 153-160. doi: 10.1007/s10554-015-0740-9

ISSN 2377-164X Open Journal http://dx.doi.org/10.17140/HROJ-2-125

40. Willemink MJ, Vliegenthart R, Takx RA, et al. Coronary artery calcification scoring with state-of-the-art CT scanners from different vendors has substantial effect on risk classification. *Radiology*. 2014; 273(2): 695-702. doi: 10.1148/radiol.14140066

HEART RESEARCH

Openventio PUBLISHERS

ISSN 2377-164X

Open Journal

http://dx.doi.org/10.17140/HROJ-2-126

Research

*Corresponding author
Syed Najam Hyder, MBBS, MCPS, FCPS, PhD
Associate Professor of Pediatric Cardiology
Children Hospital and Institute of Child Health, Lahore, Pakistan
Tel. 92333-4262250
E-mail: drnajamhyder@gmail.com

Volume 2 : Issue 5
Article Ref. #: 1000HROJ2126

Article History
Received: March 20th, 2016
Accepted: April 28th, 2016
Published: April 29th, 2016

Citation
Hyder SN, Kazmi U, Kazmi T. Small ventricular septal defect considered not requiring surgical closure: The frequency of developing complications in our center. *Heart Res Open J*. 2016; 2(5): 144-149. doi: 10.17140/HROJ-2-126

Small Ventricular Septal Defect Considered Not Requiring Surgical Closure: The Frequency of Developing Complications in Our Center

Syed Najam Hyder, MBBS, MCPS, FCPS[1*]; Uzma Kazmi, FCPS[2]; Tehmina Kazmi, FCPS[3]

[1]*Associate Professor of Pediatric Cardiology, The Children's Hospital & Institute of Child Health, Lahore, Pakistan*

[2]*Assistant Professor of Pediatric Cardiology, The Children's Hospital & Institute of Child Health, Lahore, Pakistan*

[3]*Assistant Professor of Pediatric Cardiology, The Children's Hospital & Institute of Child Health, Lahore, Pakistan*

ABSTRACT

Objectives: The study was conducted to check the frequency of development of complication in the patients with small Ventricular Septal Defects (VSDs) considered not requiring surgical closure during childhood.

Methods: A descriptive study was conducted on children from January 2015 to December 2015 at Children Hospital and Institute of Child Health, Lahore, Pakistan. The data with isolated VSDs considered too small to require surgery from 1 month to 15 years of age were reviewed. The data was analyzed with SPSS 20 version.

Results: The total of 883 patients of restrictive VSDs considered not to require surgery, 60.6% (n=535) were males and 39.4% (n=348) were females. The significant number of patients i.e. 18.7% (n=166) developed complications. Aortic cusp prolapsed developed in 13.6% i.e. $p \leq 0.05$, 2.3% developed aortic regurgitation secondary to aortic cusp prolapsed. 1.8% developed right ventricular track outflow obstruction (RVOT) i.e. $p \leq 0.05$ and 0.3% of patient developed left ventricular outflow track obstruction (LVOT) i.e. $p \leq 0.05$. Similarly 0.8% patients developed endocarditis. Regarding types of VSD, we found Perimembranous in 65.8%, muscular in 12.6%, Subaorticin 8.3%, doubly committed in 6.0%, Inlet in 5% and outlet in 1.7% of our patients.

Conclusions: Patients with small restrictive Ventricular Septal Defects (VSDs) generally been considered as do not required surgery, the data suggested that a significant percentage of these patients developed complications later in their life i.e., 18.7%.

KEYWORDS: Ventricular septal defect; Aortic cusp prolapsed; Aortic regurgitation; Right ventricular outflow track obstruction; Left ventricular outflow track obstruction.

ABBREVATIONS: VSD: Ventricular Septal Defect; RVOT: Right Ventricular Outflow; LVOT: Left Ventricular outflow; AR: Aortic Regurgitation.

INTRODUCTION

Isolated ventricular septal defect occurs in approximately 2-6 of every 1000 live births and accounts for more than 15-20% of all congenital heart diseases.[1] Soto et al divided VSD into Perimembranous, Muscular and Doubly committed sub-arterial (DCSA) types.[2] It had been well accepted for many years that patients with a small ventricular septal defect (VSD) as defined by a left-to-right shunt of <50%, normal pulmonary artery pressure (PAP), and absence of symptoms do not require surgical repair.[3,4] Operation were postponed on the observation that VSDs frequently close spontaneously.[5,6] The patients with such small defects are unlikely to

ISSN 2377-164X Open Journal http://dx.doi.org/10.17140/HROJ-2-126

develop pulmonary hypertension and that the clinical outcome was assumed to be good.[4]

The natural history of VSD is also characterized by many complications. Of special interest is prolapse of the aortic valve cusp, which classically occurs with doubly committed subarterial and less commonly with perimembranous outlet type.[7] Secondary aortic insufficiency, is associated along with prolapse of aortic valve cusps. This complication is observed only in 5% of patients with ventricular septal defect.[8] Aortic regurgitation occurs due to a poorly supported right coronary cusp combined with the Venturi effect produced by the ventricular septal defect jet, resulting in cusp prolapsed.[9] Aortic regurgitation is progressive in nature and presence of even mild aortic regurgitation or aortic valve prolapse in the absence of aortic regurgitation is an indication for surgery.[10] Perimembranous outlet VSD are also associated with infundibular hypertrophy, and right ventricular outflow tract obstruction can progress in severity. This also requires surgical intervention.[11] Discrete fibrous subaortic stenosis is occasionally associated with a ventricular septal defect. This complication is most often reported with perimembranous ventricular septal defects and can first appear after either spontaneous or surgical closure.[12] Infective endocarditis is rare in children younger than 2 years.[6]

METHODS

Data Collection Procedure

All echocardiography reports were reviewed from hospital record. Patients only having isolated restrictive ventricular septal defect (VSD) were included in the study. Associated complications like aortic valve prolapse and aortic regurgitation, acquired right and left ventricular outflow tract obstruction and infective endocarditis were noted.

Patient Population

The patient population represents the total number of patients visited in the Department of Cardiology for echocardiology in Children Hospital & Institute of Child Health, Lahore, Pakistan from January 2015 to December 2015. A total of 883 patients with small VSDs (male/female 535/348) were selected. All patients fulfilled the following inclusion criteria:

1) Surgical closure had not been performed for the following reasons:

   a. Gradient across VSD more than 50 mm of Hg,
   b. Normal LVEDD according to age,
   c. Size of VSD less than 3 mm,
   d. No PR (normal PAP) and
   e. Asymptomatic children.

2) No additional hemodynamically related heart defects were present.

Echocardiography

All echocardiograms were performed and interpreted at one laboratory by consultant pediatric cardiologist. Standard transthoracic M-mode, two-dimensional and Doppler echocardiography were performed with GE VIVID-7 DIMENSION echo-machine. The VSDs were classified by their location into perimembranous, inlet, outlet, doubly committed (Supracristal), and muscular. A normal left ventricular end-diastolic diameter (LVEDD) according to age. The peak pressure difference between right and left ventricle (LV) was calculated from the continuous-wave Doppler-measured maximum VSD jet velocity using the simplified Bernoulli equation. Systolic right ventricular-to-right atrial pressure difference was calculated from the continuous-wave Doppler-measured peak tricuspid regurgitant velocity with the simplified Bernoulli equation. Systolic PAP was obtained by adding 5 mmHg for the right atrial pressure as long as the gradient did not indicate pulmonary hypertension and tricuspid regurgitation was not hemodynamically relevant. A systolic PAP ≤25 mmHg was considered normal.[13-15] If no adequate Doppler signal of the tricuspid regurgitant flow could be obtained, PAP was calculated by subtracting the left ventricular to right ventricular systolic gradient (LV-RV gradient) from the systemic arterial pressure measured with cuff, provided that no aortic stenosis was present.[15]

Statistical Analysis

Appropriate statistical data analysis technique by using SPSS version 20 was applied. Qualitative variables were described by numbers and percentages while quantitative were described as mean and SD (standard deviations). Chi-square test was applied for categorical variables and independent sample t-test was applied for quantitative variables. Five percent level of significance was used.

RESULTS

The 883 patients of restrictive hemodynamically small VSDs considered not to require surgery were entered. There were 60.6 % (n=535) males and 39.4% (n=348) were females (Figure 1). Regarding types of ventricular septal defects (VSD), we found Perimembranous in 65.8%, muscular in 12.6%, Subaortic in 8.3%, doubly committed in 6.0%, inlet in 5% and outlet in 1.7% of patients (Table 1). Complications were predominantly found more in male in case of perimembranous and doubly committed VSD i.e. 67% and 7.1% respectively (Figure 1).

The significant number of patients i.e. 18.7% (n=166) developed complications. Aortic cusp prolapsed was found to be the commonest one i.e. developed in 13.6% (n=120) $p \leq 0.05$ of patients. Second common complication was aortic regurgitation secondary to aortic cusp prolapsed which was found in 2.3% (n=20) of patients. 1.8% (n=16) of patients developed right ventricular track outflow obstruction (RVOTO) $p \leq 0.05$ and 0.3% (n=3) of patient developed left ventricular outflow track obstruction (LVOTO) $p \leq 0.018$. Similarly 0.8% (n=7) patients

ISSN 2377-164X Open Journal http://dx.doi.org/10.17140/HROJ-2-126

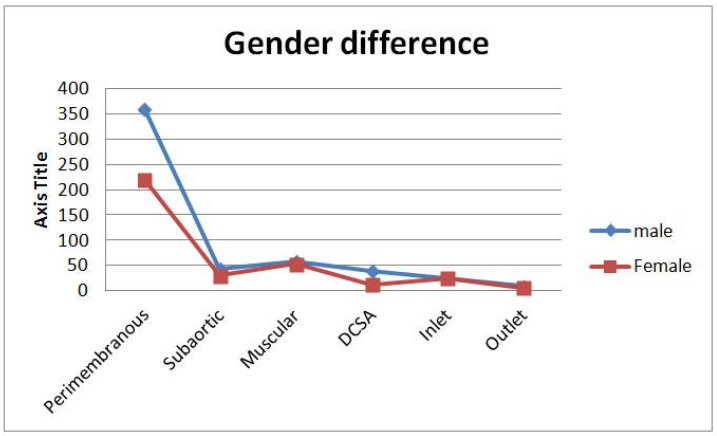

Figure 1: Gender difference with type of VSDs.

VSDs	Total	Percent %
Perimembranous	581	65.8%
Muscular	111	12.6%
Subaortic	73	8.3%
DCSA	53	6.0%
Inlet	50	5.7%
Outlet	15	1.7%
Total	883	100.0%

Table 1: Type of VSD (n=883).

developed echo based endocarditic (Tables 2 and 3).

Regarding complications aortic cusp prolapse was found commonly in perimembranous ventricular septal defect i.e. 11.09% as compared to doubly committed VSD which was 1.2% $p \leq 0.05$. Similarly aortic regurgitation was also commonly found in perimembranous types of ventricular septal defect (Table 4).

Patients were grouped into four groups according to age. Group-1 included patients of 1 day to 1 year, Group-2 included from 1 year to 5 years, Group-3 included from 6 years to 10 years and group-4 included more than 10 years of age.

DISCUSSION

The significant number of patients of restrictive small ventricular septal defect developed complications in our study. We found it to be 18.7%. Associated complications related with VSD are already known in the literature, these included upto 25%, including infective endocarditis in 11 percent.[16] Another follow-up study revealed that 22% subjects had major, VSD-related complications.[17]

The natural history has a wide spectrum, ranging from spontaneous closure to congestive heart failure (CHF) to death in early infancy.[7] Spontaneous closure frequently occurs in children, usually by age of 2 years. Closure is most frequently observed in muscular defects (80%), followed by perimembranous defects (35-40%).[5] Outlet ventricular septal defects have a low incidence of spontaneous closure, and inlet ventricular septal defects does not close.[1]

Regarding complication in our study aortic cusp prolapsed was found to be the commonest one i.e. developed in 13.6% (n=120) of patients. Similar results were shown in local

Complications of VSD	Number of patients	Percentage %
Aortic cusp prolapse	120	13.6%
Aortic regurgitation	20	2.5%
RVOT obstruction	16	1.8%
Vegetation	07	0.8%
LVOT obstruction	03	0.3%

Table 2: Complications Observed with restricted VSDs (n=166).

ISSN 2377-164X Open Journal http://dx.doi.org/10.17140/HROJ-2-126

Complications	Types of VSD					
	Perimembranous	Muscular	Subaortic	DCSA	Inlet	Outlet
Aortic cusp prolapse	98	0	10	11	0	1
Aortic regurgitation	16	0	1	2	0	0
RVOTobstruction	7	3	5	1	0	0
Vegetation	4	0	2	1	0	0
LVOT obstruction	0	1	2	0	0	0

Table 3: Complications Observed with Types of VSDs (n=166).

	Age				Total
	Day 1 to 1 year	1 year to 5 years	5 years to 10 years	10 to onward	
Subaortic	21	8	6	2	37
	9.3%	5.0%	7.3%	16.7%	7.7%
perimembranes	145	112	58	9	324
	64.4%	70.4%	70.7%	75.0%	67.8%
muscular	34	22	11	0	67
	15.1%	13.8%	13.4%	0.0%	14.0%
outlet	3	2	2	0	7
	1.3%	1.3%	2.4%	0.0%	1.5%
inlet	15	8	2	1	26
	6.7%	5.0%	2.4%	8.3%	5.4%
DCSA	7	7	3	0	17
	3.1%	4.4%	3.7%	0.0%	3.6%
	225	159	82	12	478
	100.0%	100.0%	100.0%	100.0%	100.0%

Table 4: Types of VSDs according to age groups.

studies by Uzma Kazmi et al[18] and Masood Sadiq et al[19] conducted in Lahore, Pakistan. This frequency is in keeping with other studies. Lue et al[20] found aortic cusp prolapse and aortic regurgitation in 11.9% of their patients with VSD. Brauner et al[21] found aortic cusp prolapse in over 5% of children with VSD.

Classically Doubly committed sub-arterial type VSD is associated with progressive development of aortic cusp prolapse and aortic regurgitation.[7] Contrary to this; our study showed that incidence of aortic cusp prolapse and aortic regurgitation with doubly committed VSD was 1.2%.

Development of aortic regurgitation (AR) or presence of AR at late follow-up has been reported within the wide range of 2% to 20% in previous studies.[10] Patients with obvious prolapse of an aortic cusp into the VSD have the highest risk of developing progressive aortic regurgitation. We found 2.3% of our patients developed aortic regurgitation which was more common in case of perimembranous type of VSD.

Right ventricular outflow obstruction occurs in 3 to 7% patients and is due to hypertrophy of anomalous muscle bundles.[11] We found 1.8% of our patients with development of RVOT obstruction. Glenn et al[22] found that 5.8% patients of VSD developed infundibular stenosis. One study from Multan showed 1.6% of cases of their patients developed RVOT obstruction.

Discrete fibrous subaortic stenosis most often reported with perimembranous ventricular septal defects and can first appear after either spontaneous or surgical closure.[12] 0.3% of our patients developed LOVT obstruction.

The occurrence of endocarditis has been described as the major risk in small VSDs.[6] Again, the incidence of this complication varies widely in previous reports, ranging from 1% to15%.[6,7] Variations reflect the difficulty of estimating the true incidence of this complication.[5] Shah et al[23] estimated the risk of a 15-year-old with a VSD developing bacterial endocarditis by age 70 to be 11.5%. The highest percentage of 15% (5.7 per 1,000 patient-years) was reported by Otterstadet al.[17] On the contrary, we found 0.8% echo based endocarditis in our patients.

LIMITATION

Limitation of this study is that it did not reflect the complications in total population as it was limited to one hospital attendance. Also, excluded were children not reaching a tertiary care centre

ISSN 2377-164X Open Journal http://dx.doi.org/10.17140/HROJ-2-126

or admitted to critical care or ward, yet the results are comparable with other local and international studies. As it was a retrospective study, it was difficult to control bias and confounders. Also, we had to rely on the available written record. Results are, at best, hypothesis-generating.

CONCLUSION

Although patients with small VSDs have generally been considered not to require surgery, data suggests that a significant percentage of these patients developed complications later in their life i.e., 18.7%.

GRANT SUPPORT AND FINANCIAL DISCLOSURES: None.

CONFLICTS OF INTEREST: None.

ETHICS COMMITTEE APPROVAL

The study was approved by the Institutional Review Board and Ethical Committee of The Children Hospital and Institute of Child Health, Lahore, Pakistan and written informed consent was taken from both the parents of the patients.

REFERENCES

1. Sadiq M, Roshan B, Latif F, Bashir I, Sheikh SA, Khan A. Pattern of pediatric heart disease in Pakistan. *J Col Physicians Surg Pak*. 2002; 12(3): 149-153. Web site. https://inis.iaea.org/search/search.aspx?orig_q=RN:34015814. Accessed March 19, 2016.

2. Soto B, Becker AE, Moulaert AJ, Lie JT, Anderson RH. Classification of ventricular septal defects. *Br Heart J.* 1980; 43: 332-343. doi: 10.1136/hrt.43.3.332

3. Bloomfield DK. The natural history of ventricular septal defects in patients surviving infancy. *Circulation.* 1964; 29: 914-955. doi: 10.1161/01.CIR.29.6.914

4. Dickinson DF, Arnold R, Wilkinson JL. Ventricular septal defect in children born in Liverpool 1960 to 1969. Evaluation of natural course and surgical implications in an unselected population. *Br Heart J.* 1981; 46(1): 47-54. doi: 10.1136/hrt.46.1.47

5. Campbell M. Natural history of ventricular septal defect. *Br Heart J.* 1971; 33(2): 246-257. Web site. http://www.ncbi.nlm.nih.gov/pmc/articles/PMC487172/. Accessed March 19, 2016.

6. Alpert BS, Cook DH, Varghese PJ, Rowe RD. Spontaneous closure of small ventricular septal defects: Ten-year follow-up. *Pediatrics.* 1979; 63(2): 204-206. Web site. pediatrics.aappublications.org/content/63/2/204?variant=long&sso=1&sso_redirect_count=1&nfstatus=401&nftoken=00000000-0000-0000-0000-000000000000&nfstatusdescription=ERROR%3a+No+local+token. Accessed March 19, 2016.

7. Keith JD, Rose V, Collins G, Kidd BS. Ventricular septal defect: Incidence, morbidity, and mortality in various age groups. *Br Heart J.* 1971; 33: 81-87. Web site. http://heart.bmj.com/content/33/supplement/81.long. Accessed March 19, 2016.

8. Corone P, Doyon F, Gaudeau S, et al. Natural history of ventricular septal defect. A study involving 790 cases. *Circulation.* 1977; 55(6): 908-915. Web site. http://circ.ahajournals.org/content/55/6/908.full.pdf. Accessed March 19, 2016.

9. Chaudhry TA, Younas M, Baig A. Ventricular Septal defect and associated complications. *JPMA*. 2011; 61(10): 1001-1004. Web site. http://jpma.org.pk/full_article_text.php?article_id=3021. Accessed March 19, 2016

10. Kobayashi J, Koike K, Senzaki H, et al. Correlation of anatomic and hemodynamic features wtih aortic valve leaflet deformity in doubly committed subarterial ventricular septal defect. *Heart Vessels.* 1999; 14(5): 240-245. doi: 10.1007/BF01747853

11. Tomita H, Arakaki Y, Ono Y, Yamada O, Yagihara T, Echigo S. Imbalance of cusp width and aortic regurgitation associated with aortic cusp prolapse in ventricular septal defect. *Jpn Circ J.* 2001; 65(6): 500-504. doi: 10.1253/jcj.65.500

12. Chiu SN, Wang JK, Lin MT, et al. Aortic valve prolapse associated with outlet-type ventricular septal defect. *Ann Thorac Surg.* 2005; 79(4): 1366-1371. doi: 10.1016/j.athoracsur.2004.10.012

13. Pongiglione G, Freedom RM, Cook D, Rowe RD. Mechanism of acquired right ventricular outflow tract obstruction in patients with ventricular septal defect: an angiocardiography study. *Am J Cardiol*. 1982; 50(4): 776-780. doi: 10.1016/0002-9149(82)91233-4

14. Zielinsky P, Rossi M, Haertel JC. Subaortic fibrous ridge and ventricular septal defect: role of septal malalignment. *Circulation.* 1987; 75(6): 1124-1129. doi: 10.1161/01.CIR.75.6.1124

15. Gabriel HM, Heger M, Innerhofer P, et al. Long-term outcome of patients with ventricular septal defect considered not to require surgical closure during childhood. *J Am Coll Cardiol*. 2002; 39(6): 1066-1071. doi: 10.1016/S0735-1097(02)01706-0

16. Mehta AV, Goenka S, Chidambaram B, Hamati F. Natural history of isolated ventricular septal defect in the first five years of life. *Am J Cardiol*. 2000; 93(4): 136-138. Web site. http://europepmc.org/abstract/med/10754804. Accessed March 19, 2016.

17. Otterstad JE, Erikssen J, Michelsen S, Nitter-Hauge S. Long-term follow-up in isolated ventricular septal defect considered too small to warrant operation. *Circulation*. 1990; 228(4): 305-309. doi: 10.1111/j.1365-2796.1990.tb00237.x

18. Kazmi U, Sadiq M, Hyder SN. Pattern of ventricular septal defects and associated complications. *J Coll Physicians Surg*

ISSN 2377-164X Open Journal http://dx.doi.org/10.17140/HROJ-2-126

Pak. 2009; 19(6): 342-345. Web site. http://www.jcpsp.pk/archive/2009/Jun2009/04.pdf. Accessed March 19, 2016.

19. Sadiq M, Roshan B, Khan A, Latif F, Bashir I, Sheikh SA. Pediatric heart disease in Pakistan - epidemiological data on 6620 patients. *Pak Paed J.* 2001; 25: 63-70.

20. Lue HC, Sung TC, Hou SH, et al. Ventricular septal defect in Chinese with aortic valve prolapse and aortic regurgitation. *Heart Vessels*. 1981; 2(2): 111-116. doi: 10.1007/BF02059965

21. Brauner R, Birk E, Blieden L, Sahar G, Vidne BA. Surgical management of ventricular septal defect with aortic valve prolapse: clinical considerations and results. *Eur J Cardiothoracic Surg*. 1995; 9(6): 315-319. doi: 10.1016/S1010-7940(05)80189-7

22. Glen S, Burns J, Bloomfield P. Prevalence and development of additional cardiac abnormalities in 1448 patients with congenital ventricular septal defects. *Heart*. 2004; 90(11): 1321-1325. doi: 10.1136/hrt.2003.025007

23. Shah P, Singh WS, Rose V, et al. Incidence of bacterial endocarditis in ventricular septal defect. *Circulation.* 1966; 34: 127-131. doi: 10.1161/01.CIR.34.1.127