Openventio PUBLISHERS

ISSN 2473-4799

DERMATOLOGY

Open Journal

| August 2016 | Volume 1 | Issue 2 |

www.openventio.org

DERMATOLOGY

Openventio PUBLISHERS

ISSN 2473-4799

Open Journal

TABLE OF CONTENTS

Editorial

1. Look Good Today or To Look Good Everyday? e1-e2

   – *Sowmya Naga Dogiparthi**

Case Report

2. Genital Necrotizing Fasciitis: Fournier's Gangrene 30-34

   – *Manuel Macía Cortiñas, Maite Peña Fernández, Susana González López and Sara Yáñez Madriñán**

Case Report

3. Segmental Lichen Aureus: A Case Report 35-37

   – *Rosa Giménez-García*, Juan Sánchez-Bordona Marqués and Tomas Martinez Zamora*

Mini Review

4. Shaping Up Mitochondrion in Motion Page 38-41

   – *Chie Mifude and Kuniyoshi Kaseda**

Case Report

5. The Use of Freshly Roasted Coffee Bean Powder in the Treatment of Burn Wound: A Case Report 42-46

   – *Bisrat Hailemeskel and Fekadu Fullas**

DERMATOLOGY

Openventio PUBLISHERS

ISSN 2473-4799 Open Journal http://dx.doi.org/10.17140/DRMTOJ-1-e001

Editorial

*Corresponding author
Sowmya Naga Dogiparthi, MD, FAM
Consultant Dermatologist and Cosmetologist
Chettinad Superspeciality Hospital and Medical College, Kelambakkam and Dermipure Dermaclinic
Adyar, Chennai 600020, TN, India
E-mail: sowmy88688@gmail.com

Volume 1 : Issue 2
Article Ref. #: 1000DRMTOJ1e001

Article History
Received: March 24th, 2016
Accepted: April 13th, 2016
Published: April 26th, 2016

Citation
Dogiparthi SN. Look good today or to look good everyday? *Dermatol Open J.* 2016; 1(2): e1-e2. doi: 10.17140/DRMTOJ-1-e001

Look Good Today or To Look Good Everyday?

Sowmya Naga Dogiparthi, MD, FAM*

Consultant Dermatologist and Cosmetologist, Chettinad Superspeciality Hospital and Medical College, Kelambakkam and Dermipure Dermaclinic, Adyar, Chennai 600020, TN, India

Looking good on special occasions means wearing the perfect dress/suit, getting hair set and for the women its perfect makeup besides all these.

When we introduce ourselves to a stranger, the first thing they notice is our appearance. Skin, Hair and Nails give each one of us an external appearance that one see's before knowing anything about the person.

For both men and women racial Skin types vary from Fitzpatrick Skin Types I-VI; Type I being very Pale White Skin prone to burning all the time and at the end of the spectrum is Type VI skin which never burns, but easily gets tanned and deeply pigmented. The genetic variation in human skin colors is mainly because their melanocytes produce different amount and kinds of melanin. Melanocytes are the pigment producing cells being the product of both of the individual's biological parents' genetic makeup. The amount of melanocytes and the type of melanin production within the epidermis determines the skin and hair color of an individual.

As an individual grows, Multiple factors play a role that alters the skin and hair. The most common factors are: ultraviolet rays, nutrition, cosmetics, shampoos, hair serums and personal hygiene and habits.

Is it important to only look good on special occasions or is it important to look good on a daily basis? Here are some tips to keep your Skin, Hair and Nails healthy in order to look good not only outside but also to feel confident from inside. Yes, Cosmetics play vital role to enhance beauty but do not camouflage your natural beauty with cosmetics all the time. Spending extra ten-minutes of meticulous time for skin, hair, nail maintenance can win you the signs of aging and delay its process.

Approximately 65%, the majority of the human body is composed of water. It is advised to drink at least 2-3 liters of water per day to keep skin, hair and nails healthy. More water keeps the ceramides in the epidermis healthy.

Inadequate nutrition can lead to pale skin, lusterless hair, hair fall and brittle nails. As suggested by the main scientific societies a daily diet should include a bowl of fresh fruits, a cup of sprouts and a bowl of oil free vegetables and 2-3 almonds/day. Reduce the amount of oily and fatty food products, especially fast food; as these can increase the insulin levels in the body which in turn stimulate the sebaceous glands to secrete more oil leading to acne and dandruff. As smoking can enhance aging of skin; leading to wrinkles at a very young age; it is advised to quit smoking to keep oneself healthy.

When coming to usage of the right soaps and shampoos to cleanse body and hair. It is mandatory to use Syndet base Soap, free non-irritating cleanser which restores moisture. A low pH shampoo is advised to rinse hair twice weekly followed by a conditioner application for 3-4 min only for hair and should be rinsed with cold water. Towel drying of hair is recommended over blow drying or straitening as the later two can form microscopic heat bubbles that damage the hair roots and break the hair. Anti frizz serums of choice can be applied to hair strands to

ISSN 2473-4799 Open Journal http://dx.doi.org/10.17140/DRMTOJ-1-e001

maintain the shine and to have manageable hair while combing. Avoid frequent coloring of hair, as chemicals present in the hair dye can lead to a skin condition called Allergic Contact Dermatitis of forehead.

The primary function of the Stratum corneum is to act as a physicochemical semi- permeable barrier against both the environment and the transepidermal water loss (TEWL) from the body. Frequent application of a good moisturizer recommended by a dermatologist not only prevents TEWL from the body but also restores the Ceramides in the epidermis and delays aging in all seasons. Along with a moisturizer, a frequent application of sunscreen between SPF 30-50 is recommended to avoid harmful effects of UV rays and to prevent sunburns and tans. For further protection, it is recommended to wear wide brim hats, sunglasses, and light colored cotton clothes during summer.

One's genetic color cannot be changed permanently; but can be enhanced by cosmetic dermatology procedures such as chemical peels. Chemical peels are therapeutic acids with different strengths and compositions based on client's needs applied on skin in sequential sittings to enhance the look of one skin. In simple terms, it is a process of removing the "Dead dirty Skin" and regenerating "New Skin". To maintain the affect of a chemical peel one should follow the pre- and post-peel guidelines given by their Dermatologist/Cosmetologist.

Finally, coming to Nail care. Both Toe nails and finger nails should be frequently trimmed in order to prevent fungal and dirt accumulation under long thick nails. Also frequent nail polish application is not advised from a dermatologist's perspective as there toxic chemicals in nail polish that can damage the nail and can reduce the natural shine of the nail.

Following the above tips on a regular basis, can help you look young even in late sixties and be confident in your smile.

DERMATOLOGY

Openventio PUBLISHERS

ISSN 2473-4799 Open Journal http://dx.doi.org/10.17140/DRMTOJ-1-109

Case Report

*Corresponding author
Sara Yáñez Madriñán, PhD
Department of Obstetrics and Gynecology Service
University Hospital of Santiago de Compostela
Corunna, Spain
Tel. 650927231
E-mail: sara.yanez.madrinan@gmail.com

Volume 1 : Issue 2
Article Ref. #: 1000DRMTOJ1109

Article History
Received: January 30th, 2016
Accepted: May 18th, 2016
Published: May 18th, 2016

Citation
Cortiñas MM, Fernández MP, López SG, Madriñán SY. Genital necrotizing fasciitis: fournier's gangrene. *Dermatol Open J.* 2016; 1(2): 30-34. doi: 10.17140/DRMTOJ-1-109

Genital Necrotizing Fasciitis: Fournier's Gangrene

Manuel Macía Cortiñas, PhD; Maite Peña Fernández, PhD; Susana González López, PhD; Sara Yáñez Madriñán, PhD*

Department of Obstetrics and Gynecology Service, University Hospital of Santiago de Compostela, Corunna, Spain

ABSTRACT

Necrotizing fasciitis is characterized by a rapidly progressive infectious disease affecting skin and soft tissue, usually accompanied by severe systemic toxicity. In fact, it is considered the most serious expression of soft tissue infection, by its rapid destruction and tissue necrosis, reaching more than 30% of patients checkered shock and organ failure. In recent years, its incidence is reported at 1: 100,000. This entity in the case of perineal and genital tract involvement, it is called Fournier's gangrene. In the specialty of Obstetrics and Gynecology is a rare infectious complication.

INTRODUCTION

Necrotizing fasciitis is a term that describes a disease condition of rapidly spreading infection, usually located in fascial planes of connective tissue necrosis. Fascial planes are bands of connective tissue tha surround muscles, nerves and blood vessels.

When this condition affects the perineal area and genital tract, it is known as Fournier's gangrene, rare process, with an incidence in males of 1 in 75,000.[1] It presents greater predisposition towards males with a ratio of 1 woman for every 10 men.[2]

Despite its rarity, high morbidity and mortality, accompanied by the speed of disease progression make the process a medical emergency that must be diagnosed quickly to allow adequate treatment to combat its fatal consequences.

The percentages of secondary death itself, are around 22-40%[3] although there is a wide range depending on the series ranging from 6 to 76%.[4]

Below, we are going to introduce a case which it was addressed in our Department of Gynecology of the Clinical Hospital of Santiago de Compostela; case whose primary source is rare, within the rarity of the entity in question.

CLINICAL CASE

Female, 60 years old; as personal history included diabetes mellitus type II, hypercholesterolemia, alcoholism and smoking of 10 cigarettes a day. It presents a previous admission in 2014 in general surgery for cholelithiasis with mild acute pancreatitis, hepatic steatosis and acute exacerbation of underlying disease. Her regular treatments are: 850 mgr metformin, 1000 mg paracetamol, aspirin 100 mgr, ursobilane 500 mgr, enalapril 5 mgr.

The patient comes to the emergency room for mild infectious process, a left side Bartholinitis. She is evaluated in gynecology's emergency, where they proceed to drain the abscess and antibiotic coverage begins with amoxicillin-clavulanate 875 mgr orally, was discharged home.

ISSN 2473-4799 Open Journal http://dx.doi.org/10.17140/DRMTOJ-1-109

Ten-days after the diagnosis the patient comes to the emergency room with a severe case of hemodynamic inestability; entering the emergency room under the diagnosis of diabetic hyperosmolar decompensation, as a result of the suspension of their usual medication (metformin) with a superimposed sepsis caused in the genital area.

At this time, resuscitation equipment is necessary to stabilize the patient, correcting her diabetic hyperosmolar descompensation and initiate and antibiotic coverage with amoxicillin clavulanate 1 g intravenously every eight hours and a single dose of intravenous tazobactam.

The patient is explored by the gynecology service, it highlights a fecaloid odor whose origin is in the genital area. That area is explored, and soft tissue infection is observed with a large necrosis area located at about 4 cm of the left lower and higher around the lip area before drainage. The area of erythema and induration beyond, reaching mons pubis, without reaching inguinal region and later affects the whole perineal area and buttocks, reaching inside of his left thigh. Throughout the process, the patient never reached a fever.

Laboratory data were diagnosed with their diabetic hyperosmolar descompensation: glycemia of 591 mg/dl and 324 mOsm/kg osmolarity, severe sepsis with metabolic acidosis; acompanied of 46830 leukocytes x10e^3/mm^3, 87.3% neutrophils, 17% of staffs, 1% metamyelocytes and GSA pH 6.92, pCO2 15 3 mmHg, pO2 140 mmHg, 3.1 mmol/L Real bicarbonate, lactate 2.25 mmol/L and incipient renal failure with creatinine 1.04 mg/dl, 103 urea mg/dl, sodium 132 mmol/l, potassium 3.5 mmol/l.

Once the patient is stabilised, after electrolyte replacement and insulin infusion pump; gynecology service in conjunction with general surgery service, immediately proceed to surgical repair process. A first incision over the area of skin necrosis in left lip, that should be extended to the perineum to verify that the necrotic area includes it is done, proceed to resection and extensive debridement of affected tissue, during which, it is evident that fasciitis goes reaching beyond the left buttock. Is required again to extend the incision to correct excision of the entire affected area. Intraoperative H_2O_2 disinfection is carried out. The open wound is allowed to close by secondary intention. Currently cures are made with clostridiopeptidase, topical neomycin sulfate in the morning and nitrofurazone topical at night.

After the intervention the antibiotic regimen with a higher microbial coverage, as meropenem and metronidazole combination is changed.

At 24 hours post-operatively the patient reoperation is decided, to ensure proper excision of the affected areas to prevent the disease's progression, they observed right lip's edema, without fluctuations or emphysema, presence of fibrin and necrosis towards lower edge of the resection left buttock, which dries and verified that there are no more plates or apparent progress of necrotic fasciitis.

After surgery the patient is stable, with a gradual improvement in their biochemical parameters, eliminating mechanical ventilation on the 6th day. By the 8th day of admission, the patient was conscious, oriented, collaborative, without neurological deficit, hemodynamically stable, with good peripheral perfusión, with sinus rhythm and eupneic. Correct renal function and a good reaction to a normal diet started on the 7th day of admission.

Prior to resuscitation room's discharge, analytical parameters clear evidence correction process: 11790 leucos $\times$10e^3/mm^3 with 81.2% neutrophils, not crooks. Creatinine 0.3 mg/dl, 163 mg/dl glucose, albumin 2.4 g/dL, PCR 6502 mg/dl.

Given the stability of the patient the anesthetist decides to move her to a general hospital Ward, with positive progress.

Microbiological data showed positive for *Streptococcus agalactiae* cultures and *Escherichia coli* in the material of the surgical wound and *streptococcus sp.* sensitive to penicillin and levofloxacin, and clostridium in the purulent material Bartholinitis. The remaining urine cultures, blood, and nasorectal sputum were negative.

DISCUSSION

Necrotizing fasciitis, is part of necrotizing soft tissue infections (cellulitis, myositis, fascitis). In the perineal area is called Fournier's gangrene, in honor of Jean Alfred Fournier, 1883, who described the first case.

The process by which it takes place can be explained by poor patient's immune system response to an infectious aggression due to some type of debilitating disease (such as diabetes) or an infection with a highly virulent. In both situations a subcutaneous cellulitis that quickly evolves skin and subcutaneous tissue necrosis occurs. Local ischemia, favored by arterial and arteriolar thrombotic processes, facilitates the creation of a vicious cycle, where by the body is unable to oxygenate tissues and favor the arrival of cells and substances responsible in combating the infectious process, so infection is extending up to superficial and deep muscle fascia, producing purulent necrotizing fasciitis characteristic of the disease.

In gynecology, obstetrics is a rare infection. Donald et al wrote one of the longer series (case studies) with 23 cases over 14 years, and the literature review performed, we found isolated cases reported by different authors.

Although uncommon, this type of infection has a high morbidity and mortality rates ranging from 6-76% according to different authors. The last reported cases, describe a figure that is around 22-40%. The reduction in morbidity and mortality is subject to rapid and aggressive treatment. Also described as more severe perianal necrotizing fasciitis tracking as many germs in-

ISSN 2473-4799 Open Journal http://dx.doi.org/10.17140/DRMTOJ-1-109

volved to treat than those found in other locations.[4]

It has partnered developing Fournier's gangrene with certain debilitating condition, such as diabetes mellitus, chronic alcoholism, cancer, some rheumatic diseases (which require prolonged treatment with corticosteroids). Of these, diabetes mellitus is the most common risk factor associated with the condition of Fournier's gangrene. We can say that the prevalence of diabetes mellitus in patients with Fournier's gangrene is higher than in the general population. However, when we reviewed the literature, we found some controversy at the time to discern whether the coexistence of diabetes mellitus influences the prognosis. Nisbet et al[5] show that diabetic patients require more surgical debridement with more extensive resections of tissue.

As the source of the infectious process, you may find a urogenital, colorectal or skin cause, with or without recent previous surgical procedures. Colorectal origin is usually the most frequently described, 35.5%[5]; and frequently it described associated with a worse prognosis as noted above.

Other risk factors may be obesity, cytotoxic drug abuse, malnutrition and extreme ages.

With regard to gynecological obstetric origin, we can find infectious origin as the Bartholin gland abscesses, vulvar abscesses, episiotomy 3-4 degree, post-abortion endometritis, pudendal and paracervical blocks, cesarean section, hysterectomy and even laparoscopy by surgical wound infection. Less than ¼ of the processes are considered idiopathic.[2]

If we focus on the etiological agent, two diagnostic entities are defined. The first is type I or NF poly microbial, in 2/3 cases caused by anaerobic germs (*Bacteroides, Clostridium* and *peptoestreptocosos*) and one or more facultative anaerobes (*Streptococcus* not A) and enterobacteria, the synergistic action causes the infection. Agents such as s. *pneumoniae, Aeromonas* and *Vibrio*, are rare, causing the latter a fulminant course of this entity with high mortality especially in patients with comorbidity such as chronic liver disease or diabetes mellitus. The origin is mainly located in the genitourinary tract, gastrointestinal tract and skin beneath. The other type is the type II necrotizing fasciitis or streptococcal, caused by a single principal agent. Generally found SBH group A, as *Streptococcus pyogenes* (to a lesser extent C and G) and less frequently, other species such as *S. aureus* (MRSA) that can produce syndromes such as SSTS, of great gravity.

Our patient had several clear risk factors for the process, such as diabetes, alcoholism and history of local surgery; the latter, considered the primary source of the infectious process. In view of the positive microbiological results for *Streptococcus agalactiae* Group B, *Escherichia coli* and *clostridium sp.* can be classified here as a polymicrobial NF type I.

The diagnosis of Fournier's gangrene is initially clinical, always confirmed by surgical, histological and microbiological findings. It can be difficult, especially in cases of Type II NF (which in our field usually occurs in obstetric patients), since the initial clinical signs are bland and scarce. There is often a mismatch between the clinic patient, who refer severe pain in the affected area where physical signs and mild erythema and induration which does not differ from a banal cellulite will be appreciated.

There are 4 main clinical signs must be suspected of a necrotizing infection: swelling and induration beyond the erythematous area, existence of blisters (especially if your content is hemorrhagic), crepitus or gas in imaging tests and absence of lymphangitis or lymphadenitis associated. However, the rapid progression of inflammation to adjacent areas in hours (progression 2-3 cms per hour), with a significant clinical deterioration in patients; with fever, tachycardia, hypotension, leukocytosis, and coagulopathy or hydroelectric alterations, we will think of this process. In later stages, the skin is tough, tense and may even appear black and crackling areas are ominous signs of subcutaneous necrosis points. It should be noted the feculent smell of this injuries attributed to anaerobic participation in infection.

Other findings that help us diagnosis can be among others, laboratory results, such as: anemia, leukocytosis, hyperglycemia, elevation of serum Cr, hypoalbuminemia, azotemia. Wong and Khin[6] proposed in 2004 an index to establish the diagnostic probability of NF early, but has not yet been validated in prospective studies; it is the Laboratory Risk Indicator for Necrotizing fasciitis (RLINEC Score), in which an index >=6 would establish the suspicion of NF or a value >=8 would be highly predictive of the disease.

Variable	Values	Score
PCR (mg/L)	<50	0
	>=150	4
Leukocytes (x10³/mm³)	<15	0
	15-25	1
	>25	2
Hemoglobin (g/dL)	>13,5	0
	11-13,5	1
	<11	2
Sodium (mmol/L)	>=135	0
	<135	2
Creatinine (mg/dL)	<1,6	0
	>=1,6	2
Glucose (mg/dL)	<=180	0
	>180	1

Table 1: Laboratory risk indicator for necrotizing fasciitis (RLINEC Score).

In our patient, at the arrival to the emergency room, the RLINEC score was 9.

ISSN 2473-4799 Open Journal http://dx.doi.org/10.17140/DRMTOJ-1-109

When the clinical suspicion is high it should not be delayed surgical debridement by performing an imaging test; however, could be carried out complementary techniques such as TC or MRI, which false negative rate is high. They allow to identify asymmetric fascial thinning fluid collections, abscesses, subcutaneous emphysema and even get to determine the cause of the NF as would perineal abscess, fistula tracts or perineal or retroperitoneal infection process. You can even differentiate less aggressive processes such as edema or cellulite affecting superficial fascia, the more aggressive NF which also affects the deep fascia. Ultrasonography and plain radiography are less useful.

In the case of our patient the diagnosis was clinical, supported by laboratory data, and imaging tests, it was performed an abdominal ultrasound which result was non-specific.

For microbiological testing, tissue obtained in the surgical debridement (ideally peripheral necrosis zone), will be studied primarily. Blood cultures may not accurately reflect the microorganisms involved in local infection (may be positive in 29% of patients *vs* 76%[2] positive surgical cultures) as well as the cultivation of vesicular exudate or skin surface that is unprofitable. This fact is confirmed in our patient where blood cultures are negative against the positive cultures of the resected surgical material.

One of the most important and what else has insisted on the management of NF, is the need for early surgical treatment and empirical antibiotics.

Since many patients are in septic shock at the time of diagnosis is essential hemodynamic stabilization (especially hypotension or evidence of organ dysfunction), sometimes even being necessary the vasoactive amine's administration in cases with refractory shock to volume replacement.

In a first-line treatment with empirical antibiotic therapy should be started as soon as possible, being the most used guidelines: triple therapy with penicillin or cephalosporins 3ªG, an aminoglycoside (gentamicin) and metronidazole or clindamycin. Many have suggested adding penicillin for the treatment of *streptococcus*, especially *Clostridium* suspected. Alternatively, clindamycin and chloramphenicol, may be substituted empirically to cover Gram-positive cocci and anaerobes. In patients infected with MRSA, vancomycin should be used. Amphotericin B or caspofungin should be empirically added when fungi are detected in tissue culture.

In our patient's case, after the first surgery it was performed antibiotic coverage with meropenem and metronidazole instead of amoxicillin clavulanic unique pattern. The microorganisms *Streptococcus agalactiae* and *Escherichia coli* were sensitive to amoxicillin clavulanate and levofloxacin; and the *Clostridium sp*. that came in Bartolino's drained culture, was sensitive to penicillin and levofloxacin. In this case meropenem is used, a broad spectrum antibiotic, covering the three microorganisms (gram positive, gram negative) and metronidazole (covering anaerobes) is added for possible secondary infection.

Surgical treatment should not be delayed in time. Its objectives are necrosectomy, extensive surgical debridement, drainage of possible existing collections and obtain material for histological and microbiological diagnosis. Although, studies have found that there is not significantly different mortality if surgery is done before or after the first 24 hours.[2] It should be undertaken as soon as possible to preserve as much healthy tissue as possible.

It is advisable the surgical revaluation of patients with in 24 hours of the first intervention, to ensure no disease progression. In fact, all necessary interventions must be performed to remove all necrotic tissue and local infection control. For larger defects can reach appropriate to each case needed reconstructive surgery.

After surgery, regarding local therapy, it has been seen that Dankin solution (sodium hypochlorite) has greater antimicrobial effect for aerobic and anaerobic agents than povidone-iodine. It is to emphasize the use of topical unprocessed honey for healing of these injuries because of its ability to inhibit microbial growth by its osmotic effect (because of their high sugar concentrations). In a study reach to compare its effectiveness with radical surgical debridement.[2]

In cases of severe perineal affectation, colostomy can be needed to prevent fecal contamination. Amounts to 15% of patients requiring these techniques.[2]

In overall, despite early intensive treatment, NF mortality is high. Type I NF sets around 21%, and type II between 14-34%. In the case of Fournier's gangrene, increased from 22 to 40% of cases as we discussed previously.[3]

The prognosis gets worse according to certain factors, which are: the volume of necrosis (<3% body surface area affected is a low mortality, but if it exceeds 5%, the prognosis worsens substantially),[2] associated comorbidities (ischemic heart disease, renal failure hemodialysis dependent).

With regard to the analytical parameters already mentioned above, the RLINEC Score, plays a prominent role in the prognosis of this disease, since scores greater than 9 suggest a high probability of death and lower scores, 78% chance survival.[2]

Fournier's gangrene has a high mortality rate despite aggressive treatment with intravenous antibiotics and a large surgical approach, aiming to achieve a complete resection of the affected area. The older people and those suffering some debilitating disease, qualities that are usually associated, have a worse prognosis. It is a disease that requires early diagnosis, because of its rapidly advancing in adjacent tissues. It's known

ISSN 2473-4799 Open Journal http://dx.doi.org/10.17140/DRMTOJ-1-109

that a greater extent of disease worse prognosis. Therefore, rapid diagnosis of the process, with the immediate application of therapeutic measures are the key to minimize the morbidity and mortality of the case.

CONFLICTS OF INTEREST: None.

CONSENT: No consent required.

REFERENCES

1. JI Rodríguez Hermosa, A Codina Cazador, MJ García Oria, et al. Fournier's gangrene. *Cir Esp*. 2001; 69(2): 128-135. doi: 10.1016/S0009-739X(01)71710-1

2. Chennamsetty A, Khourdaji I, Burks F, Killinger KA. Contemporary diagnosis and management of Fournier's gangrene.*Ther Adv Urol*. 2015; 7(4): 203-215. doi: 10.1177/1756287215584740

3. Pedro PC, Silvia PE, María Ester PR, Santos CS, Jesús Alberto GV. Actualización en fascitis necrotizante. *Semin Fund Esp Reumatol*. 2012; 13(2): 41-48. doi: 10.1016/j.semreu.2011.12.005

4. Gallup DG, Freedman MA, Meguiar RV, Freedman SN, Nolan TE. Necrotizing fasciitis in gynecologic and obstetric patienta: a surgical emergency. *Am J Obstet Gynecol*. 2002; 187(2): 305-310. doi: 10.1067/mob.2002.126000

5. Medina Polo J, Tejido Sánchez A, de la Rosa Kehrmann F, Felip Santamaría N, Blanco Álvarez M, Leiva Galvis O. Fournier gangrene: Evaluation of prognostic factors in 90 patients. *Actas Urol Esp*. 2008; 32(10): 1024-1030. doi: 10.1016/S0210-4806(08)73982-2

6. Wong C, Khin L, Heng K, Tan K, Low C. The LRINEC (Laboratory Risk Indicator for Necrotizing fasciitis) score: a tool for distinguishing necrotizing fasciitis from other soft tissue infections. *Crit Care Med*. 2004; 32(7): 1535-1541. doi: 10.1097/01.CCM.0000129486.35458.7D

DERMATOLOGY

Openventio PUBLISHERS

ISSN 2473-4799 Open Journal http://dx.doi.org/10.17140/DRMTOJ-1-110

Case Report

*Corresponding author
Rosa Gimenez-Garcia, MD
Associate Professor
Department of Dermatology
Hospital Universitario Río Hortega
Valladolid, Spain
E-mail: rosagim@hotmail.com

Volume 1 : Issue 2
Article Ref. #: 1000DRMTOJ1110

Article History
Received: May 6th, 2016
Accepted: June 2nd, 2016
Published: June 3rd, 2016

Citation
Gimenez-Garcia R, Sánchez-Bordona Marqués J, Zamora TM. Segmental lichen aureus: a case report. *Dermatol Open J.* 2016; 1(2): 35-37. doi: 10.17140/DRMTOJ-1-110

Segmental Lichen Aureus: A Case Report

Rosa Giménez-García, MD[1,2*]; Juan Sánchez-Bordona Marqués, MD, PhD[1]; Tomas Martinez Zamora, MD, PhD[1]

[1]*Department of Dermatology, Hospital Universitario Río Hortega, Valladolid, Spain*
[2]*Department of Medicine, Dermatology and Toxicology, Faculty of Medicine, Valladolid, Spain*

KEYWORDS: Lichen aureus; Segmental lichen; Pigmented purpuric dermatosis.

INTRODUCTION

Lichen Aureus (LA) is a rare asymptomatic dermatosis of unknown etiology which is classified under the group of Pigmented Purpuric Dermatosis (PPD). It is characterized by solitary or scant grouped macules or lichenoid papules, more common on the lower part of the legs, and typically very persistent. Histologically, the epidermis is normal, with a lymphohistiocytic band like infiltrate with extravasated blood red cells and hemosiderin deposits observed in the dermis.[1-4] A segmental or zosteriform pattern has been rarely described.[5,6] The aim of our study was to evaluate the clinicopathologic features of LA with segmental presentation.

CASE REPORT

A 39-year-old barman presented to our clinic with a history of asymptomatic pigmented lesions on his right leg for approximately 10 months. The patient had no family or personal history of dermatosis. He had antecedents of varicose syndrome and had given up smoking one year ago. There was no history of trauma or drug intake prior to onset of the eruption.

Physical examination showed purpuric macules with zosteriform distribution on the backside of the right thigh and the right popliteal cavity (Figure 1). The laboratory data were all normal. The biopsy revealed capillaritis and endothelial hypertrophy in the dermis along with a per vascular lymphoid infiltrate, and a marked deposition of hemosiderin as result of the extravasations of red blood cells. The epidermis was normal. These findings were consistent with a purpuric lichenoid reaction that is suggestive of lichen aureus. The patient was treated with an association of Ruscusaculeatus, Hesperidine and Vitamin C (Fabroven®) for 3 months, without improvement but he stopped smoking and a year later no lesions were present.

Figure 1: Physical examination showed purpuric macules with zosteriform distribution on the backside of the right thigh and the right popliteal cavity.

ISSN 2473-4799 Open Journal http://dx.doi.org/10.17140/DRMTOJ-1-110

DISCUSSION

The eruption has a predilection for the younger adults and is more common in males. A few cases of LA with zosteriform presentation have been reported in children. LA is usually unilateral and asymptomatic. Typical clinical presentation consists of a circumscribed area of pigmented macules or groups of coalescent papules whose colour varies from dark brown to bronze or gold. Lower parts of the legs are the most frequently affected sites, but it can also involve the forearms and trunk.[1-6]

The etiology is unknown. Factors such as focal infections, traumas, capillary fragility, venous insufficiency, drugs (medroxyprogesterone, Interferon-Alpha with Ribavirin) or even energy drinks have been postulated as possible causes of LA. There is one case in the literature of a patient with LA and a previous diagnosis of familial mediterranean fever.[7-11]

Differential diagnosis of LA included lichen planus, drug eruptions, bruises and other diseases of the family of the PDD. Purpuric lesions resembling LA histopathologically have been described in mycosis fungoides.

Histologically, LA differs from other PPD in the density of the lichenoid tissue reaction and the marked acumulation of hemosiderin-containing macrophages. The epidermis is normal in LA, while epidermal spongiosis and parakeratosis are seen in some of the PPD.[4] Dermoscopy can be useful.[12] Lesions are slow to evolve and usually persist unchanged for many years. Complete resolution rarely occurs. Gelmetti et al[1] suggest that childhood lichen aureus has a greater tendency for spontaneous regression (with an average duration of 3.4 years).

Treatment is usually difficult. Review of the literature suggests that spontaneous resolution rarely occurs and usually only after several years. Vitamin C, nonsteroidal anti-inflammatory agents, topical or systemic corticosteroids, topical pimecrolimus, and pentoxifylline together with prostacyclin have been used in its treatment. PUVA therapy has been shown to be effective in LA.[13-17]

CONCLUSIONS

• Lichen aureus is a rare dermatosis of unknown etiology which is classified under the group of Pigmented Purpuric Dermatosis (PPD).
• Lichen aureus is more common than it is believed and it has a predilection for male young adults. A few cases of LA with zosteriform presentation have been reported in children.
• Factors such as focal infections, traumas, capillary fragility, venous insufficiency, drugs or even energy drinks have been postulated as possible causes of LA.
• Segmental pattern of the lesions should be differentiated from other dermatosis with linear or zosteriform distribution such as lichen planus, drug eruptions and other diseases of the family of the PPD.
• Purpuric lesions resembling LA histopathologically have been described in mycosis fungoides.
• Treatment is difficult and complete resolution rarely occurs.

CONFLICTS OF INTEREST: None to declare.

CONSENT

The patient has provided written permission for publication of the case details.

REFERENCES

1. Gelmetti C, Cerri D, Grimalt R. Lichen aureus in childhood. *Pediatr Dermatol*. 1991; 8(4): 280-283. doi: 10.1111/j.1525-1470.1991.tb00933.x

2. Tilly JJ, Drolet BA, Esterly NB. Lichenoid eruptions in children. *J Am Acad Dermatol*. 2004; 51(4): 606-624. doi: 10.1016/j.jaad.2003.12.012

3. Fujita H, Iguchi M, Ikari Y, Asahina A. Lichen aureus on the back in a 6-year-old girl. *J Dermatol*. 2007; 34(2): 148-149. doi: 10.1111/j.1346-8138.2006.00237.x

4. Fink-Puches R, Wolf P, Kerl H, Cerroni L. Lichen aureus. clinicopathologic features, natural history, and relationship to mycosis fungoides. *Arch Dermatol*. 2008; 144(9): 1169-1173. doi: 10.1001/archderm.144.9.1169

5. Yáñez Díaz S, Val-Bernal JF, Arce Mateos F, Navarro Baldeweg O. Liquen áureo o purpúrico Estudio de seis casos, tres con presentación zosteriforme [In Spanish]. *Actas Dermosifiliogr*. 2002; 93(7): 437-442.

6. Jara M, Rivera T, Piqueras M, Zamora E, Burbujo J. Liquen áureo metamérico Presentación de tres casos [In Portuguese]. *Actas Dermosifiliogr*. 1998; 89: 480-483.

7. Shelley WB, Swaminathan R, Shelley ED. Lichen aureus: a hemosiderin tattoo associated with perforator vein incompetence. *J Am Acad Dermatol*. 1984; 11(2 pt 1): 260-264. doi: 10.1016/S0190-9622(84)70162-9

8. Hermoza Rodríguez J. Liquen aureus. *Dermatol Per.* 2003; 13(3): 223-224. Web site. http://200.62.146.19/BVRevistas/dermatologia/v13_n3/Pdf/a08.pdf. Accessed

9. González-Sixto B, García-Doval I, Conde A, et al. Lichen aureus induced by interferon-alpha plus ribavirin. *Acta DermVenereol*. 2007; 87(1): 87-98. doi: 10.2340/00015555-0187

10. Yazdi AS, Mayser P, Sander CA. Lichen aureus with clonal T cells in a child possibly induced by regular consumption of an energy drink. *J Cutan Pathol*. 2008; 35(10): 960-962. doi: 10.1111/j.1600-0560.2007.00918.x

ISSN 2473-4799 Open Journal http://dx.doi.org/10.17140/DRMTOJ-1-110

11. Erbil H, Sezer E, Koseoglu D, Filiz N, Kurunlu Z, Bülent Tastan H. Coexistence of lichen aureus with familial Mediterranean fever. *J Eur Acad Dermatol Venereol*. 2007; 21(7): 1001-1002. doi: 10.1111/j.1468-3083.2006.02075.x

12. Zaballos P, Puig S, Malvehy J. Dermoscopy of pigmented purpuric dermatoses (Lichen Aureus): a useful tool for clinical diagnosis. *Arch Dermatol*. 2004; 140(10): 1290-1291. doi: 10.1001/archderm.140.10.1290

13. Ling TC, Goulden V, Goodfield MJ. PUVA therapy in lichen aureus. *J Am Acad Dermatol*. 2001; 45(1): 145-146. doi: 10.1067/mjd.2001.114560

14. Böhm M, Bonsmann G, Luger TA. Resolution of lichen aureus in a 10-year-old child after topical pimecrolimus. *Br J Dermatol*. 2004; 150(2): 519-520. doi: 10.1111/j.1365-2133.2004.06155.x

15. Lee HW, Lee DK, Chang SE, et al. Segmental lichen aureus: combination therapy with pentoxifylline and prostacyclin. *J Eur Acad Dermatol Venereol*. 2006; 20(10): 1378-1380. doi: 10.1111/j.1468-3083.2006.01732.x

16. Moche J, Glassman S, Modi D, Grayson W. Segmental lichen aureus: a report of two cases treated with methylprednisolone aceponate. *Austral J Dermatol*. 2011; 52(2): e15-e18. doi: 10.1111/j.1440-0960.2010.00655.x

17. Chu Ch, Chou Ch Y. Segmental lichen aureus responsive to oral pentoxifylline monotherapy: a case report and literature review. *J Am Acad Dermatol*. 2016; 74(5): AB71. doi: 10.1016/j.jaad.2016.02.282

DERMATOLOGY

Openventio PUBLISHERS

ISSN 2473-4799 Open Journal http://dx.doi.org/10.17140/DRMTOJ-1-111

Mini Review

*Corresponding author
Kuniyoshi Kaseda, PhD
Director
Saravio Central Institute
Saravio Cosmetics Ltd.
1356-6 Oaza Tsurumi
Beppu, Oita 874-0842, Japan
Tel. +81-977-75-8575
Fax: +81-977-75-8112
E-mail: kaseda@saravio.jp

Volume 1 : Issue 2
Article Ref. #: 1000DRMTOJ1111

Article History
Received: June 21st, 2016
Accepted: July 25th, 2016
Published: July 25th, 2016

Citation
Mifude C, Kaseda K. Shaping up mitochondrion in motion [Video]. *Dermatol Open J.* 2016; 1(2): 38-41. doi: 10.17140/DRMTOJ-1-111

Shaping Up Mitochondrion in Motion

Chie Mifude, BS; Kuniyoshi Kaseda, PhD*

Saravio Central Institute, Saravio Cosmetics Ltd., 1356-6 Oaza Tsurumi, Beppu, Oita 874-0842, Japan

ABSTRACT

We previously reported that hair follicle dermal papilla cells (HFDPCs) show two types of mitochondria, which are filamentous (untangled) and rounded (tangled) mitochondria. Platelet-derived growth factor-AA (PDGF-AA) shifts the population balance toward the filamentous type that produces more adenosine triphosphate (ATP) than the other. In addition, the cells show filamentous mitochondria during the process of cellular migration. Furthermore, here we demonstrated that an inner membrane protein, optic atrophy 1 (OPA1), is involved in the filamentous-rounded transition of the organelle. We suggest that OPA1 confers longitudinal rigidity on the filamentous mitochondria. Other cells such as breast cancer cells utilize small fragmented mitochondria, instead of a filamentous form, in the migration process. Regarding the apparent inconsistency with those other reports on the morphological change upon the onset of cellular migration, we discuss communal feature of the regulation of mitochondrial morphology in different cellular systems: all previous reports showed that the organelle become slender or smaller in the energy-demanding activity.

KEYWORDS: Mitochondria; Morphology; Lymphocytes; Dermal papilla; Migration; OPA1.

ABBREVIATIONS: ATP: Adenosine Triphosphate; HFDPC: Hair Follicle Dermal Papilla Cell; MMP: Mitochondrial Membrane Potential; OPA1: Optic Atrophy 1; PDGF-AA: Platelet-Derived Growth Factor-AA; RNA: Ribonucleic Acid; ROS: Reactive Oxygen Species; MTOC: Microtubule-organizing center.

SUMMARY

The morphological balance of mitochondria is physiologically essential, which is ingeniously maintained by the fission/fusion regulations. The morphological balance can be abruptly changed upon cellular needs and/or environmental stimuli.[1-5] Mitochondrial functions, such as ATP synthesis, reactive oxygen species (ROS) production, calcium regulation, heme-synthesis and apoptotic induction, are closely coupled with the morphology of the organelle. Undoubtedly, a further understanding of the multi-faced organelle will contribute to the applications in the health and therapeutic worlds.[6-11]

We have demonstrated that HFDPCs show mainly two different mitochondrial morphologies, i.e., filamentous and rounded forms.[12] PDGF-AA shifts the balance of the population toward the filamentous form. The filamentous mitochondria produce more chemical energy than the rounded mitochondria while the levels of mitochondrial membrane potential (MMP) and ROS production are kept unchanged. Importantly, the fibroblast-like cells make use of the elongated mitochondria in the process of energy-demanding migration (Figure 1, green box). On the contrary, it was previously reported that other cells, such as metastatic cancer cells and lymphocytes, utilize fragmented mitochondria in the migration process, at the leading edge and trailing edge, respectively.[13] Therefore, it seems that the regulation of mitochondrial morphology depends on the types of cells.

In this article, we describe a communal feature of the morphological regulation of mitochondria in the process of cellular migration. Firstly, the rounded mitochondria we discov-

ISSN 2473-4799 Open Journal http://dx.doi.org/10.17140/DRMTOJ-1-111

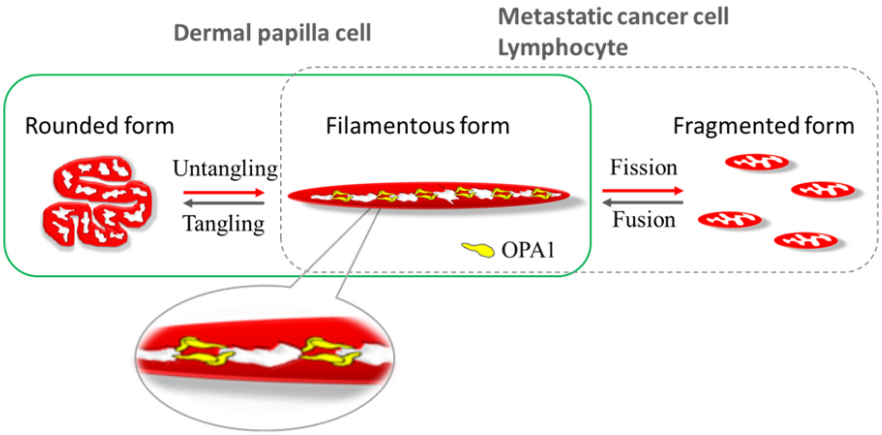

Figure 1: Morphological regulation of mitochondria in cellular migration. Dermal papilla cells utilize tangling-untangling transition (green box). OPA1 plays a role in maintaining the rigidity of filamentous mitochondria by linking the neighboring inner membranes together. Without the inner fusion protein, mitochondrion become less stiff and thereby tangled. In contrast, metastatic cancer cells and lymphocytes use the fission-fusion regulation (dotted box). In all cases, mitochondria become less obstructive in response to the onset of migration process (red arrows).

ered in the primary hair follicle cells are totally different from typical fragmented mitochondria. Indeed, live cell imaging demonstrated that the rounded mitochondrion is formed by the process of tangling or curling-up of a filamentous mitochondrion, therefore, the round form is considerably big and fat. The tangled mitochondrion is untangled to become a filamentous mitochondrion (Supplementary video S1). In contrast to the rounded mitochondria, the apoptotic HFDPCs show typical fragmented mitochondria along with the remarkable reduction of MMP and the elevated level of reactive oxygen species. Therefore, the rounded mitochondria and fragmented mitochondria are to be discriminated both in size and configuration (Supplementary Figure S1, Figure 1). In this sense, rounded mitochondria that were previously reported are to be re-scrutinized whether they are the tangled type or not.

It is noteworthy that mitochondria become slenderer or smaller in the process of cellular migration in the different cellular types (Figure 1, red arrows). In the metastatic cancer cells, it was demonstrated that the regulation by dynamin-related protein-1 (Drp 1) and mitofusin-1 (Mfn 1) triggers the fragmentation of mitochondria and that the small organelles readily relocate into extended actin-rich area, i.e. lamellipodia.[14] In lymphocytes, the fragmented mitochondria are relocated at tubulin-rich microtubule-organizing center (MTOC).[15] On the other hand, HFDPCs spread the filamentous mitochondria over the large body with a small portion of fragmented mitochondria at the tip of filamentous mitochondria near the edge of the cells (Supplementary Figure S2). In addition, filamentous mitochondria dominate the dermal papilla cells when autophagy is induced. These results regarding the energy-demanding activities make sense since the filamentous mitochondria produce a higher level of ATP compared to the tangled mitochondria as described above. It seems that the tangling-untangling regulation is more beneficial to dermal papilla cells than fusion-fission regulation. This is possibly because HFDPC maintains sufficient ATP supply and avoids the excessive production of reactive oxygen species from fragmented mitochondria (it is generally known that the fragmented mitochondria produce less ATP and more ROS). In contrast, it would be essential for metastatic cancer cells to provide the narrow leading edge of the cells with the organelle that produce energy as quick as possible.

Finally, as for the tangling-untangle transition, silencing OPA1 gene in HFDPCs suppressed the formation of filamentous mitochondria, which suggests that the inner membrane protein confers longitudinal rigidity on mitochondria (Figure 1, enlarged view). Consistently, the hair follicle cells up-regulated OPA1 antisense ribonucleic acid (RNA1) and simultaneously down-regulated the gene expressions of OPA1 upon spheroid formation, which leads the cell to the quiescent stage along with the elimination of filamentous mitochondria (unpublished data). In other cells, it is well known that OPA1 plays a role in the mitochondrial fusion process,[16] in which the protein would give the longitudinal stiffness to elongated filaments (Figure 1, dotted box). The novel role of OPA1, along with the orchestrated mechanisms of those regulatory proteins, is to be further investigated.

Understanding the detailed mechanism and maintaining a sound balance in the properties of mitochondrial morphology function will contribute to human health. Therefore, locomotion would be promising as they are on a slimming diet.

ACKNOWLEDGMENTS

Authors acknowledge Mr. Hiroyuki Watanabe and Ms. Thanh Loan Trần for their assistance in English language editing.

CONFLICTS OF INTEREST

The authors declare that they have no conflicts of interest.

REFERENCES

1. Patrushev MV, Mazunin IO, Vinogradova EN, Kamenski PA. Mitochondrial fission and fusion. *Biochemistry (Mosc)*. 2015; 80(11): 1457-1464. doi: 10.1134/S0006297915110061

ISSN 2473-4799 Open Journal http://dx.doi.org/10.17140/DRMTOJ-1-111

2. Mishra P, Chan DC. Metabolic regulation of mitochondrial dynamics. *J Cell Biol*. 2016; 212(4): 379-387. doi: 10.1083/jcb.201511036

3. Wai T, Langer T. Mitochondrial dynamics and metabolic regulation. *Trends Endocrinol Metab*. 2016; 27(2): 105-117. doi: 10.1016/j.tem.2015.12.001

4. Liesa M, Palacín M, Zorzano A. Mitochondrial dynamics in mammalian health and disease. *Physiol Rev*. 2009; 89(3): 799-845. doi: 10.1152/physrev.00030.2008

5. Youle RJ, van der Bliek AM. Mitochondrial fission, fusion, and stress. *Science*. 2012; 337(6098): 1062-1065. doi: 10.1126/science.1219855

6. Chen L, Winger AJ, Knowlton AA. Mitochondrial dynamic changes in health and genetic diseases. *Mol Biol Rep*. 2014; 41(11): 7053-7062. doi: 10.1007/s11033-014-3663-y

7. López-Lluch G, Irusta PM, Navas P, de Cabo R. Mitochondrial biogenesis and healthy aging. *Exp Gerontol*. 2008; 43(9): 813-819. doi: 10.1016/j.exger.2008.06.014

8. Campello S, Scorrano L. Mitochondrial shape changes: Orchestrating cell pathophysiology. *EMBO Rep*. 2010; 11(9): 678-684. doi: 10.1038/embor.2010.115

9. Hudson L, Bowman A, Rashdan E, Birch-Machin MA. Mitochondrial damage and ageing using skin as a model organ. *Maturitas*. 2016. doi: 10.1016/j.maturitas.2016.04.021

10. Feichtinger RG, Sperl W, Bauer JW, Kofler B. Mitochondrial dysfunction: A neglected component of skin diseases. *Exp Dermatol*. 2014; 23(9): 607-614. doi: 10.1111/exd.12484

11. Kandola K, Bowman A, Birch-Machin MA. Oxidative stress a key emerging impact factor in health, ageing, lifestyle and aesthetics. *Int J Cosmet Sci*. 2015; 37(Suppl 2): 1-8. doi: 10.1111/ics.12287

12. Mifude C, Kaseda K. PDGF-AA-induced filamentous mitochondria benefit dermal papilla cells in cellular migration. *Int J Cosmet Sci*. 2015; 37(3): 266-271. doi: 10.1111/ics.12190

13. da Silva AF, Mariotti FR, Máximo V, Campello S. Mitochondria dynamism of shape, transport and cell migration. *Cell Mol Life Sci*. 2014; 71(12): 2313-2324. doi: 10.1007/s00018-014-1557-8

14. Zhao J, Zhang J, Yu M, et al. Mitochondrial dynamics regulates migration and invasion of breast cancer cells. *Oncogene*. 2013; 32(40): 4814-4824. doi: 10.1038/onc.2012.494

15. Campello S, Lacalle RA, Bettella M, Mañes S, Scorrano L, Viola A. Orchestration of lymphocyte chemotaxis by mitochondrial dynamics. *J Exp Med*. 2006; 203(13): 2879-2886. doi: 10.1084/jem.20061877

16. van der Bliek AM, Shen Q, Kawajiri S. Mechanisms of mitochondrial fission and fusion. *Cold Spring Harb Perspect Biol*. 2013; 5(6): 1-16. doi: 10.1101/cshperspect.a011072

ISSN 2473-4799 Open Journal http://dx.doi.org/10.17140/DRMTOJ-1-111

Supplementary Data

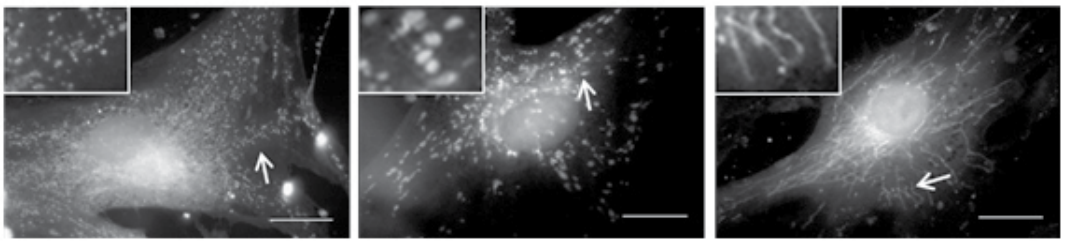

Supplementary Figure S1: Apoptotic dermal papilla cells show fragmented mitochondria.
When apoptosis was induced with the 1 μM staurosporine treatment for 3 hours the cells showed small fragmented mitochondria (left), which are different from big rounded mitochondria (middle). Filamentous mitochondria are also shown (right). Scale bar is 20 μm. Adapted from the previous report.[12]

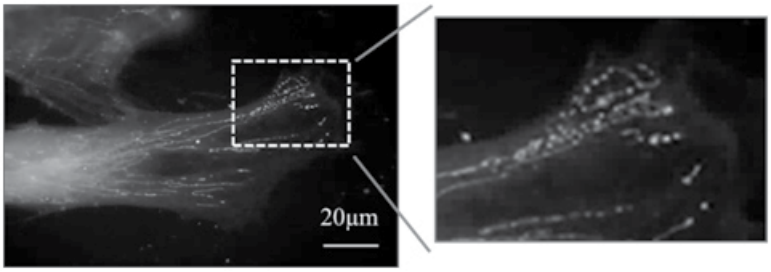

Supplementary Figure S2: Migrating dermal papilla cells spread over filamentous mitochondria.
In the process of migration, filamentous mitochondria dominate the hair follicle cells. The elongated filaments are expanded throughout the cell body. Fragmented mitochondria, in a small minority of the population, can be seen near the edge of the cell. The view in the dotted square is enlarged (right).

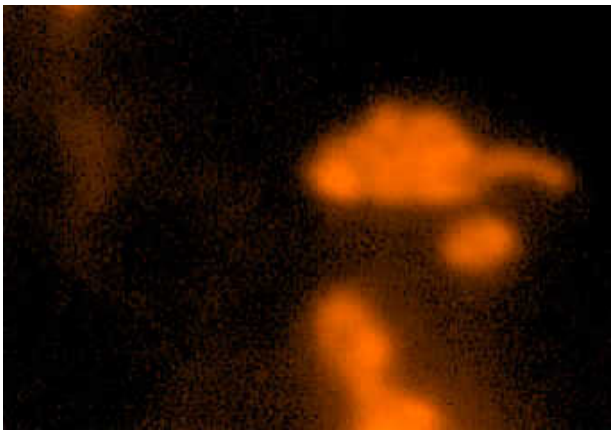

Supplementary Video S1: Formation of a filamentous mitochondrion by untangling.
The live cell imaging shows a rounded mitochondrion transforming into a filamentous mitochondrion *via* untangling. Thirty images were recorded every 10 seconds.

Also you could view this video by clicking the following link:
https://www.youtube.com/watch?v=1heWGPB43cs&feature=youtu.be

Note: To best view

1. Kindly open the pdf file in Adobe Reader XI version.
2. Please save the pdf file on your local computer.
3. To watch the video kindly install the latest adobe flash player. Click here to download: http://get.adobe.com/flashplayer/otherversions/

DERMATOLOGY

Openventio PUBLISHERS

ISSN 2473-4799 Open Journal http://dx.doi.org/10.17140/DRMTOJ-1-112

Case Report

*Corresponding author
Fekadu Fullas, RPh, PhD
Clinical Pharmacist
UnityPoint Health - St. Luke's
Pharmacy Department
2720 Stone Park Boulevard
Sioux City, IA 51104, USA
Tel. (712) 266-6156
Fax: (712) 279-3372
E-mail: FeFuBal@aol.com

Volume 1 : Issue 2
Article Ref. #: 1000DRMTOJ1112

Article History
Received: August 4th, 2016
Accepted: August 23rd, 2016
Published: August 23rd, 2016

Citation
Hailemeskel B, Fullas F. The use of freshly roasted coffee bean powder in the treatment of burn wound: A case report. *Dermatol Open J*. 2016; 1(2): 42-46. doi: 10.17140/DRMTOJ-1-112

The Use of Freshly Roasted Coffee Bean Powder in the Treatment of Burn Wound: A Case Report

Bisrat Hailemeskel, PharmD, RPh[1]; Fekadu Fullas, PhD, RPh[2*]

[1]Associate Professor & Co-Director of International Projects ((HUGIN, HUGISA), College of Pharmacy, Howard University, 2300 4th Street, NW, Washington, D.C. 20059, USA

[2]Clinical Pharmacist, UnityPoint Health - St. Lukes, Pharmacy Department, 2720 Stone Park Boulevard, Sioux City, IA 51104, USA

ABSTRACT

Introduction: Many patients use home remedies for various maladies. The effectiveness of these remedies is not always scientifically ascertainable. Some may be backed by limited scientific studies.

Case Summary: A few years ago, a five-year old girl in Addis Ababa, Ethiopia sustained heavy burns from spillage of boiling water. The child was taken to a local Emergency Department (ED) of a hospital for evaluation and treatment. The patient was discharged after the burn was treated and the wound was appropriately dressed. The mother was instructed to take the child to a clinic for follow-up. After four days of treatment at the clinic, no arrangement was made for visits during the weekend. Upon the advice of her neighbor, the mother decided to apply coffee powder from freshly roasted coffee beans to the wound. In the few days that followed, she observed significant improvement in the healing of the wound. She continued this treatment daily, *in lieu* of visits to the clinic. In about three weeks, the wound was completely healed. The mother who now lives in the USA recently contacted the Drug Information Center at Howard University (HU) inquiring about the merits of coffee powder in the treatment of burn wounds. A literature review revealed various studies confirming the potential effectiveness of powder prepared from freshly roasted coffee beans in the treatment of wounds.

Conclusion: A mother of a five-year old reported that treatment of a burn wound sustained by her child with powder from freshly roasted coffee resulted in healing. A literature review found some evidence to support the usefulness of this home remedy in wound treatment.

INTRODUCTION

The National Coffee Association and The Specialty Coffee Association of America conducts annual surveys regarding coffee consumption each year. Over 50% of over 18 years of age drink coffee every day. This represents over 150 million daily drinkers. About 30 million American adults drink specialty coffee beverages daily: mocha, latte, espresso, café mocha, cappuccino, frozen/iced coffee beverages and others. Among coffee drinkers, the average consumption in the United States is 3.2 cups of coffee per day, and men drink as much coffee as women.[1,2] The claimed main reason why majority of users consume caffeinated beverage daily is to improve mental alertness, concentration and fatigue.[3,4] Several epidemiological findings have also suggested that coffee consumption might be associated with a decrease in all-cause mortality.[5] Having originated in Ethiopia, coffee is a useful commodity and finds various applications locally.

Multiple studies have highlighted the beneficial effects in several disease conditions, such as type II diabetes mellitus, hepatitis C virus, hepatocellular carcinoma, nonalcoholic fatty liver disease and neurodegenerative disorders.[6-9] Long term coffee consumption has also been associated with prevention of cognitive decline, and reduced risk of developing stroke and neurodegenerative diseases (NDD).[10] The FDA has suggested that for healthy adults, caffeine

ISSN 2473-4799 Open Journal http://dx.doi.org/10.17140/DRMTOJ-1-112

intake up to 400 mg/day (about 5 cups of coffee) is not associated with adverse health effects.[11]

Although caffeine may disturb sleep and raise anxiety in sensitive individuals, it does not seem to lead to dependence. However, people experience withdrawal symptoms. Caffeine is also known to potentiate the effect of regular analgesic drugs for headache and migraine. For example, the ingredient caffeine in the product Excedrin® serves such purpose when taken to alleviate migraine headache symptoms.

Coffee powder has been reported to absorb water from wounds.[12] It has also been reported to facilitate wound healing.[13,14] Antibacterial activities of coffee have been demonstrated against Methicillin-Resistant *Staphylococcusaureus* (MRSA), *Streptococcus* spp.[15] and a range of gram-negative bacteria.[16]

CASE REPORT

A question was recently received at HU Drug Information Center from a mother whose daughter was burned by boiling water several years ago in her native country, Ethiopia. The five-year old girl was burned in her thighs on both legs after she tripped over and fell on a floor-top oven, where water was boiling in a cooking pan. The burn covered about 20% of her upper thighs. The mother immediately took the child to the closest local ED in Addis Ababa, Ethiopia, where work up was done properly. A clean gauze was wrapped around the entire wound area, and an instruction was given to the mother to take the child to the clinic daily for follow-up cleaning and wound care. Having noticed some improvement after four days of follow-up visits, the mother found out that the clinic was closed on the fifth day, which was on a Friday leading up to the weekend. While she was in desperation as to what to do next, the mother was advised by her neighbors to apply finely powdered freshly roasted coffee beans on the wound twice daily. She was also instructed to protect it from getting wet. Accordingly, she followed the advice. When she saw a significant improvement by the Monday that followed, she decided to stay home and continued the home remedy using of the coffee powder. According to the mother, the child's wound completely healed in about three weeks. Being curious about the result, she recently called HU Drug Information Center inquiring about any scientific merits in support of the use of ground roasted coffee beans for wound healing.

DISCUSSION

Burn wound can lead to serious infections if it is not treated timely. Although not specific to burn wounds, this literature review was done to look for any evidence from studies conducted on the use of coffee powder in the treatment of various types of experimental and other wounds.

In a study cited by Kenisa et al[13] when Robusta coffee powder was applied on rat-induced alloxan incision wound, it demonstrated clinically similar healing rate with medications that are commonly used in wound care, such as povidone iodine 10%. In another experiment by Kenisa et al[13] 20 male guinea pigs (*Caviacabaya*) with full-thickness wounds were treated with Robusta coffee beans extract ointment at concentrations of 22.5%, 45%, and 90%, while the control group was given ointment base material. The animals were then harvested on the fourth day. The Robusta coffee bean extract ointment-treated group showed an increase the number of lymphocytes, plasma cells, macrophages, fibroblasts, and blood vessels caused by the Constituents Chlorogenic Acid (CGA) and caffeic acid that are present in the coffee. The authors of the study concluded that Robusta coffee bean extract ointment enhanced the healing process of full thickness skin wound of *Caviacabaya*.

Coffee powder has also shown to increase wound healing efficacy when it is combined with other established antimicrobials. In a study published by Nebioglu-K et al.[14] N-Heterocyclic carbene (NHC)-silver complexes were synthesized from pyridine linked pincer legends and methylated caffeine. Pincer NHC-silver complexes were found to have more potent antimicrobial activity than the conventionally used silver antimicrobials. An NHC precursor derived from caffeine was found to have low toxicity, and the resulting silver complex showed antimicrobial activity against numerous pathogens including resistant organisms isolated from the lungs of patients with cystic fibrosis.

Bleeding after a minor cut, a postoperative procedure, or after an accident is a common incident. Because of the commonality of this complication, homeostasis is an important concept to address when considering wound healing. In addition to all the benefits of coffee in healing wounds, it can help stop the bleeding of small cuts. When there is a minor cut, the wound is washed and coffee grounds are applied to cover the cut area. It usually halts the bleeding immediately, because coffee powder on the wound helps to clot the blood, thus reducing the bleeding. If bleeding slows but doesn't stop, the process is repeated making sure the cut area is fully covered with grounds.[14]

Coffee powder absorbs water very fast; therefore it also plays a role by continuously absorbing wound fluids. With the presence of a thick layer of coffee powder, the fluid gets absorbed from the wound by creating negative pressure on the surface of the wound. The co-existence of both carboxylic acid and basic groups on the surface of coffee powder was hypothesized as an explanation for its adsorption behavior of materials including metals that are anionic.[12]

One of the many benefits of coffee in wound healing may be due to its antibacterial properties. Coffee has a strong inhibition against MRSA that is proven on agar plates, which may be due to phenolic acidity and hyperosmolarity formed when mixed with a liquid wound. Raman and colleagues investigated the antibacterial activities of decaffeinated and non-decaffeinated NESCAFÉ instant coffee against some pharyngitis-causing *Streptococcus* species – *Group A Streptococcus*, *Group B Streptococcus*, *Group D Streptococcus* and *Streptococcus pneumonia*

ISSN 2473-4799 Open Journal http://dx.doi.org/10.17140/DRMTOJ-1-112

at eight different concentrations.[15] The study utilized three sensitivity-testing methods: disc diffusion, well diffusion and coffee agar plate sensitivity testing. Zones of inhibition and growth on the plates were observed at 24 hours and 48 hours. The results showed inhibition of growth on coffee agar plate with all *Streptococcus* species. At the highest concentration of coffee solution used in the study (8 g/100 ml), growth inhibition was observed in all the four *Streptococcus* species-inoculated plates, with non-decaffeinated coffee acting much more strongly.

According to Daglia et al, roasted coffee also showed antibacterial properties against a range of Gram-negative bacteria.[16] On the basis of their findings, the activity was not affected by the brewing procedure. However, the degree of roasting and the coffee species affected significantly the antimicrobial activity. In a later study, the same researchers investigated the relationship between the inhibitory effect of brewed coffee on *Staphylococcus aureus* and the degree of roasting as determined by chemical indicators, confirming the influence of the degree of roasting on the inhibitory effect.[17] Dogazaki et al and Furuhata et al reported antibacterial activity of brewed coffee against a strain of *Legionella pneumophila*, bacteria involved in atypical respiratory infections, and identified caffeic, chlorogenic, and protocatechuic acids as the active substances.[18,19] According to Daglia et al[20] and Almeida et al[21] the growth of *Streptococcus mutans*, the major causative agent of dental caries in humans, was inhibited by coffee extracts and by the chemical compounds such as trigonelline, chlorogenic acid, caffeic acid, and protocatechuic acid that are found in coffee. The compounds trigonelline, caffeine, and protocatechuic acid have been reported as potential natural antimicrobial agents against *Nitrobacteria* and therefore could be used in foods as a natural preservative to control their growth.[22]

Treatment of chronic ulcers due to diabetes is a problem and usually leads to amputation. As a result of chronically elevated blood glucose, impaired wound healing is one of the many serious issues that can occur in diabetic patients. Impaired wound healing and vascular disorders are caused by diminished angiogenesis, decreased lymphangiogenesis, and destruction of endothelial cells. Coffee powder is one of the herbal medicines used as a traditional treatment of varying type of wounds including diabetic foot ulcer in rural areas of coffee plantation without any harmful complications. The best evidence regarding the healing properties of coffee powder in humans come from a series of studies done by a vascular surgeon.[23] Several experiments conducted over the years using powdered coffee beans have shown the efficacy of coffee in treating a variety of wounds effectively. Based on these experiments, it was shown that coffee beans powder promoted wound and helped to stop the bleeding from subcutaneous layer that was previously difficult to manage. In the studies, coffee powder was left on the wound tissue for many weeks without cleaning or wetting while adding the powder occasionally as needed until the wound was finally covered itself by epithelial cells. Coffee powder not only healed the wound faster but also decreased the frequency of wound dressing replacement. Less frequent wound dressing resulted in less disruption of the growth of new cells and reduced pain and discomfort associated with removal of dressing from the wound surface. Coffee powder appears to exemplify a new paradigm of thinking in the management of wounds.[24] The powder contains many antioxidants which help in wound healing. Coffee has been effectively used as a debarment agent in reduction of scarring upon healing.

When coffee was used in wound management, the coffee powder on the wound did not need to be cleaned every day and could be left on the wound for as long as 4 to 7 days without closed with gauze. However, the wound was covered with gauze to prevent spills littering the surrounding, especially in patients who are mobile. This eliminated frequent dressing change. By minimizing pain secondary to less frequent dressing changes, coffee powder was reported to be a cost-effective alternative with no observed adverse reactions. In addition, coffee powder application did not require skilled personnel, and could easily be done by anyone in some home settings. Depending on the magnitude of size and depth, the author reported that the drying of the coffee-treated wounds occurred at week 8, and closure of the skin epithelium occurred at the 12th-16th week.[24] It was hypothesized that wound healing in this manner was enhanced by antioxidants (phenolic acid), and that coffee within wound fluids formed a high hyperosmolar fluid is capable of killing pathogenic bacteria cells. Antioxidants absorb the free radical oxygen and reduce tissue damage. Unprocessed coffee beans are claimed to have 1,000 antioxidants which are more than the number found in green tea, or cocoa polyphenols.[24]

Caffeine may have the capacity to decrease the risk of diabetes and improve wound healing through its antioxidant properties and increasing the number of adenosine receptors. To investigate the effects of caffeine on processes involved in epithelialization, Ojeh et al[25] used primary human keratinocytes, HaCaTcell line and an *ex vivo* model of human skin. The investigators tested the effects of caffeine on cell proliferation, differentiation, adhesion and migration, processes essential for normal wound epithelialization and closure *in vitro*. They found that caffeine restricted cell proliferation of keratinocytes in a dose-dependent manner. Furthermore, scratch wound assays performed on keratinocyte monolayers indicated dose-dependent delays in cell migration. Using a human *ex vivo* wound healing model, the researchers also tested topical application of caffeine and found that it impeded epithelialization, thus confirming the *in vitro* data. The researchers concluded that caffeine may have an inhibitory effect on wound healing and epithelialization.

Caffeine acts as adenosine-receptor antagonist. Adenosine is a Purina nucleoside, which is a key local stimulator of cell proliferation and wound healing. Adenosine could be activated by interaction with specific adenosine A1, A2A, A2B, and A3 receptors. Caffeine is a nonselective antagonist of all the adenosine receptor subtypes and has demonstrated physiological effects in *in vitro* and *in vivo* studies. In addition, occupancy of

ISSN 2473-4799 Open Journal http://dx.doi.org/10.17140/DRMTOJ-1-112

adenosine receptors may accelerate wound healing and reduce pro-inflammatory cytokine secretion, including tumor necrosis factor-α and interleukin-6. Zeinab Bonyanian Z and Rose' Meyer RB.[25]

LIMITATIONS

Detailed information regarding the treatment received in the emergency department was not elicited from the mother whose child sustained the burn from boiling water many years ago in Addis Ababa, Ethiopia. The degree of burn could not also be determined based on the phone call received. The medical chart of the patient was not available to track the ED course and follow-up clinic visits. The literature search did not specifically focus on the use of coffee for burn wound treatment only.

CONCLUSION

A five-year old child who sustained an extensive burn wound on the thighs from boiling water was home-treated daily with topical application coffee powder prepared from freshly roasted coffee beans. The mother of the child reported the wound was healed in about three weeks. Literature review on the use of coffee powder in the treatment of wounds seems to support the claim.

CONFLICTS OF INTEREST

We declare that we have no conflicts of interest.

CONSENT

The mother of the five-old described in this case report has provided a written permission for publication of the case details.

REFERENCES

1. The National Coffee Association. Web site. http://www.ncausa.org/. Accessed July 16, 2016

2. The Specialty Coffee Association of America. Web site. http://www.scaa.org. Accessed July 16, 2016

3. Mitchell DC, Knight CA, Hockenberry J, Teplansky R, Hartman TJ. Beverage caffeine intakes in the US. *Food Chem Toxicol*. 2014; 63: 136-142. doi: 10.1016/j.fct.2013.10.042

4. Heckman MA, Weil J, Gonzalez de-ME. Caffeine (1,3,7-trimethylxanthine) in foods: a comprehensive review on consumption, functionality, safety, and regulatory matters. *J Food Sci*. 2010; 75(3): R77-R87. doi: 10.1111/j.1750-3841.2010.01561.x

5. Freedman ND, Park Y, Abnet CC, Hollenbeck AR, Sinha R. Association of coffee drinking with total and cause-specific mortality. *N Engl J Med*. 2012; 366(20): 1891-1904. doi: 10.1056/NEJMoa1112010

6. Bambha K, Wilson L, Unalp A, et al. Coffee consumption in NAFLD patients with lower insulin resistance is associated with lower risk of severe fibrosis. *Liver Int*. 2014; 34(8): 1250-1258. doi: 10.1111/liv.12379

7. Molloy JW, Calcagno CJ, Williams CD, Jones FJ, Torres DM, Harrison SA. Association of coffee and caffeine consumption with fatty liver disease, nonalcoholic steatohepatitis, and degree of hepatic fibrosis. *Hepatology*. 2012; 55(2): 429-436. doi: 10.1002/hep.24731

8. Wilson KM, Kasperzyk J, Rider JR, et al. Coffee consumption and prostate cancer risk and progression in the health professionals follow-up study. *J Natl Cancer Inst*. 2011; 103(11): 876-884. doi: 10.1093/jnci/djr151

9. Liu R, Guo X, Park Y, et al. Caffeine intake, smoking, and risk of Parkinson disease in men and women. *Am J Epidemiol*. 2012; 175(11): 1200-1207. doi: 10.1093/aje/kwr451

10. Nehlig A. Effects of coffee/caffeine on brain health and disease: What should I tell my patients? *Pract Neurol*. 2016; 16(2): 89-95. doi: 10.1136/practneurol-2015-001162

11. U.S. Food and Drug Administration. Letter from Jeanne Ireland, Assistant Commissioner for Legislation, FDA, to Senator Richard J. Durbin, August 10, 2012. Web site. http://www.durbin.senate.gov/public/index.cfm/files/serve?File_id=17eadaa1-85e7-4ceb-a827-be244fbddfa5. Accessed July 21, 2016

12. Bailey SE, Olin TJ, Bricka RM, Adrian DD. A review of potentially low-cost sorbents for heavy metals. *Water Res*. 1999; 33(11): 2469-2479. doi: 10.1016/S0043-1354(98)00475-8

13. Kenisa YP, Istiati I, Setyari JW. Effect of Robusta coffee beans ointment on full thickness wound healing. *Dental Journal*. 2012; 45(1): 52-57. doi: 10.20473/j.djmkg.v45.i1.p52-57

14. Nebioglu-KA, Panzner MJ, Tessier CA, et al. N-Heterocyclic carbene–silver complexes: A new class of antibiotics. *Coord Chem Rev*. 2007; 251(5-6): 884-885. doi: 10.1016/j.ccr.2006.08.019

15. Rahman NAA, Muharram SH, Abiola O. Antibacterial activity of NESCAFÉ instant coffee beverages and pharyngitis-causing Streptococcus species. *Brunei Darussalam Journal of Health*. 2014; 5: 70-79. Web site. http://www.ubd.edu.bn/BDJH/BJH/Home/Current%20issue/Antibacterial%20activity%20of%20NESCAF%C3%89%20instant%20coffee.pdf. Accessed August 3, 2016

16. Daglia M, Cuzzoni MT, Dacarro C. Antibacterial activity of coffee. *J Agric Food Chem*. 1994; 42(10): 2270-2272. doi: 10.1021/jf00046a035

17. Daglia M, Cuzzoni MT, Dacarro C. Antibacterial activity

ISSN 2473-4799 Open Journal http://dx.doi.org/10.17140/DRMTOJ-1-112

of coffees relationship between biological activity and chemical markers. *J Agric Food Chem*. 1994; 42(10): 2273-2277. doi: 10.1021/jf00046a036

18. Dogazaki C, Shindo T, Furuhata K, Furuyama M. Identification of chemical antibacterial components against Legionellapneumophila in a coffee beverage. *Yakugaku Zasshi*. 2002; 122(7): 487-494. doi: 10.1248/yakushi.122.487

19. Furuhata K, Dogaski C, Hura M, Fukuyama M. Inactivation of Legionella pneumophilia by phenol compounds contained in coffee. *J Antibact Antifung Agents*. 2002; 30: 291-297. Web site. http://agris.fao.org/agris-search/search.do?recordID=JP2002005669. Accessed August 3, 2016

20. Daglia M, Tarsi R, Papetti A, et al. Antiadhesive effect of green and roasted coffee on Streptococcus mutans adhesive properties on saliva-coated hydroxyapatite beads. *J Agric Food Chem*. 2002; 50(5): 1225-1229. doi: 10.1021/jf010958t

21. Almeida AAP, Naghetini CC, Santos VR, Glória MBA. In Vitro antimicrobial activity of coffee extracts on Streptococcus mutans. In 20th International Conference on Coffee Science. Bangalore, India: Proccedings of ASIC Conferences; 2004: 242-248.

22. Almeida AAP, Farah A, Silvia DA, Nunan EA, Glória MBA. Antibacterial activity of coffee extracts and selected coffee chemical compounds against enterobacteria. *J Agric Food Chem*. 2006; 54(23): 8738-8743. doi: 10.1021/jf0617317

23. Yuwono SH. The Advantages of Coffee Powder for the Healing Of Diabetic Foot Ulcer. Presented as a Poster in ATTD 2012 Barcelona, Spain, at February 8, 2012. Web site. http://pustaka.unpad.ac.id/wp-content/uploads/2014/06/Advantages-Of-Coffee-Powder-For-The-Healing-Of-Diabetic-Foot-Ulcer.pdf. Accessed July 21, 2016

24. Yuwono HS. The new paradigm of wound management using coffee powder. *Glob J Surg*. 2014; 2(2): 25-29. doi: 10.12691/js-2-2-2

25. Ojeh N, Stojadinovic O, Pastar I, et al. The effects of caffeine on wound healing. *Int Wound J*. 2014. doi: 10.1111/iwj.12327