Openventio PUBLISHERS

ISSN 2377-1623

DENTISTRY

Open Journal

| November 2015 | Volume 2 | Issue 4 |

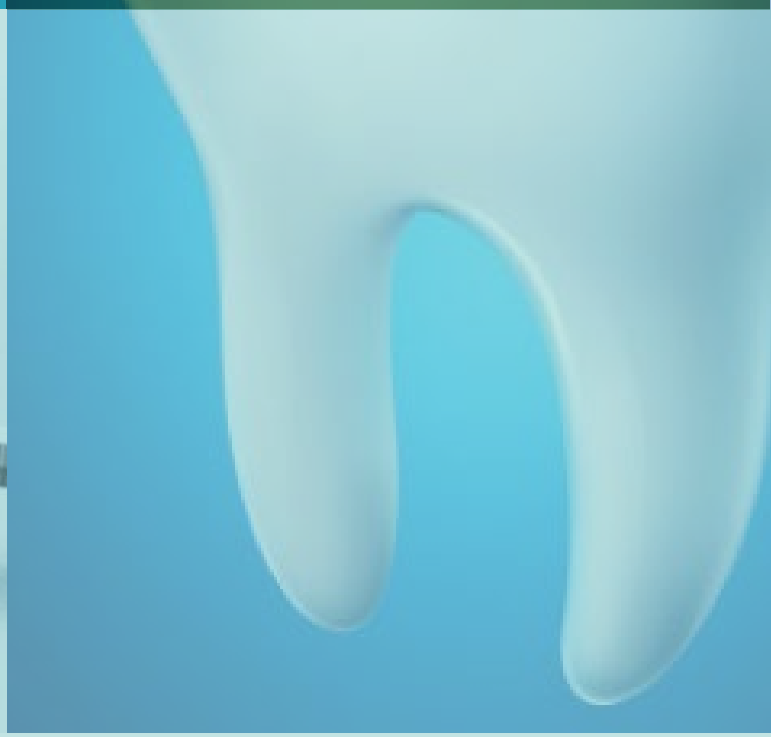

www.openventio.org

DENTISTRY

Openventio PUBLISHERS

ISSN 2377-1623

Open Journal

TABLE OF CONTENTS

DENTISTRY

Openventio PUBLISHERS

ISSN 2377-1623 Open Journal http://dx.doi.org/10.17140/DOJ-2-e003

Editorial

*Corresponding author
Daniel Kazachkov, DMD
Dental Arts of Westwood
Dentist Serving Westwood
Needham, Dedham, Norwood
MA, USA
E-mail: dr.dan@dentalartsofwestwood.com

Volume 2 : Issue 4
Article Ref. #: 1000DOJ2e003

Article History
Received: October 29th, 2015
Accepted: October 30th, 2015
Published: October 30th, 2015

Citation
Kazachkov D. Implantology have forever changed dentistry. *Dent Open J*. 2015; 2(4): e5-e7. doi: 10.17140/DOJ-2-e003

Implantology have Forever Changed Dentistry

Daniel Kazachkov*

Dental Arts of Westwood, Dentist Serving Westwood, Needham, Dedham, Norwood, MA, USA

Implantology have forever changed dentistry as we know it and its rapid leaps and bounds are trying to keep up with many of the patient's wants and needs as well as with all the clinician's skill sets. It used to be implants had to be long, engaging the zygomatic bone in places where bone was low on the maxilla, and dentistry evolved to move and lift the sinus. We used to have to move nerves on the mandible, but now we have mini implants for patients who would not be great candidates for such major surgical procedures. We used to have no options when a tooth would fracture and had to bring the depressing diagnoses to our patients with a sad look and offer last ditch efforts in things like root hemisections to help retrieve some semblance of occlusal function for people that desperately wanted to avoid dentures. Dentures are still the basis on which I scare my younger patients to brush and floss and to avoid the lifestyle of their grandparents, but implants have even become a life saver for those patients in dentures as well who used to suffer through their meal, eating more fixodent then food. Speaking about the good old days of enjoying a simple meal.

Implants have brought a lot of confidence to dentists in many other dental procedures, like root canals, knowing that if a tooth breaks or a root canal fails, all we have to do is open up a small sterile container and take out a titanium masterpiece of a tooth that comes in many sizes, which we can use to build a whole new foundation for the patients future bite. And these days, implants allow for amazing immediate placement, which with bone grafting has been shown to allow for easier and faster healing of extraction sites with less bone loss then if the implant was to be placed after the healing of the socket has taken place. It seems like the implant is the perfect tool for any general practitioner and can truly be a rescuer of hopeless teeth, impossible dental procedures and the patient's bite.

Other things we have noticed in the 4 years we've been placing implants and in the 5 years our office has been open, when an oral surgeon used to place our implants for us, is the staggering ability of patients to gain comfort and confidence in areas where they had severe pain, periodontal destruction around teeth, infections from endodontic failures, and general oral discomfort in all the areas where we would expect someone to be hurting. All that was to keep the hopeless teeth in place for a better picture, or for the lack of desire to have a gap in the mouth.

Interestingly enough, it was the other areas that the patients never complained about that began to become noticed and sore by the patients. Areas that we as providers had mentioned to them years before and got the same response of "*It doesn't hurt though Doc*." By eliminating the areas that the patients are desperately clinging on to, and treating those areas first, we were able to reduce the general discomfort the patients have been living with for years, and after the major problems were gone, patients started to feel the minor ones as uncomfortable, helping us as clinicians to deliver the full array of dentistry and help prevent the full destruction of the rest of the mouth. It was as if the patients have been experiencing so much pain that they had what I call "*referred comfort*." Referred comfort is the camouflaging of pain in minor areas by pain and discomfort from major ones. This was most notably seen in old failed root canal procedures with sinus tracts that the patients wanted to hold on to in order to chew, but always avoided

ISSN 2377-1623 Open Journal http://dx.doi.org/10.17140/DOJ-2-e003

when eating. This would lead to the overuse of the opposite side. This would lead to further poisoning of the periodontal ecosystem and eventually bone loss, and possible endodontic needs on the surrounding teeth from combined periodontal and endodontic lesions and J-lesions. Many people had said they never knew that teeth were not supposed to hurt after age 50. They believed this was the normal progression of aging.

Another issue I've seen increase drastically is dental hygiene compliance to flossing on a regular bases. We have all had patients that told us that they were afraid to floss because they were "*gonna pop out their old filling or crown*," and that was a good enough reason for the patient to fully neglect flossing in their own minds.

As irrational as it sounds, there are patients like this that I encounter every week. And this condition will not change until the patient will have a stable oral cavity. However with the types of forces that the mouth experiences, and especially in today's grind happy and stressed out society, floss is hardly the culprit in the destruction of teeth.

Once the implants are placed and the loose teeth were eliminated, we had noticed that patients increase the flossing of the entire oral cavity. The stability of their teeth allows them to focus on the rest of the big picture and to maintain the remainder of their teeth with gusto and vigor. This of course could be from the sticker shock of the still very expensive dental implant as well, and the desire to maintain something new and beautiful that the patient hasn't had. Especially when we are talking about the anterior region of the mouth. But whatever it is that elevates the compliance, it's there, and we hope it's there to stay. This allows us to retain a healthy periodontia which will be important not just for dental reasons but for medical ones as well, as Diabetes and Heart disease have been linked to periodontitis for many years now, as have some cancers. The British Journal of Medicine as well as the American Diabetes Association, since 1993 and 2008 accordingly had listed that periodontal disease increases the correlation to risk factors of heart disease by 72 percent, diabetes by 50%, and certain cancers by 30-50%. But these facts alone were not always able to motivate the patient that was concerned about flossing damaging their mobile tooth. Pus from the teeth in the mouth was not enough to have flossing compliance. However, the delivery of the final fix in a form of the implant was indeed something that we have seen change our patients behavior. This allows me to confidently say that even a single implant has a huge impact on oral hygiene compliance of the entire oral cavity. This is of course not a full-fledged correlation, but something that had been noticed in the majority.

It is also widely known that people without any teeth don't suffer from periodontal disease. Let's not go ahead and rush all of our patients for full mouth extractions though as a ploy to prevent cancer. But keeping a destructive tooth in a healthy mouth or in an unhealthy mouth is never a good idea. However, helping people treat their dental problems and reducing their general oral inflammation and pain is certainly something to practice on a regular bases. By eliminating the hot spots, patients have started to notice other areas, such as old root canals that have stood for decades, as something that was now bothersome. Those areas may not warrant treatment immediately but become something we watch on a regular bases. Sometimes a CT scan of the patient will be a peak into what you may not see on a 2-Dimentional Periapical Radiograph. Using the Planmeca Head and Neck CT we have found more asymptomatic abscesses then I'd like to count. Everyone from family members to implant patients treating neighbouring voids has fallen into this category. It appears to me, their old root canals have found a balance in the infection and the body's ability to respond and tame the discomfort, but the abscess is still there like a time bomb waiting to break the confines of the immune system and erupt with pain or a sinus tract. There would be a time when we could only hope that the endodontists could retreat these failed old root canals, or in a worst case scenario perform an apicoectomy to further close the leaking, abscessed tooth, as if it was an agitated soda can of infection. And as long as it remained closed, the infection was left in the tooth and the decay would slowly continue.

I used to advocate the saving of the natural tooth by any means possible, but today with the magic of our tooth in a jar, aka Implant, I am able to provide the type of service to my patients that I myself would want. And an apico is not a procedure I'd be very excited about, especially knowing the epidemiology of the inside of the apicoectomied tooth. My personal philosophy has changed in my office, and it is entirely due to implants. Implants have even changed endodontic practices at their fundamental core both in my office and in that of my fellow endodontists. I have become quite proficient at root canal retreats in my career, but I simply do not do them myself anymore. I always give my patient the available option of seeing my fellow endodontists, who are true magicians at their craft. But with the costs of a retreat being what they are, and the drop in the price of implants, I find it hard for myself to fight for preserving the tooth as much as I used too. And especially when I think of how humbling it is to remove a tooth that had undergone an apicoectomy and has been "Saved" in the mouth for 30 plus years. The bone we have to lose to retreat the entire tooth's root tips and shards and the old amalgam filler is truly sad. This is all bone that could be supporting a bigger, longer implant and aid in avoiding peri-implantitis.

We still do dozens of root canals a month at my office, and the root canals are still outnumbering implants 5 to 1, but I do not see many retreats these days, nor do I have many patients opting to see the endodontists. There are a few exceptions, such as patients

Openventio PUBLISHERS

ISSN 2377-1623 Open Journal http://dx.doi.org/10.17140/DOJ-2-e003

on Bisphosphonate cancer therapy, and people who mentally can't handle the idea of an implant. But those are fewer in number now than ever before. I used to try to retreat front teeth and still may to save the natural anterior tooth due to their enamel rich structure and esthetic importance, but with the revolutionary break through after break through with tissue grafting and zirconium abutments, these are becoming less common as well.

Peri-implantitis is still the major problem with implants and one that has to be communicated to patients. Nothing will last forever in this world, but a well maintained implant has the best chance of all. It has been a break through saver of edentulous patients with locator supported over-dentures and those broken teeth in accidents that would have needed a flipper or a prepping of 2 healthy adjacent teeth for a fixed partial bridge. The future is looking bright for us dentists and I feel more and more confident each and every time I sit chairside with my patient knowing that in the drawer beside me is an amazing piece of engineering, science and art called a dental implant which I can place and allow my patient to have a great solution for years to come, and one we could both be happy and proud of. Here is to the implant revolution and evolution.

DENTISTRY

Openventio PUBLISHERS

ISSN 2377-1623 Open Journal http://dx.doi.org/10.17140/DOJ-2-119

Review

*Corresponding author
Amina Khiari, DDM
Department of Fixed Prosthodontics
Faculty of Dental Medicine
Monastir, Tunisia
Tel. +216 55 96 78 60
E-mail: amina_khiari@hotmail.fr

Volume 2 : Issue 4
Article Ref. #: 1000DOJ2119

Article History
Received: September 23rd, 2015
Accepted: October 13th, 2015
Published: October 15th, 2015

Citation
Khiari A, Hadyaoui D, Saâfi J, Harzallah H, Cherif M. Clinical attitude for failed fixed restorations: an overview. *Dent Open J*. 2015; 2(4): 100-104. doi: 10.17140/DOJ-2-119

Clinical Attitude for Failed Fixed Restorations: An Overview

Amina Khiari[1*], Dalenda Hadyaoui[2], Jilani Saâfi[2], Hassen Harzallah[2] and Mounir Cherif[2]

[1]DDM, Department of Fixed Prosthodontics, Faculty of Dental Medicine, Monastir, Tunisia
[2]Philosophic Doctor, Department of Fixed Prosthodontics, Faculty of Dental Medicine, Monastir, Tunisia

ABSTRACT

Fixed prosthodontic failures are varied and complex. Complications associated with conventional fixed prostheses are dental caries, need for endodontic treatment, periodontal disease. Poor esthetic is one of the most frequent reasons for replacing failed restorations. Knowledge regarding the clinical complications enhances clinicians to complete a thorough clinical examination and diagnosis, and to develop an esthetic-driven treatment plan including the selection of bleaching agent, the reconstruction type, and the ceramic material. This article illustrates several clinical complications of full coverage restorations, and discusses different therapeutic modalities which have to be combined and synchronized to enhance the esthetic outcome of the final fixed prostheses.

KEYWORDS: Failure; Whitening; Fiber reinforced composite post; Zirconia; Esthetic; Crowns.

ABBREVIATIONS: FPD: Fixed Partial Dentures; CAD/CAM: Computer-aided design/Computer-aided manufacturing; YTZP: Yttria Stabilized Zirconia.

INTRODUCTION

A failure has been defined as the state or condition of not meeting a desirable or intended objective, and may be viewed as the opposite of success. Fixed prosthodontic failures can be complex in terms of both diagnosis and treatment.[1] Knowledge regarding the clinical complications that can occur in fixed prosthodontics enhances the clinician's ability to complete a thorough diagnosis, develop the most appropriate treatment plan, communicate realistic expectations to patients, and plan the time intervals needed for post treatment care.[2] When a crown or Fixed Partial Dentures (FPD) fails, the primary question is whether the problem can be easily resolved, or requires extensive rehabilitation and reconstruction. A mild failure may be considered one that is generally correctable without having to remake the restoration.[1] As a matter of fact, the objectives of fixed prosthodontic treatment include: the preservation or the improvement of tissue structure, oral functions, and esthetics, ensuring restoration retention, resistance, and stability, and improving patient comfort for maximum longevity.[1]

Fixed prosthodontic failures are varied and include secondary caries, endodontic complications, ditching of the cement margin, unacceptable esthetics, cracking, and chipping fracture.[3] Burke, et al. reported in a retrospective study that there were 36% of the re-intervention involving recementing, 17% replacement of crowns, 13% direct restorations, and 12% root treatment.[4]

Walton, et al.[5] studied in 1986 the causes of loss of serviceability of crowns and FPD, and concluded that secondary caries were the most frequent cause of failure accounting 24.3% of the units requiring replacement. The decay process may be responsible for the structural weakening of teeth.[6] This may explain what was cited by Burke, et al.[4] reporting a percent-

ISSN 2377-1623 Open Journal http://dx.doi.org/10.17140/DOJ-2-119

age of 12% of root treatment as a reason of re-intervention on crowns placed in the oral cavity for 18 years or more. The caries removal and teeth preparation for endodontic treatment may contribute to the increased fragility.

In case of large destruction of coronal tooth structure and after endodontic therapy, the reconstruction of structurally compromised non vital teeth seems to be necessary. In fact, selecting the appropriate reconstruction for each non vital tooth should be based on many factors such as the remaining hard tooth structure, the number and thickness of the residual cavity, the position of the tooth in the arch and the load implied.[6] The clinical choice may be an esthetic post and core restoration consisting of a composite resin core retained by a fiber post which has better stress distribution pattern and esthetic result.[7]

As reported, Walton, et al.[5] periodontal diseases or mobility were the next most frequent oral diseases causing failure of single crowns or PDF accounting 4.6% of all units requiring replacement. The second most frequent reason for replacement was poor esthetics as reported by patients themselves accounting for 6% units requiring replacement. Worn or loss of resin veneers led to failure in 10.8% of the units observed and the need of replacement in 7.2%.

The metallic component in some restorations can cause a discoloration of the abutment teeth and gingival collar, and aesthetic demands have an enormous impact of the treatment planning of single tooth crowns replacement, this leads to interdisciplinary treatments such as intracoronal bleaching to improve esthetic, and to the use of colored material like ceramic and glass fiber post with a reinforced composite to build up post cores.[8]

Following the introduction of the first feldspathic porcelain crown, the interest and demand for non-metallic and biocompatible restorative materials increased for clinicians and patients. Developments in ceramic core materials such as lithium disilicate, aluminium oxide, and zirconium oxide have allowed more widespread application of all-ceramic restorations over the past 10 years.[9]

In the past, the importance of esthetics was discounted in favor of terms such as function, structure, and biology. However, if a treatment plan does not begin with a clear view of its esthetic impact on the patient, then the outcome could be disastrous. In today's interdisciplinary dental world, treatment planning must begin with well-defined esthetic objectives. By beginning with esthetic considerations, and taking into consideration the impact on function, structure, and biology, the clinician can use the various disciplines in dentistry to deliver the highest level of dental care to each patient.[10]

The ultimate goal of single crown replacement is to treat at first crown complications and second to improve esthetic and to restore function. This article illustrates the clinical techniques and esthetic-driven sequence for an outcome-based protocol that enhances therapeutic cohesiveness and ensures the sequential transfer of design objectives for the preservation of esthetics in multidisciplinary therapy.

MANAGEMENT PROTOCOL

Complex perio-prosthetic cases that require multidisciplinary therapy often result in compromised esthetics.[11] Once, of the most common, yet difficult clinical determination is the prognosis of teeth that may serve again as prosthetic abutments. The crown-to-root ratio is one of the primary variables in the evaluation of the suitability of the tooth as an abutment for a fixed partial denture. Radiographic evaluation has been the most widely used technique in clinical practice for assessing bone level around teeth.[12] If the abutment can be conserved and the crown removal is recommended, it should be atraumatic to allow the protection of residual tissues, and then to inspect the prepared abutments.

Why Treating Abutments Endodontically?

Usually, when abutments are misaligned, orthodontic treatment is often an integral component of multidisciplinary therapy, frequently enhancing the esthetics of the final restorations.[11] However, sometimes this treatment option cannot be accepted by the patient who refuses any long-lasting treatment. In same situations in order to realign the teeth in occlusal plan, the axes of the abutments need to be significantly shifted. This rectification can require in some situations an endodontic treatment of the vital abutment. As it was reported by Goodcare, et al.[2] in 2003 that two of three needing endodontic treatment occurred in conjunction with tooth preparation and one subsequent to restoration. Stavropoulou, et al.[13] showed in 2007 that root canal treated teeth restored with crowns show an acceptable long-term survival of 10 years. The quality of root canal preparation and filling and coronal sealing are essential factors to achieve high rates of success.[14] In fact, the root canal treatment excellency is associated with the disinfection process, which involves removing microorganisms from the root canal system by emptying, cleaning, and enlarging/shaping, combined with the use of antibacterial therapies.[14] Estrela, et al.[14] reported that higher success rates are achieved when root canal filling is short 1 to 2 mm of the apex, and the filling material should remain confined to the root canal.

Bleaching Agent Selection

On the other hand and after removing metal restorations, the abutments can be discolored. This leads to intracoronal whitening as a step to lighten the abutment, especially when translucent ceramics are recommended. Intracoronal bleaching is a conservative alternative to the more invasive esthetic treatment of non-vital discolored teeth. For that a careful examination is necessary, since the method requires healthy periodontal tissues and a root canal that is properly filled to prevent the bleach-

ISSN 2377-1623 Open Journal http://dx.doi.org/10.17140/DOJ-2-119

ing agent from reaching the periapical tissues.[15] Maleknejad, et al.[16] demonstrated in 2012 that all bleaching agents increased dentinal tubule diameter and promote alterations in mineral content of dentin with the exception of sodium perborate mixed with water. Chemical analysis revealed a significant reduction in sulfur weight percent in sodium perborate mixed with water and no significant reduction in phosphorus and calcium weight percent. These findings were proved by Rotstein, et al.[17] Moreover, Dahl, et al.[15] proved that no evidence of root canal resorption was found when sodium perborate mixed with water was used as a bleaching agent. More than 90% immediate success has been reported with the conventional bleaching process using sodium perborate mixed with water.[18] Dahl, et al.[15] reported that at present no study has provided a good predictor for the long-term outcome of internal bleaching. Sometimes, the attempt of whitening cannot be contributing and a slight discoloration persists. This can lead to contra-indicate vitro-ceramic in favor of opaque ceramic which can hide the coloration of the abutment tooth.

Why Fiber Reinforced Composite Posts Are Recommended?

In another point of view, and after failed restoration removal, abutments can be decayed. This can indicate its reconstruction. For that, many clinical factors can be implicated when selecting the appropriate reconstruction for non-vital tooth, such as: the number, the thickness and the length of residual dental tissues, the remaining hard tooth structure, the position of the tooth into the arch and the load implied, and the type of the restoration.[6] Recently, fiber reinforced composite post and core systems have become widely used in the restoration of endodontically treated teeth. Fiber reinforced resin posts offer a number of advantages over metal posts thanks to their modulus of elasticity being closer to that of dentin and superior esthetic quality.[19] For esthetic consideration, dentin color post core materials are normally used for all-ceramic crown restorations regarding its esthetic performance.[8] Teeth restored with fiber reinforced resin posts show better resistance to fracture propagation than teeth restored with prefabricated or cast metal posts.[19] Different factors are important in longevity of the post and composite core restorations, such as: the core material, post type, and the bonding strength between the fiber post and the composite cement, and between post and the composite core restoration. But the failure of these restorations mostly occurs at the junction between the composite resin core and fiber post. However, Chemical treatments can also roughen the post surface and consequently increase its mechanical interlock with composite resin core. Mosharraf, et al.[7] proved in 2012 that the tensile bond strength of core resin to fiber posts was affected by the surface treatments applied to the post surface. Sandblasting and silanization of the post surface could result in a slight improvement of the bonding strength of core resin to fiber posts. Hattori, et al.[19] reported in 2010 that the use of a prefabricated fiber post in a post-and-core complex improved the flexural properties of the core composite, regardless of fiber direction. Roberto, et al.[20] studied the influence of different restorative procedures on the fracture resistance of endodontically treated teeth submitted to intracoronal bleaching, and found a decrease in the fracture resistance of teeth submitted to dental bleaching, and restored only with composite resin or with fiberglass post, with no statistically significant difference observed when these teeth were compared to healthy teeth.

Recommendations for Preparation

After abutment teeth reconstruction, preparations should be rectified following traditional preparation guidelines not only to enhance retention of all-ceramic crowns, but also for stress distribution during dynamic loading of the restoration. Tooth preparations are made in a standardized manner: the incisal edge reduction is 1.5 to 2 millimeters, 10 degrees taper is made following the scalloping of the free gingiva margins. For esthetic reasons and for a sound tooth structure, the facial side taper is generally located 0.5 millimeter deep subgingivally with a supragingival lingual side.[21] Orkin, et al.[22] proved since 1987 that the mean duration of subgingival crowns is significantly longer than the supragingival crowns. Feather-edge finish lines, deep retentive grooves, and complex occlusal morphology are not recommended, not only for scanning and milling prerequisites, but also to decrease stress that would develop in a restoration with inadequate preparation and margin geometry.[9]

Interim Restoration Roles

A completed laboratory wax up reflecting final restorations should be utilized as a basis for the fabrication of a provisional prosthesis. Since the aesthetic outcome is pre-established in the waxup and subsequently programmed into the design of the provisional prosthesis, the latter may be utilized as a guide during adjunctive treatment procedures.[11] This provisional helps also to periodontal healing and serve to control the reduction measurements of prepared teeth. Once space requirements are satisfied, the procurement of accurate definitive impressions is quintessential to the fabrication of indirect restorations. Adequate periodontal health is a prerequisite to maintain predictable post-impression gingival margins. Atraumatic cord placement is mandatory if soft tissue marginal integrity is to be maintained. Proper technique will limit cord placement to the gingival sulcus and the junctional epithelium.[11] Then, the master impression is made reproducing the finish line, the prepared teeth, and the root emergent area.

Ceramic Selection

As it is known that the poly crystal ceramics are more opaque than vitro-ceramic. So when abutment discoloration persists, the opaque ceramics are recommended. With the development of crystalline ceramics, alumina and zirconia came into use for prosthetic reconstruction.[23] Zirconia based prostheses are commonly used for esthetic crowns and fixed restorations.[21] It can be indicated for posterior teeth, and for opaque or discolored anterior teeth. The overall esthetic and biological clinical scores for the analyzed zirconia prostheses are universally acceptable.

Tartaglia, et al.[21] reported that the patient satisfaction with the zirconia crown was also generally high. A shaded zirconia core, which has a more natural appearance with an opaque, yellow dentin overlaid by translucent enamel, provides greater esthetic results.[24] These findings were also confirmed by Schmitter, et al.[25] Yttrium-oxide partially stabilized zirconia (Y-TZP) has mechanical properties that are attractive for restorative dentistry; namely, its chemical and dimensional stability, high mechanical strength, and fracture-toughness.[9] Its mechanical properties, which are similar to those of stainless steel, allow for a substantial reduction in core thickness. Cyclical stresses are also well tolerated by this extremely biocompatible material.[21] So, zirconia has an acceptable clinical longevity that accompanies their long-lasting esthetic advantages.[26] Örtrop, et al.[27] evaluated in 2012 the 5-year clinical performance and survival of zirconia single crowns and found that out of the 143 crowns followed for 5 years, 126 (88%) did not have any complications. However, 9% of the restorations were judged as failures. Nevertheless, chipping of the veneering ceramic on zirconia restorations continues to be a problem.[26] Y-TZP can be manufactured through Computer-aided design/Computer-aided manufacturing (CAD/CAM) technology.

CONCLUSION

Clinical complications in fixed prosthodontics require specific knowledge by the clinician to enhance a thorough diagnosis. Compromised abutments may need an endodontic treatment and reconstruction that should be selected appropriately regarding esthetics and fracture resistance of abutments. Esthetic reasons confirm the need of bleaching and opaque ceramic to hide abutment coloration. Zirconia prostheses may be a suitable treatment as they proved an overall esthetic and biological clinical scores.

CONFLICTS OF INTEREST

The authors declare no conflict of interest for the manuscript.

ACKNOWLEDGEMENT

We thank our team work for its valuable efforts that helped to manage a successful treatment.

REFERENCES

1. Manappallil JJ. Classification system for conventional crown and fixed partial denture failures. *The Journal of prosthetic dentistry.* 2008; 99: 293-298. doi: 10.1016/S0022-3913(08)60064-5

2. Goodacre CJ, Bernal G, Rungcharassaeng K, Kan JY. Clinical complications in fixed prosthodontics. *The Journal of prosthetic dentistry.* 2003; 90: 31-41. doi: 10.1016/S0022-3913(03)00214-2

3. Anusavice KJ. Standardizing failure, success, and survival decisions in clinical studies of ceramic and metal-ceramic fixed dental prostheses. *Dental Materials.* 2012; 28: 102-111. doi: 10.1016/j.dental.2011.09.012

4. Burke F, Lucarotti P. Re-intervention on crowns: what comes next? *Journal of dentistry*. 2009; 37: 25-30. doi: 10.1016/j.jdent.2008.11.007

5. Walton JN, Gardner FM, Agar JR. A survey of crown and fixed partial denture failures: length of service and reasons for replacement. *The Journal of prosthetic dentistry.* 1986; 56: 416-421.

6. Deliperi S. Direct fiber-reinforced composite restoration in an endodontically-treated molar: a three-year case report. *Operative dentistry.* 2008; 33: 209-214. doi: 10.2341/07-99

7. Mosharraf R, Baghaei Yazdi N. Comparative evaluation of effects of different surface treatment methods on bond strength between fiber post and composite core. *The journal of advanced prosthodontics.* 2012; 4: 103-108. doi: 10.4047/jap.2012.4.2.103

8. Ge J, Wang X-Z, Feng H-L. Influence of different post core materials on the color of Empress 2 full ceramic crowns. *Chinese medical journal.* 2006; 119: 1715-1720.

9. Conrad HJ, Seong W-J, Pesun IJ. Current ceramic materials and systems with clinical recommendations: a systematic review. *The Journal of prosthetic dentistry.* 2007; 98: 389-404.

10. Spear FM, Kokich VG. A multidisciplinary approach to esthetic dentistry. *Dental Clinics of North America.* 2007; 51: 487-505.

11. Lee EA, Jun S. Aesthetic design preservation in multidisciplinary therapy: philosophy and clinical execution. *Practical Procedures and Aesthetic Dentistry.* 2002; 14: 561-569.

12. Grossmann Y, Sadan A. The prosthodontic concept of crown-to-root ratio: a review of the literature. *The Journal of prosthetic dentistry.* 2005; 93: 559-562.

13. Stavropoulou A, Koidis P. A systematic review of single crowns on endodontically treated teeth. *Journal of dentistry.* 2007; 35: 761-767. doi: 10.1016/j.jdent.2007.07.004

14. Estrela C, Holland R, Estrela CRdA, Alencar AHG, Sousa-Neto MD, Pécora JD. Characterization of successful root canal treatment. *Brazilian dental journal.* 2014; 25: 3-11.

15. Dahl J, Pallesen U. Tooth bleaching-a critical review of the biological aspects. *Critical Reviews in Oral Biology & Medicine.* 2003; 14: 292-304.

16. Maleknejad F, Ameri H, Kianfar I. Effect of intracoronal

bleaching agents on ultrastructure and mineral content of dentin. *Journal of conservative dentistry: JCD.* 2012; 15: 174. doi: 10.4103/0972-0707.94586

17. Rotstein I, Dankner E, Goldman A, Heling I, Stabholz A, Zalkind M. Histochemical analysis of dental hard tissues following bleaching. *Journal of endodontics.* 1996; 22: 23-25. doi: 10.1016/S0099-2399(96)80231-7

18. Howell RA. Bleaching discoloured root-filled teeth. *British dental journal.* 1980; 148: 159-162.

19. Hattori M, Takemoto S, Yoshinari M, Kawada E, Oda Y. Durability of fiber-post and resin core build-up systems. *Dental materials journal.* 2010; 29: 224-228. doi: 10.4012/dmj.2009-113

20. Roberto AR, Sousa-Neto MD, Viapiana R, et al. Effect of different restorative procedures on the fracture resistance of teeth submitted to internal bleaching. *Brazilian oral research.* 2012; 26: 77-82. doi: 10.1590/S1806-83242012000100013

21. Tartaglia GM, Sidoti E, Sforza C. A 3-year follow-up study of all-ceramic single and multiple crowns performed in a private practice: a prospective case series. *Clinics.* 2011; 66: 2063-2070. doi: 10.1590/S1807-59322011001200011

22. Orkin D, Reddy J, Bradshaw D. The relationship of the position of crown margins to gingival health. *The Journal of prosthetic dentistry.* 1987; 57: 421-424.

23. Piconi C, Maccauro G. Zirconia as a ceramic biomaterial. *Biomaterials.* 1999; 20: 1-25.

24. Shah K, Holloway JA, Denry IL. Effect of coloring with various metal oxides on the microstructure, color, and flexural strength of 3Y-TZP. *Journal of biomedical materials research Part B, Applied biomaterials.* 2008; 87: 329-337. doi: 10.1002/jbm.b.31107

25. Schmitter M, Mussotter K, Rammelsberg P, Gabbert O, Ohlmann B. Clinical performance of long-span zirconia frameworks for fixed dental prostheses: 5-year results. *Journal of oral rehabilitation.* 2012; 39: 552-557. doi: 10.1111/j.1365-2842.2012.02311.x

26. Della Bona A, Kelly JR. The clinical success of all-ceramic restorations. *Journal of the American Dental Association.* 2008; 139: 8S-13S.

27. Örtorp A, Kihl ML, Carlsson GE. A 5-year retrospective study of survival of zirconia single crowns fitted in a private clinical setting. *Journal of dentistry.* 2012; 40: 527-530. doi: 10.1016/j.jdent.2012.02.011

DENTISTRY

Openventio PUBLISHERS

ISSN 2377-1623 Open Journal http://dx.doi.org/10.17140/DOJ-2-120

Research

*Corresponding author
Janvière Mutamuliza
Department of Dentistry
Rwanda Military Hospital
P.O. Box 3377, Kigali, Rwanda
E-mail: jmutamuliza@gmail.com

Volume 2 : Issue 4
Article Ref. #: 1000DOJ2120

Article History
Received: July 15th, 2015
Accepted: October 19th, 2015
Published: October 19th, 2015

Citation
Mutamuliza J, Rwema F, Rulisa S, Ntaganira J. Prevalence and associated risk factors of periodontal disease among adults attending dental department in Rwanda Military Hospital (Rwanda): a cross sectional study. *Dent Open J*. 2015; 2(4): 105-111. doi: 10.17140/DOJ-2-120

Prevalence and Associated Risk Factors of Periodontal Disease among Adults Attending Dental Department in Rwanda Military Hospital (Rwanda): A Cross Sectional Study

Janvière Mutamuliza[1*], Frank Rwema[1], Stephen Rulisa[2,3] and Joseph Ntaganira[4]

[1]*Department of Dentistry, Rwanda Military Hospital, PO Box 3377, Kigali, Rwanda*
[2]*University of Rwanda, Department of Obstetrics & Gynecology, PO Box 5229, Kicukiro, Kigali, Rwanda*
[3]*Department of Clinical Research, University Teaching Hospital of Kigali, Kigali, Rwanda*
[4]*Departments of Epidemiology and Biostatistics, School of Public Health, College of Medicine and Health Sciences, University of Rwanda, PO Box 5229, Kicukiro, Kigali, Rwanda*

ABSTRACT

Background: Periodontal disease is one of the most widespread bacterial diseases of mankind and is estimated to affect 10-15% of the population. Data indicate that the prevalence of periodontal disease is very high particularly in several African countries affecting all age groups. The purpose of the present investigation was to study the prevalence of periodontal disease among 1282(15-65 years) old individuals attending the Department of Dentistry of the Rwanda Military Hospital (RMH) from July to December 2013. In addition, an attempt is made to identify possible risk factors of periodontal disease in this population.
Methods: The study included all patients aged 15-65 years old. This was a retrospective cross-sectional study where by we abstracted data from medical files of the patients and then completed a questionnaire designed for each patient. Periodontal status was assessed using the epidemiological part of the Community Periodontal Index of Treatment Needs (CPITN), the Community Periodontal Index (CPI) with 10 index teeth (17, 16, 11, 26, 27, 47, 46, 31, 36, 37) and 6 sextants (17-14, 13-23, 24-27, 38-34, 33-43, 44-47) per individual, four indicators of periodontal status were applied. All statistical analyses were performed using SPSS version 20.
Results: Of the 1282 patients enrolled in the study, 49.5% were detected with calculus. Shallow pockets (4-5 mm) were present in 26.1%, and 13.6% had deep pockets (>5 mm), 9.3% had bleeding, and only 1.5% were healthy. After multiple regression analysis and adjustment for potential confounders, our findings indicated that the age, a low level of education, frequency of tooth brushing, attending dental clinic only in an emergency, diabetes mellitus, HIV/AIDS, and smoking ($P<0.01$) were all statistically associated with the dependent variable "*periodontal disease*".
Conclusion: The results demonstrate that the vast majority of patients attending the Department of Dentistry at RMH in Rwanda had different degrees of periodontal infection and demonstrates for the first time high prevalence of periodontal status and associated risk factors in an adult cohort. Our findings are of major public health significance and needs urgent attention and also calls for further population-based research studies.

KEYWORDS: Prevalence; Periodontal diseases; Risk factors; Adults; Rwanda.

ABBREVIATIONS: ANUG: Acute Necrotizing Ulcerative Gingivitis; AOR: Adjusted Odd Ratio; CAL: Clinical Attachment Level; CDC: Centers for Disease Control and Prevention; CI: Confidence Interval; CPI: Community Periodontal Index; CPITN: Community Periodontal In-

ISSN 2377-1623 Open Journal http://dx.doi.org/10.17140/DOJ-2-120

dex of Treatment Needs; DHS: Demographic and Health Survey; NHANES III: National Health and Nutrition Examination Survey III; OR: Odd Ratio; RMH: Rwanda Military Hospital; SES: Socioeconomic status; WHO: World Health Organization; USA: United States of America; UR/CMHS/SPH: University of Rwanda, College of Medicine and Health Sciences, School of Public Health.

BACKGROUND

Periodontal disease is an inflammatory disease that affects the soft and hard structures that support the teeth and is a leading cause of connective tissue attachment and tooth loss in older adults.[1] They are the most common chronic diseases affecting people of all ages worldwide. However, the severe forms of the disease are more pronounced in older individuals primarily due to prolonged exposure to risk factors.[2] Several methods have been developed to study the distribution of periodontal diseases in a population. From the epidemiological and clinical data, it is clear that the severity of periodontal disease can be categorized as mild, moderate, or severe on the basis of multiple measurements of periodontal pocket depth, attachment loss, and gingival inflammation around teeth.[3] Additionally, data from large epidemiological studies indicate in some populations periodontal disease is more prevalent in males than in females and it worsens with increasing age.[4,5] One of the major risk factors of periodontal diseases is considered to be poor oral hygiene.[5] The most widely accepted methods for controlling periodontal diseases and the associated conditions are personally and professionally applied mechanical oral hygiene measures.[6,7]

Severe periodontal disease can be associated with other systemic diseases, for example, diabetes mellitus, HIV infection, adverse pregnancy outcomes, cardiovascular diseases, certain types of leukemia, neutropenias and genetic disorders. Furthermore, some systemic diseases have oral manifestations which increase the risk of oral disease, which in turn is a risk factor for a number of general health conditions.[5,8] With such a relationship between oral health and general health, there is a strong reason to prevent and control periodontal diseases, to do otherwise would be irresponsible and unethical.

To date, there is no information on the prevalence and risk factors of periodontal diseases in Rwanda. Such data are important to identify people at high risk for periodontal disease and undertake strategic planning for preventive and therapeutic programs. Against this background, the present study has been designed to study the prevalence of periodontal diseases and associated risk factors including the age, gender, frequency of tooth brushing, and smoking in an adult population seeking dental services in Rwanda Military Hospital, Kigali City, Rwanda.

METHODS

This retrospective, cross-sectional, descriptive study was undertaken to evaluate the periodontal status and their risk factors in 15-65 year old individuals attending the Department of Dentistry of the Rwanda Military Hospital (RMH) at Kicukiro District, Rwanda. A total of 1282 adults aged of 15-65 who attended the Hospital for dental services from July to December 2013 were included in the study.

DATA COLLECTION

The required information for each patient was abstracted from their medical files and then completed using a questionnaire designed for each patient. The questionnaire was composed of 4 parts: demographic characteristics (sex, date of birth, educational level and occupation); oral health behaviours (oral hygiene aids used, use of toothpaste, frequency of tooth brushing and flossing, current smoker, frequency of smoking, preventive dental visits and other aspects of care that might influence the participant's oral health); systemic diseases and other conditions related to periodontal diseases and finally, periodontal condition. Community periodontal index (CPI) of community periodontal index of treatment need (CPITN) was used to record the periodontal status. Periodontal status was assessed using the epidemiological part of the CPITN, the CPI[12,13] with 10 index teeth (17, 16, 11, 26, 27, 47, 46, 31, 36, 37) and 6 sextants (17-14,13-23, 24-27, 38-34, 33-43, 44-47) per individual, four indicators of periodontal status were recorded.

When two indexed teeth were considered in a sextant, the tooth with the highest score was recorded. Each indexed tooth was scored on 2 sites (buccal and lingual) and each sextant was scored according to its highest CPI score. If no indexed tooth was present in a sextant, all the remaining teeth in that sextant were examined and the highest score was recorded as the score for that sextant. The overall CPI score of the participant represented the value of the highest recorded code for that individual. A patient was considered as having periodontitis when he/she was classified as having CPI $\leq$ to 3.

STATISTICAL METHODS

Statistical analysis was performed using statistical package for social sciences (SPSS version 20). Cross tabulation, chi square statistics, logistic regression analyses was used for statistical analysis at 5% level of significance. The variables were age, gender, education level, occupation, use of toothpaste, frequency of tooth brushing, frequency of tooth-flossing, dental office attendance, variables related to conditions known to be linked to periodontal diseases and variables related to smoking status of the patient. These variables were compared with the CPI codes.

ETHICAL CONSIDERATIONS

Permission and ethical clearance was sought from the Institutional Review Board of the University of Rwanda, College

ISSN 2377-1623 Open Journal http://dx.doi.org/10.17140/DOJ-2-120

of Medicine and Health Sciences, School of Public Health (UR/CMHS/SPH). Approval reference number was 017/UR/CMHS/SPH/2014. The UR/CMHS/SPH Institutional Review Board is operating under the Rwanda National Ethics Committee (FWA Assurance No: 00001973; IRB 00001497 of IORG 0001100). This study was based on hospital records.

RESULTS

Of the 1282 adults who participated in this study, 588(45.9%) were females and 694(54.1%) were males. 773(60.3%) were in the age group of 15-34 years and 509(39.7%) 35-65 years. 173(13.5%) were illiterate or had primary school level of education while 1109(86.5%) had secondary or university level of education; 511(39.9%) were unemployed and 771(60.1%) were employed (Table 1). All patients enrolled in the study were documented as using a toothbrush. In terms of frequency of tooth-brushing, more than half of the patients enrolled in the study (69.7%) were reported as, brushing once per day, 349(27.2%) were reported as brushing twice or more a day and 39(3%) were brushing their teeth irregularly. The vast majority of the patients numbering at 1280(99.8%) were documented using dome form odd toothpaste. Of 1256 patients 98 percent never used dental floss.

Variables	Number	%
Age		
15-34 years old	773	60.3
35-65 years old	509	39.7
Gender		
Female	588	45.9
Male	694	54.1
Education level		
Illiterate or primary school	173	13.5
Secondary school/University	1109	86.5
Occupation		
Unemployed	511	39.9
Employed	771	60.1

Table 1: Socio-demographic characteristics of the study population (N=1282).

Only 22(1.7%) reported were irregular users of dental floss, 3(0.2%) were using dental floss once per day. A single individual (0.1%) was using dental floss twice or more a day. As per dental office attendance, 1217 patients (94.9%) reported attending when there is an emergency dental situation while 65(5.1%) were attending the dental department for preventive purposes (Table 2). The prevalance of conditions that impact on the pathogenesis is of periodontal diseases are shown in Table 3. Accordingly, a small proportion of patients, 107(8.3%) were pregnant, 107(8.3%) were documented as diabetic patients, 104(8.1%) were living with HIV/AIDS and 23(1.8%) suffered from different forms of cancer. As for the smoking status of the participants, those who never smoked comprised 108(9.5%) of the study population. The vast majority 1257(98%) were documented as not undergoing orthodontic treatment. Of the 1282 adults enrolled in the study, the majority, 49.5% were detected with calculus followed by shallow pockets (4-5 mm) 26.1%; 13.6% had deep pockets, 9.3% had bleeding, and only 1.5% were healthy as it is demonstrated in Table 4.

Variables	Number	%
Tooth-brushing		
Irregular	39	3.0
Once per day	894	69.7
Twice or more a day	349	27.2
Use of toothpaste		
Yes	1280	99.8
No	2	0.2
Tooth-flossing		
Never	1256	98.0
Irregular	22	1.7
Once per day	3	0.2
Twice or more a day	1	0.1
Dental Office Attendance		
Emergency only	1217	94.9
Preventive	65	5.1

Table 2: Oral health behaviour (N=1282).

Variables	Number	%
Orthodontic treatment		
Yes	25	2
No	1257	98
Pregnancy		
Yes	107	8.3
No	1175	91.7
Diabetes		
Yes	107	8.3
No	1175	91.7
HIV/AIDS		
Yes	104	8.1
No	1178	91.9
Cancer		
Yes	23	1.8
No	1259	98.2
Smoking Status		
Ever smoked	108	9.5%
Never smoked	1174	91.5%

Table 3: Distribution of clinical conditions known to be related to Periodontal Diseases (N=1282).

ISSN 2377-1623 Open Journal http://dx.doi.org/10.17140/DOJ-2-120

CPI	Variables	Number	%
0	Healthy gingival	19	1.5
1	Bleeding on gentle probing	120	9.3
2	Calculus at any supra or sub gingival site	635	49.5
3	Shallow pocket (4-5 mm)	334	26.1
4	Deep pocket (6 mm or more)	174	13.6

Table 4: Distribution of Periodontal Condition (N=1282).

In the logistic regression (full and reduced model) shown in Table 5, patient between 35-65 years old were 11.421 times more likely to develop periodontal diseases. On the other hand low level of education, irregular tooth brushing, attending dental clinic only in an emergency situation, diabetes mellitus, HIV/AIDS and smoking were also associated with periodontal diseases.

DISCUSSION

The purpose of this study was to determine the prevalence of periodontal disease among individuals aged between 15-65 years old who attend dental clinic in Rwanda Military Hospital. In our study, one of the most frequently observed condition was calculus at any supra or sub gingival site (49.5%) followed by shallow pockets of 4-5 mm (26.1%). Deep pockets

	Full model				Reduced model		
Factors	**Prevalence**	**OR**	**95% C.I.**	**P value**	**AOR**	**95% C.I.**	**P value**
1. Socio-demographic characteristics							
Age							
15-34 years old	15.9%	1			1		
35-65 years old	75.6%	11.440	(8.032-16.294)	**0.000****	11.421	(8.029-16.247)	**0.000****
Education level							
Illiterate or primary school	69.9%	1			1		
Secondary school and beyond	34.9%	0.360	(0.221-0.586)	**0.000****	0.358	(0.220-0.583)	**0.000****
Occupation							
Unemployed	24.7%	1			1		
Employed	49.5%	2.017	(1.374-2.962)	**0.000****	2.042	(1.392-2.997)	**0.000****
Oral health behaviour characteristics							
Toothbrushing							
Irregular user	92.3%	1			1		
Regular user	38%	0.100	(0.023-0.428)	**0.002****	0.105	(0.025-0.446)	**0.002****
Dental Office Attendance							
Emergency	40.4%	1					
Preventive	24.6%	0.244	(0.119-0.501)	**0.000****	0.243	(0.119-0.498)	**0.000****
2. Clinical conditions known to be related to Periodontal Diseases							
Pregnancy							
Yes	22.4%	1					
No	41.2%	1.369	(0.770-2.432)	0.285	-	-	-
Diabetes							
Yes	90.7%	1			1		
No	35%	0.327	(0.159-0.673)	**0.002****	0.317	(0.154-0.651)	**0.002****
HIV/AIDS							
Yes	93.3%	1			1		
No	34.9%	0.027	(0.011-0.064)	**0.000****	0.146	(0.011-0.063)	**0.000****
3. Smoking status							
Smoking status							
Patients with smoking history	90.7%	1			1		
Patients without smoking history	34.9%	0.150	(0.071-0.319)	**0.000****	0.146	(0.069-0.310)	**0.000****

Table 5: Predictors of periodontal diseases.

ISSN 2377-1623 Open Journal http://dx.doi.org/10.17140/DOJ-2-120

of more than 6 mm were found in 13.6% of the subjects. Bleeding on gentle probing was found in only 9.4% of the population surveyed. Only 1.5% had healthy periodontium (Table 4). These findings are not surprising as most of the cohort were nit attending to regular oral hygiene measures.

The high prevalence of gingivitis (58.9%) and periodontitis (39.6%) found in this study is similar to that of gingivitis (98.7%) reported in a similar study done in Morocco and in West Africa (84.2%) respectively.[14-17] The latter studies of Harley and Floyd,[14] Adegbembo and El-Nadeef,[15] Kubota, et al.,[16] indicate that the major problem in this geographic region as in many other jurisdictions of the developing world is gingivitis and to a lesser extent periodontal disease. Other studies, for instance in Gambia, have also shown a much higher proportion (80%) of participants in need of complex periodontal treatment.[17] Interestingly in Uganda, 41% of the subjects in the age group below 25 years, one of the major problems reported were Acute Necrotizing Gingivitis[18] and early onset periodontitis (28.8%).

Further in Kenya, where both the child and adult populations have been studied adults studied, aged 15-65 years, only 20% of the surfaces had loss of attachment ≥4 mm.[19] In Tanzania, in 1967, it had been reported from the Usambara Mountains, particularly from Bumbuli and Mayo villages that more than 75% of the people over 20 years had different degrees of periodontal infection.[20]

The risk factors for periodontal disease in our study population were older age, low level of education, poor oral hygiene, the behaviour of attending dental clinic only when the patient is sick, diabetes, HIV/AIDS and smoking.[21-24] Therefore, some of these modifiable risk factors should be considered to improve the oral health of these populations.

The surface of calculus is always covered by a viable microbial plaque with periodontal pathogens, and therefore it is considered to be a secondary etiological factor for periodontal disease.[25] The proportion of study participants that exhibited these risk factors was 58.9% and therefore population-based preventive measures should be done as a priority.

Our findings showed a high prevalence of periodontal disease in diabetics compared with their peers without diabetes (90.7% *versus* 35%) and this difference was statistically significant ($p<0.01$). It is now known that periodontal disease is often a complication of diabetes. Indeed, a recent meta-analysis of 23 studies the authors concluded that the prevalence and severity of periodontal disease is greater in diabetics than non-diabetics. On the other hand, periodontitis contributes to poor metabolic control in people with diabetes[26-35] which can in turn place them at risk for diabetic complications. More studies are needed to explore fully the effects of periodontal diseases and their progress in diabetes patients.

CONCLUSION

This study shows that the oral hygiene status among the study population was very poor, and did not match the self-reported tooth brushing practices. The majority had plaque, calculus, gingival bleeding and a moderate periodontal probing pocket depth of 4-5 mm. In view of the potential association of periodontal disease with systemic diseases (atherosclerosis, diabetes, HIV/AIDS, Leukemia, myocardial infarction, stroke and pregnancy) as documented in different studies, this current health situation is of major public health significance and needs urgent attention. To conclude, our study for the first time has provided an insight into the periodontal status and risk factors for periodontal disease among adults aged between 15-65 years old in Rwanda. As such it provides valuable information to help plan a full national study.

COMPETING INTERESTS

The authors declare that they have no competing interests.

AUTHOR'S CONTRIBUTIONS

Mutamuliza Janvière (MJ) designed the protocol in collaboration with Joseph Ntaganira (JN), developed the questionnaire and directed all steps of data collection in collaboration with Rulisa Stephen (RS). Frank Rwema (FR) supervised all the data collection, supervised data entry and cleaning. MJ carried out the statistical analyses with support from JN and RS. MJ drafted the manuscript; FR, RS and JN read and revised the text until a final version, which was accepted by all authors.

ACKNOWLEDGMENT

The authors wish to thank the administrative body and clinical staffs of Rwanda Military Hospital for their support.

CONSENT

In this retrospective study, the written informed consent was waived as the required information for each patient enrolled in the study was abstracted from their medical files.

REFERENCES

1. Ranney RR. Classification of periodontal diseases. *Periodontol 2000.* 1993; 2: 13-25.

2. Albandar JM. Global risk factors and risk indicators for periodontal diseases. *Periodontology 2000*. 2002; 29: 177-206. doi: 10.1034/j.1600-0757.2002.290109.x

3. Armitage GC. Classifying periodontal diseases -a long-standing dilemma. *Periodontol 2000.* 2002; 30: 9-23.

4. Albandar JM, Brunelle JA, Kingman A. Destructive periodontal disease in adults 30 years of age and older in the United States, 1988-1994. *J Periodontol.* 1999; 70: 13-29. doi: 10.1902/jop.1999.70.1.13

5. Le CT, Boen JR. Health and numbers: basic biostatistical methods. John Wiley, Chichester, 1995.

6. Gift HC. Social factors in oral health promotion. In: Schou L, Blinkhorn AS, eds. Oral health promotion. Oxford: Oxford University Press, 1993: 65-102.

7. Axelsson P, Albandar JM, Rams TE. Prevention and control of periodontal diseases in developing and industrialized nations. *Periodontol 2000.* 2002; 29: 235-246. doi: 10.1034/j.1600-0757.2002.290112.x

8. Petersen PE. Global policy for improvement of oral health in the 21st century-implications to oral health research of World Health Assembly 2007, World Health Organization. *Community Dent Oral Epidemiol.* 2009; 37: 1-8. doi: 10.1111/j.1600-0528.2008.00448.x

9. Moore PA, Weyant RJ, Mongelluzzo MB, et al. Type 1 diabetes mellitus and oral health: assessment of tooth loss and edentulism. *J Public Health Dent*. 1998; 58: 135-142.

10. Preferansow E, Gołebiewska M, Kulikowska-Bielaczyc E, Górska M. The assessment of periodontium in patients with uncontrolled diabetes. *Adv Med Sci*. 2006; 51(Suppl 1): 170-172.

11. Selwitz RH, Pihlstrom BL. How to lower risk of developing diabetes and its complications: recommendations for the patient. *J Am Dent Assoc.* 2003; 134: 54S-58S.

12. Omar SM, Pitts NB. Oral hygiene, gingivitis and periodontal status of Libyan school children. *Community Dent Health.* 1991; 8: 329-333.

13. Ainamo JJ, Barmes DD, Beagrie GG, Cutress TT, Martin JJ, Sardo-Infirri JJ. Development of the World Health Organization (WHO) community periodontal index of treatment needs (CPITN). *International Dental Journal.* 1982; 32(3): 281-291.

14. Harley AF, Floyd PD. Prevalence of juvenile periodontitis in schoolchildren in Lagos, Nigeria. *Community Dent Oral Epidemiol.* 1988; 16: 299-301. doi: 10.1111/j.1600-0528.1988.tb01780.x

15. Adegbembo AO, El-Nadeef MA. National survey of periodontal status and treatment need among Nigerians. *Int Dent J.* 1995; 45: 197-203.

16. Kubota K, Watanabe H, Hollist NO, et al. Dental survey in Nigeria. Part 4. Prevalence and severity of periodontal diseases. *Bull Tokyo Med Dent Univ.* 1988; 35: 11-17.

17. Adegbembo AO, Adeyinka A, Danfillo IS, et al. National pathfinder survey of periodontal status and treatment needs in The Gambia. *South Afr Dent J*. 2000; 55: 151-157.

18. Wandera M, Twa-Twa J. Baseline survey of oral health of primary and secondary school pupils in Uganda. Afr Health Sci. 2003; 3: 19-22.

19. Baelum V, Fejerskov O, Manji F. Periodontal diseases in adult Kenyans. *J Clin Periodontol.* 1988; 15: 445-452.

20. Jacobson LE, Kreysler JV. Dental status of different age groups in the Usambara mountains, Tanzania. *East Afr Med J.* 1967; 44: 221-226.

21. Petersen PE, Ogawa H. Strengthening the prevention of periodontal disease: the WHO approach. *J Periodontol*. 2005; 76: 2187-2193.

22. Kocher T, Schwahn C, Gesch D, et al. Risk determinants of periodontal disease--an analysis of the study of health in Pomerania (SHIP 0). *J Clin Periodontol.* 2005; 32: 59-67. doi: 10.1111/j.1600-051X.2004.00629.x

23. Corraini P, Baelum V, Pannuti CM, Pustiglioni AN, Romito GA, Pustiglioni FE. Risk indicators for increased probing depth in an isolated population in Brazil. *J Periodontol*. 2008; 79: 1726-1734. doi: 10.1902/jop.2008.070586

24. Haubek D, Ennibi OK, Poulsen K, Vaeth M, Poulsen S, Kilian M. Risk of aggressive periodontitis in adolescent carriers of the JP2 clone of Aggregatibacter (Actinobacillus) actinomycetemcomitans in Morocco: a prospective longitudinal cohort study. *Lancet.* 2008; 371: 237-242. doi: 10.1016/S0140-6736(08)60135-X

25. Ready D, D'Aiuto F, Spratt DA, Suvan J, Tonetti MS, Wilson M. Disease severity associated with 313 presence in subgingival plaque of Porphyromonas gingivalis, Aggregatibacter actinomycetemcomitans, and Tannerella forsythia, singly or in combination, as detected by nested multiplex PCR. *J Clin Microbiol*. 2008; 46: 3380-3383. doi: 10.1128/JCM.01007-08

26. Sheiham A. Is the chemical prevention of gingivitis necessary to prevent severe periodontitis? *Periodontol 2000.* 1997; 15: 15-24. doi: 10.1111/j.1600-0757.1997.tb00100.x

27. Slots J. Herpesviruses, the missing link between gingivitis and periodontitis? *J Int Acad Periodontol.* 2004; 6: 113-119.

28. Eke PI, Thornton-Evans G, Dye BA, Genco R. Advances in surveillance of periodontitis: the centers for disease control and prevention periodontal disease surveillance project. *J Periodon-*

ISSN 2377-1623 Open Journal http://dx.doi.org/10.17140/DOJ-2-120

tol. 2012; 1337-1342. doi: 10.1902/jop.2012.110676

29. Cianciola LJ, Park BH, Bruck E, Mosovick L, Genco RJ. Prevalence of periodontal disease in insulin-dependent diabetes mellitus (juvenile diabetes). *J Am Dent Assoc.* 1982; 104: 653-660. doi: 10.14219/jada.archive.1982.0240

30. Taylor GW, Burt BA, Becker MP. Non-insulin dependent diabetes mellitus and alveolar bone loss progression over 2 years. *J Periodontol*. 1998; 69: 76-83. doi: 10.1902/jop.1998.69.1.76

31. Salvi GE, Kandylaki M, Troendle A, Persson GR, Lang NP. Experimental gingivitis in type 1 diabetics: a controlled clinical and microbiological study. *J Clin Periodontol.* 2005; 32: 310-316. doi: 10.1111/j.1600-051X.2005.00682.x

32. Lalla E, Cheng B, Lal S, et al. Diabetes mellitus promotes periodontal destruction in children. *J Clin Periodontol.* 2007; 34: 294-298. doi: 10.1111/j.1600-051X.2007.01054.x

33. Loe H. Periodontal disease: the sixth complication of diabetes mellitus. *Diabetes Care.* 1993; 16: 329-334. doi: 10.2337/diacare.16.1.329

34. Khader YS, Dauod AS, El-Qaderi SS, Alkafajei A, Batayha WQ. Periodontal status of diabetics compared with nondiabetics: a meta-analysis. *J Diabetes Complications.* 2006; 20: 59-68. doi: 10.1016/j.jdiacomp.2005.05.006

35. Taylor GW, Borgnakke WS. Periodontal disease: associations with diabetes, glycemic control and complications. *Oral Dis*. 2008; 14: 191-203. doi: 10.1111/j.1601-0825.2008.01442.x

DENTISTRY

Openventio PUBLISHERS

ISSN 2377-1623 Open Journal http://dx.doi.org/10.17140/DOJ-2-121

Research

*Corresponding author
Renate Lux
School of Dentistry
University of California at Los Angeles
10833 LeConteAvenue, Los Angeles
CA 90095-1668, USA
Tel. + 1 310 267 2767
Fax: + 1 310 794 7109
E-mail: rlux@dentistry.ucla.edu

Volume 2 : Issue 4
Article Ref. #: 1000DOJ2121

Article History
Received: October 19th, 2015
Accepted: November 5th, 2015
Published: November 6th, 2015

Citation
Li L, Guo L, Wolinsky L, Shi W, Lux R. The antimicrobial activity of pomegranate polyphenol extract (POMx) lozenges in a saliva-derived biofilm model system. *Dent Open J.* 2015; 2(4): 112-120. doi: 10.17140/DOJ-2-121

The Antimicrobial Activity of Pomegranate Polyphenol Extract (POMx) Lozenges in a Saliva-Derived Biofilm Model System

Lina Li[1], Lihong Guo[1], Lawrence Wolinsky[2], Wenyuan Shi[1] and Renate Lux[1*]

[1]*School of Dentistry, University of California at Los Angeles, Los Angeles, CA, USA*
[2]*Texas A & M University Baylor College of Dentistry, Dallas, TX, USA*

ABSTRACT

The ellagitannin type polyphenols present in Pomegranate extracts (POMx) have been associated with numerous health benefits including antibacterial activities. Despite their antibacterial potency, however, these purified pomegranate polyphenol extracts need to be incorporated into a delivery system for convenient human treatments. In this study, we performed a detailed investigation of the antimicrobial activity of pomegranate polyphenol fortified lozenges against oral bacteria including the major cariogenic species *Streptococcus mutans*. Since oral bacteria exert their cariogenic effects when they are attached as biofilms on the tooth surface, we developed a stationary saliva-derived biofilm model for high throughput parallel screening to assess effects on bacteria in their biologically relevant mode. We found strong antibacterial activities (up to >99% killing of biofilm cells) for the POMx lozenges at exposure times (15-20 min) relevant for lozenge consumption. Most interestingly, *S. mutans* appeared to be even more sensitive to these products than the general biofilm population. Furthermore, consistent with data derived for polyphenols extracted from other plants, the POMx lozenges completely prevented bacterial surface adherence as determined by live imaging. In summary, our data show that the strong antibacterial and anti-adherence activities of pomegranate extracts are maintained after processing in products such as the POMx lozenges that can be easily consumed and are therefore excellent candidates for prevention and possibly treatment of oral disease.

KEYWORDS: Pomegranate extract; Antimicrobial activity; Adherence; Biofilm; *Streptococcus mutans.*

ABBREVIATIONS: POMx: Pomegranate extracts; HBP: Hop Bract Polyphenols; GAE: Gallic Acid Equivalents; Scr: Sucrose; BHI: Brain Heart Infusion; MIC: Minimum Inhibiting Concentration; PBS: Phosphate-Buffered Saline.

INTRODUCTION

Oral plaque (biofilm) control is essential to oral disease prevention due to its strong association with dental caries and periodontitis incidence.[1] Typical approaches to oral biofilm reduction include treatment with antibacterial synthetic chemical compounds such as chlorhexidine or triclosan.[2] In recent years, the search for effective antimicrobials lead to a renewed interest in traditionally used natural substances in medical as well as the dental applications. An increasing body of research explores the antibacterial potential of especially plant extracts such as polyphenols in search for more effective and readily available biofilm control agents.[3-14] A considerable portion of these reports focuses on the efficacy against *Streptococcus mutans,*[3,5-9,11,15-24] an oral pathogen which has been recognized as the primary etiological agent for dental caries.[25]

Polyphenols extracted from various plants were reported to display a broad spectrum

of antimicrobial, antiviral and antifungal activities,[26] which include a positive effect on oral health.[27] More detailed mechanistic studies revealed that green and oolong tea extract containing catechines and other polymeric polyphenol inhibit glucosyltransferase activity in different species of mutans streptococci, consequently reducing glucan synthesis.[5,16,19] Diminished glucan synthesis was reported to decrease *S. mutans* surface attachment *in vitro*[28] as well as caries incidence in *S. mutans* infected rats.[29] Similar to the polyphenols found in tea leafs, polyphenols isolated from Hop Bract Polyphenols (HBP) exhibited inhibition on *S. mutans* glucan synthesis and adherence *in vitro*.[9] More recently, a clinical study revealed that HBP can suppress plaque re-formation during a three day period after complete plaque removal.[22]

Another botanical product with a natural high content of polyphenols are pomegranates.[30,31] These fruits have been cultivated since ancient times and were early on linked to numerous health benefits which include strong antibacterial activities.[26] A number of clinical trials have confirmed the health promoting effect of pomegranate based products in reducing low-density lipoprotein oxidation and plaque build up in atherosclerotic lesions,[32-34] and most recently, a clinical study indicated that an alcoholic pomegranate extract is active against dental plaque bacteria.[27]

In this study, we evaluated the antimicrobial effect of lozenges containing a pomegranate extract (POMx) that differs in composition from a previously reported alcoholic extract.[27] We developed an *in vitro* saliva-derived biofilm model that enables assessment of effects against oral biofilms and the primary causative agent of dental caries, *S. mutans* in particular. Inhibition of oral bacterial surface adherence was monitored using time-lapse video microscopy. The finding that the POMx containing lozenges exhibit very strong antibacterial as well as anti-adherence activities is very promising, since these products are ready for human consumption and can be easily applied for therapeutic treatment of oral diseases.

MATERIALS AND METHODS

Bacterial Strains and Culture Conditions

S. mutans strain JM11 (UA140::*pldh-luc*, Spc^r)[35] was grown anaerobically (N_2 85%, H_2 10%, and CO_2 5%) at 37 °C in BHI medium or on BHI agar plates supplemented with 800 µg/ml spectinomycin (Sigma, St Louis, MO, USA).

Treatment Solutions

Pomegranate extract (POMx) containing lozenges were obtained from POM Wonderful, LLC (Los Angeles, CA, USA). Lozenges were manufactured according to standard hard lozenge sugar process (Yummy Earth, LLC) containing two levels of purified pomegranate polyphenol extract powder (POMx). Lozenge-50 and lozenge-100 contained 1.44% for 10,000 ppm (50 mg/lozenge) and 3.09% for 20,000 ppm (100 mg/lozenge) polyphenol Gallic Acid Equivalents (GAE), respectively. The mean lozenge weight was 5 grams with the hard lozenge base mainly comprised of Sucrose (Scr). The lozenges were dissolved in 10 ml microorganism-free saliva per one lozenge since 10 ml is the average amount of saliva produced by a person eating one lozenge considering an average whole saliva production of about 0.6 ml/min and a dissolving time of about 15-20 min.[36] To address the effect of sugar in the lozenge base, 5 grams of Scr were dissolved in 10 ml microorganism-free saliva (resulting in a 50% Scr solution) as a placebo control. Microorganism-free saliva was prepared by collecting unstimulated saliva from 6 different subjects followed by a high speed spin (10 min at 16,000×*g*) and filter-sterilization (0.22 µm Millipore Corp. Billerica, MA, USA) for removal of debris and bacteria. Treatment with microorganism-free saliva served as a negative control to adjust for "carrier" and wash solution effects, whereas 70% EtOH was used as a positive microbiocidal control.

Determination of the Minimal Inhibitory Concentration (MIC)

An overnight culture of *S. mutans* strain JM11 was grown anaerobically (N_2 85%, H_2 10%, and CO_2 5%) in Brain Heart Infusion (BHI) at 37 °C and diluted to 10^5 cells/ ml. Hundred µl of this bacterial culture were placed into the necessary number of wells of a 96-well culture plate. A series of 1:2 dilutions of the treatment solutions was prepared, 100 µl portions thereof were added to each well and incubated overnight in an anaerobic chamber (N_2 85%, H_2 10%, and CO_2 5%) at 37 °C. Minimum Inhibiting Concentration (MIC) was determined to be the highest dilution at which no *via*ble cells were observed as evaluated by both microscopic examination using cell *via*bility stains (Invitrogen) and plating on BHI plates.

Biofilm growth

Biofilms were grown in sterile 48-well cell culture plates that had been coated with about 100 µl of 50% microorganism-free saliva in Phosphate-Buffered Saline (PBS) (pH 7.0) per well (see treatment solutions for preparation of microorganism-free saliva). After air-drying the saliva solution completely, the wells were UV sterilized for 1 hour. Biofilms were then seeded into the coated wells as follows: Unstimulated saliva was collected (in the late afternoon) from 6 subjects who had refrained from cleaning their teeth for about 8 hrs. This saliva was pooled at equal proportions, diluted 1:4 into BHI supplemented with 1% glucose, 1% mannose and 1% sucrose and subjected to a low speed centrifugation (10 min at 600×*g*) to remove eukaryotic cells and large debris. For specific evaluation of antibacterial effects on *S. mutans* in a saliva-derived biofilm setting, this cariogenic oral pathogen was added to the salivary bacteria as follows: An overnight culture of thespectinomycin-resistant *S. mutans* strain JM11 was grown in unsupplemented BHI, diluted 1:3 in BHI and further grown into the logarithmic growth phase.

ISSN 2377-1623 Open Journal http://dx.doi.org/10.17140/DOJ-2-121

About 1.25×10^6 of these *S. mutans* cells were added together with 400 µl of the saliva mixture into each well of the saliva-coated 48-well cell culture plate. The inoculated plates were incubated anaerobically (N_2 85%, H_2 10%, and CO_2 5%) at 37 °C overnight (16 to 18 hrs for the treatments up to 30 min of duration and 24 hrs for the overnight treatment) to allow biofilm formation. This procedure would typically yield saliva-derived biofilms containing about 0.5 to 1×10^8 total biofilm cells with an *S. mutans* proportion of 5 to 10%.

Biofilm treatments

Prior to exposure to the above treatment solutions, the growth medium was removed from the biofilms and they were washed twice with 800 µl PBS. Residual PBS was carefully removed and 100 µl (200 µl for overnight treatment) of the respective treatment was added. The biofilms were incubated with the treatment solutions for the indicated time periods and the treatment was stopped by addition of 800 µl PBS. All liquid was then removed immediately and the biofilms were washed two more times with PBS. Exposure to PBS does not interfere with biofilm *via*bility (data not shown). Treatment efficiency was evaluated by determining colony forming units (cfu). Biofilms were vigorously resuspended by pipetting in 1 ml BHI to break up the biofilms. Serial dilutions were prepared and plated for enumeration of surviving biofilm cells. To determine the effect of the treatment solution on *S. mutans*, an aliquot of the serial dilutions was plated onto BHI plates containing 800 µg/ml spectinomycin, which only allows growth of the *S. mutans* derivative JM11 that was added to the saliva-derived biofilms. Total biofilm survival was evaluated as mentioned above by plating an aliquot of the same serial dilutions onto BHI plates without antibiotic. The plates were incubated anaerobically o/n and colony forming units were counted. Treatments were typically performed in triplicate.

Assessment of bacterial adherence by video microscopy

Additionally, biofilm formation was monitored by video microscopy to address the effect of above treatments solution on the ability of bacteria to attach to the surface as well as their growth. Saliva was collected and processed as described above for preparation of biofilms. The microorganisms present in 500 µl salivary solution were collected *via* high speed centrifugation (10 min@16,000×*g*), the supernatant was removed and the pellet resuspended in 1 ml treatment solution, followed by an additional 1:5 dilution. Four hundred µl of the diluted saliva sample were placed into a well of a 24-well cell culture plate. The bacterial cells were allowed to settle for 30 min prior to recording. The plate was positioned on an inverted microscope (Nikon Eclipse TE300) fitted with a temperature stage set to 37 ºC. Biofilm development was monitored over a 7.5 hr time period with a live imaging system (SPOT camera/software-Diagnostic Instruments, Inc).

RESULTS

Effect of pomegranate polyphenol based POMx lozenges on the cariogenic oral bacterium *Streptococcus mutans*

First, the potential impact of the pomegranate extract-based POMx lozenges on oral health was evaluated by determining their MICs for *S. mutans*, an oral species that has been strongly associated with the development of dental caries. The *S. mutans* killing efficacy was directly correlated with the polyphenol content of the POMx lozenges and displayed significant antimicrobial effects at 1:4 and 1:8 final dilutions for lozenge-50 and Lozenge-100, respectively, which corresponds to about 1.25 mg/ml GAE for each lozenge (Table 1). In contrast, the 50% Scr in microorganisms-free saliva lozenge base control did not seem to have any negative effect on *S. mutans* growth despite the high osmolarity of the solution.

Treatment	MIC *Streptococcus mutans*
Microorganism-free saliva	No effect
50% Scr	No effect
Lozenge-50	1:4dil (1.25 mg/ml GAE)
Lozenge-100	1:8dil (1.25 mg/ml GAE)

The 50% Scr solution and the lozenges were prepared in microorganism-free saliva as indicated in the Materials and Methods section.

Table 1: MICs of POMx containing lozenges for *Streptococcus mutans.*

Effect of pomegranate polyphenol based POMx lozenges on the cariogenic oral bacterium *Streptococcus mutans* grown in a saliva-derived biofilm environment

MICs are typically obtained with planktonic cells. Most oral microorganisms including *S. mutans*, however, reside in complex oral biofilm communities also referred to as dental plaque. Since biofilm cells are more resilient to antimicrobial agents and have different surface properties compared to planktonic cells,[37] the effect of pomegranate polyphenol based products tested in this study on *S. mutans* was evaluated in the context of a saliva-derived biofilm environment. Addition of 1.25×10^6 *S. mutans* cellsto the saliva biofilm inoculum resulted in a proportion of *S. mutans* comprising 5-10% of the total biofilm cells (Figures 1, 2 and 3-saliva treated control). The biofilms were incubated overnight anaerobically at 37 ºC in the presence of the different treatment solutions. A striking reduction (more than 4 orders of magnitude) of total biofilm cell viability similar to EtOH treatment was observed for POMx lozenges when compared to the microorganism-free saliva control. Exposure to 50% Scr did not reduce the overall biofilm population but surprisingly resulted in a 10-fold reduction in the proportion of *S. mutans* (Figure 1).

To narrow down the effective time scale of the POMx lozenges tested in this study, overnight grown *S. mutans*-spiked

ISSN 2377-1623 Open Journal http://dx.doi.org/10.17140/DOJ-2-121

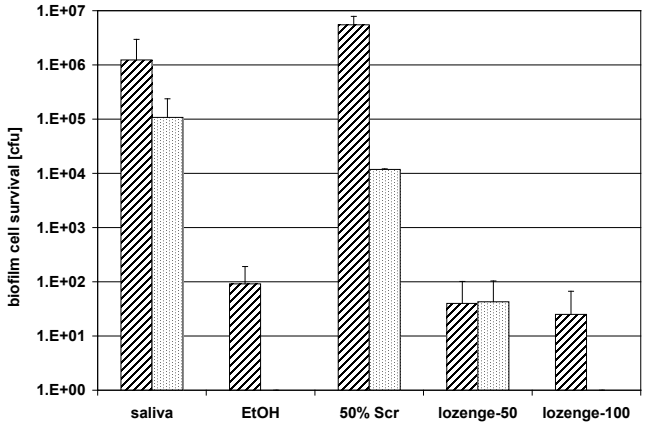

Figure 1: Survival of S. *mutans*-spiked saliva-derived biofilms after overnight exposure with treatment solutions. Shown are the colony forming units (cfu) on BHI (striped columns to indicate total biofilm cell survival) and on BHI supplemented with spectinomycin (dotted columns to indicate specific S. mutans survival) after biofilms were treated with the respective treatment solution including negative (saliva) and positive (70% EtOH) controls overnight. A minimum of three experiments was performed for each treatment solution.

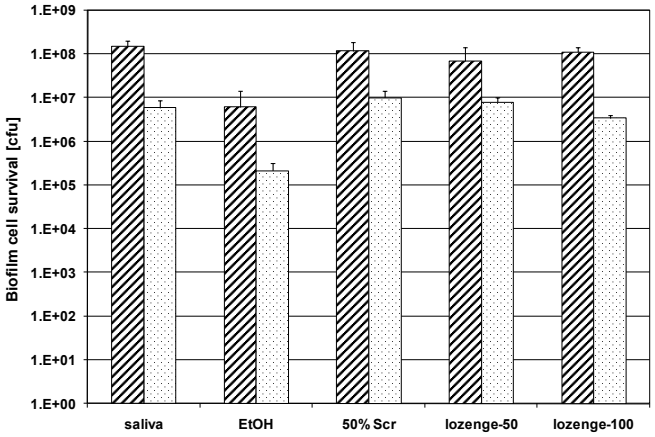

Figure 2: Survival of S. *mutans*-spiked saliva-derived biofilms after 1 min exposure with treatment solutions. Shown are the colony forming units (cfu) on BHI (striped columns to indicate total biofilm cell survival) and on BHI supplemented with spectinomycin (dotted columns to indicate specific *S. mutans* survival) after biofilms were treated with the respective treatment solution including negative (BHI, PBS, saliva) and positive (70% EtOH) controls for 1 min. A minimum of three experiments was performed for each treatment solution.

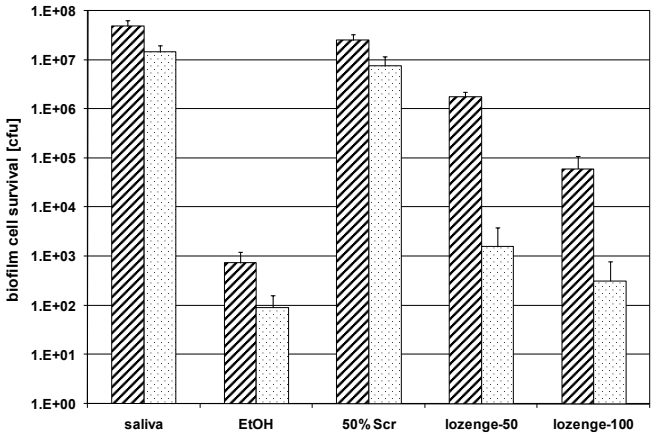

Figure 3: Survival of S. *mutans*-spiked saliva-derived biofilms after 30 min exposure with treatment solutions. Shown are the colony forming units (cfu) on BHI (striped columns to indicate total biofilm cell survival) and on BHI supplemented with spectinomycin (dotted columns to indicate specific *S. mutans* survival) after biofilms were treated with the respective treatment solution including negative (BHI, PBS, saliva) and positive (70% EtOH) controls for 30 min. A minimum of three experiments was performed for each treatment solution.

ISSN 2377-1623 Open Journal http://dx.doi.org/10.17140/DOJ-2-121

saliva-derived biofilms were exposed to the different treatment solutions for 1 min or 30 min, respectively. At the relatively short treatment time of 1 min, a slight reduction of *S. mutans* viability was observed for treatments with POMx lozenge-100 compared to the negative control treatment with microorganism-free saliva (Figure 2-dotted bars). The overall saliva-derived biofilm population, however, did not appear to be affected by any of the treatment solution at this exposure time (Figure 2-striped bars). Upon longer exposure (30 min), a different picture emerged. Both POMx lozenges produced a striking killing effect of 3 to 4 orders of magnitude on *S. mutans* (Figure 3-dotted bars). A less pronounced but nonetheless significant reduction in overall biofilm viability (more than one order of magnitude for lozenge-50 and almost three orders of magnitude for lozenge-100) was observed (Figure 3-striped bars). For both exposure times the 50% Scr control was indistinguishable from the microorganism-free saliva treated controls.

Detailed evaluation of the antibacterial effect of POMx lozenges on saliva-derived biofilms

Lozenges constitute a well-accepted and easy to use delivery vehicle that allows for extended exposure since they are dissolved slowly in the mouth. Since the POMx lozenges displayed very striking bacterial killing during the 30 min treatment, their antibacterial activities were further examined on a more detailed timescale by exposing *S.mutans*-spiked saliva-derived biofilms to the test solutions for 1, 5, 10, 15, 20 and 30 min (Figure 4). POMx lozenge-100 started to exhibit significant antibacterial activity after only 5 min of exposure, eliminating about 50% of the biofilm population (Figure 4-striped bars). At the 20 min time point, lozenge-100 had eliminated more than 99% of the biofilm cells. Consistent with the previous observations (Figures 1 and 3) the antimicrobial activity of the POMx lozenges on the cariogenic species *S. mutans* (dotted bars) was even more pronounced than on the overall biofilm population. The killing curve for both the total biofilm population as well as *S. mutans* fits best a logarithmic decline with R^2-values of 0.984 and 0.9324, respectively. Consistent with the data obtained for 1 min, 30 min and overnight exposures, lozenge-50 was less effective than lozenge-100 but followed a similar trend and also resulted in a logarithmic decline in bacterial survival, while exposure to 50% Scr did not exhibit any discernible effects (data not shown).

Evaluation of anti-adherence effect of POMx lozenges based treatment solutions

The effect of POMx lozenges on the ability of bacteria to adhere to a surface was tested using the live imaging approach described in Material and Methods. This approach enables distinction between growth and adherence. During the 7.5 hr observation period the salivary bacteria that were suspended in the microorganism-free saliva used as a control solution grew to almost confluence even though no additional carbohydrate source was added (Figure 5-upper panel). In the presence of either one of the POMx lozenges bacterial adherences was greatly reduced and no growth occurred during the observation period (Figure 5-lower panel: POMx lozenge-100 is shown as an example).

DISCUSSION

The search for new sources of biologically active components has triggered a renewed interest in the health benefits of natural products that have been historically used in many

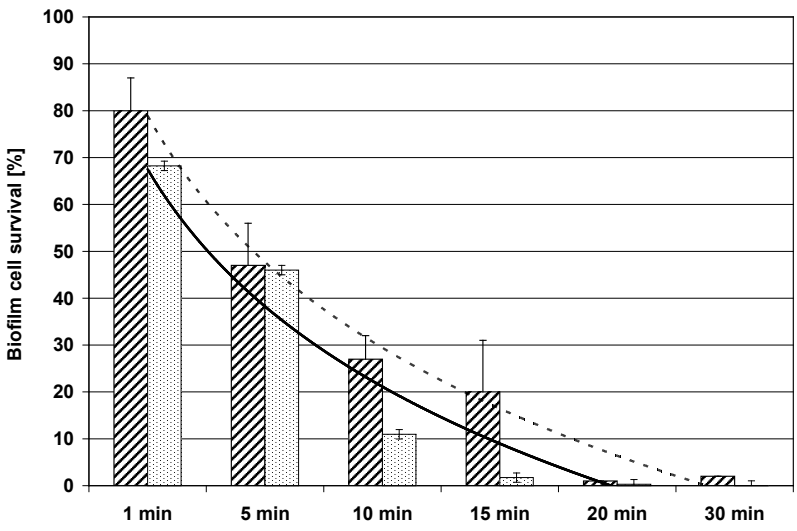

Figure 4: Detailed time course of antibacterial activities of POMx lozenge-100. Shown is the survival of all bacterial cells grown as a saliva-derived overnight biofilm (diagonally striped bars) and the *S. mutans* population (dotted bars) within these biofilms after treatment for 1, 5, 10, 15, 20 and 30 min withPOMxlozenge-100 containing 100 mg GAE/piece. The percentage survival was calculated relative to the negative control samples that were treated with microorganism-free saliva. The decline in survival over time was best fitted by logarithmic trend lines with R^2 values of 0.984 for the killing of the total biofilm population (solid line) and 0.9324 for the *S. mutans* cells (dashed line).

ISSN 2377-1623 Open Journal http://dx.doi.org/10.17140/DOJ-2-121

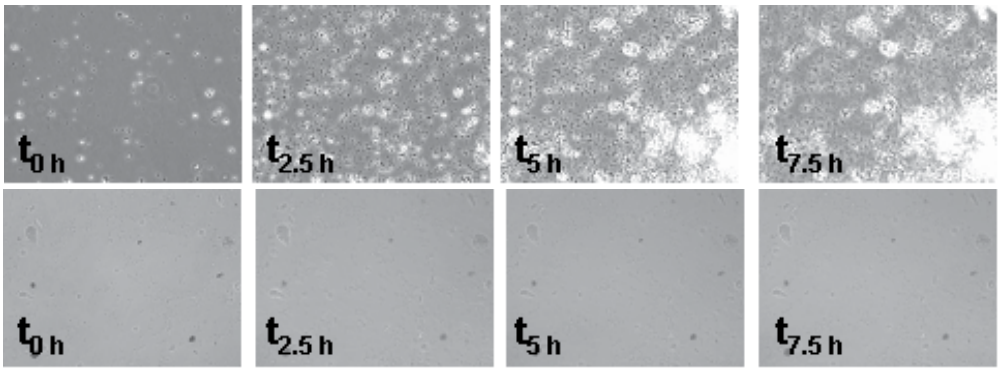

Figure 5: Effect of POMx lozenges on surface adhesion of oral bacteria. Shown are selected frames from movies taken over a7.5 hour time period. Large debris visible in the images originate from particles present in the different treatment solutions and do not correspond to bacteria.

cultures to treat a variety of ailments. Especially ellagitannin polyphenols, a main ingredient of pomegranate and a number of other plant extracts, have been studied extensively for their antibacterial activities. The effect of polyphenols extracted from a variety of plants on oral health in general and especially on the highly cariogenic species *S. mutans* has been the subject of numerous studies.[3,5-9,11,17,19-24,38] The data presented in this study revealed that the previously described health benefits of pomegranate polyphenol extract (POMx) can be extended to the oral cavity. Consistent with the findings in a limited clinical trial, which demonstrated oral biofilm reduction upon treatment with a hydroalcoholic pomegranate extract,[27] the pomegranate extracts based lozenges (which are different in composition from the hydroalcoholic extracts used by Menezes and co-workers) evaluated in this study displayed significant antibacterial activity against oral biofilm bacteria and especially the cariogenic species *S. mutans*.

Due to its role as an important oral pathogen *S. mutans* has been the major focus of a number of reports that examine the antibacterial activities of plant extracts including tea, cacao, grapesamong others. MICs between 0.5 and 32 mg ml^{-1} (4 mg ml^{-1} pomegranate skin extract) for *S. mutans* have been described for polyphenols from different sources.[8] The MICs for the pomegranate extract based lozenges tested in this study was found to be 1.25 mg/ml, which puts their activity towards the more effective end of the polyphenol extract spectrum. Even though MICs can provide a good general idea on antibacterial activities of the test components, the use of planktonic cells does not always allow drawing conclusions for bacteria grown in a biofilm setting. In particular, up to 1000-fold increased resistance against antimicrobial agents has been observed.[37] Since the majority of persistent infections including oral diseases such as caries are based on pathogenic species present in resident biofilms, the search for novel antibacterial agents with anti-biofilm activities has become an important task, which increasingly focuses on naturally occurring products. To address this important aspect, we expanded the assessment of the antibacterial activities of the POMx lozenges from standard MIC determination (Table 1) to efficacy testing against relevant oral biofilms containing the major cariogenic species *S. mutans* at a final proportion of about 5-10% (Figure 1). Most interestingly, *S. mutans* appeared to be even more sensitive to these POM products than the general biofilm population. The concern that the high osmolarity of the dissolved lozenges (50% Scr) could affect biofilm viability was not substantiated and the observed antimicrobial activities can therefore be fully attributed to pomegranate polyphenols present in the POMx based lozenges. Very importantly for a potential application as a clinically relevant and easy to administer prophylactic measure, the effective anti-biofilm and anti-adherence concentration and time frame of exposure fit very well real life lozenge consumption (Figures 3 and 4).

In addition to the antibacterial activities observed against biofilm grown bacteria the POMx lozenges drastically inhibited the surface attachment of salivary bacteria as monitored over a 7.5hr time period with video microscopy (Figure 4). This suggests that their high carbohydrate content, which would typically promote bacterial adherence and growth[39] is superseded by the antibacterial and anti-adherence activities of the polyphenols present. The effect of polyphenols on the surface attachment of *S. mutans* has been the focus of numerous mechanistic studies and revealed that a major factor is the inhibitory effect on glycosyltransferases (Gtfs).[5,11,16,19,20,29,40-42] Glycosyltransferases play a key role in biofilm formation since they are the major enzymes involved in glucan production which comprises the matrix material that *S. mutans* needs for surface attachment and biofilm build-up.[43,44] The enzymatic activity of Gtfs is greatly reduced in the presence of various polyphenols, resulting in significant decrease in surface attachment.[5,8,11] This inhibitory effect of polyphenols on one of the key enzymes for sucrose-dependent surface attachment of *S. mutans* could play in the observed effect of POMx lozenges that attachment is inhibited despite the high Scr content of the test solutions. Substitution of the high sucrose content in the lozenge base with a biological inert substitute could potentially further enhance the antibacterial activity of the POMx lozenges in oral applications.

CONCLUSION

The pomegranate polyphenol extract based lozenges tested in this study displayed antibacterial activities consistent

ISSN 2377-1623 Open Journal http://dx.doi.org/10.17140/DOJ-2-121

with their polyphenol content against saliva-derived oral biofilms and *S. mutans* in particular. The most striking effects were observed for lozenge-100, which exhibited antibacterial activities comparable to other oral care products. In addition to antibacterial activities, anti-adherence activities consistent with earlier studies on the effects of polyphenols were found. The POMx lozenges incorporate these two important polyphenol mediated anti-biofilm into a delivery vehicle (lozenge) that is generally more easily accepted than traditional oral care products such as tooth pastes or mouth rinses. Furthermore, lozenges are typically slowly dissolved in the oral cavity thereby enabling longer exposure times to the active ingredients compared to especially mouth rinses. Due to these distinguishing features the POMx lozenges provide a promising new perspective on oral care and therapy especially of children, elderly or disabled populations which are often less perceptive to traditional oral care.

CONFLICTS OF INTEREST

The authors declare that they have no conflicts of interest.

ACKNOWLEDGEMENTS

This study was supported by a grant from POM Wonderful, LLC.

Authors Contributions

Lina Li and LihongGuo performed the experiments and analyzed the data. Lawrence Wolinsky, Wenyuan Shi and Renate Lux designed and supervised the study. All authors participated in writing the manuscript.

CONSENT

No consent is required for publication of this article.

REFERENCES

1. Loe H. Oral hygiene in the prevention of caries and periodontal disease. *Int Dent J.* 2000; 50: 129-139. doi: 10.1111/j.1875-595X.2000.tb00553.x

2. Eley BM. Antibacterial agents in the control of supragingival plaque--a review. *Br Dent J.* 1999; 186, 286-296.

3. Duarte S, Gregoire S, Singh AP, et al. Inhibitory effects of cranberry polyphenols on formation and acidogenicity of *Streptococcus mutans* biofilms. *FEMS Microbiol Lett*. 2006; 257: 50-56. doi: 10.1111/j.1574-6968.2006.00147.x

4. Huber B, Eberl L, Feucht W, Polster J. Influence of polyphenols on bacterial biofilm formation and quorum-sensing. *Z Naturforsch (C).* 2003; 58: 879-884.

5. Nakahara K, Kawabata S, Ono H, et al. Inhibitory effect of oolong tea polyphenols on glycosyltransferases of mutans Streptococci. *Appl Environ Microbiol*. 1993; 59: 968-973.

6. Ooshima T,Minami T, Aono W, et al. Oolong tea polyphenols inhibit experimental dental caries in SPF rats infected with mutans streptococci. *Caries Res.* 1993; 27: 124-129. doi: 10.1159/000261529

7. Percival RS, Devine DA, Duggal MS, Chartron S, Marsh PD. The effect of cocoa polyphenols on the growth, metabolism, and biofilm formation by *Streptococcus mutans* and *Streptococcus sanguinis*. *Eur J Oral Sci.* 2006; 114: 343-348. doi: 10.1111/j.1600-0722.2006.00386.x

8. Smullen J, Koutsou GA, Foster HA, Zumbe A, Storey DM. The antibacterial activity of plant extracts containing polyphenols against *Streptococcus mutans*. *Caries Res.* 2007; 41: 342-349. doi: 10.1159/000104791

9. Tagashira M, Uchiyama K, Yoshimura T, Shirota M, Uemitsu N. Inhibition by hop bract polyphenols of cellular adherence and water-insoluble glucan synthesis of mutans streptococci. *Biosci Biotechnol Biochem.* 1997; 61: 332-335.

10. Yamanaka A, Kouchi T, Kasai K,Kato T, Ishihara K, Okuda K. Inhibitory effect of cranberry polyphenol on biofilm formation and cysteine proteases of *Porphyromonas gingivalis*. *J Periodontal Res.* 2007; 42: 589-592. doi: 10.1111/j.1600-0765.2007.00982

11. Yanagida A, Kanda T, Tanabe M, Matsudaira F, Oliveira Cordeiro, JG. Inhibitory effects of apple polyphenols and related compounds on cariogenic factors of mutans streptococci. *J Agric Food Chem.* 2000; 48: 5666-5671.

12. Lee P, Tan KS. Effects of Epigallocatechin gallate against *Enterococcus faecalis* biofilm and virulence. *Arch Oral Biol.* 2015; 60: 393-399. doi: 10.1016/j.archoralbio.2014.11.014

13. Shahzad M,Sherry L, Rajendran R, Edwards CA, Combet E, Ramage G. Utilising polyphenols for the clinical management of *Candida albicans* biofilms. *International journal of antimicrobial agents.* 2014; 44: 269-273. doi: 10.1016/j.ijantimicag.2014.05.017

14. Tomczyk M, Wiater A, Pleszczynska M. *In vitro* anticariogenic effects of aerial parts of *Potentilla recta* and its phytochemical profile. *Phytotherapy research: PTR* 2011; 25: 343-350. doi: 10.1002/ptr.3262

15. Hamada S. Kontani M, Hosono H. Peroxidase-catalyzed generation of catechin oligomers that inhibit glucosyltransferase from *Streptococcus sobrinus*. *FEMS Microbiol Lett.* 1996; 143: 35-40. doi: 10.1111/j.1574-6968.1996.tb08458.x

16. Hattori M, Kusumoto IT, Namba T, Ishigami T, Hara Y. Ef-

fect of tea polyphenols on glucan synthesis by glucosyltransferase from *Streptococcus mutans*. *Chem Pharm Bull (Tokyo).*1990; 38: 717-720.

17. Iwamoto M,Uchino K, Toukairin T,et al. The growth inhibition of *Streptococcus mutans* by 5'-nucleotidase inhibitors from *Areca catechu* L. *Chem Pharm Bull (Tokyo).*1991; 39: 1323-1324.

18. Kashket S, Paolino VJ, Lewis DA, van Houte J. In-vitro inhibition of glucosyltransferase from the dental plaque bacterium *Streptococcus mutans* by common beverages and food extracts. *Arch Oral Biol.* 1985; 30: 821-826. doi: 10.1016/0003-9969(85)90138-4

19. Matsumoto M, Hamada S, Ooshima T. Molecular analysis of the inhibitory effects of oolong tea polyphenols on glucan-binding domain of recombinant glucosyltransferases from *Streptococcus mutans* MT8148. *FEMS Microbiol Lett.* 2003; 228: 73-80.

20. Ooshima T, Minami T, Aono W, Tamura Y, Hamada S. Reduction of dental plaque deposition in humans by oolong tea extract. *Caries Res.* 1994; 28: 146-149.

21. Sasaki H,Matsumoto M, Tanaka T,et al. Antibacterial activity of polyphenol components in oolong tea extract against *Streptococcus mutans*. *Caries Res.* 2004; 38: 2-8. doi: 10.1159/000073913

22. Shinada K,Tagashira M, Watanabe H, et al. Hop bract polyphenols reduced three-day dental plaque regrowth. *J Dent Res.* 2007; 86: 848-851. doi: 10.1177/154405910708600908

23. Signoretto C, Burlacchini G, Bianchi F, Cavalleri G, Canepari P. Differences in microbiological composition of saliva and dental plaque in subjects with different drinking habits. *New Microbiol.* 2006; 29: 293-302.

24. Thimothe J, Bonsi IA, Padilla-Zakour OI, Koo H. Chemical characterization of red wine grape (*Vitis vinifera* and *Vitis interspecific* hybrids) and pomace phenolic extracts and their biological activity against *Streptococcus mutans*. *J Agric Food Chem.* 2007; 55: 10200-10207.

25. Shaw JH. Causes and control of dental caries. *N Engl J Med.* 1987; 317: 996-1004.

26. Jayaprakasha GK, Negi PS, Jena BS. Antimicrobial activities of pomegranate. In: Seeram NP, Schulman RN, Heber D, eds: Pomegranates: Ancient roots to modern medicine Medicinal and aromatic plants - industrial profiles. Boca Raton, Florida, USA: CRC Press; 2006; 43: 167-183.

27. Menezes SM, Cordeiro LN, Viana GS. *Punica granatum* (pomegranate) extract is active against dental plaque. *Journal of herbal pharmacotherapy.* 2006; 6: 79-92.

28. Hamada S, Slade HD. Biology, immunology, and cariogenicity of *Streptococcus mutans*. *Microbiol Rev.* 1980; 44: 331-384.

29. Taubman MA, Holmberg CJ, Smith DJ. Immunization of rats with synthetic peptide constructs from the glucan-binding or catalytic region of mutans streptococcal glucosyltransferase protects against dental caries. *Infect Immun.* 1995; 63: 3088-3093.

30. Gil MI, Tomas-Barberan FA, Hess-Pierce B, Holcroft DM, Kader AA. Antioxidant activity of pomegranate juice and its relationship with phenolic composition and processing. *J Agric Food Chem.* 2000; 48: 4581-4589. doi: 10.1021/jf000404a

31. Ben Nasr C, Ayed N, Metche M. Quantitative determination of the polyphenolic content of pomegranate peel. *Z Lebensm Unters Forsch.* 1996; 203: 374-378. doi: 10.1007/BF01231077

32. Aviram M, Dornfeld L, Kaplan M, et al. Pomegranate juice flavonoids inhibit low-density lipoprotein oxidation and cardiovascular diseases: studies in atherosclerotic mice and in humans. *Drugs under experimental and clinical research.* 2002; 28: 49-62.

33. Aviram M, Rosenblat M, Gaitini D, et al. Pomegranate juice consumption for 3 years by patients with carotid artery stenosis reduces common carotid intima-media thickness, blood pressure and LDL oxidation. *Clinical nutrition (Edinburgh, Scotland).* 2004; 23: 423-433. doi: 10.1016/j.clnu.2003.10.002

34. Kaplan M,Hayek T, Raz A,et al. Pomegranate juice supplementation to atherosclerotic mice reduces macrophage lipid peroxidation, cellular cholesterol accumulation and development of atherosclerosis. *The Journal of nutrition.* 2001; 131: 2082-2089.

35. Merritt J, Kreth J, Qi F, Sullivan R, Shi, W. Non-disruptive, real-time analyses of the metabolic status and viability of *Streptococcus mutans* cells in response to antimicrobial treatments. *J Microbiol Methods.* 2005; 61: 161-170. doi: 10.1016/j.mimet.2004.11.012

36. Percival RS, Challacombe SJ, Marsh PD. Flow rates of resting whole and stimulated parotid saliva in relation to age and gender. *J Dent Res.* 1994; 73: 1416-1420. doi: 10.1177/00220345940730080401

37. Costerton JW, Lewandowski Z, Caldwell DE, Korber DR, Lappin-Scott HM. Microbial biofilms. *Annual review of microbiology.* 1995; 49: 711-745. doi: 10.1146/annurev.mi.49.100195.003431

38. Otake S, Makimura M, Kuroki T, Nishihara Y, Hirasawa M. Anticaries effects of polyphenolic compounds from

ISSN 2377-1623 Open Journal http://dx.doi.org/10.17140/DOJ-2-121

Japanese green tea. *Caries Res.* 1991; 25: 438-443. doi: 10.1159/000261407

39. Krzysciak W, Jurczak, A, Koscielniak D, Bystrowska B, Skalniak A. The virulence of Streptococcus mutans and the ability to form biofilms. *European journal of clinical microbiology & infectious diseases: official publication of the European Society of Clinical Microbiology.* 2014; 33: 499-515. doi: 10.1007/s10096-013-1993-7

40. Aoki H, Shiroza T, Hayakawa M, Sato S, Kuramitsu HK. Cloning of a *Streptococcus mutans* glucosyltransferase gene coding for insoluble glucan synthesis. *Infect Immun.* 1986; 53: 587-594.

41. Hanada N, Kuramitsu HK. Isolation and characterization of the *Streptococcus mutansgtfC* gene, coding for synthesis of both soluble and insoluble glucans. *Infect Immun.* 1988; 56: 1999-2005.

42. Yamashita Y, Bowen WH, Burne RA, Kuramitsu HK. Role of the *Streptococcus mutansgtf* genes in caries induction in the specific-pathogen-free rat model. *Infect Immun.* 1993; 61: 3811-3817.

43. Tamesada M, Kawabata S, Fujiwara T, Hamada S. Synergistic effects of streptococcal glucosyltransferases on adhesive biofilm formation. *J Dent Res.* 2004; 83: 874-879. doi: 10.1177/154405910408301110

44. Thurnheer T, van der Ploeg JR, Giertsen E, Guggenheim B. Effects of *Streptococcus mutansgtfC* deficiency on mixed oral biofilms *in vitro*. *Caries Res.* 2006; 40: 163-171. doi: 10.1159/000091065

DENTISTRY

Openventio PUBLISHERS

ISSN 2377-1623 Open Journal http://dx.doi.org/10.17140/DOJ-2-122

Case Report

*Corresponding author
Nissaf Daouahi
Faculty of Dentistry
Department of Fixed Prosthodontics
Monastir University
Monastir, Tunisia
Tel. 1650725047
Fax: 1678562420
E-mail: nissafdaouahi@gmail.com

Volume 2 : Issue 4
Article Ref. #: 1000DOJ2122

Article History
Received: September 28th, 2015
Accepted: November 6th, 2015
Published: November 9th, 2015

Citation
Daouahi N, Hadyaoui D, Khlifa MB, Cherif M. Management of missing second premolar with single-tooth implant using flapless surgery. *Dent Open J.* 2015; 2(4): 121-124. doi: 10.17140/DOJ-2-122

Management of Missing Second Premolar with Single-Tooth Implant using Flapless Surgery

Nissaf Daouahi[1#*], Dalenda Hadyaoui[1#], Mohamed Ben Khlifa[2] and Mounir Cherif[1]

[#]These authors contributed equally to this work

[1]Faculty of Dentistry, Department of Fixed Prosthodontics, Monastir University, Tunisia
[2]Faculty of Dentistry, Department of Surgery, Monastir University, Tunisia

ABSTRACT

This article describes a case report of rehabilitation of missing mandibular premolar using implant supported crown and a flapless surgery. A 23 year old female patient, with agenesis of second premolar, was referred to the department of fixed prosthodontics at Dental Clinic of Monastir. Comprehensive examination revealed that, an orthodontic treatment was set up leading to space opening. The edentulous ridge was measured and it was suitable for adequate dimensions of second premolar. The adjacent teeth were vital, free from caries and fillings. Radiographic evaluation showed the feasibility of implant placement in the edentulous site. A flapless surgery technique was performed for implant placement. The implant supported crown was cemented using Zinc phosphate cement.

KEYWORDS: Missing mandibular premolar; Implant supported single crown; Flapless surgery; Cemented crown; Screw retained crown.

INTRODUCTION

For many years, conventional fixed bridges were considered to be the best treatment option for the replacement of missing single tooth. Their survival rate was estimated to be about 75% after 15 years**.** But, extensive teeth preparations can result in devitalization of the pulp which requires canal therapy. As the ideal treatment approach should be the less invasive one, two treatment modalities have become popular for single tooth replacement including implant retained restorations and resin bonded bridges. This later may, according to recent studies, function for many years. But, its credibility has been reduced especially in the posterior teeth.[1-4]

Implant supported restorations is widely proclaimed in the literature. In addition to its high success rate, it leaves the adjacent teeth untouched. Successful use of dental implants depends on optimal conditions of peri-implant tissue around it. The determination of implant size imposes a three dimensional evaluation of bone thickness. A minimum of 1.5 mm between the implant fixture and adjacent roots is, in that order, required to avoid bone resorption and be in favor of papilla regeneration. Ideal tri-dimensional positioning of dental implants, requires adequate edentulous ridge with sufficient bone thickness.[1,4-7] According to studies, the majority of failures are associated with the supra-structure rather than with the implant itself.

Recently, the use of "flapless" implant surgery has gained popularity among surgeons. In fact, it has numerous advantages, including preservation of circulation, soft tissue architecture, and hard tissue volume at the site; decreased surgical time; improved patient comfort; and accelerated recuperation. It allows also the patient to resume normal oral hygiene procedures immediately after the surgery. The successful use of this approach often requires advanced

ISSN 2377-1623 Open Journal http://dx.doi.org/10.17140/DOJ-2-122

clinical experience and surgical judgment.[7]

Implant supported fixed prostheses may be cemented or screw retained on the implant abutments. According to some authors, cementation may be preferred particularly in single unit restorations. It offers the potential for higher passivity placement of the crown.[8,9]

CLINICAL REPORT AND PROCEDURE

A 23 year old female patient, with agenesis of second premolar, was referred to the department of fixed prosthodontics after orthodontic treatment. She expressed her wishes for a minimally invasive treatment approach.

Comprehensive examination revealed that, an orthodontic treatment using edgewise brackets was performed leading to space opening for eventual prosthetic replacement of the missing tooth (Figure 1). The adjacent teeth were vital, free from caries and fillings with a suitable crown volume and height. Oral hygiene was evaluated as good. Radiographic evaluation Cone Beam Computed Tomography (CBCT) showed the feasibility of implant placement in the edentulous site. It revealed thick cortical bone and adequate cancellous bone of type 3 quality in the premolar and molar area based on the classification of Lekholm and Zarb and no remarkable alveolar ridge resorption. The edentulous ridge was measured and it was suitable for adequate dimensions of second premolar (7 mm with a thickness of 8 mm).

The mandibular canal was almost in the center of the mandible buccolingually and in the inferior 1/3 of the mandible vertically, at a distance approximately 12 mm from the alveolar crest. The decision of implant supported crown was so retained. After administration of local anesthesia with a 2% Lidocaine hydrochloride solution containing epinephrine at 12.5 ùg/ml, a flapless surgical technique was used for implant placement (Figure 2). When drilling the implant site, a direction indicator was used to check the orientation of the fixture. An implant fixture (Drive System; diameter 3.75 mm; Length 10 mm) was then placed. As aesthetic was not advocated in this situation, provisional restoration was not necessary. Initial stability was excellent. One week post flapless implant placement, peri-implant tissues health was ideal. During the healing period, the patient does not expressed discomfort or neurological symptoms. Peri implant bone was also subsequently monitored by radiological control. Osseo-integration was excellent and no bone resorption has been observed around the implant (Figure 3).

After 4 months of healing and management of peri implant soft tissues, an accurate impression using the Pick-up technique was then performed. It uses square copings and an open tray allowing the coronal coping screw to be exposed. The copings are then unscrewed to be removed along with the impression. The analogs are connected to the copings to fabricate de definitive cast (Figures 4, 5 and 6).

The abutment was selected and prepared according to the adjacent and opposite teeth. Final restoration, which consists on metal ceramic crown, was performed and cemented using Zinc phosphate cement (Figure 7). After prosthetic treatment was completed, a follow up program was carried for the patient. It offers the opportunity to examine the patient every 6 months in the first year and every 12 months in subsequent years.

DISCUSSION

The use of dental implants in the rehabilitation of dental agenesis after orthodontic treatment has become a well established and accepted contemporary clinical method. Recent studies reported implant success greater than 95% after restoration with single crowns.[1,2,5,6,10-12]

Brånemark established the use of extensive surgical flaps to visualize the surgical field during implant surgery. In fact, the elevation of a muco periosteal flap can facilitate implant placement by allowing the surgeon to visually assess bone

1. Implant placement and radiological evaluation of Osseo-integration

Figure 1: Management of adequate space for implant placement.

Figure 2: implant placement using flapless surgery.

Figure 3: Radiological evaluation after 2 months of Osseo-integration.

ISSN 2377-1623 Open Journal http://dx.doi.org/10.17140/DOJ-2-122

2. Management of periodontal tissues during the healing period

Figure 4: Placement of abutment healing.

Figure 5: Management of peri implant soft tissues.

3. The impression technique :Pick up

Figure 6: coping removed along with the impression.

4. The final restoration

Figure 7: Final restoration; cemented metal ceramic crown with reduced bucco-lingually diameter.

quantity and morphology at the site. Over the past three decades there have been several alterations to this flap design in favor of flapless implant surgery which has gained popularity among surgeons. It is indicated when the bone has abundant width and when the soft tissue has sufficient amounts of keratinized mucosa.

According to studies that compared the average marginal bone loss occurring with conventional *versus* flapless implant surgery, the authors reported slightly less bone loss for the flapless approach (-2.1 mm, SD 1.4 mm; n=70 implants) *versus* the conventional approach (-2.8 mm, SD 1.5 mm; n=39 implants).[13]

This technique has numerous advantages, including preservation of circulation, soft tissue architecture, and hard tissue volume at the site; decreased surgical time; improved patient comfort; and accelerated recuperation. It also allows the patient to resume normal oral hygiene procedures immediately after the surgery. The successful use of this approach often requires advanced clinical experience and surgical judgment

The approach has some drawbacks including a lack of proper drilling depth assessment and an inability to correct peri-implant defects because they are not exposed during surgery.[4,6,7]

There are two different methods of retaining a fixed supported restoration: screw retention and cementation. The screw retained prosthesis was originally more popular because it simplified retrieval of the supra structure. However, occlusal screw holes can compromise occlusion and porcelain strength. Recent studies, showed occlusion improvement and simplicity of fabrication for cemented restorations. From a biomechanically point of view the potential for passivity is higher when a cemented restoration is placed on the implant. The fact that there is only one screw attaching each abutment to each implant in a cemented design, *versus* two screws in screw retained prosthesis reduces the possibility of preload stresses and screw loosening. In addition, the cement space that exists between the crown and abutment can help compensate for minor discrepancies in the fit of the prosthesis.[6,8,9]

CONCLUSION

Implants placement using a flapless surgery seems to be a suitable option in the rehabilitation of missing single teeth. It is indicated in cases with sufficient bone with sufficient amounts of keratinized mucosa. It has become a well established and accepted contemporary clinical method. has numerous advantages. The successful use of this approach often requires advanced clinical experience and surgical judgment.

ISSN 2377-1623 Open Journal http://dx.doi.org/10.17140/DOJ-2-122

CONFLICTS OF INTEREST

The authors declare that they have no conflicts of interest.

CONSENT

The patient has no problem with publishing the details of the clinical report.

REFERENCES

1. Creugers NHJ, Kreulen CM, Snoek PA. A systematic review of single tooth restorations supported by implants. *Journal of dentistry.* 2008; 28: 209-217. doi: 10.1016/S0736-5748(99)00078-7

2. Sabri R. Management of congenitally missing second premolars with orthodontics and single tooth implants. *Am J Orthod Dentofacial Orthop.* 2004; 125: 634-642. doi: 10.1016/j.ajodo.2003.05.010

3. Sekine H, Miyazaki H. Dental implant treatment after improvement of oral environment by orthodontic therapy. *Bull Tokyo Dent Coll*. 2012; 53(3): 109-117. doi: 10.2209/tdcpublication.53.109

4. Kokich VG, Kokich VO. Congenitally missing mandibular second premolars: clinical options. *Advanced esthetics and interdisciplinary dentistry.* 2006; 130(4): 437-444. doi: 10.1016/j.ajodo.2006.05.025

5. Bartell D. Implants for life? a critical review of implant supported restorations. *Journal of Dentistry.* 2007; 35: 768-77.

6. Taylor TD, Agar JR. Twenty years of progress in implant prosthodontics. *JPD.* 2002; 88: 89-95. doi: 10.1067/mpr.2002.126818

7. Brodala N. Flapless surgery and its effect on dental implant outcomes. *Int J oral Maxillofac Implants.* 2009; 24(Supp l): 118-125.

8. El Anwar MI, Tamam RA, Fawzy UM, Yousief SA. The effect of luting cement type and thickness on stress distribution in upper premolar implant restored with metal ceramic crowns. *Tanta Dental Journal.* 2015; 12: 48-55. doi: 10.1016/j.tdj.2015.01.004

9. Nissan J. Long term outcome of cemented Verus Screw-Retainrd implant supported partial restorations. *Quint International*. 2011; 26: 1102-1107.

10. Simon RL. Single implant supported molar and premolar crowns: a ten-year retrospective clinical report. *JPD.* 2003; 90: 517-521. doi: 10.1016/j.prosdent.2003.08.025

11. Ozkurt Z, Kazazoglu E. Treatment modalities for single missing teeth in a Turkish subpopulation: an implant, fixed partial denture, or no restoration. *Journal of dental Sciences.* 2010; (5): 183-188. doi: 10.1016/j.jds.2010.11.002

12. Gibbard LL, Zarb G. A 5-year prospective study of Implant supported single-tooth replacements. *Journal of Canadian dental association.* 2002; 68(2): 110-116.

13. Sennerby L, Rocci A, Becker W, Jonsson L, Johansson LA, Albrektsson T. Short-term clinical results of Nobel direct implants: a retrospective multicentre analysis. *Clin Oral Implants Res*. 2008; 19: 219-226. doi: 10.1111/j.1600-0501.2007.01410.x