

Case Report

Corresponding author*Rakesh Gupta, MD, MPhil**

Professor & Head

Department of Pediatrics

Command Hospital (CC)

Lucknow-226002

Uttar Pradesh, India

Tel. 9935842002

E-mail: colrgupta@gmail.com

Volume 2 : Issue 2

Article Ref. #: 1000HARTOJ2106

Article HistoryReceived: April 15th, 2015Accepted: April 24th, 2015Published: April 27th, 2015**Citation**

Dash S, Kumar M, Gupta R, Saxena A. A rare case of BCGiosis with severe combined immunodeficiency. *HIV/AIDS Res Treat Open J.* 2015; 2(2): 41-43. doi: [10.17140/HARTOJ-2-106](https://doi.org/10.17140/HARTOJ-2-106)

Copyright

©2015 Gupta R. This is an open access article distributed under the Creative Commons Attribution 4.0 International License (CC BY 4.0), which permits unrestricted use, distribution, and reproduction in any medium, provided the original work is properly cited.

A Rare Case of BCGiosis With Severe Combined Immunodeficiency

Swati Dash¹, Mahadevan Kumar², Rakesh Gupta^{3*} and Ashok Saxena⁴¹Graded Specialist Pediatrics, INHS Jeevanti, Lucknow, Uttar Pradesh, India²Associate Professor, Department of Microbiology, Armed Forces Medical College, Pune, Maharashtra, India³Professor & Head, Department of Pediatrics, Command Hospital (CC), Lucknow, Uttar Pradesh, India⁴Brig Med & Consultant, Department of Pediatrics and Neonatology, Command Hospital (CC), Pune, Maharashtra, India**ABSTRACT**

Background: Bacille Calmette-Guerin (BCG), a live attenuated vaccine, is safe and given to all neonates in endemic countries; however may rarely cause disseminated disease, especially in immuno-deficient individuals.

Case characteristics: A 6 month old male infant, presented with vomiting, loose motions and failure to thrive. He was found to have features of severe acute malnutrition and abscess at BCG site. On investigations had features of disseminated tuberculosis in lung and skin and severe combined immunodeficiency.

Message: Infants with disseminated tuberculosis should be screened for underlying immunodeficiencies.

KEYWORDS: Disseminated tuberculosis; BCGiosis; Severe combined immunodeficiency.

INTRODUCTION

Bacille Calmette-Guerin (BCG), a live attenuated vaccine, is routinely given to all neonates in countries, where tuberculosis is endemic.¹ The most serious complication of BCG is disseminated disease occurring in immuno-deficient individuals. *Mycobacterium tuberculosis*, BCG and Non-tuberculous mycobacteria (NTM) may cause a severe disease in patients with primary immunodeficiencies.² We report a rare case of disseminated BCG infection (BCGiosis) in an infant with an underlying severe combined immunodeficiency.

CASE REPORT

A 6 month old male infant, 2nd product of a non consanguineous marriage, born by full term cesarean delivery following uneventful perinatal period with birth weight of 3.2 Kg. He was present with complaints of vomiting and loose stools for last 1 month and failure to thrive since early infancy. Vomiting was 5-6 times per day, immediately after feeding, containing undigested milk, and infant used to feel hungry and cry for food after vomiting episodes and loose stools 7-8 times per day (i.e. watery, greenish yellow in color, not mixed with blood or mucus). The infant was not gaining weight since early infancy and associated gross motor delay in form of not being able to hold his head. There was no history suggestive of any systemic illness. The infant had been exclusively breast fed till date. The infant had been administered BCG at birth and one dose of DPT immunization. There was no history of contact with tuberculosis. The general examination revealed an anxious looking infant with features of Severe

Acute Malnutrition (SAM) in form of wt/ht <-3 SD and features of visible severe wasting. There were multiple non tender, non erythematous nodules over the trunk and abscess present over the BCG site over left arm with regional adenopathy as seen in Figure 1.

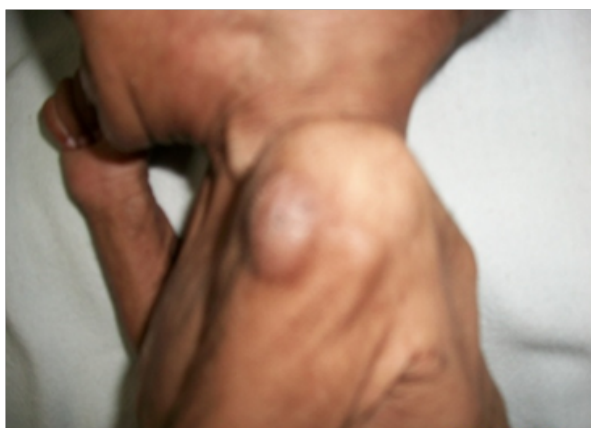

Figure 1: Showing features of Severe Acute Malnutrition (SAM) and abscess at BCG site.

CNS examination revealed symmetrically reduced bulk, global hypotonia with preserved power and reflexes. Rest of systemic examination was within normal limits. Laboratory investigations revealed: hemogram, biochemical, liver and renal parameters, stool and urine analysis were within normal limits. Venous Blood Gas analysis showed - pH -7.52, pO_2 - 53.2, pCO_2 - 22.9, HCO_3^- - 22.6, Mother's ELISA for HIV and HIV DNA-PCR for infant was negative. Mantoux test- negative, Chest X-ray (CXR) revealed patchy opacities in the right mid zone, Ultrasonography of abdomen did not reveal any organomegaly or retroperitoneal lymphadenopathy, or any lymph nodes at porta hepatis. Gastric aspirate (Figure 2) and aspirate from the BCG injection site showed numerous Acid Fast Bacilli (AFB). Histopathological examination of biopsy from the skin nodules also showed AFB and findings consistent with cutaneous tuberculosis. Infant was started on anti-tubercular treatment with rifampicin, isoniazid and Ethambutol (EHR) and management for Severe Acute Malnutrition (SAM). Breast feeding was continued and complementary feeding was initiated. After documenting weight gain in the hospital, baby was discharged.

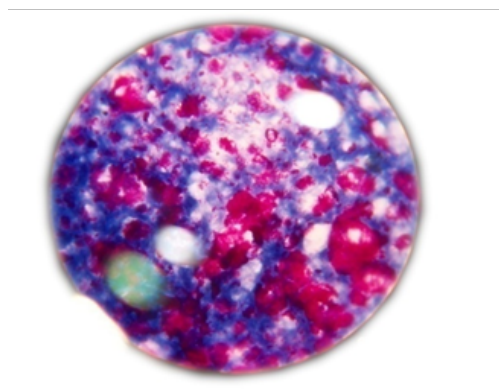


Figure 2: Gastric aspirate showing AFB.

The infant was further evaluated for the possibility of disseminated BCG infection and underlying immune-deficiency state. The aspirates from the stomach, BCG abscess and the skin nodules were subjected to DNA extraction by the spin column method as per manufacturer's instructions (Qiagen GmbH, Germany). The extracted DNA was amplified using primers targeting the RD-1 region as described by Talbot, et al.³ gel electrophoresis of the amplified products identified the organism as *Mycobacterium bovis* BCG based on the 200 bp band generated (Figure 3). The aspirates were also processed for culture on Lowenstein Jensen Medium. A dysgonic growth was observed after 4 weeks of incubation which was identified on biochemical testing as *Mycobacterium bovis* BCG. Immunoglobulin profiling revealed - IgG 75 mg/dL, IgM 10 mg/dL, IgA 13 mg/dL (less than normal). Absolute lymphocyte count- 262 /uL (less than normal). Based on above findings the diagnosis of BCGiosis with underlying Severe combined immunodeficiency (SCID) with SAM was made. The specialized tests to characterize the SCID could not be carried out. The treatment of child was modified accordingly and showing improvement on follow-up.

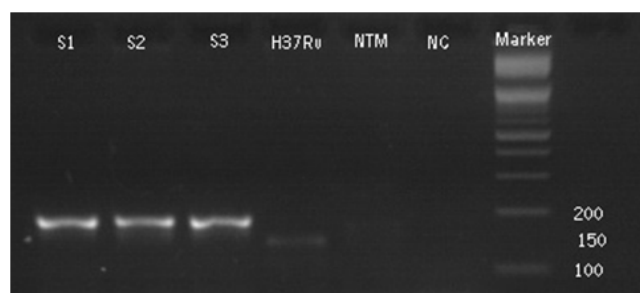


Figure 3: PCR targeting the RD1 region. Lanes S1- S3 Gastric aspirate, aspirates from BCG abscess and skin nodule. H37Rv - *Mtb*, NTM- Non tuberculous control NC - negative control, Marker 100 bp DNA Ladder.

DISCUSSION

BCG vaccine is generally safe, however, possible complications including hypersensitivity, localized lymphadenitis, fistula formation and rarely disseminated disease and death may occur. Disseminated disease is the most serious complication that may develop in children with immunodeficiency disorders, although, there are a few reports of disseminated BCG infection in normal hosts.^{4,6} The commonly associated immunodeficiencies include severe combined immunodeficiency, cellular immune defects and chronic granulomatous disease.^{1,2} In addition, recently it has been shown that patients with inherited deficiency of IL12/IL23/IFN γ axis show increased susceptibility to invasive diseases caused by the intramacrophage pathogens such as *salmonella* and *mycobacteria*.⁷ The estimated incidence of disseminated disease was 2 cases per million vaccinated children, and the mortality rate was 80%.⁸ The commonly noted sites of dissemination include lymphnodes, lung, liver/spleen, bone marrow and less commonly the skin and bones.^{1,2} The anti-mycobacterial regimens used to treat patients varied in different centre's with isoniazid, rifampicin, ethambutol, and streptomycin used most often. Despite 3-4 drug regimens, up to 70% mortality has been

described in these children with immunodeficiency. The high mortality rate was ascribed to associated immunodeficiencies, delay in diagnosis or treatment, BCG resistance to pyrazinamide, and general resistance to present therapy for disseminated BCG infection in addition to a possible reporting bias.² Bone marrow transplant has been tried in children with disseminated BCG infection and immunodeficiency.^{9,10}

In our case, the immunological panel revealed hypogammaglobulinemia and grossly reduced T-cells. Mother was negative for ELISA-HIV. There was evidence of disseminated BCG tuberculosis in form of involvement of lungs (positive CXR shadow and gastric aspirate for AFB) and skin (multiple nodules with AFB on histopathology) in addition to the BCG site abscess. The presence of multiple skin nodules is not commonly reported. Though, the child has shown weight gain on three drugs ATT, it is early to predict a good outcome and hence the child was on close follow-up. This report adds to the existing literature on disseminated BCG infection in children with congenital immunodeficiency.

ACKNOWLEDGEMENTS

SD & RG conceived the study. MK helped in laboratory investigations. SD, RG & AS involved in drafting the article.

ETHICAL CLEARANCE

The ethical clearance was obtained from the Institutional Ethical Committee.

FUNDING: None.

COMPETING INTERESTS: None stated.

REFERENCES

1. Paiman SA, Siadati A, Mamishi S, Tabatabaie P, Khotae G. Disseminated Mycobacterium bovis infection after BCG vaccination. *Iran J Allergy Asthma Immunology*. 2006; 5(3): 133-137.
2. Talbot EA, Perkins MD, Silva SF, Frothingham R. Disseminated bacilli Calmette-Guerin disease after vaccination: case report and review. *Clin Infect Dis*. 1997; 24: 1139-1146. doi: [10.1086/513642](https://doi.org/10.1086/513642)
3. Talbot EA, Williams DL, Frothingham R. PCR identification of Mycobacterium bovis BCG. *J Clin Microbiol*. 1997, 35(3): 566.
4. Doffinger R, Dupuis S, Picard C, et al. Inherited disorders of IL-12- and IFN gamma-mediated immunity: a molecular genetics update. *Mol Immunol*. 2002; 38: 903-909. doi: [10.1016/S0161-5890\(02\)00017-2](https://doi.org/10.1016/S0161-5890(02)00017-2)
5. Gonzalez B, Moreno S, Burdach R, et al. Clinical presentation of Bacillus Calmette-Guerin infections in patients with immunodeficiency syndromes. *Pediatr Infect Dis J*. 1989; 8(4): 201-206.
6. Katzir Z, Okon E, Ludmirski A. Generalized Lymphadenitis following BCG vaccination in an immunocompetent 12 years old boy. *Eur J Pediatr*. 1984; 141(3): 165-170. doi: [10.1007/BF00443216](https://doi.org/10.1007/BF00443216)
7. Mohapatra S, Sethy S, Mohanty P, Mohapatra A, Pradhan S. Primary paediatric TH1 immunodeficiency with BCG-osis. *International Journal of Case Reports and Images*. 2012; 3(5). doi: [10.5348/ijcri-2012-05-123-CR-8](https://doi.org/10.5348/ijcri-2012-05-123-CR-8)
8. Lotte A, Wasz-Hockert O, Poisson N, et al. Second IUATLD study on complications induced by intradermal BCG-vaccination. *Bull Int Union of Tuberc*. 1988; 63: 47-59.
9. Bacalhau S, Freitas C, Valente R, et al. successful handling of disseminated bcg disease in a child with severe combined immunodeficiency. *Case Reports in Medicine*. 2011; 2011: 527569. doi: [10.1155/2011/527569](https://doi.org/10.1155/2011/527569)
10. Ikinçioğullari A, Doğu F, Ciftci E, et al. An intensive approach to the treatment of disseminated BCG infection in a SCID patient. *Bone Marrow Transplant*. 2002; 30(1): 45-47. doi: [10.1038/sj.bmt.1703578](https://doi.org/10.1038/sj.bmt.1703578)