Openventio PUBLISHERS

ISSN 2572-4665

UROLOGY AND ANDROLOGY

Open Journal

| April 2017 | Volume 1 | Issue 1 |

Editor-in-Chief
Reza Mehrazin, MD

Associate Editors
Bilal Chughtai, MD
Eric Chung, MBBS, FRACS
Sanjay Gupta, PhD

www.openventio.org

UROLOGY AND ANDROLOGY

Openventio PUBLISHERS

ISSN 2572-4665

Open Journal

TABLE OF CONTENTS

UROLOGY AND ANDROLOGY

Openventio PUBLISHERS

ISSN 2572-4665 Open Journal http://dx.doi.org/10.17140/UAOJ-1-e001

Editorial

*Corresponding author
Shivam Priyadarshi, MBBS, MS, DNB, MCh
Professor
Department of Urology
S. M. S. Medical College and Hospital
C-80 Gole Market, Jawahar Nagar
Jaipur, Rajasthan 302004, India
Tel. 91-141-2654631; 98280-15854
E-mail: spriyadarshi64@gmail.com

Volume 1 : Issue 1
Article Ref. #: 1000UAOJ1e001

Article History
Received: September 11th, 2016
Accepted: September 15th, 2016
Published: September 15th, 2016

Citation
Priyadarshi S. Male infertility: The current status. *Urol Androl Open J.* 2016; 1(1): e1-e2. doi: 10.17140/UAOJ-1-e001

Copyright
©2016 Priyadarshi S. This is an open access article distributed under the Creative Commons Attribution 4.0 International License (CC BY 4.0), which permits unrestricted use, distribution, and reproduction in any medium, provided the original work is properly cited.

Male Infertility: The Current Status

Shivam Priyadarshi, MBBS, MS, DNB, MCh*

Department of Urology, S. M. S. Medical College and Hospital, C-80 Gole Market, Jawahar Nagar, Jaipur, Rajasthan 302004, India

Infertility is now a leading issue on the reproductive agenda. It is a widespread problem affecting an estimated 20% of all couples who are trying to conceive. The science and practice of male infertility has evolved tremendously in last few decades. Infertility may be attributable to male in as many as 50% cases. There have been many recent advances in the field. Refined techniques of molecular biology are now well integrated into investigative processes and diagnostic procedures. The evolving field of genomics, proteomics and metabolomics has the potential to radically change the methods of diagnosis, prognostication and management of infertility. The impact of genetic disorders on testicular functions is beginning to be understood. Research in genetic sequencing and processing may provide answers of many poorly understood causes of idiopathic male infertility today. This might also lead to identification of effective interventional techniques and a possible gene therapy. With observation and quantification of sperm bound antibodies, immunologic infertility is also becoming a challenge in the field of medical research. The future of stem cell treatment of infertility is probably the most exciting treatment in the horizon. Successful transplantation of spermatogonial stem cells into adults with resultant spermatogenesis is a distinct possibility in near future.

Other advances in technology have opened doors for improvement in diagnosis and therapy of infertile patients. Micromanipulation and intracytoplasmic sperm injection (ICSI) has tremendous potential of offering children to barren couples. Assessing the quality of embryo with optics, genomics and metabolomics has revolutionized the treatment further. Similarly, microsurgery for restoration of patency in patients with ductal obstruction is an evolving field with technical refinements constantly being introduced. Ultrasonography is playing an increasing role in the urologist's quest for accurate identification of obstruction in the male ductal system. In the past, male infertility has been approached at a descriptive level. The classification is usually based in terms of the number and concentration of spermatozoa, their motility and a subjective assessment of their morphology. These criteria represent a blunt instrument for diagnosing the fertilizing potential of the male patients. It is not so much the number or appearance of the spermatozoa that we are interested in, but it is their functional competence. Anyone involved with *in vitro* fertilization (IVF) will testify to the fact that some patients produce samples that are normal in a descriptive sense and yet repeatedly fail to fertilise eggs *in vitro*, while in other patients the opposite applies. Clearly a descriptive assessment of the semen should be reinforced with a functional analysis to assess the ability of spermatozoa to perform the complex cascade of cell recognition and membrane fusion involved in fertilizing the human ovum. Deoxyribonucleic acid (DNA) fragmentation and flouroscent *in situ* hybridization testing are replacing some of the previously used evaluation, i.e. post coital test, sperm penetration assay, of sperm function.

Seventy percent of infertile couples seeking medical help eventually succeed in having children through a variety of medical procedures and treatments available today. With the success of these "high-tech", high cost procedures like *in vitro* fertilization pre-embryo transfer (IVF-ET) and micromanipulation-intracytoplasmic sperm injection (ICSI), the evaluation of the male is often bypassed, because it is thought of as a tedious and ineffective evaluation. This approach ignores the fact that many causes of male infertility such as varicocele, ductal obstruction and infections are easily and effectively treated. In addition without a full evaluation significant diseases such as testicular cancer, pituitary tumors and neurologic disease may be overlooked. Factors like high cost, reports of an increased incidence of ovarian cancer in

ISSN 2572-4665 http://dx.doi.org/10.17140/UAOJ-1-e001

women who had been treated with fertility drugs in the past has led many couples to re-examine this approach.

Ideally the evaluation of the infertile male should result in the identification of the specific abnormality responsible for infertility. Although this is possible in some instances, many men demonstrate abnormal semen analysis for which no aetiology can be identified. When possible specific treatment is directed toward a specific aetiology. However both empirical therapies and assisted reproductive technologies (ART) may be of value in the absence of known aetiologic factors. It is important to remember that therapeutic donor insemination and adoption are treatment alternatives. The infertile couple should be made aware of these options with the physician playing a counselling role to avoid excessively prolonged futile treatments.

UROLOGY AND ANDROLOGY

Openventio PUBLISHERS

ISSN 2572-4665 Open Journal http://dx.doi.org/10.17140/UAOJ-1-e002

Editorial

*Corresponding author
Ege Can Serefoglu, MD, FECSM
Department of Urology
Bagcilar Training and Research Hospital
Istanbul, Turkey
E-mail: egecanserefoglu@hotmail.com

Volume 1 : Issue 1
Article Ref. #: 1000UAOJ1e002

Article History
Received: September 12th, 2016
Accepted: September 12th, 2016
Published: September 15th, 2016

Citation
Cakir OO, Serefoglu EC. Post-Finasteride Syndrome: An underestimated phenomenon. *Urol Androl Open J.* 2016; 1(1): e3-e4. doi: 10.17140/UAOJ-1-e002

Copyright
©2016 Serefoglu EC. This is an open access article distributed under the Creative Commons Attribution 4.0 International License (CC BY 4.0), which permits unrestricted use, distribution, and reproduction in any medium, provided the original work is properly cited.

Post-Finasteride Syndrome: An Underestimated Phenomenon

Omer Onur Cakir, MD; Ege Can Serefoglu, MD, FECSM*

Department of Urology, Bagcilar Training and Research Hospital, Istanbul, Turkey

With their increased popularity in the treatment of benign prostate hyperplasia (BPH), physicians are encountering with the side effects of 5 alpha reductase inhibitors (5ARIs) (finasteride and dutasteride) more often. Although reports regarding the persistence of these problems raise the concerns of physicians and BPH patients alike,[1,2] annual 5ARI sales continue to increase, generating approximately half billion dollars in the United States, according to Information Management System (IMS) data.[3] The United States Food and Drug Administration (FDA) approval of finasteride for androgenic alopecia (AGA) contributes to the 5ARI market and broaden the population who may suffer from side effects by decreasing the age span.[4]

Although the exact mechanism of the side effects of 5ARIs are not completely elucidated yet, the inhibition of testosterone (T) conversion to its active metabolite dihydrotestosterone (DHT) may play a role. Consequent alterations in penile nitric oxide (NO) metabolism may be responsible for erectile dysfunction (ED) whereas alterations in the neurotransmitters in the central nervous system may cause ejaculatory dysfunction and decreased libido. These sexual side effects seem to be more frequent in higher doses and in the beginning of the 5ARI therapy.[5,6] Although sexual problems induced by 5ARIs diminish after the second year of the therapy in the majority of cases, some persist during the treatment or even after treatment cessation.[7]

When the side effects of 5ARI persist even three months after cessation of the drug and are accompanied by other physical, mental and neurological adverse effects, this clinical entity is named post-finasteride syndrome (PFS).[8] Although, the prevalence of the PFS is not exactly determined, the number of men reporting these persistent sexual side effects to health professionals is increasing worldwide. The symptomatology of PFS is quite variable and the symptoms may range from minor to severe. In addition to the aforementioned sexual side effects, the PFS patients may report psychological issues such as emotional sensitivity, attention deficiency depression, panic attacks and anxiety leading to functional decline and even suicidal ideation. Other physical symptoms of PFS include muscle atrophy, dry and thin skin, chronic fatigue, tinnitus, gynecomastia, scrotal and penile shrinkage and the Peyronie's disease

Today, there is no known cure or any effective treatments of PFS; however, medical communities and societies are recently beginning to realize the scope and burden of this problem.[4] Until the actual pathophysiology of PFS is determined and effective therapies are discovered, we all have to think twice before prescribing a 5ARIs for our patients with either BPH and/or AGA. Meanwhile, professional organizations may provide educational materials for physicians in order to increase their awareness regarding the scope of these persistent catastrophic adverse effects of finasteride and dutasteride. Considering the thousands of sufferers who already have PFS, the scientific world immediately need to conduct more research to determine how to effectively treat this horrible symptom complex.

CONFLICTS OF INTEREST

The authors declare that they have no conflicts of interest.

ISSN 2572-4665 http://dx.doi.org/10.17140/UAOJ-1-e002

REFERENCES

1. Irwig MS, Kolukula S. Persistent sexual side effects of finasteride for male pattern hair loss. *J Sex Med.* 2011; 8(6): 1747-1753.

2. Traish AM, Hassani J, Guay AT, Zitzmann M, Hansen ML. Adverse side effects of 5 alpha-reductase inhibitors therapy: Persistent diminished libido and erectile dysfunction and depression in a subset of patients. *J Sex Med.* 2011; 8(3): 872-884. doi: 10.1111/j.1743-6109.2010.02157.x

3. Cassels A, Wright JM, Mintzes B, Jauca C. Direct-to-consumer advertising. Finasteride for male pattern hair loss. *Can Fam Physician.* 2001; 47: 1751-1755. Web site. http://www.cfp.ca/content/47/9/1751.long. Accessed September 10, 2016

4. Post-Finasteride Syndrome: Overview. Post-Finasteride Syndrome Foundation Somerset, New Jersey 2016. Web site. http://www.pfsfoundation.org/post-finasteride-syndrome-overview/. Accessed September 10, 2016

5. Stoner E. Three-year safety and efficacy data on the use of finasteride in the treatment of benign prostatic hyperplasia. *Urology*. 1994; 43(3): 284-294. doi: 10.1016/0090-4295(94)90068-X

6. I Motofei DR, Georgescu SR, Tampa M, et al. The post-finasteride syndrome after distinct doses/ affections. *J Invest Dermatol.* 2015; 135: S40. Web site. http://scholar.valpo.edu/psych_fac_pub/22/. Accessed September 10, 2016

7. Wessells H, Roy J, Bannow J, et al. Incidence and severity of sexual adverse experiences in finasteride and placebo-treated men with benign prostatic hyperplasia. *Urology*. 2003; 61(3): 579-584. doi: 10.1016/S0090-4295(02)02401-9

8. Ganzer CA, Jacobs AR, Iqbal F. Persistent sexual, emotional, and cognitive impairment post-finasteride: A survey of men reporting symptoms. *Am J Mens Health.* 2015; 9(3): 222-228. doi: 10.1177/1557988314538445

UROLOGY AND ANDROLOGY

Openventio PUBLISHERS

ISSN 2572-4665 Open Journal http://dx.doi.org/10.17140/UAOJ-1-101

Research

*Corresponding author
Bilal Chughtai, MD
Assistant Professor
Department of Urology
NewYork-Presbyterian/Weill Cornell
425 East 61st Street
New York, NY 10065, USA
Tel. (646)962-4811
Fax: (646)962-0140
E-mail: bic9008@med.cornell.edu

Volume 1 : Issue 1
Article Ref. #: 1000UAOJ1101

Article History
Received: July 23rd, 2015
Accepted: October 16th, 2015
Published: October 19th, 2015

Citation
Chughtai B, Laor L, Sarkisian A, et al. Multi institutional experience with the greenlight simulator. *Urol Androl Open J*. 2015; 1(1): 1-5. doi: 10.17140/UAOJ-1-101

Copyright
©2015 Chughtai B. This is an open access article distributed under the Creative Commons Attribution 4.0 International License (CC BY 4.0), which permits unrestricted use, distribution, and reproduction in any medium, provided the original work is properly cited.

Multi Institutional Experience with the GreenLight Simulator

Bilal Chughtai[1*], Leanna Laor[1], Alexander Sarkisian[1], Claire Dunphy[1], Abby J. Isaacs[2], Matthew Rutman[1], Art Sedrakyan[2] and Alexis Te[1]

[1]*Department of Urology, Weill Medical College of Cornell University, New York-Presbyterian Hospital, New York, NY, USA*

[2]*Department of Public Health, Weill Medical College of Cornell University, New York-Presbyterian Hospital, New York, NY, USA*

ABSTRACT

Introduction: The objective of this study was to evaluate the GreenLight Laser Sim™ for resident education in a multi institutional study using a structured curriculum.
Materials and Methods: Residents from two tertiary care hospitals participated in this study. The curriculum included four SIM modules and four SIM cases on the GreenLight Laser Sim™. Participants of various training levels were evaluated by grams of tissue vaporized in allotted time, average sweep speed, blood loss, and average laser-tissue distance throughout the study.
Results: 20 residents, PGY1-PGY6, completed 331 trials on the simulator. Increased number of trials on the simulator was associated with a statistically significant increase in vaporization efficiency and reduced laser distance. No significant difference was noted between training level or simulator trial number when examining blood loss.
Conclusions: This study demonstrates that use of the GreenLight Laser Sim™ is associated with improved vaporization efficiency. The simulator is a useful tool in resident education and instruction of important safety principles and procedural techniques and can help improve vaporization efficiency.

KEYWORDS: Minimally invasive surgery; Transurethral resection of the prostate; Greenlight simulator.

ABBREVIATIONS: TURP: Transurethral resection of the prostate; BPH: Benign Prostatic Hyperplasia; SD: Standard Deviation.

INTRODUCTION

Transurethral resection of the prostate (TURP) has been the gold standard in surgical interventions for Benign Prostatic Hyperplasia (BPH) and the benchmark for which other surgical therapies for BPH have been compared to for several decades. In recent years, minimally invasive techniques have been increasing in popularity. One of the most commonly used minimally invasive techniques is the use of GreenLight (AMS Research Corporation, Minnetonka, MN, USA)[1,2] in the surgical management of BPH.

Largely modelled from the field of aviation, the use of simulation has become an integral part of medical training for both learning technical skills and improving communication among teammates.[3,4] In resident education, appropriate use of simulators may provide residents with confidence performing a procedure in a controlled setting, which can improve outcomes and reduce variability on live patients. Simulation can shorten the learning curve and has been studied in the training of a wide range of urological procedures.[5-7]

The GreenLight simulator was developed through a University of Minnesota's Center for Research and Education in Simulation Technologies and American Medical Systems. Introduced in 2011, it reproduces the experience of performing a GreenLight PVP.[8-10] A study

Openventio PUBLISHERS
ISSN 2572-4665 http://dx.doi.org/10.17140/UAOJ-1-101

by Herlemann, et al. examined the simulator and demonstrated face, content and construct validity of the GreenLight Sim in a structured curriculum.[10] Our study aims to evaluate the GreenLight Sim at two teaching hospitals utilizing a structured curriculum developed for the purpose of resident education.

MATERIALS AND METHODS

This study utilized a structured curriculum to evaluate the GreenLight Laser Sim™ V2.0 (AMS Research Corporation, Minnetonka, MN, USA), in its ability to teach safety and efficiency principles to residents. The curriculum was offered to residents at two tertiary care hospitals. Resident training level ranged from Post Graduate Year 1 to Post Graduate Year 6. Residents in PGY 1 and 2 had zero experience with PVP, while residents in years PGY 3 and 4 had performed the PVP procedure less than 5 times. PGY 5 and 6 residents had the most experience with the laser, having performed greater than 20 PVP procedures.

Participants were provided a curriculum checklist to follow (Table 1), including anatomy identification, fiber sweep speed, fiber-to-tissue distance and bleeding vessel coagulation. In addition, four different anatomical gland types included30g normal gland, median lobe, prominent apex, and a 100 g gland with trilobar hypertrophy. Participants were given 2 minutes for each of the four required SIM training modules and 10 minutes lasing time for each of the four SIM cases.

Outcome measures included global scores, sweep speed, average laser distance, and ability to coagulate bleeding vessels were recorded using the scoring system integrated into the GreenLight Laser Sim™ software. Statistical analysis was performed with SAS v9.3 (SAS Institute Inc., Cary, NC, USA). This was done with linear mixed effects models which included resident training level and number of trials completed for each outcome. All models were adjusted for repeated measures across residents.

RESULTS

20 residents completed a total of 331 trials on the simulator. The study outcomes of sweep speed, blood loss, laser distance and grams vaporized were evaluated according to resident training level (Figure 1) and the number of trials completed (Figure 2).

Instructional Element	# Times to complete task	Objective
SIM Training Modules		
Module 1 - Anatomy Identification	1	Compete the exercise and obtain SIM score
Module 2 - Sweep Speed	1	Compete the exercise and obtain SIM score
Module 3 - Tissue Fiber Distance	1	Compete the exercise and obtain SIM score
Module 5 - Controlling Bleeders	1	Compete the exercise and obtain SIM score
SIM Cases		
SIM Case: 30 g Normal Gland	3	Take down median lobe and one lateral lobe
SIM Case - Median Lobe	3	Take down median lobe
SIM Case - Prominent Apex	3	Vaporize apical tissue safely, staying away from sphincter
SIM Case - 100 g Trilobar Hypertrophy	3	Create a working channel and take down median lobe

Table 1: Curriculum Structure. Participants were allowed 2 minutes to complete each of the four required SIM training modules and 10 minutes lasing time for each of the four SIM cases.

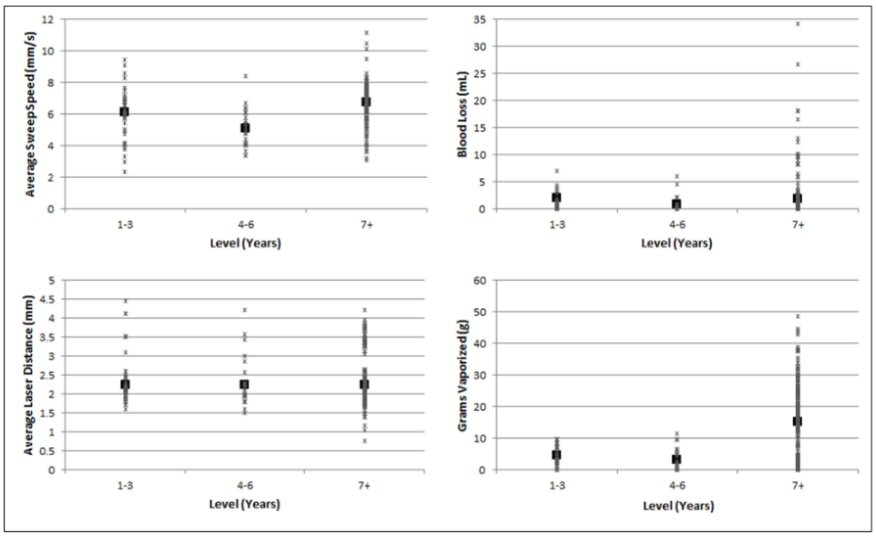

Figure 1: Simulator outcomes in each training level group with mean.

Openventio PUBLISHERS
ISSN 2572-4665 http://dx.doi.org/10.17140/UAOJ-1-101

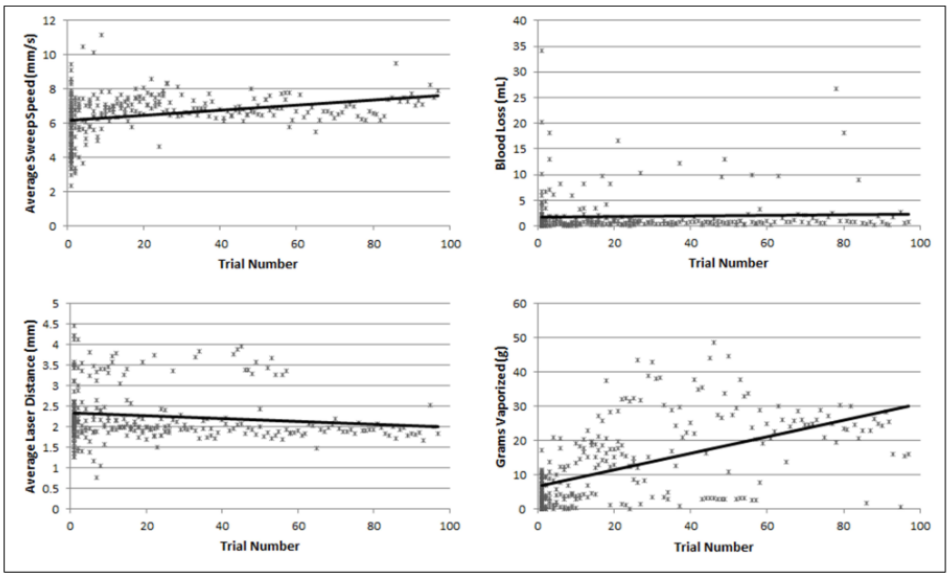

Figure 2: Simulator outcomes plotted against trial number with linear trend lines.

The average sweep speed across all participants was 6.51 mm/sec (Standard Deviation [SD]=1.28 mm/sec). A slight trend towards increased sweep speed was seen with both increased training level and increased number of trials, although these differences did not reach statistical significance in this study. The average blood loss was 1.84 mm/sec (SD=3.86) and this did not appear associated with either training level or number of trials completed. Average laser distance was 2.25 millimeters (SD=0.65 mm) and this did not vary significantly between the different levels of training or number of trials completed. A negative association did exist between laser to tissue distance trial number, estimate=-0.004(95% CI -0.007, -0.001). The average weight of tissue lasered during each of the simulated cases was 12.44 grams (SD=11.43 g).There was a significant increase in efficiency of vaporization with increased use of the simulator as evidenced by a greater amount of tissue vaporized per trial with increased trial number, estimate=0.191 (95% CI 0.144, 0.238). Although increased simulator use increased efficiency, resident training level was not associated with improved vaporization efficiency in this study. (Table 2)

DISCUSSION

Our results indicate that the use of the GreenLight simulator in a structured training program can lead to increase in vaporization efficiency. We did not observe significant differences in the other outcome measures tested, which is possibly a reflection of the relatively short learning curve for this technique. (Figure 2) A study by Woods, et al. suggested that 15-20 cases is sufficient for a user to become proficient, while Seki et al. demonstrated that there was essentially no learning curve for this procedure when performed by two physicians with no previous experience in the use of PVP, although they had received the appropriate training and had over 10 years of experience in performing TURP.[2,11] In terms of acquiring expert level proficiency, an additional study estimated that up to 120 cases may be needed to obtain expert level proficiency in the procedure.[12]

In line with our findings, Aydin, et al. performed a study that included 46 participants who were grouped by level of experience. Twenty five participants were considered novice, and had no operative or endoscopic experience. Fourteen were intermediate and seven had expert level experience. According to the authors, an average of 75 procedures was required to reach expertise level, and thus participants with experience of less than 75 procedures were considered intermediate. Their study findings were such that they determined knowledge and technical skills taught by the simulator are valid for learning PVP, and should be incorporated for training purposes.[13]

Although recommendations regarding training for GreenLight PVP have been published based on the experience and expertise of several investigators,[14,15] there is a paucity of data on the utility of the GreenLight Sim in resident education

	Outcome			
Measure	**Average Sweep Speed**	**Blood Loss**	**Average Laser Distance**	**Grams Vaporized**
Year 1-3	0.806(-0.288, 1.900)	0.335(-1.016, 1.685)	-0.201(-0.696, 0.293)	-2.261(-6.786, 2.264)
Year 4-6	-0.063(-1.274, 1.148)	-0.835(-1.016, 1.685)	-0.124(-0.679, 0.431)	-3.517(-8.895, 1.861)
Year 7+	ref.	ref.	ref.	ref.
# of Trials	-0.003(-0.003, -0.008)	0.00(-0.011, 0.027)	-0.004(-0.007, -0.001)*	0.191(0.144, 0.238)*

*p<0.05

Table 2: Model coefficients and 95% confidence intervals for simulator outcomes.

ISSN 2572-4665 http://dx.doi.org/10.17140/UAOJ-1-101

and skill acquisition. The International GreenLight User Group has recommended several key measures of proficiency in PVP including adequate background knowledge about the procedure, proper handling of the scope and probe, adequately addressing bleeding vessels, managing intra- and post-operative complications, and catheter management.[14] While several studies in the field of robotic surgery have evaluated the use of structured simulator curricula in the training of surgical residents[16,17] such studies are not as readily available in the literature for the teaching of PVP to residents.

This study demonstrated increased vaporization efficiency with repeated trials on the Green-Light simulator in a multi institutional cohort of 20 residents. Limitations include the retrospective nature of this study and small sample size limited by the number of residents that were available to participate in the study. Future investigations should include a larger cohort to further evaluate the GreenLight Sim as an educational tool in resident training. Additionally, future studies need to investigate the extent to which skills and efficiency developed on the simulator are carried over to the operating room.

CONCLUSIONS

The GreenLight Simulator was a useful tool to teach several key safety principles important to the PVP procedure. More clinical experience correlated with more efficient vaporization and shorter laser distance, but did not correlate with improved average sweep speed or a reduction in blood loss. The Green Light Simulator was a useful adjunct to teach important safety elements of the PVP procedure.

CONFLICTS OF INTEREST

The authors declare that they have no conflicts of interest.

REFERENCES

1. Kuntzman RS, Malek RS, Barrett DM, Bostwick DG. Potassium-titanyl-phosphate laser vaporization of the prostate: a comparative functional and pathologic study in canines. *Urology.* 1996; 48(4): 575-583. doi: 10.1016/S0090-4295(96)00247-6

2. Woods E. Laser ablation of the prostate: a safe effective treatment of obstructive benign prostatic disease. *Cuaj-Canadian Urological Association Journal.* 2010; 4(5): 344-346.

3. Palter VN, Grantcharov TP. Simulation in surgical education. *Canadian Medical Association Journal*. 2010; 182(11): 1191-1196.

4. Gallagher AG, Ritter EM, Champion H, et al. Virtual reality simulation for the operating room: proficiency-based training as a paradigm shift in surgical skills training. *Ann Surg.* 2005; 241(2): 364-372. doi: 10.1097/01.sla.0000151982.85062.80

5. Ahmed K, Jawad M, Abboudi M, et al. Effectiveness of procedural simulation in urology: a systematic review. *J Urol.* 2011; 186(1): 26-34. doi: 10.1016/j.juro.2011.02.2684

6. Brewin J, Ahmed K, Challacombe B. An update and review of simulation in urological training. *International Journal of Surgery.* 2014; 12(2): 103-108. doi: 10.1016/j.ijsu.2013.11.012

7. Khan R, Aydin A, Khan MS, Dasgupta P, Ahmed K. Simulation-based training for prostate surgery. *BJU Int.* 2014; 16(4): 665-674. doi: 10.1111/bju.12721

8. Shen Y, Konchada V, Zhang N, et al. Laser surgery simulation platform: toward full-procedure training and rehearsal for benign prostatic hyperplasia (BPH) therapy. *Stud Health Technol Inform.* 2011; 163: 574-580. doi: 10.3233/978-1-60750-706-2-574

9. Zhou X, Zhang N, Shen Y, Burke D, Konchada V, Sweet R. Phenomenological model wof laser-tissue interaction with application to Benign Prostatic Hyperplasia (BPH) simulation. *Stud Health Technol Inform*. 2011; 163: 749-755. doi: 10.3233/978-1-60750-706-2-749

10. Herlemann A, Strittmatter F, Buchner A, et al. Virtual reality systems in urologic surgery: an evaluation of the GreenLight simulator. *European Urology.* 2013; 64(4): 687-688. doi: 10.1016/j.eururo.2013.06.008

11. Seki N, Nomura H, Yamaguchi A, Naito S. Evaluation of the learning curve for photoselective vaporization of the prostate over the course of 74 cases. *Journal of Endourology.* 2008; 22(8): 1731-1735. doi: 10.1089/end.2007.0368

12. Misrai V, Faron M, Guillotreau J, et al. Assessment of the learning curves for photoselective vaporization of the prostate using GreenLight (TM) 180-Watt-XPS laser therapy: defining the intra-operative parameters within a prospective cohort. *World Journal of Urology.*2014; 32(2): 539-544. doi: 10.1007/s00345-013-1163-7

13. Aydin A, Muir GH, Graziano ME, et al. Validation of the greenlight simulator and development of a training curriculum for photoselective vaporisation of the prostate. *British Journal of Urology International.* 2014; 115(6): 994-1003.

14. Muir G, Sancha FG, Bachmann A, et al. Techniques and training with GreenLight HPS120-W laser therapy of the prostate: position paper. *European Urology Supplements.* 2008; 7(4): 370-377. doi: 10.1016/j.eursup.2008.01.012

15. Sancha FG, Bachmann A, Choi BB, Tabatabaei S, Muir GH. Photoselective vaporization of the prostate (GreenLight PV): lessons learnt after 3500 procedures. *Prostate Cancer Prostatic Dis*. 2007; 10(4): 316-322. doi: 10.1038/sj.pcan.4500989

16. Raza SJ, Froghi S, Chowriappa A, et al. Construct validation of the key components of fundamental skills of robotic surgery

ISSN 2572-4665 http://dx.doi.org/10.17140/UAOJ-1-101

(fsrs) curriculum-a multi-institution prospective study. *J Surg Educ*. 2014; 71(3): 316-324. doi: 10.1016/j.jsurg.2013.10.006

17. Stegemann AP, Ahmed K, Syed JR, et al. Fundamental skills of robotic surgery: a multi-institutional randomized controlled trial for validation of a simulation-based curriculum. *Urology*. 2013; 81(4): 767-774. doi: 10.1016/j.urology.2012.12.033

UROLOGY AND ANDROLOGY

Openventio PUBLISHERS

ISSN 2572-4665 Open Journal http://dx.doi.org/10.17140/UAOJ-1-102

Research

*Corresponding author
Shivam Priyadarshi, Mch-Urology
Professor
Department of Urology
S.M.S. Medical College & Hospital
C-80 Gole market, Jawahar Nagar
Jaipur-302004, Rajasthan, India
Tel. 91-141-2654631; 98280-15854
E-mail: spriyadarshi64@gmail.com

Volume 1 : Issue 1
Article Ref. #: 1000UAOJ1102

Article History
Received: November 16th, 2015
Accepted: December 8th, 2015
Published: December 10th, 2015

Citation
Priyadarshi S, Verma A. Dhat syndrome and its social impact. *Urol Androl Open J*. 2015; 1(1): 6-11. doi: 10.17140/UAOJ-1-102

Copyright
©2015 Priyadarshi S. This is an open access article distributed under the Creative Commons Attribution 4.0 International License (CC BY 4.0), which permits unrestricted use, distribution, and reproduction in any medium, provided the original work is properly cited.

Dhat Syndrome and its Social Impact

Shivam Priyadarshi[1*] and Amit Verma[2]

[1]*Professor, Department of Urology, S.M.S. Medical College & Hospital, Jaipur, Rajasthan, India*

[2]*Professor, Department of Urology, S.M.S. Medical college, Jaipur, India*

INTRODUCTION

Cultural beliefs prevalent in the society have a very severe impact on the mind and behavior of the person. Sexuality is a very important but under discussed domain in public as well as in our education system.[1,2] So there are many misbeliefs and misconceptions about sexuality prevalent in our society. Many cultures believe semen to be a very precious body fluid and its unnecessary loss to cause severe harm on the health of the person. Cultural myths in relation to semen loss can induce physical and psychological symptoms in a man which together as a syndrome termed as Dhat syndrome.[3] "Dhat" is derived from the word "dhatu". The word "Dhatu" is a Sanskrit word which means "Metal" or "Elixir".[3-5] There is description of seven "Dhatus" [Chyle (Rasa), Blood (Rakta), Flesh (Maans), Fat (Meda), Bone (Asthi), Marrow (Majja), Semen (Shukra)], out of which most important considered is "Shukra Dhatu (semen)".

Dhat syndrome is described in The Diagnostic and Statistical Manual (DSM) IV as a Culture Bound Syndrome (CBS).[6] There is an ongoing debate on nosological status of CBS.[7] Dhat syndrome has been found to be prevalent in different geographical regions of the world.[8] It has been described in literature from China, Europe, Americas, and Russia at different points of time in history.[9] Mention of semen as a "soul substance" could be found in the works of Galen and Aristotle who have explained the physical and psychological features associated with its loss.[10]

The assumption that these cultures bound syndromes affect only specific cultures have resulted in limiting global interest in understanding these conditions and their management. However, these conditions are of serious concern as they have severe detrimental effects on the life of its sufferers. So we in our study tried to find out the most predisposed group for this syndrome, its impact on their life, their surroundings and the whole society and what could be done to relieve them of their sufferings.

MATERIAL AND METHODOLOGY

The study was conducted in Urology Department of S M S Hospital, Jaipur, India. The study was approved by the ethical committee of the institution. The study included 110 patients who presented in the urology clinic with the primary complaint of involuntary discharge of semen. Informed consent was taken from all the patients before including them in the study. Patients were excluded from the study if they didn't appear for follow-up as advised. The patients were provided comfortable atmosphere and were taken in to confidence that their information will not be disclosed. The patients were enquired about their demographic profile (like age, marital status, educational status, occupation, socio-economic status, family details). They were specifically asked about their personal life like their sexual history, drug abuse, alcohol and smoking. They were enquired about their primary complaint of Dhat, timings of discharge, associated health problems or any sexual problem. They were asked about their beliefs regarding Dhat (questions asked are depicted in Table 1). To find the impact of their suffering of Dhat on their daily living, their health, their surroundings, their professional life and the society, they were asked few questions as listed in Table 2. The response was recorded as never, regular, sometimes.

Openventio PUBLISHERS
ISSN 2572-4665 http://dx.doi.org/10.17140/UAOJ-1-102

What is the substance you think is discharged in Dhat?
What do you think is responsible for this condition?
What do you think will be the consequences if you continue to have Dhat?

Table 1: Questions asked about their beliefs regarding Dhat.

During the past week, did they feel:
A vague feeling of fear?
Lack of energy?
Disturbed sleep?
Somatic symptoms like body ache, fainting, dizziness etc.?
No interest in work?
No interest in surroundings?
Easily becomes irritated?
They can't enjoy anything anymore?
Easily become emotional?
That everything is meaningless?
Unnecessarily feeling afraid?
Afraid of going to social gatherings?
Feel of inferiority complex?
Feel life is not worthwhile?
Think 'I wish I was dead"?

Table 2: Questions asked about impact of their suffering of Dhat on their daily living, their health, their surroundings, their professional life and the society.

Urine analysis was done in every patient. Patients were counseled, taught about their condition in detail, were asked to raise their doubts and sexual education was imparted to them. Patients were then called for follow-up after 1 week. Above questions (as in table 1) were again asked.

Data was collected and Statistical analyses were performed using the Statistical Package for the Social Science Version (SPSS). Descriptive analysis were analyzed in terms of mean and standard deviation for continuous variables. Frequency with percentage was used for nominal variables.

RESULTS

Assessment of Demographic Profile of Patients

The study included 110 male patients presenting with Dhat syndrome. The mean age of study sample was 23.53 years with an age range of 15-68 years. The most affected age group was of 18-25 years which constituted about 60% of patients, about 25 % were in the age range of 25-35 years, 10% were below 18 years while 5.5% patients were aged above 35 years. More than two-third (70%) of the patients were unmarried, the rest were either married (20%) or widowed/divorcee (10%). The condition had a high prevalence in educated population as well, and about 50% of patients were graduate or above. Majority of the patients were either unemployed or student (49.1 %). About half of patients had monthly family income of less than Indian Rupees 10,000 and 24.5% people had monthly income less than Indian Rupees 5000. The condition was prevalent in both urban and rural community with about two third patients belonging to rural areas. Dhat syndrome was more common in people who were living alone (54.5%) or in nuclear family (30%) as compared to joint family and in people who had no previous history of having sex (60%).

Demographic Profile

Age	<18(10%)	18-25(60%)	25-35(24.5%)	>35(5.5%)	
Educational status	Illiterate (22.7%)	Up to 10th (27.3%)	Up to graduate (45.5%)	Above graduate (4.5%)	
Occupation	Unemployed/ Student (49.1%)	Unskilled worker (20%)	Skilled worker (17.2%)	Clerical/ farmer (8.2%)	Professional (5.5%)
Monthly family income	<5000 (24.5%)	5000-10000 (50%)	10000-20000 (20%)	>20000 (5.5%)	
Marital status	Un-married (70%)	Married (20%)	Separated (10%)		
Previously ever had sex	No (60%)	Yes (40%)			
Type of family	Nuclear (30%)	Joint (15.5%)	Alone (54.5%)		
Residence	Rural (63.6%)	Urban (36.4%)			
Smoker	Yes (54.5%)	No (45.5%)			
Alcoholic	Regular (20%)	Occasional (45.5%)	Never (34.5%)		
Drug abuse	Yes (20%)	No (80%)			

Clinical Profile

The mean duration of symptoms at the time of presentation was 22 months, and nearly two-third of patients were passing Dhat every week while one-fourth of patients were passing Dhat at least once in a day. Most of the patients complained of passage of Dhat while urination More than two-third of patients have not consulted anyone while about 20% have consulted quacks or so called sexologists. When asked about associated sexual complaints, about 75% were worried about their habit of masturbation. About one third reported that their semen is thin and about 10% reported erectile dysfunction. Majority of patients reported generalized weakness, about two third patients complained of constipation and about 10% reported burning micturition.

Openventio PUBLISHERS
ISSN 2572-4665 http://dx.doi.org/10.17140/UAOJ-1-102

Clinical Profile

	n	%age
Duration of suffering		
<6 months	12	10.9
6 months-1year	23	20.9
>1 year	75	68.2
Frequency of passage of dhat		
Everyday	29	26.4
Every week	67	60.9
Once a while	14	12.7
When they have passage of Dhat*		
While passing urine	75	68.2
While straining for passing stools	10	9.1
During sleep	50	45.4
While sexual excitement	40	36.4
Anytime	25	22.7
What they have done till now for this		
Nothing	74	67.3
Consulted quacks	24	21.8
Consulted doctors	12	10.9
Any associated sexual complaint reported by patients*		
Erectile dysfunction	10	9.1
Premature ejaculation	5	4.5
Masturbation	75	68.2
Thin semen	35	31.8
Small penis	5	4.5
No other sex related symptoms	10	9.1
Any associated health problem reported by patient*		
Constipation	65	59.1
Asthenia	95	86.4
Insomnia	40	36.4
Body ache	45	40.9
Anxiety	60	54.5
Burning micturition	10	9.1
No refer to any other associated health problem	2	1.8

*A patient can have more than one response.

Urinanalysis

Urinanalysis of the patients did not show spermatozoa in any patient. Only about 5% patients showed pus cells, about 5% showed RBC and about 2% showed crystals. Urinanalysis of rest of the patient showed no abnormality.

Urinanalysis	n	%
spermatozoa	-	-
Pus cells	5	4.5
crystals	2	1.8
RBC	5	4.5
No abnormality	102	92.7

Belief of Patients

80% patients believed that they are losing semen in Dhat while 20% had no idea. About two third patients believed that they are passing Dhat because of some defect they have created by doing masturbation. Majority of patients thought that if they continue to have Dhat then they will get weak, while about 60% thought that they will be unable to have sex, about one fourth were worried that they will not be able to bear child.

What they think Dhat is?

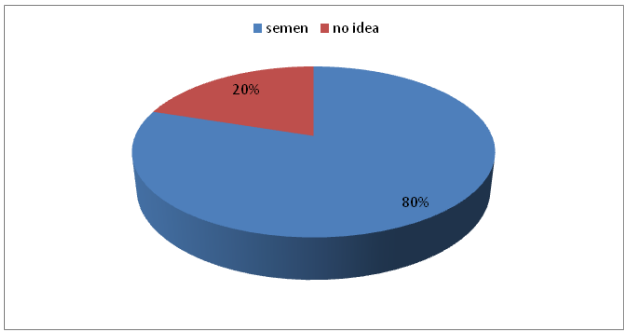

What they think is responsible for their suffering?

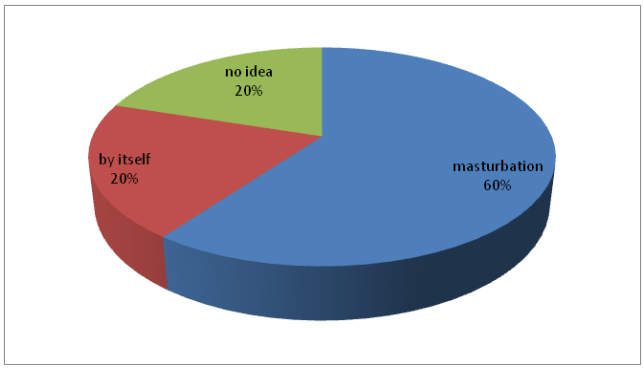

What will be the consequences?

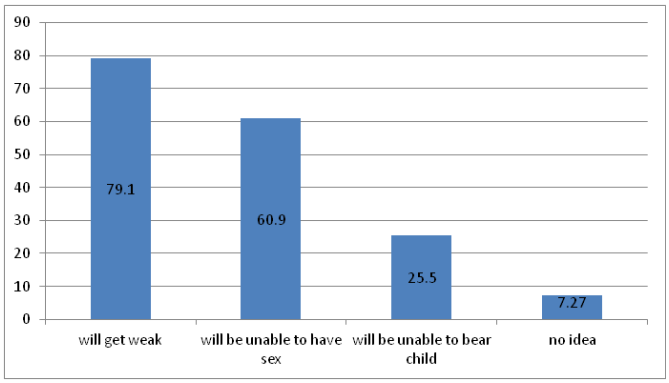

Impact on Society

It is clear from the response of patients to the questions asked (as shown in table 2), that Dhat syndrome had severe im-

ISSN 2572-4665 http://dx.doi.org/10.17140/UAOJ-1-102

pact on their daily living, their health, their surroundings, their professional life and the society. More than half of patients have regularly no interest in work and in their surroundings. About all the patents feel lack of energy and majority of patients also had disturbed sleep and complain of somatic symptoms like body ache, fainting, dizziness. About half of patients regularly remain irritable. Significant number of patients thought that everything is meaningless, feel life is not worthwhile and even wish to be dead.

Response of the patients to questions asked to find the impact of their suffering of Dhat on their daily living, their health, their family and surroundings, their professional life and the society:

During the past week, did they feel:	Never n (%)	Sometimes n(%)	Regular n (%)
A vague feeling of fear?	13(11.8)	64(58.2)	33(30)
Lack of energy?	0(0)	35(31.8)	75(68.2)
Disturbed sleep?	18(16.4)	54(49.1)	38(34.5)
Somatic symptoms like body ache, fainting, dizziness etc.	18(16.4)	43(39.1)	49(44.5)
No interest in work?	18(16.4)	33(30)	59(53.6)
No interest in surroundings	16(14.6)	37(33.6)	57(51.8)
Easily becomes irritated	21(19.1)	35(31.8)	54(49.1)
They can't enjoy anything anymore	23(20.9)	44(40)	43(39.1)
Easily become emotional	18(16.4)	38(34.5)	54(49.1)
That everything is meaningless	23(20.9)	52(47.3)	35(31.8)
Unnecessarily feeling afraid	28(25.5)	34(30.9)	48(43.6)
Afraid of going to social gatherings	38(34.5)	44(40)	28(25.5)
Feel of inferiority complex	23(20.9)	28(25.5)	59(53.6)
Feel life is not worthwhile	33(30)	46(41.8)	31(28.2)
Think ' I wish I was dead"	38(34.5)	49(44.6)	23(20.9)

At follow-up, after counseling and sex education, correction of misbeliefs and reassurance, response of the patients to similar questions:

During the past week, did they feel:	Never n(%)	Sometimes n(%)	Regular n(%)
A vague feeling of fear?	84(76.3)	19(17.3)	7(6.4)
Lack of energy?	78(70.9)	24(21.8)	8(7.3)
Disturbed sleep?	76(69.1)	27(24.5)	7(6.4)
Somatic symptoms like bodyache, fainting, dizziness etc.	80(72.7)	22(20)	8(7.3)
No interest in work?	84(76.3)	19(17.3)	7(6.4)
No interest in surroundings	82(74.5)	20(18.2)	8(7.3)
Easily becomes irritated	74(67.3)	26(23.6)	10(9.1)
They can't enjoy anything anymore	76(69.1)	26(23.6)	8(7.3)
Easily become emotional	79(71.8)	18(16.4)	13(11.8)
That everything is meaningless	82(74.5)	17(15.5)	11(10)
Unnecessarily feeling afraid	74(67.3)	23(20.9)	13(11.8)
Afraid of going to social gatherings	79(71.8)	21(19.1)	10(9.1)
Feel of inferiority complex	76(69.1)	23(20.9)	11(10)
Feel life is not worthwhile	89(80.9)	15(13.6)	6(5.5)
Think ' I wish I was dead"	92(83.6)	14(12.7)	4(3.7)

Impact of Counseling and Reassurance

By comparing the initial response of patients with the response after counseling and reassurance, it is clear that there was a dramatic positive response on the life of patients after counseling and reassurance only. Majority of patients though continued to have Dhat, were able to take interest in their work, their surroundings and in their own life. Majority of patients were able to have a healthy physical, mental and social wellbeing.

DISCUSSION

Dhat syndrome, although described as culture bound syndrome, has been found to be prevalent in different geographical regions of the world and has been found to be emerging in other countries as well. A significant number of patients with Dhat syndrome come to urologist consultation but there have been very limited reports that describe or analyze this syndrome in urological literature.[11] In the case of Dhat syndrome, the nature of underlying belief, i.e., 'semen is the most vital fluid and has to be conserved at any cost' is such that there is intense distress in the wake of continued loss of dhat.[12] Sumathipala, et al.[13] and Balhara, et al.[7] have reported that Dhat syndrome was not confined to Oriental countries infact it was prevalent in Europe, USA and Australia in the nineteenth century.

In our study we found that Dhat syndrome is mainly prevalent in particular strata of population: young male, living alone or in nuclear family, with low income, although more common in rural community but is also prevalent in urban areas, common in illiterate as well as well educated men. Few previous studies conducted by Chaddha, et al.,[14] Grover S, et al.[15] and Gautam M, et al.[16] reported that patients complaining of Dhat Syndrome are typically more likely to be young people, who are recently married or single; of average or low socio-economic status, coming from a rural area and belonging to a family with conservative attitudes towards sex while a study conducted by Verma R, et al.[17] reported more prevalence from urban area.

In our study, the mean duration of symptoms at the time of presentation was 22 months, and nearly two-third of patients were passing Dhat every week while one-fourth of patients were passing Dhat at least once in a day . In a recent study conducted in Spain by Menendez V, et al,[11] 25% of patients complained of daily sperm loss while in 37.5% it was weekly and patients complained of the syndrome lasting from 3 months up to 10 years. In a study conducted by De Silva P, et al.[18] complaint of duration of the semen loss lasts up to 20 years.

As reported by Grover S, et al.[19] and Rajkumar R, et al.[20] our study also showed that patient complaining of passage of Dhat also complains of various somatic symptoms most common being generalized weakness (86.4%) and constipation (59.1%) and also some irrelevant sex related problems like fear of thin semen or small penis.

ISSN 2572-4665 http://dx.doi.org/10.17140/UAOJ-1-102

Most of the patients believed that they are losing semen in Dhat and more than half of patients consider this to be a consequence of their habit of masturbation. Infact their self guilt of masturbation due to the misconceptions prevalent in the society lead to these false attributes.[21]

They are so much threatened by the misbeliefs in the society that they believe that they will get very weak and will not be able to do sex or bear child. Due to these fears their physical and mental health; and personal and social life get so much disturbed as clearly shown by our study that they lose all their interest in their work, their surroundings and have a feel of fear and tiredness.

In our study, in the urine analysis of the patients we did not found any spermatozoa as supported by studies conducted by Menendez V, et al.[11] and Avasthi A, et al.[22] Occasionally patient had oxaluria as supported by study conducted by Behere PB, et al.[23] while some studies[11,22] have reported no oxaluria. Various treatment strategies have been recommended with varying results in the literature. Avasthi A, et al.[24] had advised a standardized treatment protocol that mainly includes sex education, biofeedback and relaxation exercises. Bhatia, et al.[25] obtained the best result using tranquillizers, Menendez V, et al[11] have reported best results using multivitamin, Wigg NN, et al.[26] recommended proper counseling along with placebo, anti-anxiety and antidepressant drugs as required while Avasthi A, et al.[27] recommend sex education and relaxation exercises.

Our study clearly showed excellent results by the approach of emphatic listening, correction of misconceptions, sex education and reassurance. There is dramatic improvement in the lifestyle of the patients.

CONCLUSION

Dhat syndrome, a culture bound disorder is still prevalent in a large section of our society particularly rural, young, lower economic strata men. The mental conditioning of semen as a very precious fluid and its perceived loss has led to very significant impact on quality of life of such individuals. Reassurance, sex education, counseling supplemented by anti-anxiety/anti-depressants help majority of men to improve. The study also highlights the necessity of sex education, as evident by its (Dhat syndrome) presence in literate men as well, to be incorporated in the school curriculum to clear various myths and misconceptions still prevalent in some sections of the society.

CONFLICTS OF INTEREST

The authors declare that they have no conflicts of interest.

REFERENCES

1. Prakash O, Rao TS. Sexuality research in India: an update. *Indian J Psychiatry.* 2010; 52: S260S263. doi: 10.4103/0019-5545.69243

2. Avasthi A, Grover S, Kaur R, Prakash O, Kulhara P. Impact of nonorganic erectile dysfunction on spouses: a study from India. *J Sex Med.* 2010; 7: 36663674. doi: 10.1111/j.1743-6109.2009.01647.x

3. Prakash O. Lessons for postgraduate trainees about Dhat syndrome. *Indian J Psychiatry.* 2007; 49: 208210. doi: 10.4103/0019-5545.37324

4. Shushruta S. Vaidya Yadavji Tikamji Acharya. Bombay: Nirnaya Sagar Press; 1938.

5. Money J, Prakasam KS, Joshi VN. Semenconservation doctrine from ancient ayurvedic to modern sexology theory. *Am J Psychothe.* 1991; 45: 913.

6. Wig NN. Problems of mental health in India. *J Clin Social b Psychol (India).* 1960; 17: 4853.

7. Balhara Y. Culture-bound syndrome: has it found its right niche? *Indian J Psychol Med.* 2011; 33: 210215. doi: 10.4103/0253-7176.92055

8. Sumathipala A, Siribaddana SH, Bhugra D. Culture-bound syndromes: the story of dhat syndrome. *Br J Psychiatry.* 2004; 184: 200209. doi: 10.1192/bjp.184.3.200

9. Mumford DB. The 'Dhat syndrome': a culturally determined symptom of depression? Acta *Psychiatr Scand.* 1996; 94: 163167. doi: 10.1111/j.1600-0447.1996.tb09842.x

10. Jadhav S. Dhat syndrome: a reevaluation. *Psychiatry.* 2004; 3: 1416.

11. Menendez V, Fernández-Suárez A, Placer J, García-Linares M, Tarragon S, Liso E. Dhat syndrome, an emergent condition within urology in Spain. *World J Urol.* 2013; 31: 941-945. doi: 10.1007/s00345-012-0911-4

12. Prakash S, Sharan P, Sood M. A study on phenomenology of dhat syndrome in men, New Delhi (Thesis submitted to the faculty of All India Institute of Medical Sciences), 2012.

13. Sumathipala A, Siribaddana SH, Bhugra D. Culture-bound syndromes: the story of dhat syndrome. *Br J Psychiatry.* 2004; 184: 200-209. doi: 10.1192/bjp.184.3.200

14. Chadha C, Ahuja N. Dhat syndrome. a sex neurosis of the Indian subcontinent. *Br J Psychiatry.* 1990; 156: 577-579.

15. Grover S, Avasthi A, Aneja J, et al. Comprehensive questionnaire for assessment of Dhat syndrome: development and use in patient population. *J Sex Med.* 2014; 11: 2485-2495. doi: 10.1111/jsm.12241

ISSN 2572-4665 http://dx.doi.org/10.17140/UAOJ-1-102

16. Gautam M, Singh R, Weiss H, et al. Socio-cultural, psychosexual and biomedical factors associated with genital symptoms experienced by men in rural India. *Tropical Medicine and International Health*. 2008; 13(3): 384-395. doi: 10.1111/j.1365-3156.2008.02013.x

17. Verma R. A descriptive analysis of patients presenting to psychosexual clinic at a tertiary care center. *Indian Journal of Psychological Medicine.* 2013; 35(3): 241-247. doi: 10.4103/0253-7176.119473

18. De Silva P, Dissanayake SA. The loss of semen syndrome in Sri Lanka: a clinical study. *Sex Marital Ther.* 1989; 4: 195-204. doi: 10.1080/02674658908408337

19. Grover S, et al. Phenomenology and beliefs of patients with Dhat syndrome: a nationwide multicentric study. *International Journal of Social Psychiatry.* 2015. doi: 10.1177/0020764015591857

20. Rajkumar R. Dhat syndrome: evidence for a depressive spectrum subtype. *Asian Journal of Psychiatry*. 2014; 9: 57-60. doi: 10.1016/j.ajp.2014.01.007

21. El Hamad I, Scarcella C, Pezzoli MC, Bergamaschi V, Castelli F. Forty meals for a drop of blood. *J Travel Med.* 2009; 16(1): 64-65. doi: 10.1111/j.1708-8305.2008.00264.x

22. Avasthi A, Nehra R. Sexual disorders: a review of Indian Research. In: Murthy RS, ed. Mental health in India (1995-2000). People's action for mental health, Bangalore, 2001: 42-53

23. Behere PB, Natraj GS. Dhat syndrome: the phenomenology of a culture-bound sex neurosis of the orient. *Indian J Psychiatry*. 1984; 26: 76-78.

24. Avasthi A, Gupta N. Standardised management of single males with sexual disorders. Marital and Psychosexual Clinic Department of Psychiatry, PGIMER, Chandigarh, 2000.

25. Bhatia MS, Malik SC. Dhat syndrome-a useful diagnostic entity in Indian culture. *Br J Psychiatry*. 1991; 159: 691-695. doi: 10.1192/bjp.159.5.691

26. Wig NN. Dhat Syndrome. In: Brahmbhatt R, ed. Therapy of common sexual problems-A hand book. Family Planning Association of India, Mumbai, 1998.

27. Avasthi A, Jhirwal OP. The concept and epidemiology of Dhat syndrome. *J Pak Psychiatr Soc.* 2005; 2: 6-8.

UROLOGY AND ANDROLOGY

Openventio PUBLISHERS

ISSN 2572-4665 Open Journal http://dx.doi.org/10.17140/UAOJ-1-103

Case Report

*Corresponding author
Chien-Chih Wu, PhD
Department of Urology
School of Medicine
Taipei Medical University
Taipei, Taiwan
Tel. 0970405215
E-mail: ccwu@h.tmu.edu.tw

Volume 1 : Issue 1
Article Ref. #: 1000UAOJ1103

Article History
Received: May 6th, 2016
Accepted: May 26th, 2016
Published: May 26th, 2016

Citation
Chen W-C, Lin Y-H, Yeh S-D, Wu C-C. Testicular adult type granulosa cell tumor: a very rare case report and review of literature. *Urol Androl Open J*. 2016; 1(1): 12-14. doi: 10.17140/UAOJ-1-103

Copyright
©2016 Wu C-C. This is an open access article distributed under the Creative Commons Attribution 4.0 International License (CC BY 4.0), which permits unrestricted use, distribution, and reproduction in any medium, provided the original work is properly cited.

Testicular Adult Type Granulosa Cell Tumor: A Very Rare Case Report and Review of Literature

Wei-Chieh Chen, PhD[1]; Yun-Ho Lin, PhD[2,3]; Shauh-Der Yeh, PhD[1]; Chien-Chih Wu, PhD[1,4*]

[1]*Department of Urology, Taipei Medical University Hospital, Taipei, Taiwan*
[2]*Department of Dentistry, Taipei Medical University Hospital, Taipei, Taiwan*
[3]*School of Dentistry, College of Oral Medicine, Taipei Medical University Hospital, Taipei, Taiwan*
[4]*Department of Urology, School of Medicine, Taipei Medical University, Taipei, Taiwan*

ABSTRACT

Granulosa Cell Tumors (GrCT) are rare sex cord-stromal neoplasms of the gonads and can be classified into adult and juvenile types. GrCT arise more commonly from the ovary than the testis; and juvenile type Granulosa Cell Tumors (jGrCT) are more prevalent among male than female. A review of the literature shows less than 50 reported cases of adult Granulosa Cell Tumor (aGrCT) and it is still an extremely rare type of testis tumors. We report an elderly male diagnosed of aGrCT in the left testis. Radical orchiectomy was performed and no further treatment. Pathology report confirmed GrCT. Immunoprofile of the tumor was vimentin (+), inhibin-alpha (+), Bcl-2 (+), calretinin (-), CLA (-), S-100 (-) and CD99 (-).

KEYWORDS: Testis tumor; Radical orchiectomy; Adult type granulosa cell tumor.

INTRODUCTION

Granulosa cell tumors belonged to the sex cord-stromal tumors of the gonads and granulosa cell tumors commonly arose from ovaries. GrCT are rare and can be classified into adult and juvenile types. Juvenile type of GrCT mostly concerned infants and followed a benign course.[1] However, adult type GrCT may be potentially malignant and more aggressive progression. Less than 50 cases of adult granulosa cell tumor (aGrCT) have been reported.[2,3] In this paper, we presented a case of an elderly male diagnosed of aGrCT.

CASE REPORT

An 82-year-old male visited our hospital due to enlarging left testis for 3 months. He denied scrotal pain/tenderness/heaviness, abnormal urethral discharge or fever episode within the past 3 months. Physical examination showed prominent enlargement, firm and hardness of left testis. No inguinal lymphadenopathy was palpable. Sonography revealed diffuse heterogeneous density of left testis. LDH, AFP and B-HCG were all within the normal range. Abdominal to pelvic computer tomography scan (CT) showed space-occupying lesion in left testis with surrounding fluid accumulation (Figure 1) but no evidence of lymph node enlargement or distal metastasis. He denied any family history of testis cancer. There was also no gynecomastia symptoms or signs. Under the impression of testicular cancer, he received radical orchiectomy on September 13, 2013. The final stage of testis cancer is pT1N0M0. The operation went smooth and he was discharged the following day. His recovery was uneventful and no recurrence signs/symptoms were noted in subsequent follow-up.

Openventio PUBLISHERS
ISSN 2572-4665 http://dx.doi.org/10.17140/UAOJ-1-103

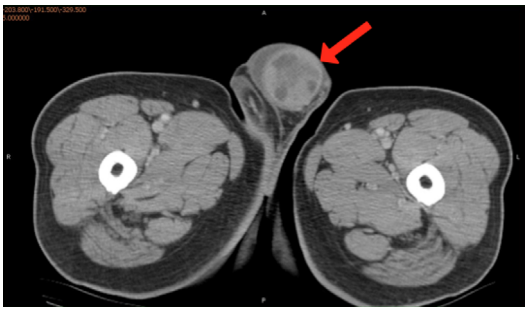

Figure 1: Pelvic CT. Space-occupying lesion in the left testis with surrounding fluid accumulation (red arrow).

PATHOLOGIC FINDINGS

Macroscopically, the testicle measured 7.0×4.7×4.0 cm. The spermatic cord measured 12 cm in length and 1.4 cm in diameter. Tumor was largely replaced by tumor lesion. The tumor is encapsulated and yellowish and homogenous in appearance, measuring in 4.5×3.5×0.9 in size (Figure 2). Some microcysts but not hemorrhagic or necrotic changes are seen on cut surface. The spermatic cord is unremarkable. The surgical margin is free from the tumor.

Figure 2: Gross cut surface. The tumor occupied the seminiferous tubules and focally extended into the rete testis tubules.

Microscopically, the tumor lesion located in the right seminiferous tubules and separated by fibrous tissue of tunica albuginea (Figure 3). It shows a solid tumor composed of compacted cells with uniform nuclei common with irregular nuclear membrane, nuclear groove, ample amphophilic cytoplasm and indistinctive border (Figure 4). Some tumor cells grew in sheet-like, cell cord, trabecular and follicular patterns. Some amorphous substance seems like the Call-Exner bodies (Figure 4) and variable thickness of the fibrous septae are also seen. No tumor necrosis or hemorrhagic change is found. The mitotic figure is variable in areas sometimes up to 7/10 HPF. The tumor is mainly located at the seminiferous tubules and focally extended into the rete testis tubules. The epididymis and the vas deferens are not tumor involved but compression and atrophic change is noted. The spermatic cord is unremarkable. The surgical margin of spermatic cord and the tunica albuginea are also unremarkable.

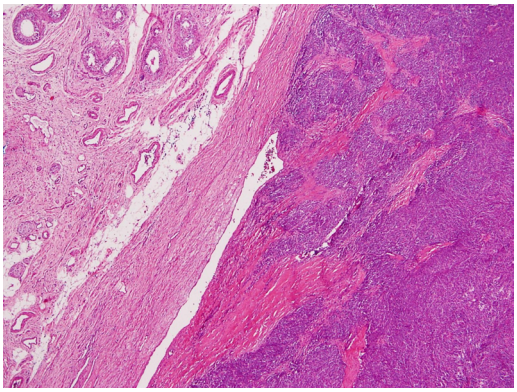

Figure 3: Tumor lesion X4. The tumor lesion located in the right seminiferous tubules and separated by fibrous tissue of tunica albuginea.

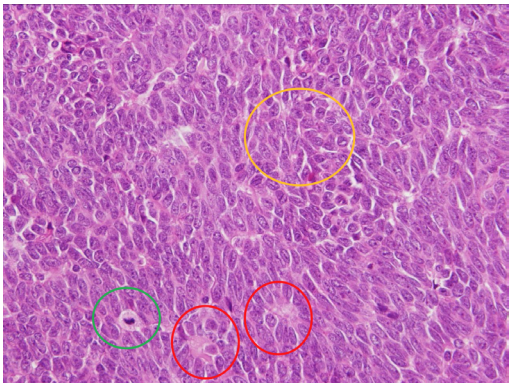

Figure 4: Tumor lesion X40. The uniform spindle to ovoid tumor cells with mildly pleomorphic nuclei sometimes with nuclear grooves (yellow circle), one or two nucleoli, present mitotic figures (green circle) and Call-Exner bodies (red circle) between the tumor cells.

The immunohistochemical stain of the neoplastic cells show positive for valentine (Figure 5), inhibin-alpha (Figure 6), and Bcl-2, focal positive for CD56 and negative for CK, calretinin, CLA, S-100, CD99, chromogranin, synaptophysin and Smooth Muscle Actin. A lesion of adult type granulosa cell tumor is considered. The tumor size is less than 7 cm, no hemorrhage and necrosis, but the mitotic figure is up to 7 /hpf (than 4 /hpf), so increase in risk potential for malignancy is noted.

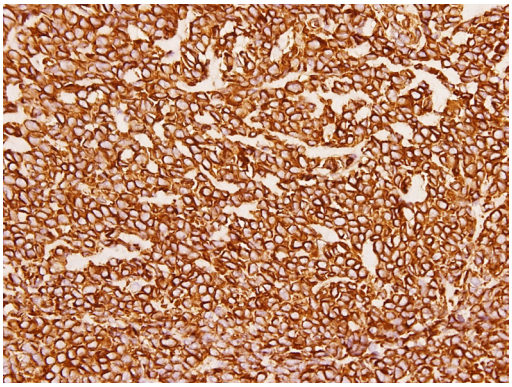

Figure 5: X40 immunohistochemical stain of the tumor showed positive for Vimentin.

ISSN 2572-4665 http://dx.doi.org/10.17140/UAOJ-1-103

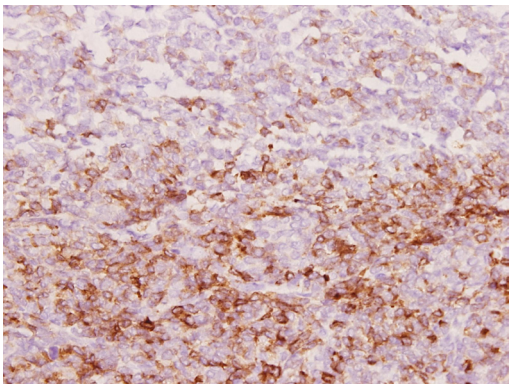

Figure 6: X20 immunohistochemical stain of the tumor showed positive for inhibin-α.

DISCUSSION

aGrCT is the minority group of reported GrCT cases as described by Miliaras et al[1]. aGrCT patients usually present with slow growth, painless scrotal swelling or mass. The average time of enlargement was 5.4 years. In particular, about 20% of male cases would present gynecomastia.[4] The prevalence age ranges from 16 to 77 years and is often above 50 years old. It is hard to make a diagnosis simply from the outer appearance and laboratory workup. The diagnosis would depend on histology and immunohistochemistry. According to Miliaras et al[1] aGrCT may have a more aggressive course and it can cause distal metastasis even after many years. However, there are no well-established concept about poor prognosis of aGrCT because of its rarity. Hanson and Ambaye have suggested that tumor size larger than 5 cm is a feature associated with malignancy in the testes.[5] Jimenez-Quintero et al considered size >7 cm, vascular or lymphatic invasion, and hemorrhage or necrosis somewhat predictive of spread.[6]

Thus, follow-up for patients receiving radical orchiectomy should be extended. As far as we know, the most common distal metastasis site of testicular germ cell tumor is the retroperitoneal lymph node. Retroperitoneal lymph node dissection (RPLND) is also a treatment option for patients with lymph node metastasis in testicular germ cell tumor. Although the therapeutic role of RPLND is unclear, it is still an option after radical orchiectomy in aGrCT patients with malignant features, as described by Ashraf et al[5] Except surgical management, Jimenez-Quintero et al[6] suggested that etoposide based chemotherapy with adjuvant radiotherapy may be a curative option for metastatic disease. To date, in the absence of guidelines regarding aGrCT, it is difficult for urologists to implement a follow-up program.

In conclusion, this patient is relative old age (in the past literature, the oldest person is 83 year-old) and short duration of clinical signs. Because of older person may lose the ability of self-care and daily activity, many patients was found of metastatic disease while diagnosed. Fortunately, in our case, he received surgical treatment within 3 months and no metastasis lesions was found *via* abdominal CT. There were also no suggestive poor prognostic factors like larger tumor size, tumor necrosis or hemorrhage. After 2 years follow-up, there was no signs of recurrence. Long-term follow-up is recommended, since recurrence of the disease may appear late in the clinical course.

CONFLICTS OF INTEREST

The authors have no conflicts of interest to declare.

CONSENT

Authors obtain written informed consent from the patient for submission of this manuscript for publication.

REFERENCE

1. Miliaras D, Anagnostou E, Moysides I. Adult type granulosa cell tumor: a very rare case of sex-cord tumor of the testis with review of the literature. *Case Rep Pathol*. 2013; 932086: 1-4. doi: 10.1155/2013/932086

2. Hanson JA, Ambaye AB. Adult testicular granulosa cell tumor: a review of the literature for clinicopathologic predictors of malignancy. *Arch Pathol Lab Med*. 2011; 135(1): 143-146. doi: 10.1043/2009-0512-RSR.1

3. Song Z, Vaughn DJ, Bing Z. Adult type granulosa cell tumor in adult testis: report of a case and review of the literature. *Rare Tumors*. 2011; 3(4): e37. doi: 10.4081/rt.2011.e37

4. Young RH. Sex cord-stromal tumors of the ovary and testis: their similarities and differences with consideration of selected problems. *Mod Pathol.* 2005; 18: S81-S98. doi: 10.1038/modpathol.3800311

5. Mosharafa AA, Foster RS, Bihrle R, et al. Does retroperitoneal lymph node dissection have a curative role for patients with sex cord – stromal testicular tumors?" *Cancer*. 2003; 98(4): 753-757. doi: 10.1002/cncr.11573

6. Jimenez-Quintero LP, Ro JY, Zavala-Pompa A, et al. Granulosa cell tumor of the adult testis: a clinicopathologic study of seven cases and a review of the literature. *Hum Pathol*. 1993; 24(10): 1120-1126. doi: 10.1016/0046-8177(93)90193-K

UROLOGY AND ANDROLOGY

Openventio PUBLISHERS

ISSN 2572-4665 Open Journal http://dx.doi.org/10.17140/UAOJ-1-104

Case Report

*Corresponding author
Marta Molina Anguita
Resident Medical Intern (MIR)
Department of Familiar and Community Medicine
General Hospital
Ciudad Real, Spain
E-mail: marta.mma88@gmail.com

Volume 1 : Issue 1
Article Ref. #: 1000UAOJ1104

Article History
Received: May 30th, 2016
Accepted: September 9th, 2016
Published: September 12th, 2016

Citation
Anguita MA, Fernández LC. Bilateral renal angiomyolipomas giants. *Urol Androl Open J*. 2016; 1(1): 15-17. doi: 10.17140/UAOJ-1-104

Copyright
©2016 Anguita MA. This is an open access article distributed under the Creative Commons Attribution 4.0 International License (CC BY 4.0), which permits unrestricted use, distribution, and reproduction in any medium, provided the original work is properly cited.

Bilateral Renal Angiomyolipomas Giants

Marta Molina Anguita[1*]; Luis Calahorra Fernández[2]

[1]Resident Medical Intern (MIR), Department of Familiar and Community Medicine, General Hospital, Ciudad Real, Spain

[2]Director, Service of Urology, General Hospital, Ciudad Real, Spain

ABSTRACT

Renal angiomyolipoma is a rare benign mesenchymal neoplasm and is characterized by the presence of thin dysmorphic vessels, smooth muscle and adipose tissue. The incidence of renal angiomyolipoma is 0.1-0.3% and it can be presented as an isolated pathology or be associated with other entities, such as Tuberous Sclerosis (TS) or Bourneville's disease, and Von Recklinghausen disease (VRD) or neurofibromatosis. We report a case of a female patient aged 22 with kidney angiolipomas giant associated with tuberous sclerosis, syndrome characterized by the formation of hamartomas and tumors in different organs of the body.

INTRODUCTION

The angiomyolipoma (AML) is a benign tumor of mesenchymal origin, compound by mature adipose tissue, aberrant blood vessels and smooth muscle, with a prevalence of approximately 1-3% of all renal masses. With the advance in diagnostics, an increase in AML has been observed.

Approximately 80% are sporadic and associated with tuberous sclerosis syndrome (TSC) 2 gene mutation, while up to 20% are associated with TSC which are related to the TSC 1 gene and sporadically with lymphangioleiomyomatosis (LAM).[1,2]

Although generally it is considered as a benign neoplasm, they have been described as an extension rare cases renal vein and inferior vena cava, plus regional infiltration ganglia, and even colon.

CLINICAL CASE

A 22-year-old female patient who was presented to the hospital emergency for pain abdominal diffuse. As medical history revealed that the patient was followed up in nephrology by chronic kidney disease (CKD) stage I, caused through bilateral renal angiomyolipoma in disease tuberous sclerosis, affecting skin (angiofibroma), liver (hamartomas), brain (hypointense subependymal nodules with calcifications) and kidney, they were controlled by the urologist and neurologist, and depression treatment. No hypertensive, diabetic or dyslipidemia.

She described hours of evolution diffuse abdominal pain without apparent cause, no hematuria or urinary symptoms. No digestive disorders was observed.

On physical examination it revealed supraventricular tachycardia and soft abdomen with tenderness without location, slight signs of peritoneal irritation and palpation of cysts. Right renal fist percussion was positive.

After performing laboratory analysis, hemoglobin (Hb) was found to be 7.8 g/dl which indicated urgent blood transfusion.

Openventio PUBLISHERS
ISSN 2572-4665 http://dx.doi.org/10.17140/UAOJ-1-104

Abdominopelvic CT

Patient with tuberous sclerosis and severe bilateral nephromegaly (>4 cm) will occupy more spec in the abdominal cavity leading to bilateral renal hamartomatous. A level mesograstrio-empty right can be see none pseudo-capsular formation of approximately 10 cm major axis sonographically which corresponds to a clot. Inside it can be seen a right renal artery branch of aneurysmal size (2 cm). The vascularization of both kidneys is greatly increased (renal vein right 2 cm gauge) (Figures 1 and 2). Free fluid between intestinal loops and retroperitoneal due to bleeding from the right renal vasculature. Homogeneous splenomegaly about 15 cm major axis (Figure 3). With multiple spinal bones window blastic lesions are seen features of Bourneville disease.

The patient was evaluated by the urology department and underwent emergency surgery along with the vascular radiology with renal embolization *via* femoral Seldinger technique and percutaneously without complications (Figure 4).

She spent 4 years in treatment with low-dose sirolimus to try to decreasing size with good response angiomyolipoma clinic but from about 7 months ago she was accepted to start treatment everolimus 5 mg every 24 hours for inhibiting proliferation and the clonal expansion of antigen-activated T-cells (Figure 5). At present the patient is asymptomatic with impaired renal function but without worsening in recent reviews and she is awaiting further revisions to ensure effectiveness with decreasing size of angiomyolipoma.

DISCUSSION

Angiomyolipomas renal tumors are uncommon, from the point of view histological consists of mesenchymal benign tissue, classified as hamartomas and variable portions composed of mature adipose tissue, fibers smooth muscle and blood vessels with irregular thickness devoid of elastic fibers.

In the last reviews one could have described also a percentage of evolution to malice of 34% to 65%, because of it of the importance of the follow-up.

The presentation of sporadic angiomyolipoma often is observed in women, with a 2:1 ratio (woman:men). The age of onset is 30 years, and most chances are unnoticed.

Approximately 20% to 30% of angiomyolipoma occur in patients with tuberous sclerosis and of these, up to 80% are bilateral.

Some authors postulate that renal angiomyolipoma, during pregnancy, may increase in size and increases the risk of spontaneous bleeding or retroperitoneal Wunderlich syndrome due to hormonal influence of this state.[3]

Diagnostic methods include ultrasound, computed tomography (CT), magnetic resonance imaging (MRI), which has been a marked increase in the incidental diagnosis renal masses.

As discussed earlier, the association of renal angiomyo-

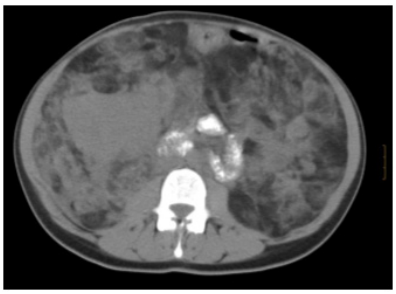

Figure 1: TAC Abdominopelvic: free fluid between intestinal loops and retroperitoneal by bleeding from the right angiomyolipomas renal.

Figure 2: Increase of the abdominal perimeter.

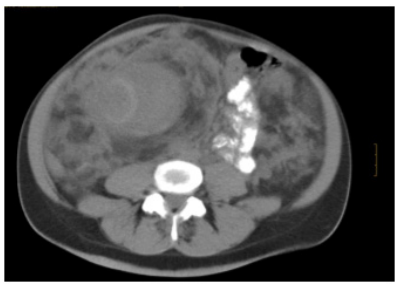

Figure 3: TAC Abdominopelvic: free fluid between intestinal loops and retroperitoneal by bleeding from the right angiomyolipomas renal.

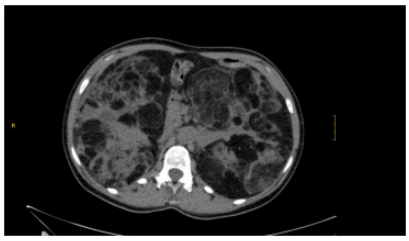

Figure 4: Renal embolization.

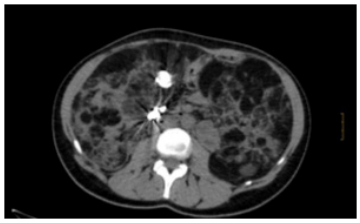

Figure 5: TAC Abdominopelvic of control after the surgical and pharmacological treatment.

ISSN 2572-4665 http://dx.doi.org/10.17140/UAOJ-1-104

lipoma is strongly associated with tuberous sclerosis, which is an autosomal dominant disease, with incomplete penetrance, so that approximately 50% of patients with this disease develop multiple hamartomas with involvement in brain, skin, retina, heart, lung and kidney.[4]

Tuberous sclerosis was recognized mainly by Friedrich von Daniel Recklinhausen in 1862, but the term was coined in 1880 Bourneville, so also it called Bourneville disease. Vougt described the classic triad of epilepsy, mental retardation and facial angiofibroma, but it just does occur 29% of cases, and 6% of patients with tuberous sclerosis cannot provide any of these findings.

Tumors larger than 4 cm associated with tuberous sclerosis are more susceptible to be symptomatic. Pain, hematuria and retroperitoneal bleeding are the most common manifestations, and if to the size the pregnancy adds, it becomes a diagnostic and therapeutic challenge.

Health care is still controversial in these patients. Oesterling and colleagues proposed as follow-up of the asymptomatic major tumors of 4 cm to realize echo or tomography every six months and in the minors of 4 cm of annual form. In symptomatic or bilateral tumors will be realized selective remobilization or conservative renal surgery (partial orlumpectomy).

Radical nephrectomy is carried out in case of uncontrolled bleeding or hemodynamic instability in large tumors, central location or coexistent carcinoma.[5] Other treatment options include cryotherapy or tumor ablation heat either ultrasonic or radio frequency. Rapamycin is a derivative of the bacterium Streptomyces higruscopicus antibiotic, also known as sirolimus, important immunosuppressant used in organ transplants has shown benefit in years of study as well as the latest introduction to the treatment of everolimus, a drug from the same therapeutic group but a pharmacokinetic profile and greater oral bioavailability than sirolimus.

CONCLUSION

Renal angiomyolipoma is a disease of low prevalence, mostly incidental diagnosis, without requiring intervention more than I tracked by the urologist. However, when faced with patients with large tumor and/or multiple masses, coupled with clinical manifestations, there will be thinking among others, association with Lymphangioleiomyomatosis pulmonary and/or tuberous sclerosis, entities that constitute a challenge from diagnosis to treatment by a multidisciplinary group, in an attempt to improve the quality of life of affected.

The managing focuses on the rapid diagnosis and the most effective treatment. The only management with periodic reviews is possible if the patient is stable or if it is the availability of embolization before surgery.

CONFLICTS OF INTEREST

The authors declare that they have no conflicts of interest.

CONSENT

The authors obtained written informed consent from the patient for submission of this manuscript for publication.

REFERENCES

1. Vega-Castro R, García-Vasquez RA, Arriaga-Aguilar J, et al. Angiomiolipoma renal múltiple bilateral asociado a esclerosis tuberosa [In Spanish]. Reporte de caso y revisión de la literatura. *Rev Mex Urol.* 2014; 74: 364-367. Web site. http://www.imbiomed.com.mx/1/1/articulos.php?method=showDetail&id_articulo=104019&id_seccion=40&id_ejemplar=10104&id_revista=8. Accessed May 29, 2016

2. Rodríguez WRR, Valbuena JEP, Orozco M. Angiomiolipoma renal gigante y linfangioleiomiomatosis pulmonar esporádica no filiada. A propósito de un caso Levi [In Spanish]. *Urología Colombiana.* 2014; 23: 227-232. doi: 10.1016/S0120-789X(14)50062-7

3. López-Álvarez A, Aragón-Tovar AR, López-Bernal C. Angiomiolipoma bilateral, esclerosistuberosa y embarazo [In Spanish]. *Rev Mex Urol*. 2012; 72: 136-140. Web site. http://new.medigraphic.com/cgi-bin/resumen.cgi?IDARTICULO=35527. Accessed May 29, 2016

4. Macaya A, Torra R. Recomendaciones para el manejo multidisciplinar del complejo esclerosis tuberosa [In Spanish]. *Medicina Clínica.* 2016. doi: 10.1016/j.medcli.2016.04.004

5. Bestard Vallejo JE, Trilla Herrera E, Celma Domenech A, Pérez Lafuente M, de Torres Ramírez I, Morote Robles J. Servicio de Urología, Angio-Radiología y Anatomía Patológica del Hospital General Universitario Valld'Hebron. UAB. Barcelona. Angiomiolipomas renales: Presentación, tratamiento y resultado de 20 casos [In Spanish]. *Actas Urol Esp.* 2008; 32(3): 307-315. doi: 10.1016/S0210-4806(08)73835-X

UROLOGY AND ANDROLOGY

Openventio PUBLISHERS

ISSN 2572-4665 Open Journal http://dx.doi.org/10.17140/UAOJ-1-105

Case Report

*Corresponding author
Somuah Tenkorang, MD
Department of Urology
Hassan II Teaching Hospital
Fez, Morocco
E-mail: snrsomuahtenkorang@gmail.com

Volume 1 : Issue 1
Article Ref. #: 1000UAOJ1105

Article History
Received: February 10th, 2017
Accepted: March 20th, 2017
Published: March 21st, 2017

Citation
Tenkorang S, Omana J-P, Bega BS, et al. Renocolic fistula secondary to tuberculosis: A case report. *Urol Androl Open J*. 2017; 1(1): 18-21. doi: 10.17140/UAOJ-1-105

Copyright
©2017 Tenkorang S. This is an open access article distributed under the Creative Commons Attribution 4.0 International License (CC BY 4.0), which permits unrestricted use, distribution, and reproduction in any medium, provided the original work is properly cited.

Renocolic Fistula Secondary to Tuberculosis: A Case Report

Somuah Tenkorang, MD*; Jean-Paul Omana, MD; Bienvenu Shamalirwa Bega, MD; Aboubakry Sow, MD; Soufiane Mellas, MD, PhD; Mohammed Fadl Tazi, MD, PhD; Abdelhak Khallouk, MD, PhD; Mohammed Jamal El Fassi, MD, PhD; Jalal Eddine El Ammari, MD, PhD; Moulay Hassan Farih, MD, PhD

Department of Urology, Hassan II Teaching Hospital, Fez, Morocco

ABSTRACT

Background: Renocolic fistula secondary to tuberculosis has become rare in recent years. The availability of tuberculosis medication and the global campaign towards it's eradication has immensely contributed to this result. The management of renocolic fistula is essentially surgical comprising of a nephrectomy and a resection of the affected segment of the colon. The underlying cause of the fistula needs to determined and must be treated appropriately in order to secure the health of the patient.
Case presentation: We present the case of a 75-year-old Moroccan man who was admitted to our department for perirenal abscess associated with a renocolic fistula. He had a 2 month history of left low back pain, intermittent fever and progressive weight loss. The diagnosis of this patient was established with the help of an abdominal computed tomography (CT) scan. A biopsy of a suspected mass on the CT scan was performed during colonoscopy. Histopathological revealed Tuberculosis (TB) as being the underlying cause of this affection.
Conclusion: Renocolic fistula secondary to TB has recently become rare with no specific clinical and radiological features that allow an easy and sure diagnosis. We therefore present this case report with the view of adding a new and recent case to the English literature. In addition, we will discuss how to best establish diagnosis and manage this disease.

KEY WORDS: Renocolic fistulas; Tuberculosis; Computed tomography (CT) scan.

ABBREVIATIONS: CT: Computed Tomography; TB: Tuberculosis; Z: Pyrazinamid; H: Isoniazid; R: Rifampicin; E: Ethambutol.

INTRODUCTION

Although renocolic fistula is a rare pathology, it is the most common of renoalimentary fistulas. This pathology continues to decrease in frequency in the last 50 years due to early and better management of renal diseases. A variety of etiologies of renocolic fistulas with their mechanisms have been reported. Tuberculosis (TB) used to be the most frequent etiology of all renocolic fistulas but this is no more as treatment medications for tuberculosis and the global campaign towards its eradication have been seriously implemented worldwide.

It is already known that tuberculosis can be an underlying cause for renocolic fistulas. However, the English literature has very few reported cases on this subject. We herein report a renocolic fistula in a 75-year-old Moroccan male diagnosed on a computed tomography (CT) scan. A biopsy of a suspected mass on the CT scan was performed during colonoscopy allowing a histopathological confirmation of TB being the underlying cause of this affection.

This presentation adds a recent case of renocolic fistula secondary to TB to the already existing literature whilst we discuss how to best diagnose and manage this affection.

Openventio PUBLISHERS

ISSN 2572-4665 http://dx.doi.org/10.17140/UAOJ-1-105

CASE REPORT

A 75-year-old Moroccan man was admitted in our department for a 2 month history of left low back pain associated with an irritable bowel syndrome, fever and weight loss.

This patient had a medical history of hypertension and ischemic cardiomyopathy under diuretics, β-blockers and low dose aspirin. There was no preceding history of pulmonary tuberculosis.

Physical examinations found the patient in an altered general condition. His blood pressure and body temperature was 160/100 mmHg and 38.5 °C respectively. The patient had a left flank pain and tenderness.

Laboratory test of the patient were as follows: Hemoglobin=8 g/L, white blood cells=12000 /mcL with an 80% neutrophil pre-dominance, C-reactive protein=266 mg/L, Blood urea nitrogen=0.83 g/L, Creatinine=16 mg/L, Urine culture grew *Escherichia* coli (E.coli).

An abdominal ultrasound showed a left perinephric abscess.

An abdominal CT scan with contrast objectified an enhanced heterogenous solid-cystic mass of the mid and lower portion of the left kidney containing gas bubbles, infiltrating the Psoas major muscle and in direct contact with the left colic flexure suggestive of a renocolic fistula (Figures 1 and 2).

A colonoscopy was performed to search for lesions and to evaluate a suspected mass revealed on the CT scan. The colonoscopy revealed a totally obstructive and ulcerative mass located at 40 cm from the anus. This mass appeared as an extrinsic process that had invaded the colon. Biopsies of the mass were performed.

Histopathological examination of the biopsies revealed granulomas composed of multiple epitheliod cells and Langhans giant cells with central caseous necrosis. Diagnosis of TB was established.

An ultrasound guided percutaneous drainage of the perirenal abscess was performed and the patient was put under anti-TB treatment. The patient was programmed for surgery of the fistula but he passed away a week after his admission from septic shock and heart failure.

DISCUSSION

Renocolic fistulas often involve the ascending and descending segments of the colon. This pathology was first described by Hippocrates in 460 B.C.[1] Though it is an ancient pathology, it remains rare with a few reported cases in the English literature.

There are various etiologies of renocolic fistulas but these can be categorized as traumatic or spontaneous.[2] The colon is rarely the origin for renocolic fistulas[3] Spontaneous renocolic fistulas are the most frequent and it's largely caused by urinary

Figure 1: Axial Abdominal Enhanced CT Scan Showing a Left Perinephric Abscess Associated with a Renocolic Fistula.

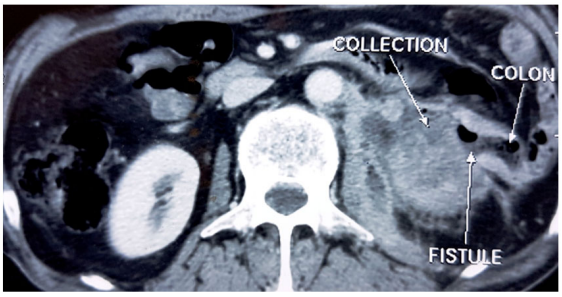

Figure 2: Axial Abdominal Enhanced CT Scan Showng Perinephric Abscess Extending to the Psoas Major Muscle Containing Gas Bubbles.

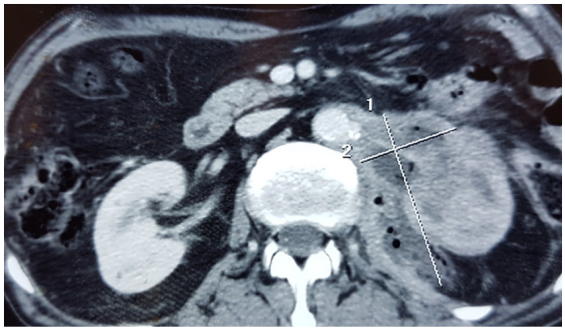

ISSN 2572-4665 http://dx.doi.org/10.17140/UAOJ-1-105

tract tuberculosis and renal calculus.

Urinary tract TB was previously known to be the most frequent etiology[4,5] but pyonephrosis secondary to renal calculus has been a predominant etiology in recent years. This can be explained by the availability of medications and efficient management of tuberculosis. Traumatic renocolic fistulas could be iatrogenic or in an event of a severe renal trauma. Iatrogenic causes of renocolic fistulas have reemerged in the last 20 years due to the increased minimal invasive kidney surgeries and percutaneous kidney drainages.[6]

There is no specific clinical sign to diagnose a renocolic fistula. Flank pain and fever are the most frequent symptoms. Pyuria, fecaluria, pnematuria and fever can be occasionally present.[7] Hence, the diagnosis of a renocolic fistula and its underlying cause is largely dependent on radiological imaging. The most useful imaging modalities are CT urography, barium enema, colonoscopy and antegrade or retrograde pyelogram.[8-10] Each imaging modality has its advantages and disadvantages. The CT scan is by far the best imaging modality to establish the diagnosis of renocolic fistula as in our case. Generally, a couple of these imaging modalities are required to determine the presence of a fistula and its underlying cause.

Surgery is the recommended treatment for renocolic fistula. The affected kidney is often not functioning. Thus, the surgery consists of nephrectomy associated with resection of the involved segment of the colon followed by anastomosis of the healthy colon segments.[3,10-12] The underlying affection responsible for the fistula must be treated as well. TB was the cause of the renocolic fistula in our case. For this reason, the patient was put on anti-TB medication. The in 2003, Center for Disease Control (CDC) guidelines recommend a nine month regimen which includes Isoniazid, Rifampicin, and Ethambutol, supplemented with Pyrazinamid during the initial 2 months (Z2H9R9E9).[13-15]

CONCLUSION

Although renocolic fistula has been known since ancient times, it is a rare pathology especially in recent times. Tuberculosis was the frequent cause of spontaneous renocolic fistulas. However, there has been a significant decrease in frequency in the last 50 years.

Radiological imaging plays a critical role in the diagnosis of renocolic fistulas as there are no specific symptoms for this pathology. The CT scan is a better diagnostic tool to diagnose renocolic fistulas.

The management of renocolic fistula requires treating the fistula as well as its underlying cause. Hence, in the case of renocolic secondary to tuberculosis, it is recommended to perform surgery consisting of nephrectomy and colon resection-anastomosis. Anti-TB medication must also be administered.

DECLARATIONS

Ethics approval and consent to participate. Not applicable.

ACKNOWLEDGEMENTS

Not applicable.

AVAILABILITY OF DATA AND MATERIALS

No additional file for data and supporting materials.

CONSENT FOR PUBLICATION

Written informed consent was obtained from the patient for publication of this case report and accompanying images.

CONFLICTS OF INTEREST

The authors declare no conflicts of interest.

FUNDING

None.

AUTHORS' CONTRIBUTIONS

TS prepared the manuscript and is the corresponding author OJP, BBS, SA contributed in the review of the articles MS, TMF, EAJE, KA, EFJM, FMH edited the manuscript. All authors read and approved the final manuscript.

REFERENCES

1. Singh G, Gordon-Harris L. Case report: Tubercular renocolic fistula. *Indian J Radiol Imaging*. 2004; 14: 295-297. Web site. http://ijri.org/article.asp?issn=0971-3026;year=2004;volume=14;issue=3;spage=295;epage=297;aulast=Singh. Accessed February 9, 2017

2. Patil SB, Patil GS, Kundaragi VS, Biradar AN. A case of xanthogranulomatous pyelonephritis with spontaneous renocolic fistula. *Turk J Urol*. 2013; 39(2): 122-125. doi: 10.5152/tud.2013.026

3. Touiti D, Ameur A, Zrara I, et al. Les fistules pyélocoliques à propos d'une observation. *Ann Urol*. 2001; 35(1): 44-46. doi: 10.1016/S0003-4401(01)80012-7

4. Yadav SP, Usha S, Poonam G, Ashwani DK. Reno-colocutaneous fistula: A case report. *Scand J Urol Nephrol*. 1997; 31(4): 411-412. doi: 10.3109/00365599709030632

5. Yadav SP, Usha S, Poonam G, Ashwani DK. Reno-colocutaneous fistula: A case report. *Scand J Urol Nephrol*. 1997; 31(4): 411-412. doi: 10.3109/00365599709030632

ISSN 2572-4665 http://dx.doi.org/10.17140/UAOJ-1-105

6. Chalise PR, Sharma UK, Gyawali PR, Shrestha GK, Joshi BR, Ghimire RK. Renocolic fistula following percutaneous nephrostomy: A case report. *Nepal Med Coll J*. 2009; 11(2): 143-144.

7. Yu NC, Raman SS, Patel M, Barbaric Z. Fistulas of the genitourinary tract: A radiologic review. *Radiographics*. 2004; 24(5): 1331-1352. doi: 10.1148/rg.245035219

8. Mander BJ, Menzies D, Motson RW. Reno-colic fistula. *J R Soc Med*. 1993; 86(10): 601-602.

9. Zafranloo S, Gerard PS, Bryk D. Xanthogranulomatous pyelonephritis in children: Analysis by diagnostic modalities. *Urol Radiol*. 1990; 12(1): 18-21. doi: 10.1007/BF02923958

10. Parasher R, Sasidharan K. Spontaneous reno-colic fistula. *Indian J Urol*. 2000; 17(1): 64-65. Web site. http://www.indianjurol.com/article.asp?issn=0970-1591;year=2000;volume=17;issue=1;spage=64;epage=65;aulast=Parasher. Accessed February 9, 2017.

11. Melvin WS, Burak WE, Flowers JL, Gann DS. Reno-colic fistula following primary repair of the colon: A case report. *J Trauma*. 1993; 35(6): 956. Web site. http://europepmc.org/abstract/med/8263999. Accessed February 9, 2017.

12. Hitter E, Ronge R, Walschap G, et al. Asymptomatic nephrocutaneous fistula: A report of 2 cases. *J Urol*. 1988; 139: 1290-1291. Web site. http://europepmc.org/abstract/med/3373604. Accessed February 9, 2017.

13. American Thoracic Society C. Infectious diseases society of america treatment of tuberculosis. *MMWR Recomm Rep*. 2003; 52: 1-77.

14. Erratum ATS, CDC. Infectious Diseases Society of America Erratum, Treatment of tuberculosis. *MMWR Recomm Rep*. 2005; 53: 1203.

15. Park SH, Yang SK, Yang DH, et al. Prospective randomized trial of six-month versus nine-month therapy for intestinal tuberculosis. *Antimicrob Agents Chemother*. 2009; 53(10): 4167-4171. doi: 10.1128/AAC.00874-09