

Case Series

*Corresponding author
Wilson I. B. Onuigbo, MD, PhD
Department of Pathology
Medical Foundation and Clinic
8 Nsukka Lane
Enugu 400001, Nigeria
E-mail: wilson.onuigbo@gmail.com

Volume 1 : Issue 2
Article Ref. #: 100TFMOJ1108

Article History

Received: October 2nd, 2016
Accepted: October 31st, 2016
Published: November 1st, 2016

Citation

Onuigbo WIB. The morals of the Ibo ethnic group and the abortion deaths among their maidens in Nigeria. *Toxicol Forensic Med Open J*. 2016; 1(2): 52-53. doi: [10.17140/TFMOJ-1-108](https://doi.org/10.17140/TFMOJ-1-108)

The Morals of the Ibo Ethnic Group and the Abortion Deaths Among their Maidens in Nigeria

Wilson I. B. Onuigbo, MD, PhD*

Department of Pathology, Medical Foundation and Clinic, 8 Nsukka Lane, Enugu 400001, Nigeria

ABSTRACT

Among the Ibo or Igbo ethnic group in Nigeria, a “daughter’s chastity” is highly valued. Little wonder that maidens could be tempted to commit abortion to conceal the illegitimate pregnancy. These abortions may have led to the sudden death in 3 cases presented here, in which microscopy revealed chorionic villi in the womb. This is comparable to other published cases of death in pregnancy. The future is important with reference to prevention practices.

KEYWORDS: Pregnancy; Concealment; Abortion; Death; Prevention; Ethnic group; Nigeria.

INTRODUCTION

The intimate work of a British anthropologist, Basden,¹ carried out among the Ibo or Igbo ethnic group in Nigeria is rich in customs. Basden’s work includes the pride in a “daughter’s chastity.” Undoubtedly, on this account, maidens are tempted to conceal illegitimate pregnancy. Thus, this could lead to abortion practices which might end with sudden death. The author’s experience of this tragedy emanated from his headship of a Reference Pathology Laboratory which facilitated the establishment of a histopathology data pool whose utility was promoted by a Birmingham (UK) group² regarding epidemiological analysis. Elsewhere, I mentioned in passing in my book on Expert Evidence,³ that 3 cases occurred locally to my knowledge. Here, I propose to use the experiences gained by local Police Doctors. One of them, Lashari,⁴ reported that he had Tuesdays for police cases including post-mortems and Wednesdays for going to court to testify to his findings although made “some months ago”. What did 3 other Police Doctors see?

CASE HISTORIES

1. OR, a 22-year-old girl, suddenly collapsed and died in a Patent Medicine Store. The owner denied giving any drug to the patient. An autopsy was carried out at the Parklane General Hospital, Enugu, by Dr. Ezeanyagu at the insistence of the Police. PM findings—collapsed left lung and flabby heart. Several pieces of tissues, the largest 4 cm across, were sent to me. There was massive edema of the lungs as well as autolysed looking endometrium.
2. UC, a 19-year-old girl, not married, disappeared from the father’s house. Three days later, she was brought dead to the Queen Elizabeth Specialist Hospital, Umuahia, by the Police. At autopsy by Dr. Akanwa, a bulky uterus was found with retained products.
3. CH, a 17-year-old girl was brought in dead from home by the Police. She was said to be procuring an abortion by taking some indigenous drugs. At autopsy by Dr. Okafor, there was marked hepatomegaly as well as congestion. Marked areola tissue of the breasts was noted with some blood. Clots in the uterus were also present.

Copyright

©2016 Onuigbo WIB. This is an open access article distributed under the Creative Commons Attribution 4.0 International License (CC BY 4.0), which permits unrestricted use, distribution, and reproduction in any medium, provided the original work is properly cited.

REGIONAL PATHOLOGY LABORATORY SERVICE

From 1963, I headed the Reference Pathology Laboratory established by the Government of the Eastern Region of Nigeria. It was on this account that the local histopathology data pool became available for epidemiological analysis, including forensic analysis. Indeed, all 3 above cases were bolstered with the specimens sent to me for an opinion. In all of them, chorionic villi were identified from the wombs (Figure 1).

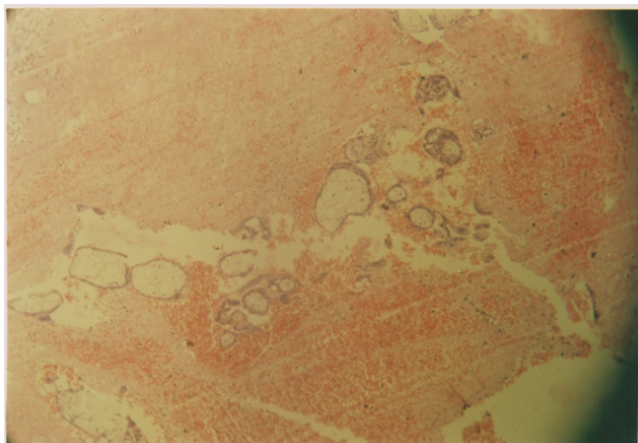


Figure 1: Chorionic villi in the midst of blood.

DISCUSSION

The above mundane cases probably rested to some extent on the administration of unknown drugs including injections which may result in anaphylactic shock. They may be especially contrasted with the sophisticated dimensions found in the world literature.

Thus, one case was in the series from 1972-1975. It was reported by Grimes and Gates and in it, the case involved fatal amniotic fluid embolism that resulted from induced abortion.⁵ Another case was due to air embolism which resulted in a 27-year-old female when the husband had intercourse in the knee-chest position.⁶ The patient was dead on arrival at the hospital. At autopsy, the wall of the uterus crackled with air; air was also present in the uterine veins, vena cava, and jugular veins, while a large amount of air was expelled from the right side when the heart was opened under water.

Unsafe abortion leading to unnecessary maternal mortality was discussed fully by Haddad and Nour,⁷ who highlighted the ominous fact that The World Health Organization (WHO) stated that “every 8 minutes a woman in a developing nation will die of complications arising from an unsafe abortion”. Little wonder that the Lancet⁸ highlighted unsafe abortion as a preventable pandemic.

In this context, a Nigerian report, fortunately, came from the South-western Region.⁹ The report concluded that “The rate of women seeking repeat abortions is high in Nigeria, the

rate of contraceptive use is low while contraceptive failure rate is high”. Wide literature searches were undertaken from 1970-2006 concerning the 11-24 years age group by Williamson and her associates.¹⁰ As they concluded, “young women often relied on traditional methods of abortion”. Perhaps, in the final analysis, let us listen to one Sedgh¹¹: “Despite recent declines, teen pregnancy rates remain high in many countries. Research on the planning status of these pregnancies and on factors that determine how teens resolve their pregnancies could further inform programs and policies”.

REFERENCES

1. Basden GT. *Niger Ibos*. London, UK: Cass; 1966: 214.
2. Macartney JC, Rollaston TP, Codling BW. Use of a histopathology data pool for epidemiological analysis. *J Clin Pathol*. 1980; 33: 351-353. doi: [10.1136/jcp.33.4.351](https://doi.org/10.1136/jcp.33.4.351)
3. Onuigbo WIB. *Expert Evidence*. Enugu, Nigeria: Medical Foundation Publishers; 2007: 97.
4. Lashari MS. A week in the life of Dr. MS Lashari. *Afr Hlth*. 1982; 48.
5. Grimes DA, Cates W. Fatal amniotic fluid embolism during induced abortion, 1972-1975. *South Med J*. 1977; 70(11): 1325-1326. Web site. <http://europepmc.org/abstract/med/918701>. Accessed October 1, 2016.
6. Lifschultz BD, Donoghue ER. Air embolism during intercourse in pregnancy. *J Forens Sci*. 1983; 28(4): 1021-1022. doi: [10.1520/JFS11615J](https://doi.org/10.1520/JFS11615J)
7. Haddad LB, Nour NM. Unsafe abortion: Unnecessary maternal mortality. *Rev Obstet Gynecol*. 2009; 2(2): 122-126. Web site. <https://www.ncbi.nlm.nih.gov/pmc/articles/PMC2709326/>. Accessed October 1, 2016.
8. Grimes DA, Benson J, Singh S, et al. Unsafe abortion: The preventable pandemic. *Lancet*. 2006; 368(9550): 1908-1919. doi: [10.1016/S0140-6736\(06\)69481-6](https://doi.org/10.1016/S0140-6736(06)69481-6)
9. Lamina MA. Prevalence of abortion and contraceptive practice among women seeking repeat induced abortion in Western Nigeria. *J Preg*. 2015; 2015: 1-7. doi: [10.1155/2015/486203](https://doi.org/10.1155/2015/486203)
10. Williamson LM, Parkes A, Wight D, Petticrew M, Hart GJ. Limits to modern contraceptive use among young women in developing countries: A systematic review of qualitative research. *Reproduct Hlth*. 2009; 6: 3. doi: [10.1186/1742-4755-6-3](https://doi.org/10.1186/1742-4755-6-3)
11. Sedgh G, Finer LB, Bankole A, Eilers MA, Singh S. Adolescent pregnancy, birth, and abortion rates across countries: Levels and recent trends. *Adoles Hlth*. 2015; 56(2): 223-230. doi: [10.1016/j.jadohealth.2014.09.007](https://doi.org/10.1016/j.jadohealth.2014.09.007)